

Effect of acrylamide on urinary bladder of adult male albino rats (histological and Immuno-histochemical study)

Abeer Fareed Abd El-Naeem^{a*}, Rania Ahmed Radwan^b, Zahraa Mohamed Ismael^a

^aDepartment of Human Anatomy and Embryology, Faculty of Medicine, Sohag University, Sohag, Egypt

^bDepartment of Forensic Medicine and Clinical Toxicology, Faculty of Medicine, Sohag University, Sohag, Egypt

Abstract

Background: Acrylamide is a widespread chemical that is used in industries and its exposure is wide from certain cooked foods like potato chips. Nevertheless, this chemical is approved to be dangerous to many organs.

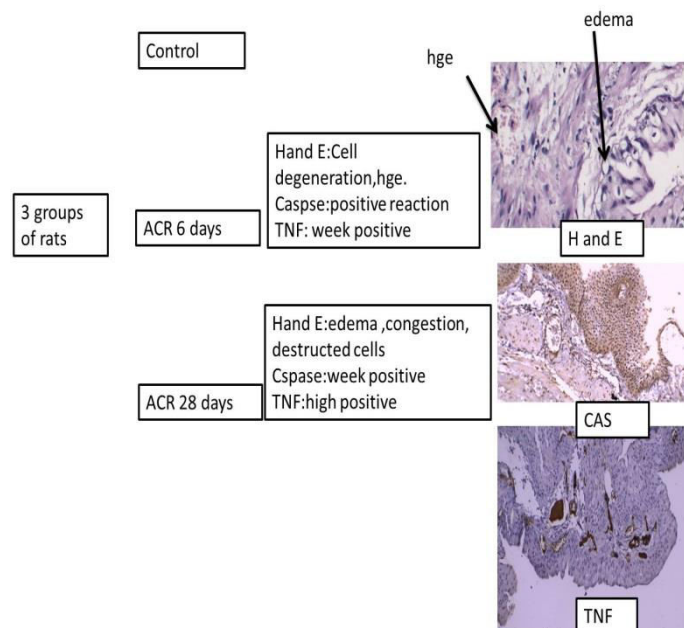
Objectives: revealing the effect of acrylamide on the histological structure of the urinary bladder.

Materials and methods: this research was done on a number of 30 adult male rats, which were divided equally into 3 groups: control group I: Without treatment, group II: treated with acrylamide 5mg orally for 6 days, group III: treated with acrylamide 5mg for 28 days. The rats were then sacrificed and the bladder was taken and prepared for histological and Immuno-histochemical study.

Results: After 6 days, the rats showed destruction of epithelium, congestion, and muscle thinning, then after 28 days, the epithelium showed edema, more congestion, and more thinning. With Caspase-3, the rats showed more reaction after 6 days than after 28 days, with tumor necrosis factor (TNF); the expression of the gene increased after 28 days.

Conclusion: Acrylamide is toxic to the bladder even for a short duration and should be avoided as possible.

Keywords: Acrylamide; Bladder; Caspase; TNF.



DOI: 10.21608/svuijm.2023.241494.1718

*Correspondence: abeerfareed167@gmail.com

Received: 15 October, 2023.

Revised: 14 November, 2023.

Accepted: 18 November, 2023.

Published: 25 December, 2023

Cite this article as: Abeer Fareed Abd El-Naeem, Rania Ahmed Radwan, Zahraa Mohamed Ismael (2023). Dacron Band versus de Vega Annuloplasty for Functional Tricuspid Regurgitation. *SVU-International Journal of Medical Sciences*. Vol.6, Issue 2, pp: 934- 946.

Copyright: © Abd El-Naeem et al (2023) Immediate open access to its content on the principle that making research freely available to the public supports a greater global exchange of knowledge. Users have the right to Read, download, copy, distribute, print or share link to the full texts under a [Creative Commons BY-NC-SA 4.0 International License](https://creativecommons.org/licenses/by-nc-sa/4.0/)

Introduction

Acrylamide (ACR) is an organic pollutant with the chemical formula $\text{CH}_2=\text{CHC}(\text{O})\text{NH}_2$ which is created when reducing sugars and asparagine reaction. It is a solid odorless, white, and a water-soluble component (Kim et al., 2017).

It is known to have many applications in industry: e.g. processing of wastewater. ACR is also widely used in molecular labs and is found in some foods that have been prepared at very high temperatures greater than $120\text{ }^\circ\text{C}$ ($248\text{ }^\circ\text{F}$), especially starchy foods like potato chips., pieces of bread, and biscuits, not in boiled food, or non-heated foods (Cortes et al., 2021 and Peris-Camarasa et al.,2023).

However, The International Agency for Research on Cancer (IARC) has classified ACR as a carcinogenic component to humans and its hazards affect multiple organs. It enters the body through the skin, inhalation, and the gastrointestinal tract. 50% of it eliminates in urine within 24 hrs. One of its metabolites Glycidamide, causes cell damage, and this is because it interacts with DNA to form toxic metabolites in both human and animal tissues (Benford et al.,2022; Adani et al.,2020 and Panel 2015).

The urinary bladder is an important organ in the urogenital system, it is responsible for urine storage and elimination (Chung et al., 2012). The process of micturition depends on the muscle action of the bladder and the urethral sphincter (Ferreira et al., 2023).

One of the main functions of the urogenital system is to eject toxic substances and metabolites with urine from the body

(Hickling et al., 2015). Furthermore, the bladder epithelium (urothelium) considered a good barrier against bacteria and urinary toxic substances (Ke et al., 2019). So if there is a disease that affects the urinary bladder it affects health and quality of life (Orabi et al., 2013). Therefore the aim of the work was to study the effect of exposure to ACR on the histological structure of the bladder.

Materials and methods

Chemicals

Acrylamide: ($\text{C}_3\text{H}_5\text{NO}$), >99.5% pure, odorless, colorless, dissolved in distilled water, purchased from Hi-Lab company, Egypt.

Animals and Experimental design

30 adult male albino rats; two months old, weighing 200 to 300 g on average, bought from the Animal house of Sohag University. The animals were kept in the animal house, and housed in plastic cages with good hygienic conditions. They had free access to food and water. They were adapted to this environment for 1 week prior to the experiment. Animal manipulation through the study comply with the ARRIVE guidelines and carried out in an accordance with the U.K animals. The Institutional Animal Care and Use Committee (IACUC) of Sohag University accepted this research under number (5-12-2023-06).

Animals were randomly divided into three groups: **Group I: control group:** 10 rats were kept with no treatment. **Group II:** 10 rats were treated with 5mg/kg ACR orally daily (Yener et al., 2016) for 6 days. **Group III:** 10 rats were treated with 5mg/kg ACR orally daily (Yener et al., 2016) as in the previous group for 28 days. 24hrs, after the last dose all the animals

were anesthetized by ether inhalation and sacrificed.

Samples preparation for histological study: The urinary bladders from all rats were completely removed, cleaned with saline, evacuated of any remaining urine, and then dried on a filter paper. They were fixed in buffered 10 % formaldehyde for 24 hours. Serial cross-sections 5-7 μ m thick from each bladder was taken from samples that were embedded in paraffin and stained with hematoxylin and eosin and photographed at magnifications of X100 and X400 (Bancroft, and Gamble, 2008).

A score for hemorrhage, edema, and the ulcer was done on sections $\times 40$ objective, and scaled from 0 (normal), 1 (mild) < 25%, 2 (moderate) 25-50%, and 3 (severe) > 75%, ulceration also scored as 0 (normal), 1 (local erosion), 2 (widespread epithelial erosion), 3 (sub mucosal ulcer) (Özcan et al., 2005).

Measurement of the immune reaction

In the paraffin sections, this was accomplished using the streptavidin-biotin-peroxidase method. Sections in paraffin (5-7 μ m thick) were 1st de-paraffinized, and after retrieval of the antigen, with citrate buffer 95 °C, hydrogen peroxide 3 % (v/v) was added for thirty minutes. Sections were then treated with:

- A. Caspase-3 (CPP32) Ab-4, rabbit polyclonal antibody (1:100 dilution) (Aydogan et al., 2014).
- B. Tumor necrosis factor (TNF) antibody (Costa et al., 2021).

Then for 30 min with polymer, diaminobenzidine -H₂O₂ solution was used for visualization of antibody binding.

Positive staining for these antibodies was determined by brown cytoplasmic staining.

Statistical analysis

The following measures were taken:

- a. Muscle thickness
- b. Area percent of caspase-3 expression
- c. Area percent of TNF reaction
- d. Score for edema, hemorrhage and ulcer.

Each value was taken from 5 different areas; the mean of each value was analyzed by SPSS (Statistical Package for the Social Sciences) version 16. ANOVA (Analysis of Variance) test was chosen to measure the thickness and area percent between the groups and if it was statistically significant, a post-hoc test was then done to identify variation between each two groups, unpaired t-test was used to compare between mean of score of edema, hemorrhage and ulcer. P value less than 0.05 considered to be statistically significant, ≤ 0.001 considered to be highly significant.

Results

Histological results

Histological examination of the urinary bladder walls of the control group showed the normal structure of the layers of the urinary bladder. It was seen consisting of 3 layers: inner mucosa, sub-mucosa, and muscular, all covered by outer serous layers. The urinary bladder was seen lined with a special type of epithelium (urothelium) or transitional epithelium with abundant wrinkles. This epithelium composed of three cell layers: surface (umbrella) layer, intermediate, and basal layers. The surface layer cells appeared flat, tightly interconnected cells having one or more nuclei. Basal and intermediate cells

appeared smaller having one nucleus. The intermediate layer arranged in several layers

while the basal cell layer was presented by a single layer of epithelial cells (**Fig.1**).

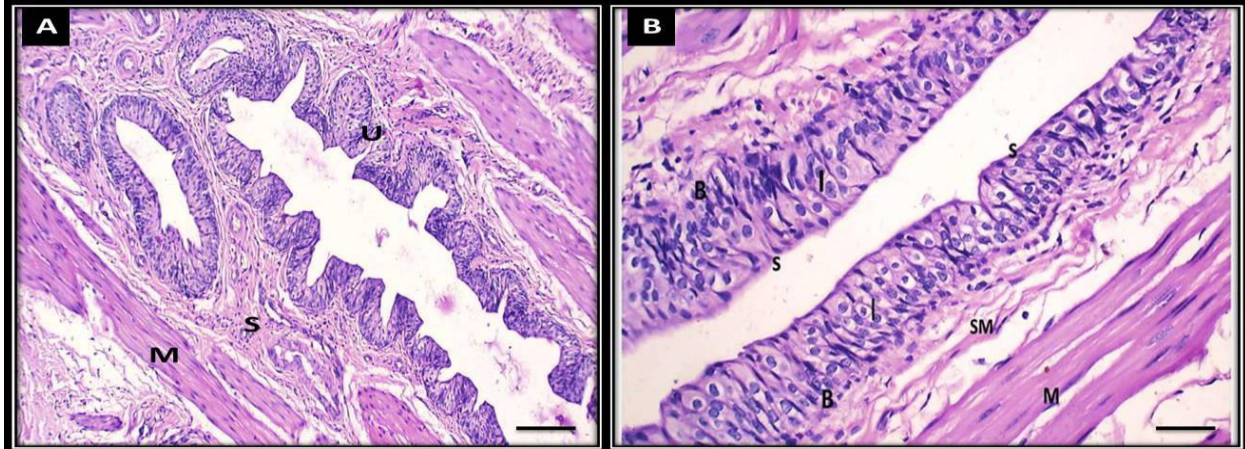


Fig 1. Photomicrographs of sections in the bladder of an adult control group I rats: (A) The layers of the bladder; inner urothelium (U), sub-mucosa (S), musculosa (M). (B) The urothelium is composed of surface flat cells (S), intermediate (I) and basal (B) multinucleated cells. Sub-mucosa is seen (SM) and muscle layer (M) (H&E scale bar: A 200 μ m X 100 and-B : 50 μ m \times 400).

Group II: after 6 days of treatment with ACR rats showed histopathological changes appeared in the form of discontinuation of the surface epithelium, the sub-mucosa appeared with moderate congestion, the muscle layer appeared fragmented. With a high magnification the

epithelium appeared with the destruction of the surface cells, degeneration of the cells appeared and some cells appeared with edema (**Fig. 2**). One rat of this group showed severe hemorrhage in all layers of bladder (**Fig. 3**).

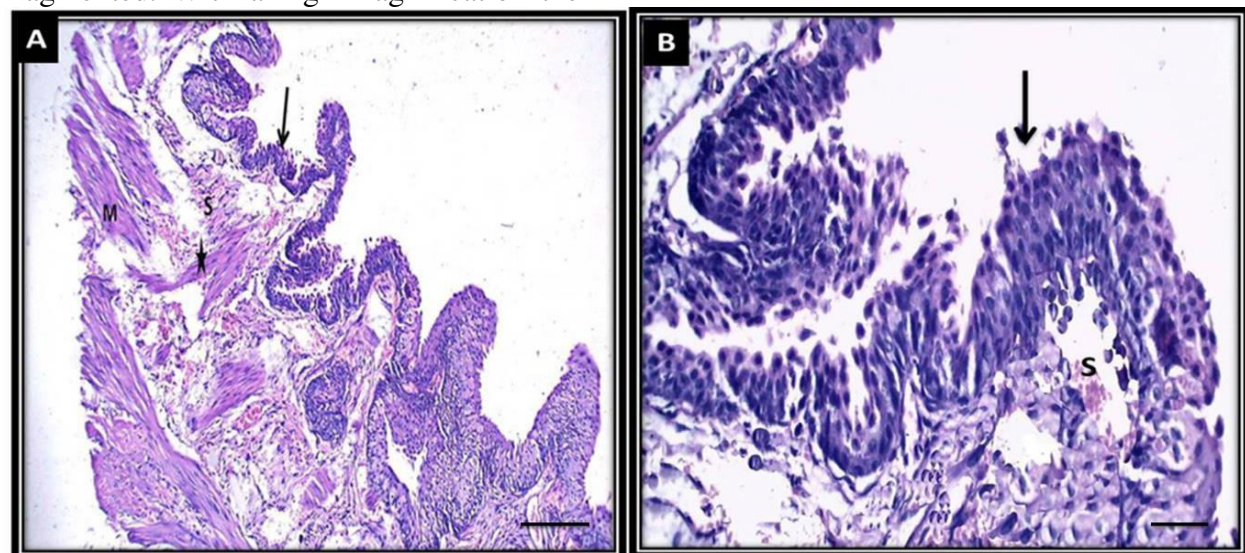


Fig 2. Photomicrograph of H&E section in bladder of adult rats of group II: (A) destruction and erosion of urothelium (arrow), sub-mucosa has moderate congestion (S), the muscle (M) is destroyed (star) (B) destruction and ulceration (arrows) are seen, mild congestion appears in sub-mucosa (S) (scale bar : A 200 μ m X 100 -B : 50 μ m \times 400).

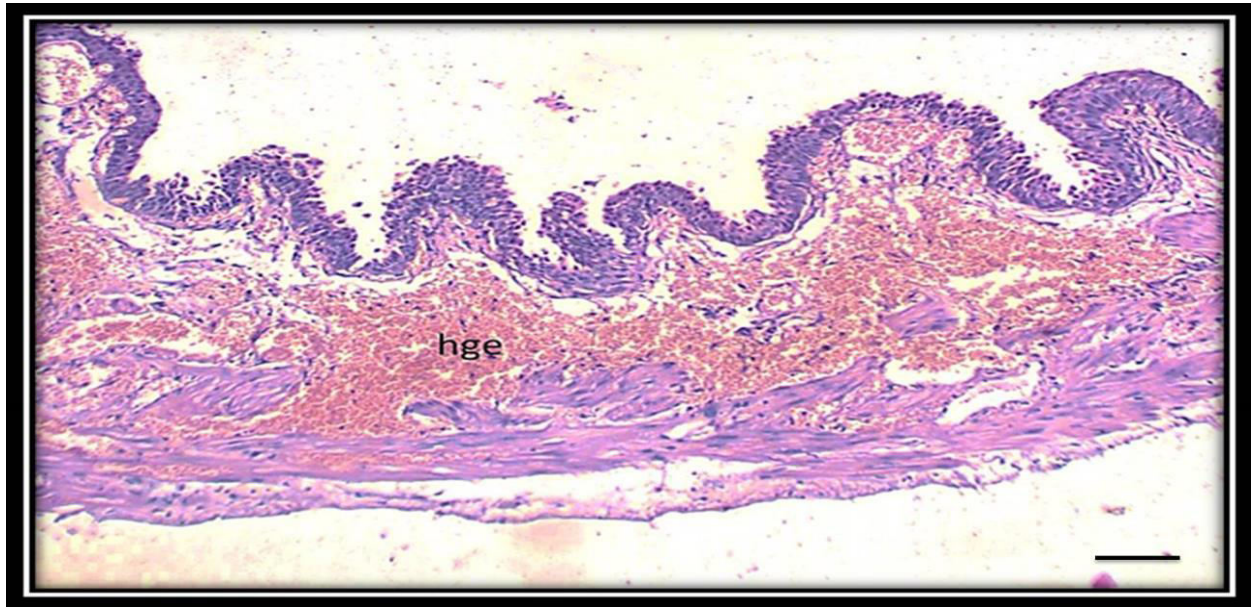


Fig 3. A photomicrograph of a section in the bladder of a rat of group II, showing severe hemorrhage in all the layers (hge) (H&E scale bar: A 200 μ m X100).

Group III: Administration of acrylamide for 28 days showed some changes; the epithelium became thinner but less destructed than in the control group and group II, more congestion of the vessels, and the muscles appeared thinner than the control group and group II. With a high

magnification more edematous cells appeared, degeneration and lymphatic infiltration appeared also, more thinning of the muscles was noticed (**Fig. 4**). The degree of ulceration, hemorrhage, edema are scored in (**Table .1**).

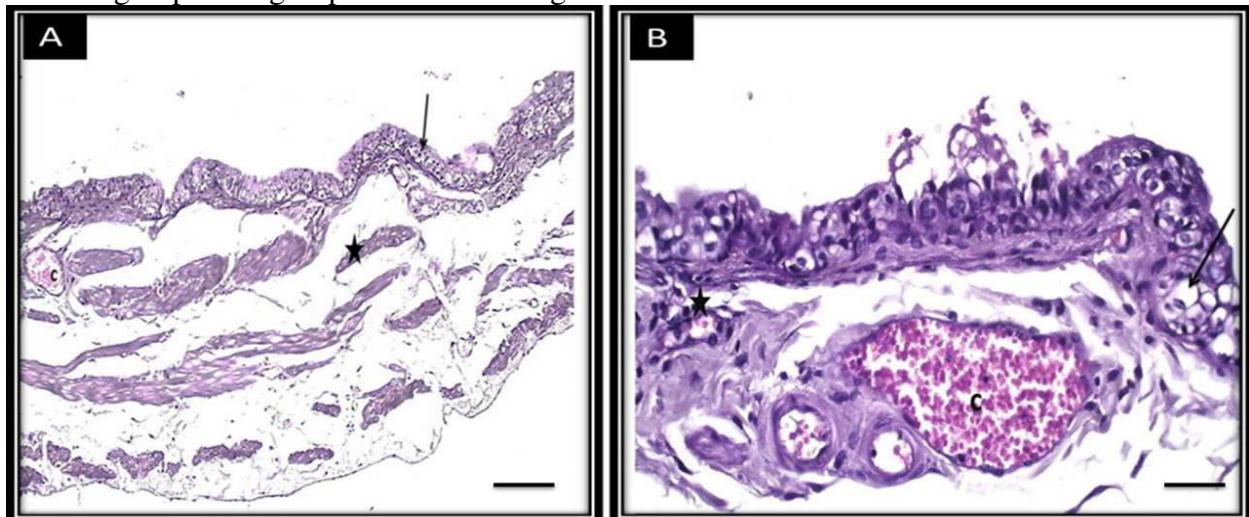


Fig 4. Photomicrograph of section in bladder of adult rats of group III: (A) thinning of epithelium (arrow), dilated congested vessel in sub-mucosa (C), thin muscles (stars) (B) the epithelium appears destructed with edema (arrow), severe congestion in the vessel (C), and some lymphatic infiltration (stars) (H&E scale bar : A 200 μ m X 100 and -B : 50 μ m X400).

Table .1. Score of ulcer, hemorrhage and edema : (p1) difference between the control and group II, (p2) difference between group II and Group III

Variables	Control	Group II	Group III	P1	P2	P3
Ulcer	0(0-0)	1.7(1-2)	1.2(1-2)	0.00	0.02	0.00
Hemorrhage	0.2(0-1)	1.6(1-3)	1.8(1-2)	0.00	0.51	0.00
Edema	0(0-0)	1.2(1-2)	1.9(1-2)	0.00	.001	0.00

Immunohistochemistry results

With caspase-3: Immune stained sections of the bladder with caspase-3 exposed week positive cytoplasmic reaction to caspase-3 in the control group that increased highly in the urothelium and around blood vessels after 6 days exposure to acrylamide, then after 28 exposure to it, rats exposed

moderate positive reaction in urothelial cells and slightly around blood vessels (Fig. 5).

With TNF: the control group expressed a negative reaction to this antigen, while after 6 days of ACR treatment, the reaction became positive in the sub-mucosa, after 28 days, the reaction appeared clearly in the urothelium and sub-mucosa (Fig.6)

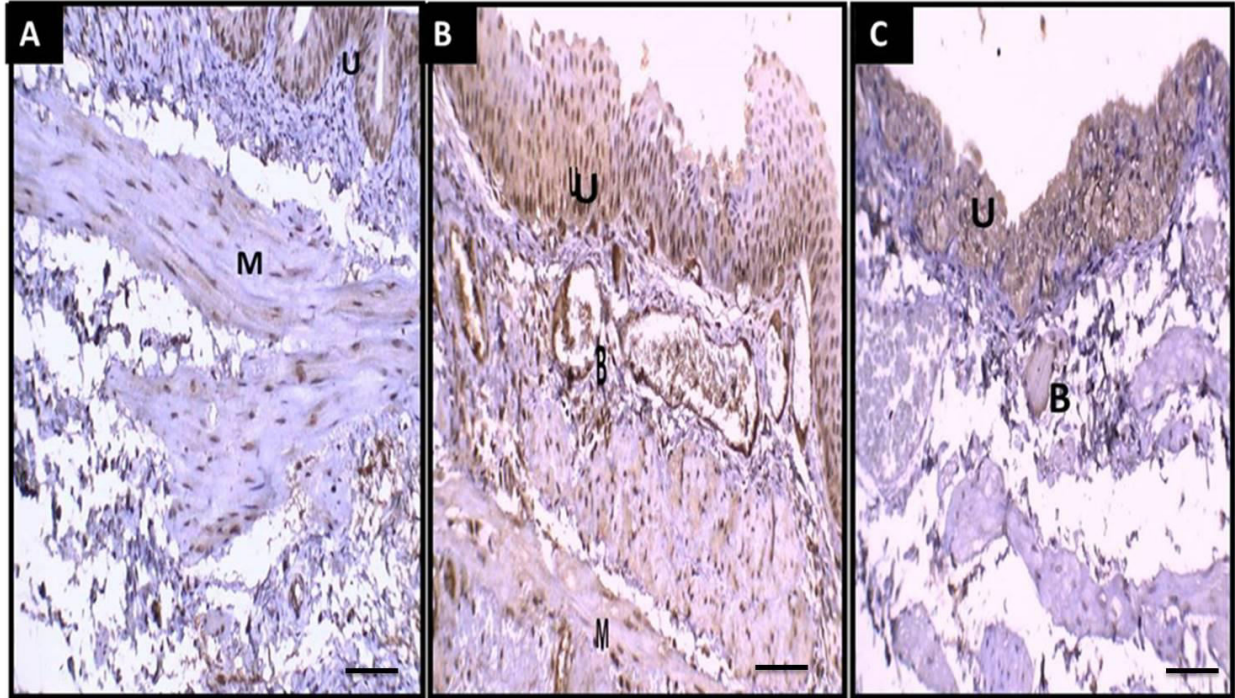


Fig.5. Photomicrographs of Caspase- 3 stained bladder sections in the three groups: control group I (A) showing a week positive reaction to the antigen on the urothelium (U) and muscles (M), group II (B) shows highly positive reaction with caspase-3 exposed in urothelium (U), around blood vessels (B), and in the muscles, group III (C) expresses moderate reaction which appears in urothelium and week around vessels (Scale bar 50 μ m X400).

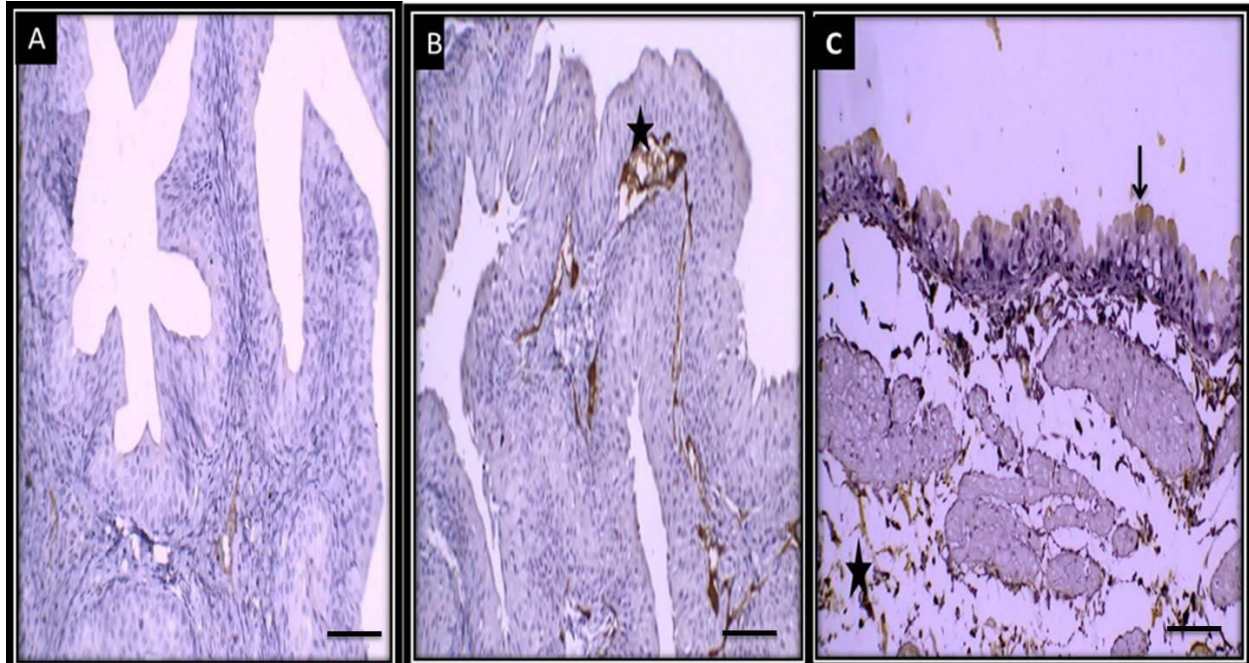


Fig 6. Photomicrographs of TNF stained bladder sections in the three groups : (A) control group I shows negative reaction to the antigen, (B) group II expresses weak positive reaction in sub-mucosa and between muscles (stars), (C) group III expresses more reaction to the antigen in urothelium (arrow) and in sub-mucosa (stars) (Scale bar μm 75 \times 200).

Statistical results (Table2, Figures 7, 8, 9)

The mean muscle thickness was highest in the control group, this thickness decreased highly after 6 days of treatment with ACR ($P=0.00$), then decreased more after 28 days of treatment ($p=0.00$).

Caspase-3 area percent was highest in group II, then group III, followed by the control group I with highly significant difference between control group I and group II and between group II and group III ($p=0.00$) but no significant change between control group I and group III was noticed ($p=2.16$).

TNF area percent in group II was lower than group III, but higher than the control group, with highly significant change between them ($p=0.00$).

Table 2 . Differences between the groups in statistical results

Variables	Control	Group II	Group III	P1	P2	P3
Muscle thickness by pixel	167.1 \pm 17,2	88.92 \pm 18.533	48.49 \pm 12.104	0.00	0.00	0.00
Caspase area percent	13.95 \pm 2.66%	23.91 \pm 4.43%	16.32 \pm 2.91%	0.00	0.00	0.216
TNF area percent	1.24 \pm 0.718%	4.7572 \pm 0.536%	11.35 \pm 1.09%	0.00	0.00	0.00

(p1) difference between the control and group II, (p2) difference between group II and Group III, (p3) difference between the control and Group III

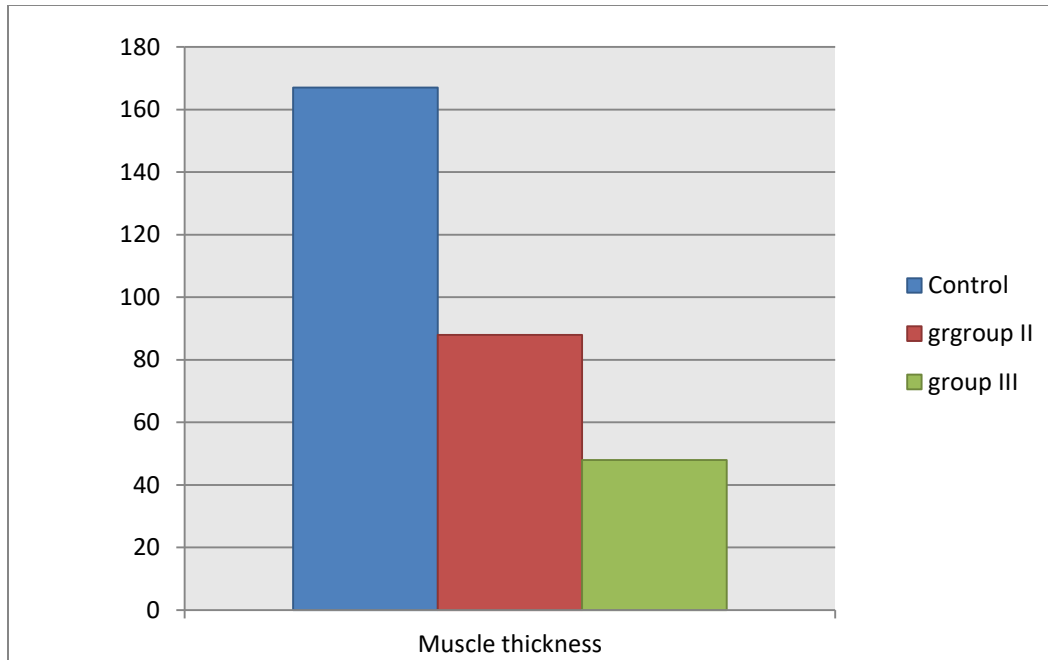


Fig. 7. Muscle thickness in pixel in the different groups

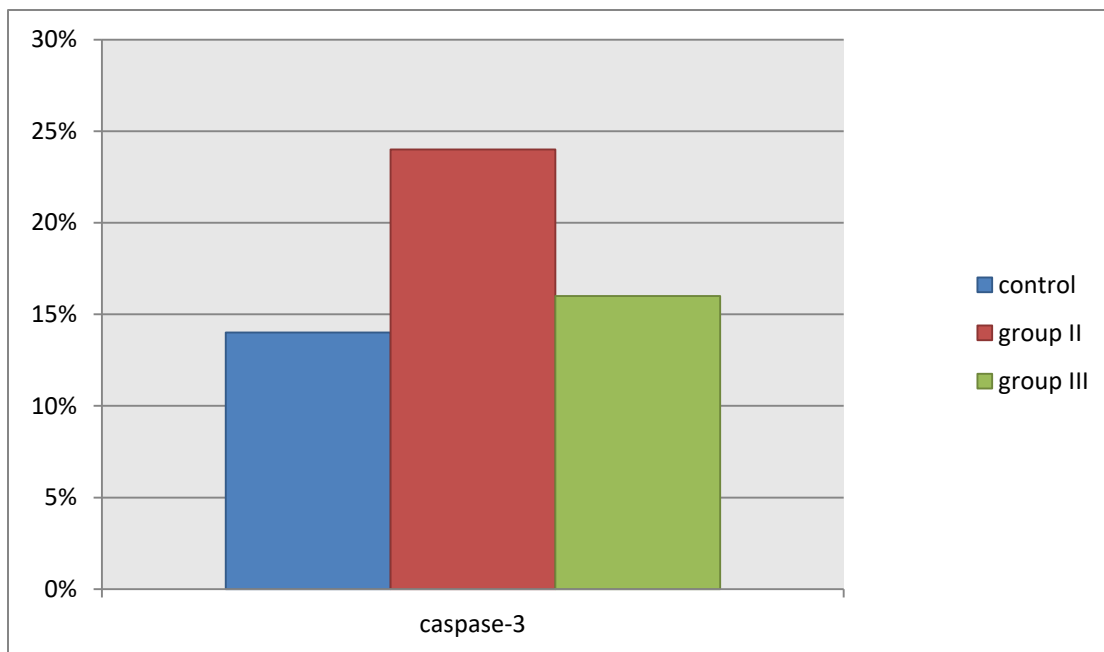


Fig8: Caspase-3 area percent in the different groups

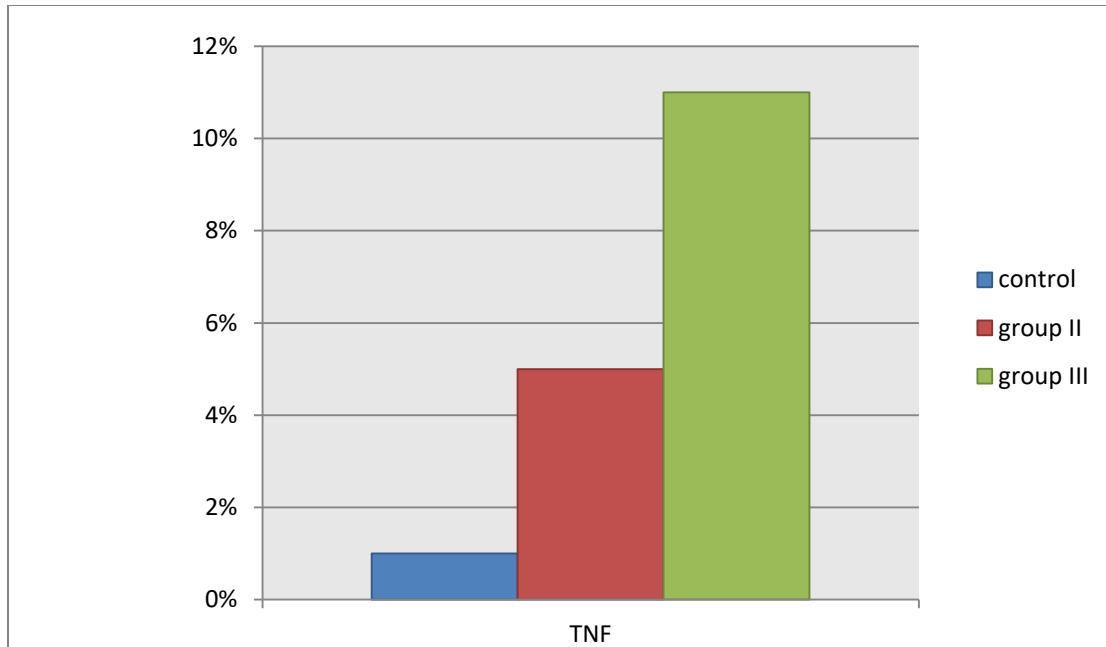


Fig.9. TNF area percent in the different groups

Discussion

This research studied the histological changes of the urinary bladder with different durations of ACR. The current study used male animals to avoid any role of hormonal changes of female estrus cycles on the values achieved as said by **Hegazy et al. (2032)**. In this study, we noticed that the oral treatment of ACR for 6 days and 28 days generated structural changes in all layers of the urinary bladder, in the form of urothelial damage, edema, congestion, and muscle thinning. That increased with increasing the duration of intake i.e. 28 days had more destruction than 6 days except ulceration which decreased as a trial for adaptation of the cells.

These results were in agreement with **Rajeh and Al-Dhaheri (2017)** who reported that a brief period of ACR administration showed harmful effects on the kidney structure in the form of distended Bowman's capsule, tubular degeneration and intertubular congestion in the renal cortex, extensive tubular damage with epithelial thinning and cytoplasmic cellular

infiltrations. **Romaniuk et al. (2017)** reported in a study on heavy metals on the bladder that 90 days treatment showed signs of adaptation than 30 days treatment which agreed with our results.

Elhelaly et al. (2019) showed that the increased DNA oxidative damage and decreased antioxidant enzyme activities caused by acrylamide-induced toxicity resulted in destruction of many organs as brain, kidneys, and liver.

ACR is a significant community health fear as it is widely generated in the daily food such as; fried bread, potato chips, any high-temperature carbohydrate-rich food, coffee, and cosmetics (**Ali et al ., 2020**).

ACR is excreted mainly via urine and bile. It has worse effects on different systems as the urinary, genital, neurological, and immunological systems in animal and human models by many studies (**Rajeh and Al-Dhaheri, 2017**), nevertheless few studies done on its acute effect on the urinary bladder are available

Many studies were done to study the effect of ACR on different systems of the

body to understand dose affecting health problems compared with nutritive intake. (Thangamany et al., 2023) said that the toxic effect of ACR occurs mainly due to disturbance in the antioxidant system in the body or by stimulation of apoptosis of the cells.

As ACR is highly obtainable in daily food, so its risk to human health needs urgent attention; its concentration in fried potato products reached 1 mg/kg, while its concentration in coffee was 4 mg/kg. Moreover, the European Commission stated that the acrylamide residue limits in roast coffee and potato chips were 400-850 g/kg and 750 g/kg, respectively as reported by Powers et al., and Pundir et al (2019)

Reactive oxygen species (ROS) is a known term that incorporates a variety of chemical species that contain oxygen, including superoxide, peroxides, alpha-oxygen, and the hydroxyl radical (Hayyan et al., 2016).

ROS production increased sharply due to many abnormal circumstances (e.g., toxins, heat exposure, and ultraviolet radiation), which can seriously harm the cellular structure (Babizhayev, 2016). ACR could interact with DNA base, 2-deoxyguanosine, and induced 8-OHdG formation which indicated that acrylamide exposure probably contributed to ROS formation and lead to the higher 8-OHdG level (Endah et al., 2023).

In this research, we noticed that caspase-3 expression was high after 6 days of treatment. This was expressed and accepted by (Eom et al., 2023) who said that ROS generates cytochrome c release from the mitochondria into the cytoplasm, which starts and controls the apoptotic cascade, and it induces Caspase activation. By cleaving at a particular location, initiator Caspase triggers caspase-3.

Additionally, ROS prevents organelles' oxidative defense mechanisms

from working properly, which causes a variety of illnesses like cancer and diabetes (Totten et al., 2021) .

TNF is a pleiotropic cytokine that is associated with many disorders, TNF is released by mast cells and increased bacterial infection, cancer, and interstitial cystitis (Yang et al., 2018).

In our study with the TNF marker, we found that the control group expressed a negative reaction to this antigen, while after 6 days of ACR treatment, the reaction became positive in the sub-mucosa, and after 28 days the reaction appeared clearly in the urothelium and sub-mucosa. This was agreed with sant et al. (2007); Chan et al. (2013), Rao et al. (2016) who found that TNF has been involved in various urinary bladder diseases, such as bacterial infection, tumors, and infiltrative colitis, as mast cell activation leads to the release of TNF that motivates urothelial apoptosis and lesion formation mediated by TNF receptor.

Jiang et al. (2021) also said that oral administration of ACR caused a significant increase ($P < 0.01$) in the levels of pro-inflammatory cytokines such as TNF- α , IL-1 β , and IL-6 Previous research done by Zhao et al. (2017) approved that ACR-induced neurotoxicity is expressed by increased levels of TNF- α , IL-6, and IL-1 β in the primary microglia during the later stage of ACR exposure.

However many researches were done in trial to counteract the dangerous effect of ACR on the body using natural components, vitamins or drugs e.g. (Hegazy et al., 2018) who approved that Vitamen E had protective effect against ACR on the liver of postnatal rats. Thangamany et al . (2023) reported that food containing lot of vegetables and fruits can give the cells the power of support against ACR destructive effect due to its antioxidant content. Mahmoud et al. (2023) reported that T. satureioides polyphenolics and essential oil could counteract the toxic

effect of ACR on the liver. **Al Syaad et al. (2023)** reported that propolis which is a plant extract had a protective effect against ACR toxicity on male rats.

Conclusion

Exposure to ACR is dangerous to the histological tissue of the urinary bladder even for a short duration.

Limitations of the study

More researches on lower doses will be needed to know if they are safe or not. Also this research studied only histological view, it's better to study also biomarkers of the body.

Funds

No funds

Conflict of interest

There is no conflict of interest.

Authors' contribution

ZA: Designed the study and forms data collection and data analysis, AA : Writing review ,statistical analysis, revision.

References

- **Adani G, Filippini T, Wise L, I Halldorsson T, Blaha L, and Vinceti M(2020)**. Dietary Intake of Acrylamide and Risk of Breast, Endometrial, and Ovarian Cancers: A Systematic Review and Dose-Response Meta-analysis. *Cancer Epidemiol Biomarkers Prev.*, 29(6):1095-1106.
- **Ali A, Ibrahim R, Ahmed A , Talaat E (2020)**. Histological Study of Toxic Effects of Acrylamide on the Liver and Kidney of Adult Male Albino Rats. *MJMR*; 31 (3): 345-350.
- **Aydogan A, Kocer G, Ozmen O, Kocer M , Onal L, Koskan O (2014)**. Immunohistochemical expression of caspase-3, caspase-5, caspase-7 and apoptotic protease-activating factor-1 (APAF-1) in the liver and kidney of rats exposed to zoledronic acid (ZOL) and basic fibroblast growth factor (bFGF). *Vet Q.*, (34):137–142.
- **Babizhayev MA (2016)**. Generation of reactive oxygen species in the anterior eye segment. Synergistic codrugs of N-acetylcarnosine lubricant eye drops and mitochondria-targeted antioxidant act as a powerful therapeutic platform for the treatment of cataracts and primary open-angle glaucoma. *BBA Clin.*; 6:49–68.
- **Bancroft JD, Gamble M (2008)**. Theory and practice of histological techniques. Elsevier health sciences, Textbook ed 6 pages: 126-127.
- **Benford D, Bignami M, Chipman JK, Ramos Bordajandi L (2022)**. Scientific report on the assessment of the genotoxicity of acrylamide. *EFSA*; 20 (5):45-47.
- **Chan CY, St John AL, Abraham SN (2013)**. Mast cell interleukin-10 drives localized tolerance in chronic bladder infection, *Immunity*; 38: 349 –359.
- **Chung BI, Sommer G, Brooks JD (2012)** .Anatomy of the lower urinary tract and male genitalia in Campbell-Walsh Urology, A. J. Wein, L. R. Kavoussi, A. C. Novick, A. W. Partin, and C. A. Peters, Eds., chapter 2, Saunders, Philadelphia, Pa, USA, 10th edition, pages: 33-70.
- **Cortes W, Vasquez S, Suárez-Mahecha H (2021)**. Consumption study and margin of exposure of acrylamide in food consumed by the Bogot ' a population in Colombia. *J Food Compost Anal.*, 100(2).
- **Costa A, de Sousa L, Alves J, Goes P, Pereira K, Alves A, et al. (2021)**. Anti-inflammatory and hepatoprotective effects of quercetin in an experimental model of rheumatoid arthritis. *Inflammation*; 44 (5): 2033-2043.
- **Elhelaly AE, Albasher G, Alfarraj SA, Almeer RS, Bahbah EI, Fouda M, et al. (2019)**. Protective effects of

- hesperidin and diosmin against acrylamide-induced liver, kidney, and brain oxidative damage in rats. *Environ Sci Pollut Res Int.*, 26: 35151–35162.
- **Endah D, Budiawan , Dani I(2023).** Confirmation DNA damage through in vitro study of formation DNA adduct 8-OHdG as biomarker caused by acrylamide exposure . *Appl Phys Lett.*, 2673(1):5-7.
 - **Eom J, Lim J , KimH (2023).** Lutein Induces Reactive Oxygen Species-Mediated Apoptosis in Gastric Cancer AGS Cells via NADPH Oxidase Activation. , 28(3): 1178-1180.
 - **Ferreira A, Nascimento D, Cruz C(2023).** Molecular Mechanism Operating in Animal Models of Neurogenic Detrusor Overactivity, A Systematic Review Focusing on Bladder Dysfunction of Neurogenic Origin. *Int J Mol Sci.*, 24(4): 3273-3274.
 - **Hayyan M, Hashim MA, AlNashef IM(2016)** .Superoxide ion: generation and chemical implications. *Chem Rev.*, 116:3029–3085.
 - **Hegazy AA, Qenawy NM, Abdel Aziz NM , El- Bestawy EM (2023).** Possible protective role of capsaicin against high fat diet effects on liver and gall bladder of adult male mice. *Egypt J Histo.*, 46(3):245-262.
 - **Hegazy AA, Morsy MM, Shehata MA , Agaga RA(2018).** Effect of Administration of Acrylamide and Possible Protective Role of Vitamin E on Postnatal Rat Liver Structure, *J Embryol Stem Cell Res.*, 2(2):1-14.
 - **Hickling DR, Sun TT, Wu, XR(2015).** Anatomy and physiology of the urinary tract, Relation to host defense and microbial infection. *Microbiol Spectr.*, 3(4)1-29.
 - **Jiang G, Lei A, Chen Y, Yu Q, Xie J, Yang Y, et al.(2021).**The protective effects of the *Ganoderma atrum* polysaccharide against acrylamide-induced inflammation and oxidative damage in rats. *Food Funct.*, 12: 397–407
 - **Ke Q, Jhang J , Lin T, Ho H, Jiang Y, Hsu Y , Kuo H(2019).** Therapeutic potential of intravesical injections of platelet-rich plasma in the treatment of lower urinary tract disorders due to regenerative deficiency. *Ci Ji Yi Xue Za Zhi.*, 31(3):135-143.
 - **Kim H, Lee SG, Rhie J(2017).** Dermal and neural toxicity caused by acrylamide exposure in two Korean grouting workers: a case report. *Ann Occup Environ Med.*, 29:1–6.
 - **Mahmoud MF, Elrashidy RA, Mohammed HO, Mahdi DB , Sobeh M (2023).** Essential oil and polyphenolics from *Thymus satureioides* Coss. Counteract acrylamide-induced liver toxicity through suppression of NLRP3 inflammasome/NF- κ B axis. *Journal of Functional Foods*; (107):1-15.
 - **Orabi H, Bouhout S, Morissette A, Rousseau A, Chabaud S, Bolduc S(2013).** Tissue engineering of urinary bladder and urethra, advances from bench to patients *ScientificWorldJournal.*, 154564
 - **Özcan A, Korkmaz A, Oter S, Coskun O(2005).** Contribution of flavonoid antioxidants to the preventive effect of MESNA in cyclophosphamide-induced cystitis in rats. *ArchToxicol.*, (79):461–465.
 - **Panel C(2015).** Scientific Opinion on acrylamide in food. *EFSA.*,13(6):4104-4110.
 - **Peris-Camarasa B , Pardo O , Fernandez S , Dualde P , Coscolla C (2023).** Assessment of acrylamide exposure in Spain by human biomonitoring: Risk and predictors of exposure. *Environ Pollut*, 33(2):1-13.

- **Powers SJ, Mottram DS, Curtis A, Halford NG (2017).** Acrylamide levels in potato crisps in Europe from 2002 to 2016. *Food Addit Contam Part A Chem Anal Control Expo Risk Assess*; 34:2085–20100
- **Pundir CS, Yadav N, Chhillar AK (2019).** Occurrence, synthesis, toxicity and detection methods for acrylamide determination in processed foods with special reference to biosensors: a review. *Trends Food Sci Technol.*, 85:211–225
- **Rajeh N, Al-Dhaheer N(2017).** Antioxidant effect of vitamin E and 5-aminosalicylic acid on acrylamide induced kidney injury in rats: *Saudi Med J.*, 38(2): 132–137.
- **Rao Q, Chen Y, Yeh CR, Ding J, Li L, Chang C , Yeh S (2016).** Recruited mast cells in the tumor microenvironment enhance bladder cancer metastasis via modulation of ER /CCL2/CCR2 EMT/MMP9 signals. *Oncotarget*; 7: 7842–7855.
- **Romaniuk A, Sikora V, Lyndin M, Smiyanov V, Sikora V, Lyndina Y, et al. (2017).** The features of morphological changes in the urinary bladder under combined effect of heavy metal salts, *Interv Med Appl Sci.*, 9(2): 105–111.
- **Sant GR, Kempuraj D, Marchand JE , Theoharides TC (2007).** The mast cell in interstitial cystitis: role in pathophysiology and pathogenesis. *Urology*; 69 (4):34 –40.
- **Syaad KM, Al-Doaiss AA, Ahmed AE, El-Mekkawy H, Abdelrahman M, El-Mansi AA, et al. (2023).** The abrogative effect of propolis on acrylamide induced toxicity in male albino rats: Histological study. *Open Chemistry*; (21): 1-10.
- **Thangamany M, Janakiraman A, Philip C (2023).** Antioxidants role against acrylamide toxicity on urogenital system; *MJMHS*; 19(1):340-347.
- **Totten SP, Im YK, Cepeda Cañedo E, Najyb O, Nguyen A, Hébert S, Ahn, R, et al.(2021).** STAT1 Potentiates Oxidative Stress Revealing a Targetable Vulnerability that Increases Phenformin Efficacy in Breast Cancer. *Nat Commun*; 12: 3299-32100
- **Yang WT, Yaggie R, Schaeffer A, Klumpp D (2018).** A MAPP Network study: overexpression of tumor necrosis factor- in mouse urothelium mimics interstitial cystitis. *Am J Physiol Renal Physiol*, 315:36– 44.
- **Yener Y, Yerlikaya FH, Toker A.(2016).** Evaluation of Some Renal Function Parameters in Rats Treated with Acrylamide. *AJAVS*, 2(1): 1-8.
- **Zhao M, Lewis Wang FS, Hu X, Chen F , Chan HM (2017).** Acrylamide-induced neurotoxicity in primary astrocytes and microglia: roles of the Nrf2-ARE and NF-kappaB pathways. *Food Chem Toxicol.*; 106:25–35