

RELIABILITY OF DIFFERENT CBCT SOFTWARE PROGRAMS IN ASSESSMENT OF THE UPPER AIRWAY SPACES

Nora Al Abbady* and Nouran Seifeldin**

ABSTRACT

Objective: The upper pharyngeal airway spaces (PAS) is gaining popularity due its close correlation to various malocclusions and different orthodontic treatments. The aim of this study was to compare two software programs; In Vivo 5 Anatomage and Planmeca Romexis viewer in measuring the PAS volume and in localizing and calculating its minimum constriction area (MCA).

Materials and Methods: InVivo 5 Anatomage software (version 5.3.1) and Planmeca Romexis viewer (version 6.4.2) were used to view and measure the PAS on 15 CBCT scans. The upper limit of the PAS was established by drawing a line extending from the posterior nasal spine to the pharyngeal wall. The lower limit was determined by a line parallel to the upper limit line. The volume and MCA of the PAS were automatically calculated by each software. Measurements were repeated after 10 days.

Results: There was no statistically significant difference between both software programs regarding the volume and MCA measurements with mean difference of 0.13 cm³ and 11.31 cm² respectively ($P \leq 0.05$). It was noticed that InVivo 5 yielded insignificantly higher mean values of the PAS volume and MCA. There was perfect inter and intra-observer agreement with ICC > 0.9.

Conclusions: Both software programs; InVivo 5 Anatomage and Planmeca Romexis can be utilized for visualization and measurement of the upper airway spaces for orthodontic diagnostic purposes interchangeably.

KEYWORDS: pharyngeal spaces, upper airway volume, CBCT software, segmentation

* Lecturer, Department of Oral and Maxillofacial Radiology, Faculty of Dentistry, Cairo University.

** Lecturer, Department of Orthodontics, Faculty of Dentistry, Cairo University.

INTRODUCTION

The impact of orthodontic treatment on the surrounding soft tissues and pharyngeal airway spaces (PAS) shouldn't be overlooked. The upper airway (UA) extends from the tip of the nose to the epiglottis, where the PAS can be divided into three sections; the nasopharyngeal, oropharyngeal, and laryngopharyngeal airways^{1,2}. Due its close correlation to growth of the craniofacial structures^{3,4}, PAS, as well as the minimum cross sectional area (MCA: the anatomic location perpendicular to the direction of airflow as visualized in the axial plane, and which the degree of its constriction shows the resistance to airflow⁵), has been studied across various malocclusions and facial patterns. It was believed that patients with longer faces have a smaller airway space compared to those with shorter faces⁶. Patients with anterior open bite were reported to have a narrower PAS and a smaller MCA⁷. Previous studies showed no difference in PAS across different anteroposterior skeletal relations⁸⁻¹⁰. However, it was also reported that the airway volumes of Class II patients were smaller when compared with Class I and Class III patients^{2,11,12}.

The effect of orthodontic treatment on the PAS has also been investigated. Trials confirming a positive correlation between different orthodontic treatment modalities and PAS¹³⁻¹⁶ are available in the literature as well as other trials negating the effect of treatment¹⁷⁻²⁰. The wide platform of information available regarding the PAS is greatly related to the imaging modality and measurement tool used. Due to the complex 3-dimensional structure of the upper airway spaces²¹, cone beam computed tomography (CBCT) is the imaging modality of choice as it allows accurate volumetric visualization and measurement of the PAS^{21,22}.

A variety of software programs are available, offering manual, semi-automatic and fully automatic CBCT segmentation of the UA^{23,24}. Manual segmentation is extremely time-consuming where tracing of airway boundaries is performed on

separate cuts, which are then converted into a precise 3D volume²⁵. On the other hand, fully automatic segmentation utilizes artificial intelligence which is expected to replace manual and semi-automatic systems despite demanding complex computer and software technology²⁶. Meanwhile, by reducing the segmentation time to up to 78.1%²⁷, the semi-automatic segmentation remains an efficient approach for UA analysis as it combines benefits of both human and automatic segmentation.²³

Differences in accuracy and reliability among different software programs in measuring the UA volume have been reported²⁸⁻³⁰. The aim of the current study was to compare InVivo 5 Anatomage and Planmeca Romexis viewer in measuring the UA volume and in localizing and calculating its minimum area.

MATERIALS AND METHODS

In this reliability study, a total of 15 craniofacial CBCT scans (10 females and 5 males) were selected from the archive of the Department of Oral and Maxillofacial Radiology, Faculty of Dentistry, Cairo University. The study was approved by the Research Ethics Committee of the Faculty (reference number 35-5-23). All the scans were with an age range of 18- 25 years old. The patients included in the study had no previous tonsillar, nasal, adenoid, head or neck surgery, and no craniofacial deformity. Scans with low quality images and narrow field of view which didn't display the complete area of UA were excluded.

Planmeca Promax 3D mid CBCT machine (Planmeca, Helsinki, Finland) with 20x20 cm field of view and 0.4 mm voxel size, was used to scan all the patients. The kilovoltage and milliamperere were set at 90 kVp and 8 mA respectively for 13.891 seconds. The images were taken in natural head position, with teeth in maximum intercuspation. InVivo 5 Anatomage software (version 5.3.1) and Planmeca Romexis viewer (version 6.4.2) were

used to analyze the UA on all CBCT scans in terms of volume and MCA. For standardization, the UA region of interest was defined on a mid-sagittal cut as an upper limit and a lower limit on each scan. The upper limit was established by drawing a line extending from the posterior nasal spine (PNS) to the pharyngeal wall. The lower limit was determined by a line parallel to the upper limit line (PNS line), extending from the most anteroinferior point of the 3rd cervical vertebra (CV3)²⁸. The volume and MCA of the PAS was automatically calculated using different tools of each software.

For InVivo 5 Anatomage software (Group 1), the airway analysis tool was enabled and a mid-sagittal cut with clear 2nd (CV2) and 3rd (CV3) vertebrae and PNS was then selected to draw a line in the from

the PNS to C3. The software then automatically generated the volume and MCA of the UA (fig. 1).

In Planmeca Romexis viewer software (Group 2), adjustment was first done to a mid-cut in all planes in the 3D imaging explorer. Airway extraction tool was then selected and points along the airway curvature were marked from the upper limit till the lower limit in a sagittal cut. The software then automatically calculated the volume and MCA of the UA (fig. 2).

An experienced radiologist (N.A) and an orthodontist (N.S) of more than 15 years' experience conducted the measurements on both software programs. For intra-observer reliability, the measurements were repeated with 10 days interval between each measurement.

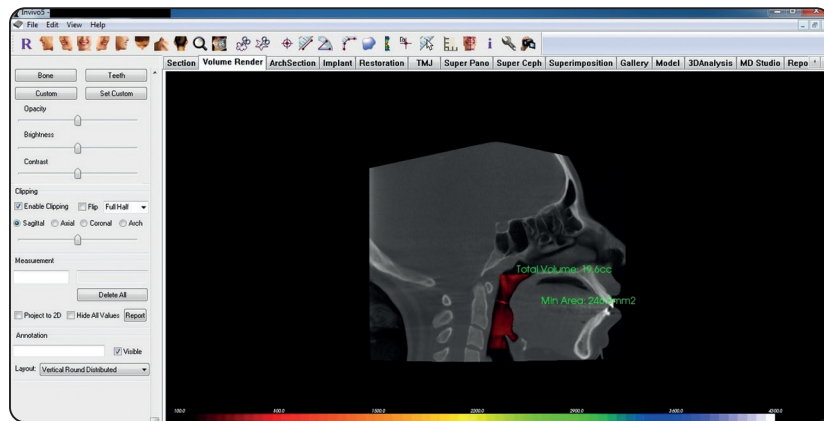


Fig. (1) Airway analysis using InVivo 5 Anatomage with minimum constriction area localization (thick red band).

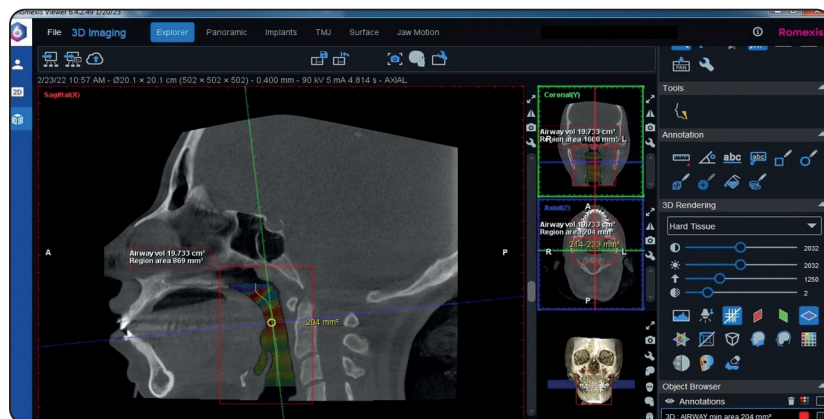


Fig. (2) Airway analysis using Planmeca Romexis viewer software with with minimum constriction area localization (yellow circle).

STATISTICAL ANALYSIS

Statistical analysis was performed with SPSS® Statistics (version 20, IBM, Armonk, NY, USA). Data was explored for normality using Kolmogorov– Smirnov and Shapiro–Wilk tests. Since the data was parametric, comparison between the two software programs outcomes was performed using Independent- t test. Inter and interobserver reliability were calculated using Inter Class Correlation Coefficient (ICC)

Sample size calculation²⁹ revealed that 11 scans were needed to compare the reliability of both programs. Using a mean value of 10.79 cm³ (± 4.26) for the PAS volume²⁹, a power of 80% and a type I error of 0.5 calculation was performed with the PS calculator (version 3.1.9.7, Creative Commons Attribution-NonCommercial-NoDerivs 3.0, USA). The calculation indicated the need for a minimum of 11 CBCT scans; and eventually, 15 scans were included in this study.

RESULTS

Comparison between both software revealed insignificant differences regarding MCA (mm²) and volume (cm³) measurements. The mean values of the upper airway MCA were 208.71 mm² and 197.40 mm² for the InVivo 5 and Romexis software

respectively, with a mean difference of 11.31 cm³. For the UA volume, the mean values were 16.58 cm³ and 16.45 cm³ for the InVivo 5 and Romexis software respectively with a mean difference of 0.13 mm² (Table 1) (fig. 3).

Inter-observer reliability coefficient was used to evaluate the agreement between the 2 assessors and revealed that there was perfect agreement (ICC > 0.9) among both groups (Table 2). Intra-observer reliability coefficient was used to evaluate the agreement between the readings of the same assessor and revealed that there was perfect agreement (ICC > 0.9) (Table 3).

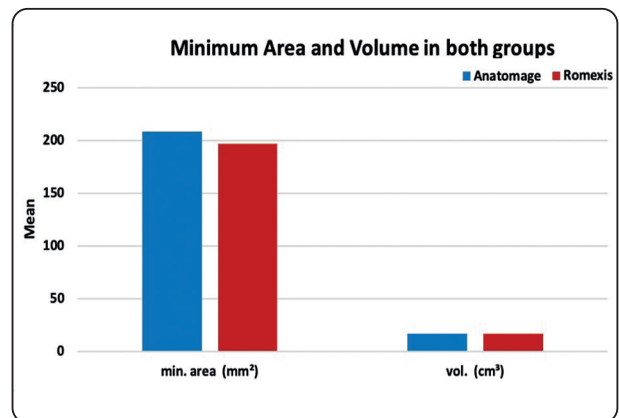


Fig. (3) Bar chart showing the mean value of the minimum constriction area and volume in Romexis and Antomage groups.

TABLE (1) Minimum, maximum, mean and standard deviation of min. area and volume in both groups and comparison between them using Independent t test:

		Min	Max	M	SD	Difference (Independent t test)				
						MD	SED	95%CI		P value
								L	U	
MCA (mm ²)	Group 1 (InVivo 5)	35.00	413.60	208.71	119.69	11.31	43.09	-76.96	99.57	0.795
	Group 2 (Romexis)	29.00	373.00	197.40	116.30					
Volume (cm ³)	Group 1 (InVivo 5)	2.70	31.80	16.58	8.80	0.13	3.10	-6.23	6.49	0.966
	Group 2 (Romexis)	4.00	31.10	16.45	8.19					

MCA: Minimum constriction area Min: minimum Max: maximum M: mean SD: standard deviation MD: mean difference SED: standard error difference CI: confidence interval L: Lower arm U: upper arm

TABLE (2) Mean and standard deviation of MCA and volume regarding 1st and 2nd observer and inter-observer reliability in both groups:

Interobserver reliability		1 st observer		2 nd observer		ICC	95% CI		P value
		M	SD	M	SD		L	U	
Group 1 (InVivo 5)	volume (cm ³)	16.58	8.80	16.63	8.68	0.999	.997	1.000	0.0001*
	MCA (mm ²)	208.71	119.69	208.75	117.90	0.999	.997	1.000	0.0001*
Group 2 (Romexis)	volume (cm ³)	16.45	8.19	16.45	8.24	0.999	.997	1.000	0.0001*
	MCA (mm ²)	197.40	116.30	192.27	112.79	0.997	.992	.999	0.0001*

*MCA: Minimum constriction area M: mean SD: standard deviation ICC: Interclass correlation coefficient
CI: confidence interval Lower arm U: Upper arm *Significant difference as P<0.05*

TABLE (3) Mean and standard deviation of MCA and volume regarding intra-observer reliability in both groups:

Intraobserver reliability		1 st read		2 nd read		ICC	95% CI		P value
		M	SD	M	SD		L	U	
Group 1 (InVivo 5)	volume (cm ³)	16.58	8.80	16.89	8.37	0.996	0.988	0.999	0.0001*
	MCA (mm ²)	208.71	119.69	212.93	121.88	0.997	0.992	0.999	0.0001*
Group 2 (Romexis)	volume (cm ³)	16.45	8.19	16.82	8.28	0.998	0.993	0.999	0.0001*
	MCA (mm ²)	197.40	116.30	196.73	113.95	0.993	0.978	0.998	0.0001*

*MCA: Minimum constriction area M: mean SD: standard deviation ICC: Interclass correlation coefficient
CI: confidence interval Lower arm U: Upper arm *Significant difference as P<0.05.*

DISCUSSION

The use of CBCT imaging for the assessment of the airway spaces before and after treatment adds up to the diagnostic information required in orthodontics as well as other dental fields. The ability of CBCT to differentiate between air spaces and both bone and soft tissues using different software segmentation tools allow for accurate volumetric visualization and measurement of the PAS^{22,31}. Following the rapid technological boom witnessed in all medical and dental fields, AI offers fully automatic segmentation of the PAS. With all the advantages that automatic segmentation can offer (less time compared with manual and semi-automatic segmentation, less subjectivity and variations among clinicians), initiating the contours or locating the seed point still

require manual intervention³². In addition, studies on automatic segmentation technique of pharyngeal and sinonasal airway regions are still limited and need further investigation³². On the other hand, semi-automatic segmentation of the PAS has been used in the last decade and has proven its efficiency. However, literature lacks sufficient comparisons between various software programs used for this purpose²⁸. In the current study, two available and user-friendly software programs used to visualize and measure the airway volume were tested and no significant differences were found. Torres et al.²⁹ investigated the reliability of InVivo 5 (version 5.4) and Dolphin 3D (version 11.7) software programs in airway space analysis. Both programs yielded valid and reliable measurements. However, unlike

the current results it was observed that InVivo 5 software tended to underestimate the measurements compared to Dolphin 3D.

In another trial³³, Romexis exhibited higher means of volume and MCA measurements when compared to InVivo 5 with no reported significant differences. This was attributed to the different segmentation methods used by both programs where in Romexis (version 3.8.2.R), the segmentation was based on region growing cube, while in InVivo 5, segmentation was based on point-based analysis that gives less deviations and a better control of airway volume. In the current study, a more recent version of Romexis was tested (version 6.4.2), and on the contrary and despite the insignificant differences between the two software programs, the present study indicates that InVivo 5 had slightly higher mean values of volume and MCA. This may be due to the same segmentation method (point-based analysis method) adopted by both InVivo 5 and Romexis (version 6.4.2) programs.

Chen et al³⁴ compared the reliability and accuracy of 3 software packages; Amira[®] (Visage Imaging Inc., Carlsbad, CA), 3Diagnosis[®] (3diemme, Cantu, Italy) and OnDemand3D[®] (CyberMed, Seoul, Republic of Korea) in the analysis of the UA space. Using each software, the volume, minimum cross-sectional area, and length of the UA were measured. Resembling the current results, the measurements of the 3 programs showed excellent agreement and reliability. The length measurements of the UA were the most accurate results in all software packages. When compared to a printed 3-dimensional anthropomorphic phantom model set as a gold standard, all software packages underestimated the UA volumetric and MCA dimensions by an average of -10.8% and -10.3% respectively. This agrees with El and Palomo³⁵ who reported that OnDemand3D software sometimes failed to depict certain parts of the upper airway, leading to an underestimation of the airway volume.

Excellent agreement was found²⁶ between Invesalius, ITK-Snap, Dolphin 3D and 3D Slicer software programs in analysis of the UA space. However, significant differences were found on comparing each software to the gold standard (manually segmented by mimic software) with a p-value of less than 0.001. Hence, different patterns of inaccuracy errors (underestimation/overestimation) of the UA dimensions should be expected. On comparing the accuracy and reliability of six programs, Weissheimer A et al³⁶ used CBCT images of 33 growing patients and an oropharynx acrylic phantom scanned with an i-CAT scanner (used as a gold standard). The authors reported that all the 6 imaging software programs were reliable but had errors in the volume segmentations of the oropharynx. The study further concluded that Ondemand 3D and InVivo 5 programs had more than 5% errors compared with the gold standard. Mimics, Dolphin3D, ITK-Snap, and OsiriX were similar and more accurate than InVivo 5 and Ondemand3D for UA assessment.

In the current study, the volume and MCA readings of both programs were comparable. Despite the InVivo 5 showed slightly higher mean values than the Romexis, no statistically significant differences were detected between the two programs neither in the UA volume nor the MCA. Hence, both software programs are reliable and can be utilized interchangeably in assessing the PAS. Yet, it is recommended to employ the same software if pre and post orthodontic treatment changes or long term follow ups are to be assessed. Further studies are also necessary to compare both software programs with other available versions and software systems used in this field. It is worth mentioning that no accuracy tests were performed and this could be counted as a limitation to the current study. The fact that both programs perform measurements with virtually no difference between them does not necessarily mean that they are actually accurate, as no gold standard method was used.

CONCLUSIONS

Both software programs; InVivo 5 Anatomage software (version 5.3.1) and Planmeca Romexis viewer (version 6.4.2) can be used for visualization and measurement of the upper airway spaces. It is recommended that pre and post treatment changes and follow ups are performed using the same software program.

ACKNOWLEDGEMENTS

Not applicable.

REFERENCES

- Hiatt JL, Gartner LP. Textbook of head and neck anatomy. New York, NY: Appleton-Century-Crofts, 1982:48-56.
- Tseng YC, Tsai FC, Chou ST, Hsu CY, Cheng JH, Chen CM. Evaluation of pharyngeal airway volume for different dentofacial skeletal patterns using cone-beam computed tomography. *J Dent Sci.* 2021 Jan;16(1):51-7.
- Moss ML, Letty Salentijn L. The primary role of functional matrices in facial growth. *Am Jour Orthod.* 1969, 55 (6): 566- 77.
- Bromage TG. The oronasopharyngeal space and renewed formalization of the functional matrix hypothesis. *The Journal of Craniomandibular & Sleep Practice.* Volume 39, 2021 - Issue 4.
- Abramson ZR, Susarla S, Tagoni JR, Kaban L. Three-dimensional computed tomographic analysis of airway anatomy. *J Oral Maxillofac Surg.* 2010 Feb;68(2):363-71.
- Opdebeeck H, Bell WH, Eisenfeld J, Mishelevich D. Comparative study between the SFS and LFS rotation as a possible morphogenic mechanism. *Am J Orthod.* 1978 Nov;74(5):509-21.
- Kim SS, Kim YI, Park SB, Kim SH. Three-dimensional evaluation of the pharyngeal airway space in patients with anterior open bite. *Korean J Orthod.* 2023 Jan 31.
- Brasil DM, Kurita LM, Groppo FC, Haiter-Neto F. Relationship of craniofacial morphology in 3-dimensional analysis of the pharynx. *Am J Orthod Dentofacial Orthop.* 2016;149(5):683-691.e1.
- Alves PV, Zhao L, O’Gara M, Patel PK, Bolognese AM. Three-dimensional cephalometric study of upper airway space in skeletal class II and III healthy patients. *J Craniofac Surg* 2008; 19:1497-507.
- Habumugisha J, Ma SY, Mohamed A.S, Cheng B, Zhao MY-Y, Bu W-Q et al. Three-dimensional evaluation of pharyngeal airway and maxillary arch in mouth and nasal breathing children with skeletal Class I and II. *BMC Oral Health.* 2022; 22, 320.
- El H, Palomo JM. Airway volume for different dentofacial skeletal patterns. *Am J Orthod Dentofacial Orthop.* 2011 Jun;139(6): e511-21.
- Alves M Jr, Franzotti ES, Baratieri C, Nunes LK, Nojima LI, Ruellas AC. Evaluation of pharyngeal airway space amongst different skeletal patterns. *Int J Oral Maxillofac Surg.* 2012 Jul;41(7):814-9.
- Chen Y, Hong L, Wang CL, et al. Effect of large incisor retraction on upper airway morphology in adult bimaxillary protrusion patients. *Angle Orthod.* 2012; 82:964–70.
- Germec-Cakan D, Taner T, Akan S. Uvulo-glossopharyngeal dimensions in non-extraction, extraction with minimum anchorage, and extraction with maximum anchorage. *Eur J Orthod.* 2011; 33:515–20.
- Guilleminault C, Abad VC, Chiu HY, Peters B, Quo S. Missing teeth and pediatric obstructive sleep apnea. *Sleep Breath.* 2016; 20:561–68.
- Yuen H, Rossouw PE, Wolford LM, Wang H. Pharyngeal Airway Space Changes After Condylar Replacement and Mandibular Advancement Surgery. *J Oral Maxillofac Surg.* 2018 Jun;76(6):1165-74.
- Orabi N, Flores-Mir C, Elshebiny T, Elkordy S, Palomo JM. Pharyngeal airway dimensional changes after orthodontic treatment with premolar extractions: A systematic review with meta-analysis. *Am J Orthod Dentofacial Orthop.* 2021 Oct;160(4):503-15.
- Park JH, Kim S, Lee YJ, Bayome M, Kook YA, Hong M, Kim Y. Three-dimensional evaluation of maxillary dentoalveolar changes and airway space after distalization in adults. *Angle Orthod.* 2018 Mar;88(2):187-94.
- Ozbilen EO, Papaefthymiou P, Yilmaz HN, Küçükkeleş N. Does surgically assisted maxillary protraction with skeletal anchorage and Class III elastics affect the pharyngeal airway? A retrospective, long-term study. *Korean J Orthod.* 2023 Jan 25;53(1):35-44.
- El H, Palomo JM. Three-dimensional evaluation of upper airway following rapid maxillary expansion: a CBCT study. *Angle Orthod.* 2014 Mar;84(2):265-73.
- Bui NL, Ong SH, Foong KW. Automatic segmentation of the nasal cavity and paranasal sinuses from

- cone-beam CT images. *Int J Comput Assist Radiol Surg.* 2015 Aug;10(8):1269-77.
22. Martins L. S, Liedke G.S, Dias HL.Ds., Tiecher P.S, Arus NA, Ongkosuwito, E.M et al. Important queries for the airway analysis in cone-beam computed tomography scans: Threshold tool and voxel size protocol. *Imaging Science in Dentistry.* 2018; 6(2), 26–30.
 23. Zhang C, Bruggink R, Baan F, Bronkhorst E, Maal T, He H et al. A new segmentation algorithm for measuring CBCT images of nasal airway: a pilot study. *PeerJ.* 2019 Jan 28;7:e6246.
 24. El Shebiny T, Morcos S, Hakan E, Palomo JM. Comparing different software packages for measuring the oropharynx and minimum cross-sectional area. *Am J Orthod Dentofacial Orthop.* 2022; 161(2): 228- 37.
 25. Khalifa I YA, Youssry H. Tissue segmentation Techniques of brain MR images: A Review. *International Conference on Intelligent Computational Systems (ICICS'2012).* Dubai; 2012.
 26. Lo Giudice A, Ronsivalle V, Gastaldi G, Leonardi R. Assessment of the accuracy of imaging software for 3D rendering of the upper airway, usable in orthodontic and craniofacial clinical settings. *Prog Orthod.* 2022, 13;23(1):22.
 27. Alsufyani N.A, Noga M.L, Witmans M, Major PW. Upper airway imaging in sleep-disordered breathing: role of cone-beam computed tomography. *Oral Radiol.* 2017; 33, 161–69.
 28. Torres HM, Evangelista K, Torres EM, Estrela C, Leite AF, Valladares-Neto J et al. Reliability and validity of two software systems used to measure the pharyngeal airway space in three-dimensional analysis. *Int J Oral Maxillofac Surg.* 2020 May;49(5):602-13.
 29. Dos Santos Trento G, Moura LB, Spin-Neto R, Jürgens PC, Aparecida Cabrini Gabrielli M, Pereira-Filho VA. Comparison of Imaging Softwares for Upper Airway Evaluation: Preliminary Study. *Craniomaxillofac Trauma Reconstr.* 2018;11(4):273-77.
 30. Zimmerman JN, Vora SR, Pliska BT. Reliability of upper airway assessment using CBCT. *Eur J Orthod.* 2019 Jan 23;41(1):101-8.
 31. Guijarro-Martínez R, Swennen GR. Cone-beam computerized tomography imaging and analysis of the upper airway: a systematic review of the literature. *Int J Oral Maxillofac Surg.* 2011 Nov;40(11):1227-37. doi: 10.1016/j.ijom.2011.06.017.
 32. Leonardi R, Lo Giudice A, Farronato M, Ronsivalle V, Allegrini S, Musumeci G, Spampinato C. Fully automatic segmentation of sinonasal cavity and pharyngeal airway based on convolutional neural networks. *Am J Orthod Dentofacial Orthop.* 2021 Jun;159(6):824-835.e1.
 33. Kamaruddin N, Daud F, Yusof A, Aziz ME, Rajion ZA. Comparison of automatic airway analysis function of In-vivo5 and Romexis software. *PeerJ.* 2019 Jan 23;7:e6319.
 34. Chen H, van Eijnatten M, Wolff J, de Lange J, van der Stelt PF, Lobbezoo F, et al. Reliability and accuracy of three imaging software packages used for 3D analysis of the upper airway on cone beam computed tomography images. *Dentomaxillofac Radiol* 2017; 46: 20170043.
 35. El H, Palomo JM. Measuring the airway in 3 dimensions: a reliability and accuracy study. *Am J Orthod Dentofacial Orthop.* 2010 Apr;137(4 Suppl):S50.e1-9; discussion S50-2.
 36. Weissheimer A, Menezes LM, Sameshima GT, Enciso R, Pham J, Grauer D. Imaging software accuracy for 3-dimensional analysis of the upper airway. *Am J Orthod Dentofacial Orthop.* 2012 Dec;142(6):801-13.