

Research Article

Sono-mammography assisted wire guided localization of non- palpable breast lesions



Nashwa Mohamed Adel¹; Mohamed Mokhtar Ali²;
Heba Allah Mansour Mohamed Gaber¹ and Mahmoud Mounir Higazi¹

¹ Department of Diagnostic Radiology, Faculty of Medicine, Minia University, Minia, Egypt

² Department of Surgical Oncology, Minia Oncology Center

DOI: 10.21608/MJMR.2023.220270.1441

Abstract

Background: Breast cancer is the most cancer type in females. The preferred method of treatment for early breast cancer is breast conserving surgery. In order to achieve satisfactory oncological and aesthetic effects, accurate preoperative lesion localization is essential. This resulted in the development of wire-guided breast lesion localization. In this study we describe our experience in localization of non palpable breast lesions with the aid of wire by using ultrasound, Mammography for localization of architectural distortion as well as combined technique for more characterization. **Methods:** 20 patients with breast lesions that were non palpable were enrolled in this study. They were pathologically proven breast cancer. **Results:** Wire localization was successful in about 18 patients (90%) and was failed in about 2 patients (10%). **Conclusion:** Image guided wire localization is feasible, accurate and help the surgeon to perform the surgery with adequate safety margin and reduce the complication of breast surgery.

Keywords: Breast conserving surgery, Breast cancer, Wire localization

Introduction

Non palpable breast lesions seems to be a challenge to the surgeon in treatment. For excision, preoperative guidance is necessary. The difficult part of the procedure is removing the lesion with negative margins while preserving as much healthy tissue as you can.

Wire guided localization (WGL) and non-wire localization (NWL) are the two forms of localization. The most established and popular technique for removing non-palpable lesions is wire-guided localization (WGL). Although the method has developed over time, it still faces numerous challenges.⁽¹⁾ The localizing wire is typically inserted with ultrasound guidance, though occasionally stereotactic localization may be necessary.^(2,3) This is often done in the radiology department with

the wire secured to prevent movement or displacement when the patient is transferred to the operation room. Rarely, the surgery could result in a pneumothorax. The location of the wire's entry point may affect how the incision is made and how the lesion is removed. The patient's appointment requires close coordination^(4,5)

Standard WGL has been described with good results, and this procedure is simple to carry out with ultrasound or mammography guidance. The ultrasound assisted WGL method, with real-time control of the wire-needle position, allows for good visualization by positioning the probe above the lesion and clearly introducing the guide wire.^(6,7,^)

In this study, we describe our initial experience in radiology department Minya

university Hospital using sono-mammography assisted wire guided localization in non-palpable breast lesions, to facilitate breast surgery and minimize complications

Aim of the work

To explore the feasibility and optimizing our protocol in detecting non-palpable breast lesions in Radiology Department, Minya university hospital.

Patient and Methods

The hospital's medical ethics committee gave the study permission to proceed (Approval No.332:6/2022 Date: 17 June 2022) and All patients gave their informed consent. A multidisciplinary team (MDT) referred 20 patients with non-palpable breast lesions to the Diagnostic Radiology Department for assessment as part of the study.

Patients with non palpable breast lesions collected from Minya University hospital and Minya Oncology center, The study was conducted in Radiology department of Minya university hospital from the period of August 2022 to June 2023.

Some patients were confirmed locally advanced breast cancer and received neo-adjuvant chemotherapy with clip insertion pre neoadjuvant therapy.

Other patients with non palpable breast lesions either presented architectural distortion or micro calcification

Patients were distributed as shown in table (1) as follows:

The study involved 20 female patients with non palpable breast lesions. The range of the age of our study patients was (32- 67) years with median (IQR) was (47.5) years.

In our study (10% of patients were unmarried and 90% were married), (20% were nulli para and were 80% were multipara), (80% were breast feeders and 20% were non breast feeders) and (40% had a family history of breast cancer and 60% had not history of breast cancer). BMI more than 25 kg/m² noted in one patient.

Inclusion criteria:

- Patients with small non palpable, non metastasizing and not multicentric breast lesions
- Patients with breast cancer aiming at breast conservative surgery achieving radiographic response to neoadjuvant chemotherapy (NAC) that is complete or nearly complete with clip insertion pre neoadjuvant chemotherapy .

Exclusion criteria:

- Palpable breast lesions.
- Advanced breast cancer or distant metastases.
- lesions that did not respond well to NAC and did not show any size reduction.

Methods and image analysis

Each patient underwent the following steps:

1. Detailed history taking
2. Clinical evaluation
3. Core biopsy under clinical or sonographic guidance was used to diagnose breast cancer, and the biopsy's final histopathological results were examined.
4. Bilateral digital mammography
5. High-field Superficial ultrasound.
6. In some circumstances, Clips must be replaced

Wire localization

To decrease the likelihood of wire migration, sono-mammography reassessments are performed one day prior to surgery, sometimes even the same day. In patients with non-palpable masses, wire localization is used, and a detailed report is written by the radiologist with feedback on the wire's place of entry, direction, distance between it and the lesion, distance between the lesion and skin, and finally, distance between the location of entry and skin, as shown in (figure. 1)

Breast conservative surgery

All patients received breast conservative surgery, which included the excision of the tumor as well as the surrounding safety

margins. and margins of excised lesions were assessed and evaluated intra operative by frozen section and radiologically to assess wire retrieval and safety margins as (figure. 2)

Statistical analysis

The data was put into a computer and analyzed utilizing IBM SPSS software edition 20.0 (Armonk, NY: IBM Corp). To describe qualitative data, percentages as well as numbers were used. To verify that the distribution was normal, the Shapiro-Wilk test was carried out. The outcomes obtained were determined to be meaningful at a 5% level.

The following tests were used:

1 - The Chi-square tests

To compare various sets of categorical variables

2-Monte Carlo adjustment

is used whenever more than 20% of the cells have an expected count of less than 5

3-Mann Whitney test

For quantitative variables with unusual distributions

Results

- Method of wire localization was ultrasound guided in about 8 patients, mammographic guided in 5 patients and combined sono-mammographic guidance in 7 patients
- There is no statistic significant relation between site and size of the breast lesion, ACR of breast as well as BMI of patients and success of wire localization.
- Success rate of wire localization among the studied patients is about (90 %) and failure rate is about (10%)

Table (1): Based on demographic information, the analyzed cases were distributed (n = 20).

	No.	%
Gender (Female)	20	100.0
Age (year)		
<50	11	55.0
≥50	9	45.0
Min. – Max.	32.0 – 67.0	
Mean ± SD.	49.15 ± 9.71	
Median (IQR)	47.50 (42.0 – 55.0)	
Marital status		
Not married	2	10.0
Married	18	90.0
Parity		
Nullipara	4	20.0
Multipara	16	80.0
Breast feeding		
No	4	20.0
Yes	16	80.0
Family history		
Negative	12	60.0
Positive	8	40.0
BMI(Body mass index) (> 25 kg/m2)	1	5.0

IQR: Inter quartile range

SD: Standard deviationmarru

Table (2): Distribution of the examined cases based on the wire-localization technique (n = 20)

Method of wire insertion	No.	%
Ultrasound guided	8	40.0
Mammography guided	5	25.0
Combined	7	35.0

Table (3): The correlation between failure/success and several parameters

	Failure /Success				Test of Sig.	P
	Failed (n = 2)		Success (n = 18)			
	No.	%	No.	%		
Site						
UIQ	0	0.0	3	16.7	$\chi^2=$ 3.586	MC p= 0.287
LIQ	1	50.0	3	16.7		
UOQ	0	0.0	9	50.0		
LOQ	1	50.0	3	16.7		
ACR						
A	0	0.0	4	22.2	$\chi^2=$ 4.631	MC p= 0.078
B	0	0.0	11	61.1		
C	2	100.0	3	16.7		
Size						
Min. – Max.	12.0 – 28.0		0.0 – 27.0		U=16.0	0.853
Mean ± SD.	20.0 ± 11.31		17.72 ± 7.78			
Median	20.0		19.0			
BMI(>25kg/m2)	1	50.0	19	2.6		0.23

χ^2 : Chi square test MC: Monte Carlo U: Mann Whitney test

p: p value for comparison between the studied categories

*: Statistically significant at $p \leq 0.05$

Table (4): Distribution of the analyzed cases based on wire localization success/failure (n = 20)

Failure /Success	No.	%
Failed	2	10.0
Success	18	90.0

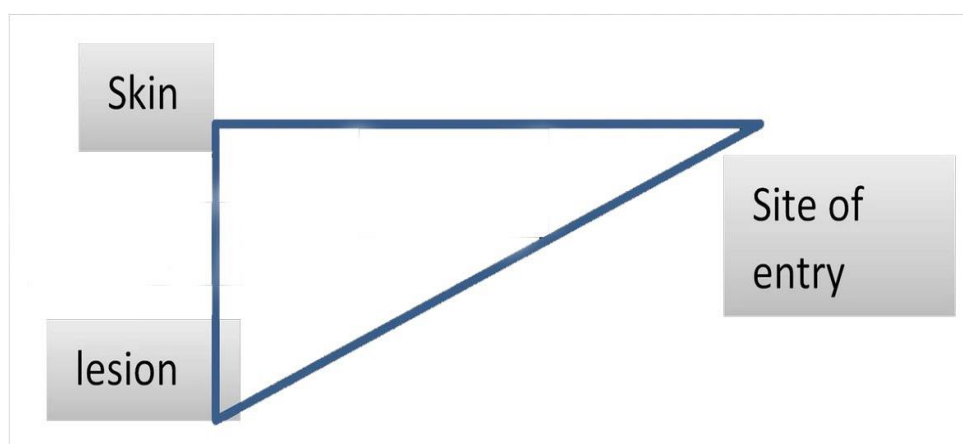


Figure (1): Graphical representation of the wire's entry point, orientation, the gap between the lesion and the skin, and, finally, distance between the place of entry and the skin

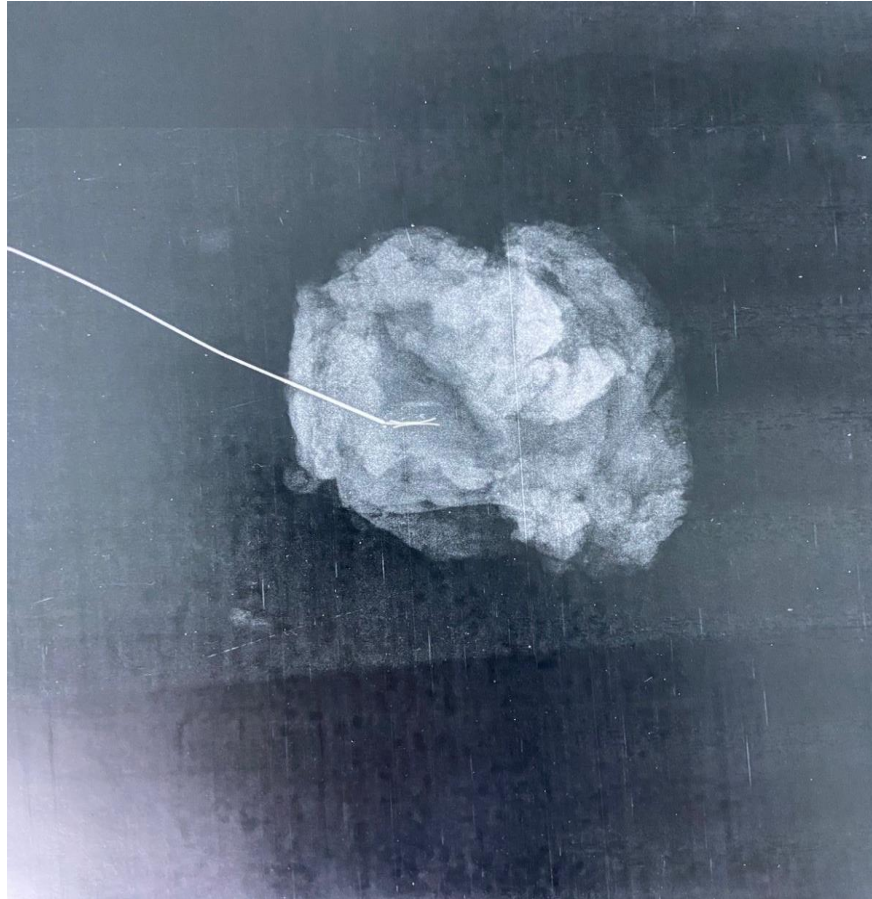


Figure 2: Intraoperative sample mammography of retrieved wire

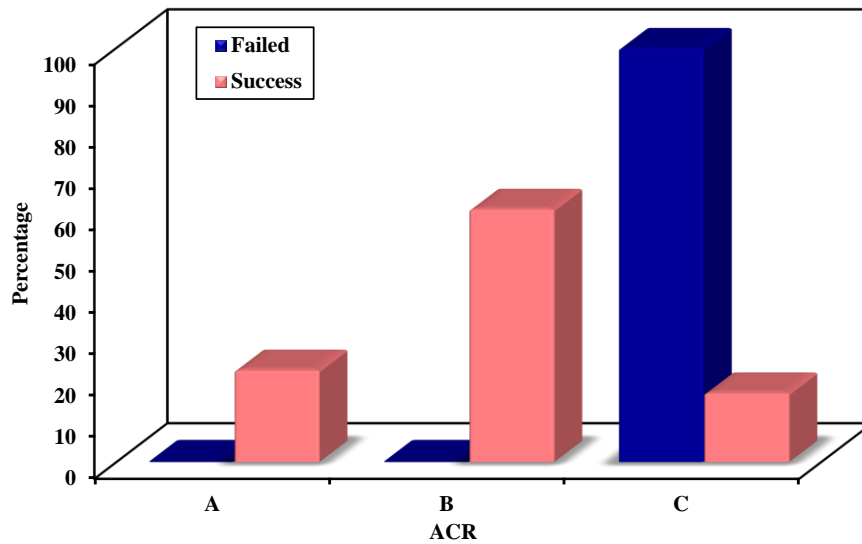


Figure (3): Relation between Failure /Success and ACR

Discussion

In women around the world, Breast cancer is the most prevalent type of cancer. The detection rate of non-palpable breast lesions has grown as a result of the widespread adoption of breast cancer

screening programmes and the use of cutting-edge mammography equipment.⁽⁹⁾

Hook wire localization is the most frequently employed technique to locate non-palpable lesions. The two most

common causes for a hook wire localization biopsy are the detection of a centre of concerning microcalcifications or the diagnosis of a non-palpable lesion. 98% of patients who got a biopsy for a nonpalpable lesion and were later diagnosed with cancer had a longer disease-free survival.⁽¹⁰⁾

The objective of this study was to assess and optimise our methods for detecting non-palpable breast lesions.

In current study, Method of wire localization: Ultrasound guided was used in about 8 patients (40%), Mammography guided was used in about 5 patients (25%) for better localization of architectural distortion and microcalcification, Combined sono-mammographic guidance was used in about 7 patients (35%) for more characterization.

According to Ernst, et al., 2002 research⁽¹¹⁾, the decision is contingent on the specific features of the lesion and the tools available. Several techniques for preoperative localization of non-palpable breast lesions have been developed. Data from image-guided core needle biopsy are promising. Historically, non-palpable breast lesions were assessed by needle localization breast biopsy (NLBB) under mammographic or ultrasonographic supervision. The use of this approach has been the 'gold' norm over the previous three decades.

Masroor, et al., 2012⁽¹²⁾ conducted WGL in 53% of the cases utilizing mammography guidance and 40% utilizing ultrasound guidance. Conversely, de Roos, et al., 2013⁽¹³⁾ reported that in their study, ultrasonography was used to aid localization in 72.6% of patients, mammography in 26.5%, and MRI in 0.9% of patients.

Our results showed the success rate of wire localization in ACR A was 100%, in ACR B was 100% and in ACR C was 80 % that is because dense breast obscure the proper visualization and localization of the lesion

so they were in need to Mammogram with contrast/ MRI guided localization

Our results showed that Body mass index (BMI) of more than 25 kg/m² is noted in one patient who experienced wire dislodgment due to difficulty in localization in pendulous breast.

Kaul, et al., 2014⁽¹⁴⁾ discovered equivalent results in human when they evaluated the movement of several wires in tissues made to simulate fatty and dense breast tissue. They argued that wire displacement in respect to clips and hooks was linked to tissue density. Larger breasts are more vulnerable to wire movement, especially when the wire is placed medially. The breast has been observed to shift laterally away from the midline, where more traction is applied to the wire due to the weight of the massive breast, implying that this is possibly related to gravity. The movement of the wire was proportional to how close the wire hook was to the flesh. Despite the fact that it may appear obvious that this issue could.

There is no correlation between the lesion site regarding quadrants of breast and accuracy of wire localization with no statistic significant relation due to limited number of patients in our study.

In Ernst et al.'s study, the distance between the localization wire and the breast lesion ranged from 0 to 80 mm.⁽¹¹⁾ The distance between the localization wire and the breast lesions, as well as the accurate inclusion of the lesion in the material, did not correspond to the degree of excisional radiculopathy.

In the study of Dimitrovska, et al., 2015⁽¹⁵⁾ The superior lateral quadrant in 53 cases (77.94%), superior medial quadrant in 4 cases (5.78%), inferior medial quadrant in 5 cases (7.35%), inferior lateral quadrant in 5 cases (7.35%), and retromammillar space in 1 cases (1.47%) were the most common quadrants where the lesion was localized. In our study, all cases underwent breast-conserving surgery, and the samples were

inspected radiologically throughout the operation using mammography and frozen section. to ensure wire presence and to assess free safety margin. Discussion and communication between the radiologist and the surgeon to choose the nearest distance between the skin and the tumor in relation to the incision site.

In accordance with our results, Wen, et al., 2020⁽¹⁶⁾ reported that with the help of a biopsy, all 15 cases of breast cancer were determined to be in the early stages, and patients could choose between breast preservation and reconstruction. Because of their concern for a cancer recurrence, no patient agreed to breast reconstruction. Overweight or obese conditions affected four out of ten individuals with in situ carcinomas and two out of five patients with invasive carcinomas.

The current study showed that Safety margins were 100/100 free.

These findings were in line with those of Ibrai, et al., 2014⁽¹⁷⁾, who determined that specimen mammography allowed for negative margins in 93.5% of cases.

Whereas, in meta-analysis conducted by Davey, et al., 2022⁽¹⁸⁾, all 24 randomized controlled trails presented results for analysis with a margin of positivity of 100 percent. 7.14 out of 4236 margins were positive, or 16.9% overall. While ultrasound-guided localization (USGL) had the lowest percentage of associated margin positive (5.4%, 17/316), cryo-assisted localization (CAL) had the highest rate (28.2%, 58/206), followed by WGL (20.1%, 411/2045). When compared to WGL, USGL (OR: 0.192, 95% CI: 0.079-0.450) and AGL (OR: 0.229, 95% CI: 0.050-0.938) exhibited significantly lower margin positive rates. In this network meta-analysis (NMA), the margin positivity rates for patients undergoing indocyanine green fluorescence-guided localization (IL) (12.5%, 4/32), magnetic-marker localization (ML), ROLL (15.1%, 110/640), radioactive seed localization (RSL) (11.7%, 99/845), CAL (28.2%, 58/206), or SMRI (11.8%, 8/68) were not significantly different.

Our results showed that Complications rate low was 5% with failure rate of localization about 20%. The complication were wire dislodgment and pain after the procedure and there were no post- procedural hematoma or pneumothorax noticed

Yilmaz, et al., 2022⁽¹⁹⁾ found that Complication rates are very low in image-guided marking procedures, and vasovagal reactions during the marking process are the most common problems encountered at a rate of around 10%. Bleeding, pneumothorax, infection, and displacement and cutting of the wire, or wires hooking on to the pectoral fascia during surgical excision are other complications that can be seen. In addition, the inability to remove the marked lesion is another important complication reported that varies between 0% and 17% in different series., complications related to the wire-localization system were observed at a rate of 6.6%.

Despite the fact that wire-guided localization is the accepted practice, Ramos, et al., 2014⁽²⁰⁾ stated that, it is a time-consuming process that necessitates the expertise of an experienced radiologist and is uncomfortable and often upsetting for the patient. likewise, it may be associated with an elevated incidence of positive margins, a rise in local recurrences, accidental wire displacement during patient transfer, surgical positioning, or post-procedure mammography, as well as a poor cosmetic outcome during intraoperative ultrasound (IOUS) excision, a desirable and suggested practice as an alternative to other excision techniques in patients with fully responsive clinical outcomes after NACT as wire localization.

According to Youn, et al., 2015⁽²¹⁾ and Masroor et al.⁽¹²⁾, there was actually no proof of wire displacement throughout postoperative follow-up, preoperative final follow-up, or in surgical specimens. Additionally, no patient reported any pain or heat during the research period, and no wire-related complications were noticed According to Athanasiou, et al., 2022⁽²²⁾, utilising USGL results in lower margin positive rates (OR: 0.19). WGL was linked

to greater margin positive rates than ROLL, according to a recent meta-analysis of RCTs by Kiruparan, et al., 2012⁽²³⁾ (OR: 1.520, 95% CI: 1.030-2.250).

According to Pasta, et al., 2015⁽²⁴⁾, the WGL approach did not result in patient issues during the preoperative stage, including a hematoma, infection, or Mondor's syndrome.

Conclusion

Finally, WGL biopsy is a reliable procedure that can offer an accurate diagnosis and surgical excision. for patients who arrive with non-palpable breast tumors.

References

- Hall, F. M., Kopans, D. B., Sadowsky, N. L., et al., Development of wire localization for occult breast lesions: Boston remembrances. *Radiology*, (2013). 268(3), 622-627.
- Kanat, N., Caglar, M., Tuncel, M., et al., Comparison of radio-guided occult lesion localization (ROLL) and wire guided localization (WGL) methods for the preoperative localization of non-palpable breast lesions (2013).
- Demiral, G., Senol, M., Bayraktar, B., et al., Diagnostic value of hook wire localization technique for non-palpable breast lesions. *Journal of Clinical Medicine Research*, (2016).8(5), 389.
- Volders, J. H., Haloua, M. H., Krekel, N. M., et al., Current status of ultrasound-guided surgery in the treatment of breast cancer. *World journal of clinical oncology*, (2016). 7(1), 44.
- Chan, B. K., Wiseberg-Firtell, J. A., Jois, R. H., et al., Localization techniques for guided surgical excision of non-palpable breast lesions. *Cochrane Database of Systematic Reviews*, (2015). (12).
- Benson, S. R. C., Harrison, N. J., Lengyel, J., et al., Combined image guidance excision of non-palpable breast lesions. *The Breast*, (2004).13(2), 110-114.
- Kolpattil, S., & Crotch-Harvey, M. Improved accuracy of wire-guided breast surgery with supplementary ultrasound. *European journal of radiology*, (2006). 60(3), 414-417.
- Ko, K., Han, B. K., Jang, et al., The value of ultrasound-guided tattooing localization of nonpalpable breast lesions. *Korean journal of radiology*, (2007).8(4), 295-301.
- Özmen, V., Özmen, T., & Doğru, V. Breast cancer in Turkey; an analysis of 20.000 patients with breast cancer. *European journal of breast health*, (2019).15(3), 141.
- Lieberman, L., Kaplan, J., Van Zee, K. J., et al., Bracketing wires for preoperative breast needle localization. *American Journal of Roentgenology*, (2001). 177(3), 565-572.
- Ernst, M. F., Avenarius, J. K. A., Schuur, K. H., et al., Wire localization of non-palpable breast lesions: out of date? *The Breast*, (2002).11(5),408-413
- Masroor, I., Afzal, S., Shafqat, G., et al., Usefulness of hook wire localization biopsy under imaging guidance for nonpalpable breast lesions detected radiologically. *International Journal of Women's Health*, (2012).445-449.
- De Roos, M. A. J., Welvaart, W. N., & Ong, K. H. Should we abandon wire-guided localization for nonpalpable breast cancer? A plea for wire-guided localization. *Scandinavian Journal of Surgery*, (2013).102(2), 106-109
- Kaul, D., Fallenberg, E., Diekmann, F., et al., Dislocability of localization devices for nonpalpable breast lesions: experimental results. *Radiology research and practice*, 2014.
- Dimitrovska, M. J., Mitreska, N., Lazareska, M., et al., Hook wire localization procedure and early detection of breast cancer-our experience. *Open Access Macedonian Journal of Medical Sciences*, (2015). 3(2), 273.
- Wen, H., Xu, T., Huang, Q., et al., Nonpalpable breast masses: One-year ultrasound follow-up and morbidity outcomes in Shanghai. *Medicine*, (2020). 99(50).
- Ihrai, T., Quaranta, D., Fouche, Y., et al., Intraoperative radiological margin assessment in breast-conserving

- surgery. *European Journal of Surgical Oncology (EJSO)*, (2014).40(4), 449-453.
17. Davey, M. G., O'Donnell, J. P., Boland, M. R., et al., Optimal localization strategies for non-palpable breast cancers—A network meta-analysis of randomized controlled trials. *The Breast*, (2022). 62, 103-113.
 18. Yilmaz, S., Ünal, G. K., Aslan, H. S., et al., Ultrasound-guided wire localization biopsy in non-palpable breast lesions: predictive factors for malignancy. *European Review for Medical & Pharmacological Sciences*, (2022). 26(4).
 19. Ramos, M., Díez, J. C., Ramos, T., et al., Intraoperative ultrasound in conservative surgery for non-palpable breast cancer after neoadjuvant chemotherapy. *International Journal of Surgery*, (2014). 12(6), 572-577.
 20. Youn, I., Choi, S. H., Kook, S. H., et al., Ultrasonography-guided surgical clip placement for tumor localization in patients undergoing neoadjuvant chemotherapy for breast cancer. *Journal of Breast Cancer*, (2015). 18(1), 44-49.
 21. Athanasiou, C., Mallidis, E., & Tuffaha, H. Comparative effectiveness of different localization techniques for non-palpable breast cancer. A systematic review and network meta-analysis. *European Journal of Surgical Oncology*, (2022). 48(1), 53-59.
 22. Kiruparan, N., Kiruparan, P., & Debnath, D. Use of wire-guided localisation and radio-guided occult lesion localisation for non-palpable breast lesions: A systematic literature review and meta-analysis of current evidence. (2021). *Asian J Surg*.
 23. Pasta, V., D'Orazi, V., Sottile, D., et al., Breast Mondor's disease: diagnosis and management of six new cases of this underestimated pathology. *Phlebology*, (2015), 30(8), 564-568.