

*“ Hybrid Revascularization by Common Femoral Artery Endarterectomy and Proximal or Distal Angioplasty in Patients with Critical Lower Limb Threatening Ischemia ”*

Authors

**Muhammad Labeq 1 Meera Refat Fekry 2**

<sup>1</sup> Vascular surgery unit, faculty of medicine, Port Said University

<sup>2</sup> Vascular surgery unit, faculty of medicine, Suez Canal University

**ABSTRACT:**

**Background:** Hybrid approach has been considered as an effective technique for reconstruction of multi-level arterial stenosis or occlusion. The simultaneous combined techniques have shown satisfactory outcomes in terms of patency, technical success and less invasiveness in high-risk patients. The purpose of this study to compare CFA endarterectomy (CFE) combined with either proximal or distal endovascular intervention or both.

**Methods:** retrospective study of prospectively collected data of patients presented with critical limb threatening ischemia (CLTI) with multi-level peripheral arterial disuses include femoral territory and proximal and/or distal arterial disease. All patients had CFE and endovascular intervention at Egypt healthcare authority hospitals.

**Results:** this study included 30 patients stratified into three groups according to the site of concurrent endovascular intervention; group 1 had proximal endovascular intervention (n=7); group 2 had distal endovascular intervention (n=12); and group 3 with combined proximal and distal intervention (n = 11), 100% technical success reported with overall primary patency at 24 months of 85%. Limb salvage at 24 months was 92.5%.

**Conclusion:** Common femoral endarterectomy is the gold standard treatment for common femoral artery lesions with excellent patency. In multi-level peripheral arterial disease, the endovascular intervention could improve the outcome and maintain patency and limb salvage.

**Key words:**

Hybrid – common femoral – endarterectomy – endovascular.

Submitted: 24/12/2023

Accepted:27/12/2023

DOI:10.21608/MUJ.2023.258185.1159

ISSN : 2682-2741

This is an open access article licensed under the terms of the Creative Commons Attribution International License (CC BY 4.0).

<https://muj.journals.ekb.egdean@med.psu.edu.eg>  
[vice\\_dean\\_postgraduate@med.psu.edu.eg](mailto:vice_dean_postgraduate@med.psu.edu.eg)

<https://creativecommons.org/licenses/by/4.0/>.



## **Introduction:**

Chronic limb threatening ischemia (CLTI), the most devastating pattern of peripheral arterial disease (PAD) represents a serious health burden due to increased mortality, risk of amputation and impaired quality of life <sup>1</sup>. Combined surgical and endovascular interventions have been adopted to treat more complex arterial diseases <sup>2</sup>.

Although isolated common femoral artery (CFA) occlusive lesions are uncommon, they represent a daunting challenge to all vascular surgeons considering the anatomical location. For many years, CFA endarterectomy was considered the preferred treatment option in this territory <sup>3</sup>. However, the technological advances and the promising outcomes of several studies made the endovascular intervention in CFA lesions to gain more popularity <sup>4,5</sup>.

The so called “hybrid approach” has been considered as an effective technique for reconstruction of multi-level arterial stenosis or occlusion. The simultaneous combined techniques have shown satisfactory outcomes in terms of patency, technical success and less invasiveness in high-risk patients <sup>6</sup>.

The purpose of this retrospective study was to compare CFA endarterectomy combined with either proximal or distal endovascular reconstruction or both.

## **Patients and methods:**

### **Study Design**

Data of patients with critical lower limb ischemia with CFA lesion associated with either iliac (proximal) or femoropopliteal or infrapopliteal (distal) lesions who underwent CFA endarterectomy with endovascular intervention to inflow or outflow lesions at the department of vascular and endovascular surgery at Egypt healthcare authority hospitals during the period between January 2021 and December 2022 were prospectively collected and retrospectively analyzed. The study was performed with the acceptance number 5387# from research ethics committee – Suez Canal university.

All included patients sign a written informed consent for procedure.

### **Patient characteristics**

Baseline characteristics of eligible patients (sex, age) and associated risk factors (diabetes mellitus, hypertension, hypercholesterolemia, cardiac disease, smoking and obesity and cerebrovascular diseases (CVD) were reported. Patients were examined preoperatively for pulsation and ankle brachial index (ABI). Radiological evaluation was done using either duplex examination or computed tomography angiography (CTA) to assess site and type of the lesion. Operative details, outcomes, complications and follow-up period were also recorded.

### **Surgical procedure**

All procedures were done under spinal and/or epidural anesthesia in a hybrid operating room equipped with a mobile (GE OEC 9800 C-Arm System). CFE was done to all patients as a unified step followed by proximal or distal endovascular step.

All patients were classified into 3 groups according to associated arterial lesions as follows: group 1 (proximal: iliac intervention); group 2 (distal: femoropopliteal and/or tibials intervention); and group 3 (combined proximal and distal intervention).

CFE step was performed using standard procedure. longitudinal arteriotomy done followed by CFE and profundaplasty, then closure of the CFA was performed using venous patch.

Endovascular step was performed in the same setting. Lumen was accessed via the patch using a 6 french sheath advanced over a wire guided by fluoroscopy either retrograde for iliac lesions or antegrade for femoropopliteal and infrapopliteal revascularization. Lesions were crossed by using supporting catheters over different types of wires including (0.035 road runner, [Cook medical]; V-18 [Boston Scientific]). Balloon dilatation was done for iliac lesions via retrograde access; while antegrade angioplasty was applied to femoropopliteal and tibial lesions. The used angioplasty balloons were Admiral Xtreme (Medtronic) and the stents were either balloon expandable (Omnalink Elite, Abbott) or self-expandable (Epic, Boston scientific). Assessment was done after balloon dilatation for the need of stent placement and stenting was indicated if there was residual stenosis or dissection. Before removing the sheath, good flow, restenosis or thrombosis was checked via completion angiography.

### **Definitions and endpoints:**

- Technical success defined as intraoperative completion angiography showing less than 30% residual stenosis in the treated arterial segment.
- Hemodynamic success defined as an elevation in ABI more than 0.10
- Major complication was defined as one who required reintervention, whereas minor complication was defined as one managed conservatively in an outpatient setting.

### **early outcome**

- Primary patency defined as patency of the treated lesions and freedom from restenosis or need for reintervention
- Primary-assisted patency defined as a patency of the treated lesions that needed at least one surgical or endovascular reintervention for stenosis not occlusion
- Perioperative morbidity and mortality were defined as any complications or mortality occurring within 30 days of the operation.

### **late outcome**

- Limb salvage (Free from major amputation)

### **Follow up**

- A weekly visit was determined for all patients in the first month postoperative, then every 3 months till 1 year.
- Evaluation of (ABI) was done before and after the intervention then every 3 months
- Assessment was made by duplex examination or CTA to determine patency

### **Statistical analysis.**

SPSS 23 (SPSS Inc., Chicago, IL, USA) was used for statistical analysis, with X<sup>2</sup> test or fisher's exact test for categorical data and t test and one way anova for continuous variables. Survival was estimated by the use of

Kaplan- Meier analysis and log rank test was used to compare between groups. Statistical significance was considered when P value <0.05.

### **Results.**

An overall thirty patients underwent hybrid techniques for CLTI during the study period and were considered for the study in which all patients underwent CFE. Furthermore, the study population stratified into three groups according to the site of concurrent endovascular intervention; group 1 with proximal intervention (n=7); group 2 with distal intervention (n=12); and group 3 with combined proximal and distal intervention (n = 11).

The mean age was  $60 \pm 8$  years; there were no statistical difference in either demographic distribution or comorbidities between study groups (Tables I).

Table I: demographic distribution & comorbidities of the groups

|                      | Group 1<br>N=7 | Group 2<br>N=12 | Group 3<br>N=11 | p    |
|----------------------|----------------|-----------------|-----------------|------|
| Age                  | 57.5±2.5       | 62±3.5          | 60.5±1.5        | 0.5  |
| Male                 | 6              | 7               | 10              | 0.15 |
| DM                   | 7              | 9               | 9               | 0.2  |
| Hypertension         | 5              | 10              | 8               | 0.8  |
| Smoking              | 4              | 8               | 7               | 0.9  |
| hypercholesterolemia | 2              | 5               | 8               | 0.1  |
| Obesity              | 3              | 4               | 7               | 0.4  |
| Cardiac              | 6              | 7               | 9               | .2   |
| CVD                  | 0              | 1               | 1               | 0.7  |

Indication for intervention included ischemic rest pain in 14 patients (3 patients in group 1; 6 in group 2 and 5 in group 3) and 16 patients were presented with tissue loss (4 in group 1 and 6 in each of group 2 and 3)

Table II show the TASC classification distribution among the study groups, and as all patients have common femoral artery lesion so TASC A and B for proximal lesions are excluded.

Table II: TASC classification distribution among the study groups

|         |        | Group 1<br>N=7 | Group 2<br>N=12 | Group 3<br>N=11 |
|---------|--------|----------------|-----------------|-----------------|
| ILIAC   | TASC C | 3              | NA              | 5               |
|         | TASC D | 4              | NA              | 6               |
| FEM POP | TASC A | NA             | 3               | 4               |
|         | TASC B | NA             | 3               | 2               |
|         | TASC C | NA             | 2               | 2               |

|        |        |    |   |   |
|--------|--------|----|---|---|
|        | TASC D | NA | 4 | 3 |
| TIBIAL | TASC A | NA | 2 | 4 |
|        | TASC B | NA | 4 | 3 |
|        | TASC C | NA | 5 | 3 |
|        | TASC D | NA | 1 | 1 |

All study population received spinal/epidural anesthesia and underwent hybrid procedure by Common femoral endarterectomy concomitant with angioplasty with or without stenting for proximal and distal lesions. Fourteen (80%) of 18 patients with iliac lesions treated with stenting while 12 (52%) of 23 patients with femoropopliteal lesions treated with stent.

The overall mean operating time was  $155 \pm 30$  minutes. On comparing between groups it was for group 1 ( $147 \pm 24$  minutes); group 2 ( $136 \pm 25$  minutes) and group 3 ( $182 \pm 14$ ) minutes which cause statistical significance ( $p=0.001$ ).

Overall technical success was 100% in all groups and no any intraoperative complications were recorded.

With an overall mean difference between pre and post-operative ABI  $0.47 \pm 0.1$ ; We achieved hemodynamic success in 100 % of patients in which postoperative ABI increase in group 1 from  $0.3 \pm 0.03$  to  $0.75 \pm 0.03$ ; group 2 from  $0.34 \pm 0.18$  to  $0.84 \pm 0.02$  and group 3 from  $.075 \pm 0.02$  ( $p < .05$  for all groups).

Perioperative complications reported only in three cases (10%) couple of them in group 2 and the last one in group 3 with no statistical significance, two were classified as minor complications (small groin hematoma and superficial wound infection) managed in conservative therapy and resolved completely; the 3rd one is a major complication which required readmission to operative room for repair of pseudoaneurysm.

This study didn't report any perioperative mortality neither due to systemic nor vascular complications.

With a mean follow up  $17.5 \pm 1.9$  months (range 15-24) we performed Kaplan Meier analysis yielded overall primary,  $85\% \pm 7\%$  at 18 months (Figure I). Group 3 patients had statistically significant lower PP rates at 2 years ( $100\%$  for group 1,  $91\% \pm 7.1\%$  for group 2, and  $65\% \pm 17\%$  for group 3;  $p = 0.04$ ) (Figure II).

Four cases lost primary patency during follow up period (1 in group 2 and 3 in group 3) and they underwent angioplasty and stenting of the restenosed lesions to restore patency which achieve primary assisted patency of 100.

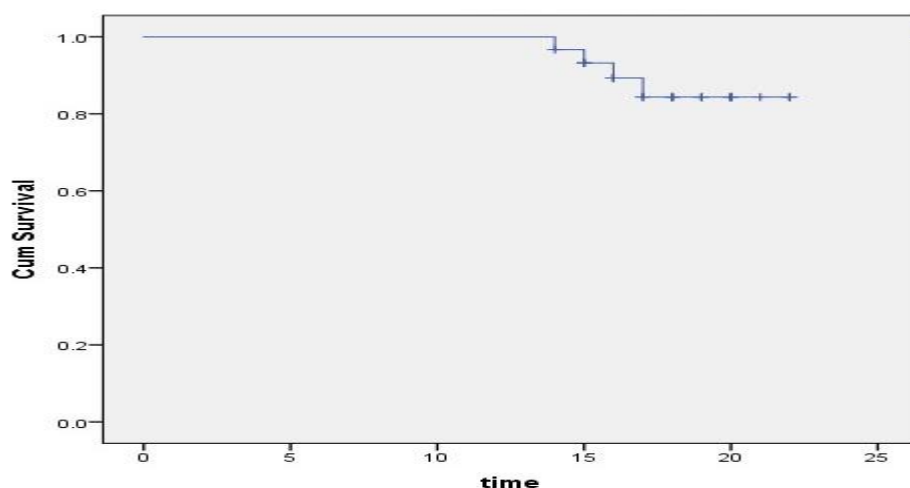


Figure I: Kaplan Meier of the overall primary patency

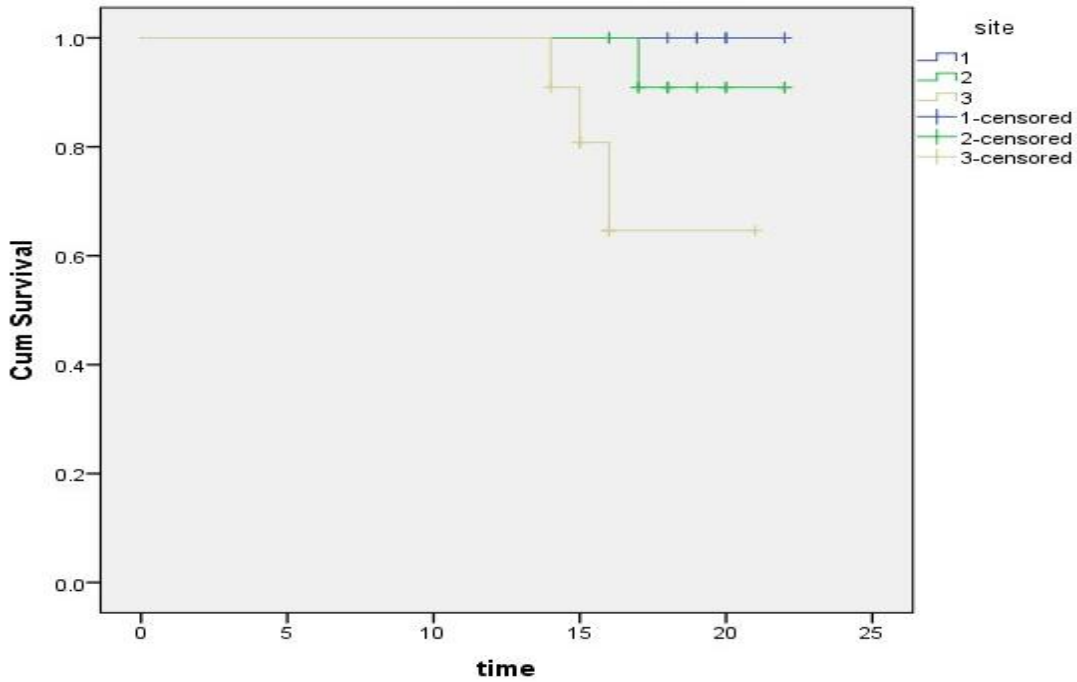


Figure II: Kaplan Meier of the primary patency between study groups

**Limb salvage:**

Couple of patient underwent major amputation one from group 2 and the other from group 3, overall limb salvage was 97% at 20 months and 92.5 at 24 months Figure III

Kaplan Meier analysis showed 100 % limb salvage of group 1 and 90 % both group 2 and 3 at 24 months, with no statistical significance  $p = 0.7$  Figure IV

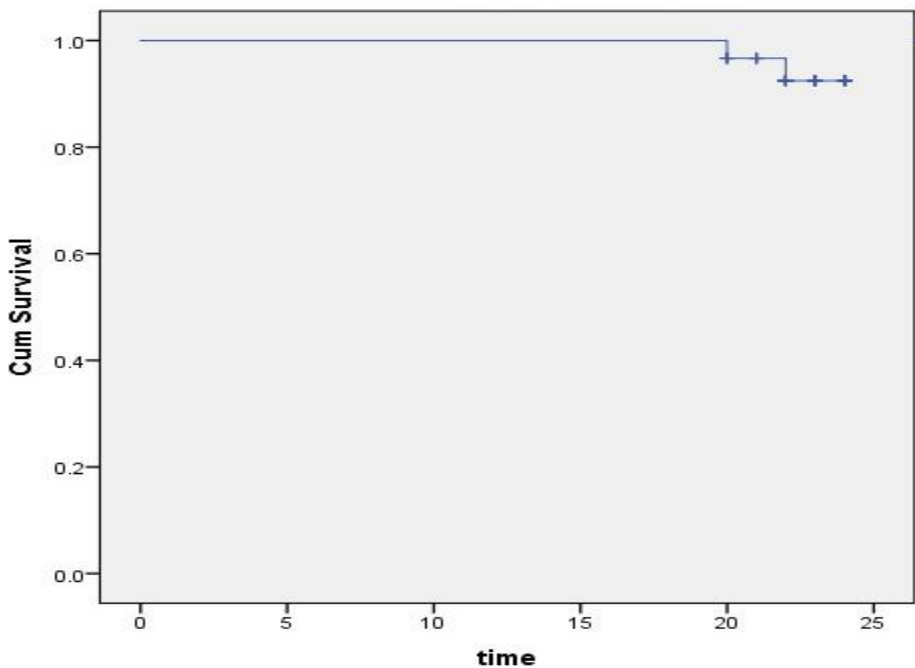


Figure III: Kaplan Meier of the overall limb salvage

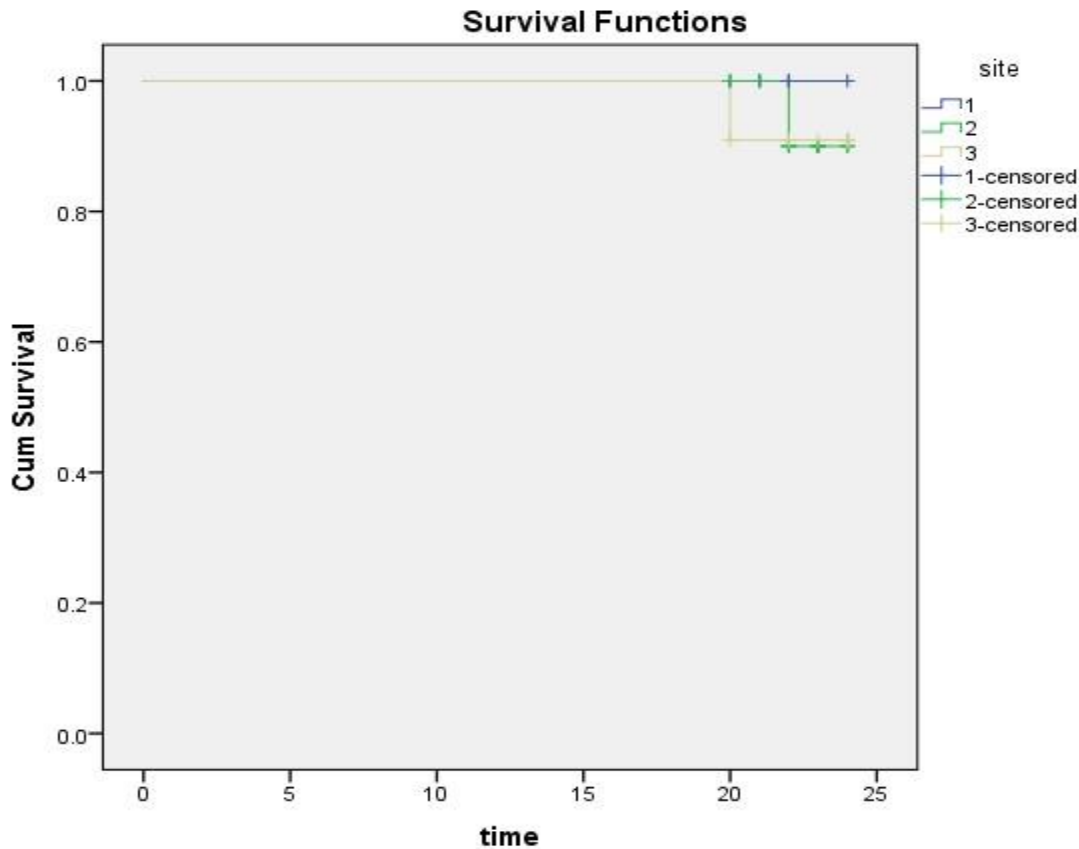


Figure IV: Kaplan Meier of the limb salvage between study groups

### Discussion

In this era of minimally invasive surgery and advances in endovascular techniques endovascular therapy become the preferred solution for a lot of surgeon. It is widely reported that endovascular therapy has a less morbidity, mortality, and short hospital stay time (7).

Although all these advantages that make endovascular therapy the procedure of choice for peripheral arterial diseases management it doesn't fit all anatomies especially in the vessels crossing joints.

The advances in the endovascular industries and the appearance of new tools push vascular surgeons for the use of endovascular therapy as a first option for patient with multilevel peripheral arterial diseases. However, because the atherosclerotic lesion in this location is often thick and highly calcified, endovascular treatments for CFA frequently fail (8) so; the most effective way to prevent the insertion of a CFA stent across a joint region with high mobility and to preserve an endovascular access for inflow and/or outflow endovascular therapy is still a common femoral endarterectomy. (9).

The data published for this issue is still conflicting, because stents might fracture and obstruct access for angioplasty, several authors are against them. Others discussed their stenting experiences with CFA lesions.

Stricker and Jacomella reported 100% technical success for their study by angioplasty of obstructions in the common femoral artery and its bifurcation with implantation of self-expanding stents and concluded that this strategy shows good midterm primary patency with no further endovascular interventions at the access site **(10)**.

In the present series of thirty patients, we reported the midterm outcome of the hybrid revascularization by common femoral artery endarterectomy and proximal or distal angioplasty procedure in patients with multilevel peripheral arterial disease.

We reported that common femoral endarterectomy combined with endovascular revascularization procedure have not associated with difference regarding technical success, and perioperative complications, but it is associated with lower primary patency in the combined proximal and distal lesions group.

We included in this study all consecutive patients with multilevel peripheral arterial disease with diseased common femoral artery and proximal lesion in 7 patients or distal lesions in 12 patients or both in 11 patients, in which all patients underwent hybrid procedure under spinal anesthesia. These data were inconsistent to study conducted by Kang et al., who reported hybrid procedure by femoral endarterectomy and endovascular revascularization for 12 proximal lesions; 17 distal lesions and 8 combined proximal and distal lesions **(9)**.

In this study The overall mean operating time was 155 minutes. On comparing between groups it was for group 1 (147 minutes); group 2 (136 minutes) and group 3 (182) minutes which cause statistical significance ( $p=0.001$ ). these findings could clarify that the combined proximal and distal lesions required longer operative time due to length of lesion and being multilevel.

The published data for hybrid procedure reported a range from 180 – 320 min procedure time **(9,11)**.

In the current series we reported technical and hemodynamic success of 100% among the whole study groups. On the other hand, Serna Santos et al. reported lower technical success 88% and this could be explained by the nature of the treated lesions in their series which were more longer and occluded rather than stenotic lesions **(6)**.

In accordance of our reported results Matsagkas et al., reported technical and hemodynamic success rates of 96.6 and 100%, respectively in a series of 37 patients using the same hybrid technique in our cohort **(12)**.

Endovascular revascularization has the advantage of less perioperative morbidity and mortality; supporting this fact our cohort results didn't identify any mortality but perioperative complications recorded in three cases (10%) of the series.

The differences in reported perioperative complication rates varying from 2% to 22% **(13,14)**.

This difference could be explained by the strong relations between patient's comorbidities and burden of disease.

During the follow-up period we reported overall primary patency of 85% at 18 months. Patients in group 3 had significantly lower PP rates at 24 months (100 % for group 1, 91% for group 2, and 65% for group 3; this difference



show statistically significance  $p = 0.04$ ; we attribute this difference due to complexity of the combined proximal and distal lesion of the arterial tree.

Nishibe et al., in their study assess the intervention for patients with TASC D lesions showed the 1ry PP rate at 24 months of 70% **(15)**. in contrast to their reported results Starodubtsev et al., in their trial, the overall PP rates at 12 and 36 months were 93% and 91% in hybrid repair group **(16)**.

The limitations of this study are small sample size, being retrospective in nature which has the character of bias and absence of control group.

### **Conclusion:**

Common femoral endarterectomy is the gold standard treatment for common femoral artery lesions with excellent patency. In multi-level peripheral arterial disease, the endovascular intervention could improve the outcome and maintain patency and limb salvage.

## References

1. Davies M. G. (2012). Critical limb ischemia: epidemiology. *Methodist DeBakey cardiovascular journal*, 8(4), 10–14. <https://doi.org/10.14797/mdcj-8-4-10>
2. Nishibe, T., Maruno, K., Iwahori, A., Fujiyoshi, T., Suzuki, S., Takahashi, S., Ogino, H., & Nishibe, M. (2015). The Role of Common Femoral Artery Endarterectomy in the Endovascular Era. *Annals of vascular surgery*, 29(8), 1501–1507. <https://doi.org/10.1016/j.avsg.2015.05.005>
3. Kuma, S., Tanaka, K., Ohmine, T., Morisaki, K., Kodama, A., Guntani, A., Ishida, M., Okazaki, J., & Mii, S. (2016). Clinical Outcome of Surgical Endarterectomy for Common Femoral Artery Occlusive Disease. *Circulation journal : official journal of the Japanese Circulation Society*, 80(4), 964–969. <https://doi.org/10.1253/circj.CJ-15-1177>
4. Thiney, P. O., Millon, A., Boudjelit, T., Della Schiava, N., Feugier, P., & Lermusiaux, P. (2015). Angioplasty of the common femoral artery and its bifurcation. *Annals of vascular surgery*, 29(5), 960–967. <https://doi.org/10.1016/j.avsg.2015.02.001>
5. Linni, K., Ugurluoglu, A., Hitzl, W., Aspalter, M., & Hölzenbein, T. (2014). Bioabsorbable stent implantation vs. common femoral artery endarterectomy: early results of a randomized trial. *Journal of endovascular therapy : an official journal of the International Society of Endovascular Specialists*, 21(4), 493–502. <https://doi.org/10.1583/14-4699R.1>
6. Serna Santos, J., Laukontaus, S., Laine, M., Valledor Pellicer, P., Sonetto, A., Venermo, M., & Aho, P. (2023). Hybrid Revascularization for Extensive Iliofemoral Occlusive Disease. *Annals of vascular surgery*, 88, 90–99. <https://doi.org/10.1016/j.avsg.2022.07.028>
7. Zhao, G. F., Pan, T., Yan, R., Deng, G., Wang, Z., Qin, Y. L., Ji, J. J., Bai, Z. B., Li, R., & Teng, G. J. (2023). Endovascular Denervation for the Improvement of Limb Ischemia in Patients with Peripheral Artery Disease: A Randomized Clinical Trial. *Annals of vascular surgery*, S0890-5096(23)00840-3. Advance online publication. <https://doi.org/10.1016/j.avsg.2023.10.011>
8. Johnston, K. W., Rae, M., Hogg-Johnston, S. A., Colapinto, R. F., Walker, P. M., Baird, R. J., Sniderman, K. W., & Kalman, P. (1987). 5-year results of a prospective study of percutaneous transluminal angioplasty. *Annals of surgery*, 206(4), 403–413. <https://doi.org/10.1097/00000658-198710000-00002>
9. Kang, J. L., Patel, V. I., Conrad, M. F., Lamuraglia, G. M., Chung, T. K., & Cambria, R. P. (2008). Common femoral artery occlusive disease: contemporary results following surgical endarterectomy. *Journal of vascular surgery*, 48(4), 872–877. <https://doi.org/10.1016/j.jvs.2008.05.025>
10. Stricker, H., & Jacomella, V. (2004). Stent-assisted angioplasty at the level of the common femoral artery bifurcation: midterm outcomes. *Journal of endovascular therapy : an official journal of the International Society of Endovascular Specialists*, 11(3), 281–286. <https://doi.org/10.1583/03-1169.1>
11. Ray, J. J., Eidelson, S. A., Karcutskie, C. A., Meizoso, J. P., DeAmorim, H., Goldstein, L. J., Karwowski, J., & Bornak, A. (2018). Hybrid Revascularization Combining Iliofemoral Endarterectomy and Iliac Stent Grafting for TransAtlantic Inter-Society Consensus C and D Aortoiliac Occlusive Disease. *Annals of vascular surgery*, 50, 73–79. <https://doi.org/10.1016/j.avsg.2017.11.061>
12. Matsagkas, M., Kouvelos, G., Arnaoutoglou, E., Papa, N., Labropoulos, N., & Tassiopoulos, A. (2011). Hybrid procedures for patients with critical limb ischemia and severe common femoral artery atherosclerosis. *Annals of vascular surgery*, 25(8), 1063–1069. <https://doi.org/10.1016/j.avsg.2011.07.010>

13. Chang, R. W., Goodney, P. P., Baek, J. H., Nolan, B. W., Rzucidlo, E. M., & Powell, R. J. (2008). Long-term results of combined common femoral endarterectomy and iliac stenting/stent grafting for occlusive disease. *Journal of vascular surgery*, 48(2), 362–367. <https://doi.org/10.1016/j.jvs.2008.03.042>
14. Piazza M, Ricotta JJ 2nd, Bower TC, Kalra M, Duncan AA, Cha S, Gloviczki P. Iliac artery stenting combined with open femoral endarterectomy is as effective as open surgical reconstruction for severe iliac and common femoral occlusive disease. *J Vasc Surg*. 2011 Aug;54(2):402-11. doi: 10.1016/j.jvs.2011.01.027. Epub 2011 Apr 30. PMID: 21531527.
15. Nishibe, T., Kondo, Y., Dardik, A., Muto, A., Koizumi, J., & Nishibe, M. (2009). Hybrid surgical and endovascular therapy in multifocal peripheral TASC D lesions: up to three-year follow-up. *The Journal of cardiovascular surgery*, 50(4), 493–499.
16. Starodubtsev, V., Mitrofanov, V., Ignatenko, P., Gostev, A., Preece, R., Rabtsun, A., Saaya, S., Popova, I., & Karpenko, A. (2022). Editor's Choice - Hybrid vs. Open Surgical Reconstruction for Iliofemoral Occlusive Disease: A Prospective Randomised Trial. *European journal of vascular and endovascular surgery : the official journal of the European Society for Vascular Surgery*, 63(4), 557–565. <https://doi.org/10.1016/j.ejvs.2022.02.002>.