

REGRESSION OF PARACETAMOL PROVOKED HEPATOTOXICITY AND NEPHROTOXICITY BY SPIRULINA, BUTYLATED HYDROXYTOLUENE AND CILOSTAZOL IN ADULT MALE ALBINO RATS: MODULATION OF INFLAMMATORY, OXIDATIVE STRESS AND APOPTOTIC BIOMARKERS

Marwa Abd El-Moniem Amer¹, Mahitab M. Nageeb², Sabah Mohamed Hanafy^{3,8}, Doaa M. Hendawy⁴, Maha Saad Elmenshawi⁵, Gena M. Elmakromy⁶, Dena Mohamed Naguib Abdel Moawed^{1,7}

¹Department of Forensic Medicine and Clinical Toxicology, Faculty of Medicine, Zagazig University, Egypt.

²Department of Pharmacology, Faculty of Medicine, Zagazig University, Egypt.

³Department of Pathology, Faculty of Medicine, Zagazig University, Egypt.

⁴Department of Biochemistry, Faculty of Medicine, Zagazig University, Egypt.

⁵Department of Clinical Pathology, Al-Ahrar Teaching Hospital, General Organization for Teaching Hospitals, and Institutes (GOTHI), Ministry of Health, Zagazig, Egypt.

⁶Department of Internal Medicine, Faculty of Medicine, Badr University in Cairo, Egypt.

⁷Forensic Medicine and Clinical Toxicology Department, Faculty of Medicine, Badr University, Egypt

⁸Laboratory Medicine Department, Applied Medical Science, Al Baha University, Saudi Arabia.

ABSTRACT

Background: Paracetamol (acetaminophen) is one of the over-the-counter analgesic antipyretic drugs. It is associated with hepatotoxicity and nephrotoxicity in overdose. Spirulina, and Butylated hydroxytoluene are valuable antioxidants. Cilostazol is a phosphodiesterase type 3 inhibitor with protective effects in some hepatic and renal injury models. **Aim of the work:** This study aims to evaluate the ameliorative effect of spirulina, BHT, and cilostazol against paracetamol-induced hepatotoxicity and nephrotoxicity. **Material and Methods:** fifty-four adult male Wistar rats were classified into 9 equal groups: I (Control group), II (Paracetamol group), III (Spirulina group), IV (BHT group), V (Cilostazol group), VI (Paracetamol+Spirulina preventive group), VII (Paracetamol+BHT preventive group), VIII (Paracetamol+Spirulina+BHT preventive group) and IX (Paracetamol+Cilostazol treatment group). Blood samples were collected at the end of the study and rats were then sacrificed and livers and kidneys were handled for biochemical, histopathological, and immunohistochemical studies. **Results:** Paracetamol overdose persuaded a significant elevation in serum liver enzymes (AST, ALT and ALP), urea, and creatinine levels. Also, it induced a significant elevation in serum MDA with a substantial decrease of hepatic GST, SOD in the liver, and catalase in the kidney. It also increased the expression of MAPK, JNK, IL8, NF-κB1, BAX and immunohistochemical P53. The administration of spirulina, BHT, and cilostazol with paracetamol significantly improves these previous parameters, implying that hepatic and renal tissues were sheltered from paracetamol's hazardous effects. **Conclusion:** Spirulina, BHT and Cilostazol administration ameliorated Paracetamol hepatotoxicity and nephrotoxicity through antioxidant, anti-inflammatory, and anti-apoptotic impacts.

Keywords: Paracetamol; Acetaminophen; Spirulina; BHT; Cilostazol; Hepatotoxicity; Nephrotoxicity

Corresponding author: Dr. Dena Mohamed Naguib Abdel Moawed

Email: Denaforensic@gmail.com; dena@zu.edu.eg

Orcid No: 0000-0002-4763-2449

INTRODUCTION

Paracetamol (acetaminophen) is a common over-the-counter analgesic antipyretic drug used worldwide. It induces liver damage and renal tubular necrosis in overdose due to the production of the of N-acetyl-p-benzoquinone imine (NAPQI), its metabolic product, and due to the depletion of liver glutathione (*Britza et al., 2020*).

Even though hepatotoxicity is more common with paracetamol, renal impairment may happen and is occasionally fatal (*Baponwa et al, 2022*).

Paracetamol is metabolized in the liver through glucuronidation and sulfation at therapeutic doses. Most metabolites are water-soluble and excreted by the kidneys. Only a very tiny amount of paracetamol

(around 5-9%) is removed intact in the urine. Cytochrome P₄₅₀ (CYP-450) enzymes, primarily CYP 2E1, oxidize the residual paracetamol converting it into NAPQI, a highly reactive intermediate metabolite (**Lancaster et al., 2015**). Reduced glutathione (GSH) then reduces NAPQI to a comparatively harmless molecule named mercapturic acid, which is removed by the kidney (**Rang et al., 2020**).

In paracetamol overdose, the stores of glutathione are exhausted and so, a greater volume is oxidized by CYP-450, producing more NAPQI (**Rang et al., 2020**). These reactive intermediates form adducts with glutathione, and sulfhydryl groups on the proteins of the cell (**Chinnappan et al., 2019**) leading to activation of apoptotic markers triggering cell death and tissue necrosis (**Canayakin et al., 2016**).

In general, paracetamol has few tolerable side effects when taken in low doses, but there have been reports that certain risk factors, such as long-term alcoholism, tobacco use, malnutrition, concurrent use of certain substances, such as anticonvulsants or anti-tuberculosis medications, and genetic susceptibility, can increase paracetamol toxicity (**Chun et al., 2009; Yoon et al., 2016; Bunchorntavakul and Reddy, 2018**).

Therefore, since paracetamol toxicity is primarily caused by oxidative damage, several pharmaceutical and nutraceutical compounds have been studied for their potential to protect hepatic and renal tissues from paracetamol toxicity. Antioxidants as *Nigella sativa* (**Canayakin et al., 2016**), Curcumin and quercetin (**Yousef et al., 2010**), can strengthen the immune system, encourage the healing of DNA mutilation, and shield cells from the injurious effects of reactive oxygen species.

Spirulina platensis is a filamentous blue-green alga that is grown for commercial purposes in several countries around the world. It is an important source of antioxidant nutraceuticals and potential pharmaceuticals (**Eltantawy et al., 2018**).

Phycocyanin, phenolic compounds, fatty acids (linoleic acid, F-linolenic acid, and palmitic acid), beta-carotene, tocopherols, essential amino acids, and vitamins A and E,

are all active ingredients found in spirulina, and due to its lengthy memoir as a food source and its ideal safety pattern in animal and human, spirulina is well known to be safe for consumption by both humans and animals. Spirulina administration showed a Protective effect of against cyclophosphamide-induced urotoxicity through the decrease of malondialdehyde (MDA) level and elevation of reduced glutathione (GSH) level (**Eltantawy et al., 2018**).

Furthermore, Spirulina showed a caring effect against the damage induced by furan in kidney and liver of rat, via suppression of the serum levels of the tissue injury biomarkers, reduced the inflammatory response, repaired the cytotoxic alterations, and restored the perturbed morphology of the hepatic and renal tissues (**Khalila et al., 2020**).

Additionally, Spirulina stated protective effect on liver, kidney, and brain acrylamide rats' toxicity via decrease of interleukins (IL-1 β , IL-6), and tumor necrosis factor (TNF- α) with increase of GSH, glutathione peroxidase (GSH-Px), superoxide dismutase (SOD), and catalase (CAT) (**Bin-Jumah et al., 2021**). Therefore, due to its anti-inflammatory and antioxidant outcome, Spirulina was used in our study.

Butylated hydroxytoluene (BHT), a phenol derivative, is a lipophilic organic compound that is regarded as a powerful synthetic antioxidant. It is the structural correspondent of vitamin E that is used as a food preservative. In several studies, BHT enhances the cellular antioxidant enzyme status (**Fahim et al., 2023**). It has been demonstrated to guard against a variety of hepatotoxins together with the toxic effects of different elements in laboratory animals. BHT and Spirulina decreased TNF α , IL6, IL1 β , and thiobarbituric acid reactive substances (TBARS) levels, while increased antioxidants in a rat model of D-galactosamine induced hepatotoxicity (**Al-Qahtani et al., 2019**).

Furthermore, BHT ameliorated tetrachloride induced hepatotoxicity in a rat model (**Dassarmaa et al., 2018**). In a model of allopurinol induced nephrotoxicity, BHT showed an ameliorative effect (**Ansari et al., 1992**).

A common anti-platelet drug used for the treatment of peripheral vascular diseases is cilostazol, a selective phosphodiesterase III (PDE III) inhibitor (*El Awdan et al., 2018*). Cilostazol demonstrated protective outcomes in hepatectomy, ischemia-reperfusion insult, and hepatic steatosis models of liver injury (*Fujii et al., 2017*). Recent research has shown that cilostazol guards against ethanol-provoked hepatocyte impairment by reducing oxidative stress (*Lee et al., 2019*). Additionally, cilostazol reduced oxidative stress, inflammation, and apoptosis to lessen the nephrotoxicity that amikacin caused in rats as it inhibited the production of reactive oxygen species, MDA, inflammatory cytokines, and nuclear factor kappa B (NF- κ B) (*Saeed et al., 2020*).

Additionally, Cilostazol proved to have hepatoprotective impact in a rat model of bile duct ligation through Sirtuin (SIRT) dependant pathway (*Kabil, 2018*).

Based on the past view about the usefulness and the importance of fighting paracetamol-induced toxicities, seeking different pharmacological manners becomes a demand, and based on the previously confirmed evidence that spirulina, BHT and cilostazol have anti-inflammatory and antioxidant impacts in various models, our analysis was conducted to study the probable protective impact of them versus paracetamol prompted liver and renal toxicity and to study the most likely involved pathways.

THE AIM OF THE WORK

The research question is “Is BHT, Spirulina and Cilostazol have ameliorative effect against paracetamol induced hepatotoxicity?”

This study aimed to evaluate the protective effect of BHT and Spirulina, the curative effect of Cilostazol against paracetamol induced hepatotoxicity and nephrotoxicity and the possible involved pathways.

MATERIAL AND METHODS

1. Drugs:

Paracetamol powder, BHT, and Cilostazol were obtained from Sigma-Aldrich, St. Louis, MO, USA. Paracetamol, and Cilostazol powders were dissolved in saline. BHT was mixed with normal diet. Pure premium Spirulina platensis was purchased from HerbaForce, UK, and was mixed with

distilled water, then the suspension was given orally to rats everyday using sonde. The suspension was prepared at time of use for each animal to ensure the same concentration.

2. Experimental Animals:

Fifty-four male Wistar adult rats, average age of 6 to 7 weeks and weighing ~250-300g, were procured from the Faculty of Veterinary Medicine, Zagazig University, Egypt. The animals were allowed to acclimatize for one week under exact pathogen-free circumstances, with a standard humidity level, 12-hour light/dark cycles, and a temperature of $22 \pm 2^{\circ}\text{C}$. The rats were provided with ordinary pelleted food and water, which were accessible without any restrictions. The research was carried out in the animal housing facility located in the Faculty of Medicine, Zagazig University.

3. Study design

After the acclimatization period, rats were randomly classified into 9 groups (6 rats/group) as follows:

- I. (Control group):** Rats fed normal diet with water *ad libitum*.
- II. (Paracetamol group):** Rats were administrated a daily dose of (2000 mg/kg) of aqueous suspension of paracetamol by oral gavage for 7 consecutive days (*El-Bakry et al., 2017*).
- III. (Spirulina group):** Rats were administrated Spirulina suspension in a dose of (1000 mg/kg/day) (*Nakata et al., 2021*) orally for ten days.
- IV. (BHT group):** Rats were administrated BHT in a dose of (0.5 mg/kg/day) (*Dassarmaa et al., 2018*) mixed with normal diet for ten days.
- V. (Cilostazol group):** Rats were administrated cilostazol in a dose of (30 mg/kg/day) (*da Motta and de Brito et al., 2016*) orally for 15 days.
- VI. (Paracetamol + Spirulina preventive group):** Rats were administrated paracetamol aqueous suspension for 7 days simultaneously with Spirulina suspension by oral gavage for 10 days at the same previously mentioned doses.
- VII. (Paracetamol + BHT preventive group)** Rats were administrated paracetamol aqueous suspension for 7 days simultaneously with

BHT mixed with normal diet for 10 days at the same previously mentioned doses.

VIII. (Paracetamol + Spirulina + BHT preventive group): Rats were administrated Paracetamol for 7 days simultaneously with Spirulina, and BHT for 10 days at the same previously mentioned doses.

IX. (Paracetamol + Cilostazol treatment group) Rats received paracetamol aqueous suspension for 7 days and were then administered cilostazol for 15 days at the same previously mentioned doses.

4. Rationale of dose selection

The dose of spirulina was used according to (*Nakata et al., 2021*), who studied its protective effect against lead poisoning and obesity. However, BHT was selected according to (*Dassarmaa et al., 2018*), who stated its protective effect as antioxidant against carbon tetrachloride-induced hepatotoxicity. Cilostazol dose was selected like (*da Motta and de Brito, 2016*), who studied its ameliorative effect against hypercholesterolemia.

5. Blood collection and serum separation:

Rats' orbital sinuses were used to obtain blood samples (2ml/rat) using capillary tubes without heparin (*Sorg and Buckner, 1964*) after the animals were anesthetized. Blood samples were kept to clot (incubated at room temperature), and then centrifuged at 3000 g for 15 minutes and serum was then separated and stored at -20°C until used for evaluation of liver enzymes (alanine transaminase (ALT), alkaline phosphatase (ALP) and aspartate transaminase (AST)), kidney parameters (Urea and creatinine) and Malondialdehyde (MDA).

6. Tissue sampling:

Rats were beheaded as a means of death on the 10th day for all groups except for the IX group; rats were beheaded on the 22nd day. The two kidneys and the liver were separated. A portion of the left kidney and a part of the liver were homogenized in 1 ml of 1X phosphate buffer solution (PBS), stored overnight at -20°C, and then cleaned with 1X PBS. The homogenates were centrifuged for 5 minutes at 5000 x g, 2 - 8°C after two freeze-thaw cycles were used to rupture the cell membranes. The supernatant was taken off and analyzed very quickly. The sample was

centrifuged over after thawing before the measurement of superoxide dismutase (SOD) and glutathione transferase (GST) in the liver, catalase in the kidney, and gene expression of mitogen-activated protein kinase (MAPK), Jun N-terminal kinase (JNK), Interleukin 8 (IL8), nuclear factor kappa B (NF-κB1), and Bcl-associated X protein (BAX). The other part of the liver and the right kidney were immersed in 10% formalin for the histopathological and immunohistochemical examination.


7. Biochemical assay:

7.1. Liver enzymes (ALT, AST, and ALP activity) assay in serum:

Liver enzymes were assayed colorimetrically consistent with the methods explained by *Moss et al (1982)*; *El-Aaser and El-Merzabani (1979)* respectively using kits purchased from Biodiagnostic Company, Dokki, Giza, Egypt (CAT NO. AL10 31, AS 10 61, and AP 26 10) respectively.

7.2. Urea assay

The method is based on the following reaction:



The ammonium ions measured by Berthelot reaction. The blue dye product reaction absorbs light proportional to the initial urea concentration according to Biodiagnostic Kit, CAT NO: UR 21 10 (*Tabacco et al., 1979*).

7.3. Serum creatinine assay

It was measured according to the fact that it forms a coloured complex with picrate in an alkaline media (Biodiagnostic Kit, CAT NO: CR 12 50 (*Young, 1995*)).

7.4. MDA evaluation in serum

Colorimetric assay was performed using the techniques outlined by *Ohkawa et al (1979)* using the corresponding commercial kits 'Biodiagnostic Kit, Cairo, Egypt (CAT. NO. MD 25 29). When combined with thiobarbituric acid, MDA can produce a variant complex.

7.5. GST activity detection

The GST activity in tissue homogenates was performed as reported by *Saggu and Kumer (2008)*. The reaction mixture consisted of 1.0 ml potassium phosphate buffer, 0.05 ml CDNB, 0.4 ml reduced GSH, 0.2 ml of sample, and 1.35 ml of water in a total assay

volume of 3.0 ml. The changes in absorbance were recorded at 340 nm.

7.6. Catalase enzyme activity evaluation.

The assay was performed using the technique outlined by *Aebi (1984)* in kidney tissue homogenate which was mixed with H₂O₂ and incubated for 2 minutes. The CAT activity was measured by the change of absorbance at 240 nm for 3 minutes.

7.7. SOD enzyme activity evaluation

The SOD activity was estimated in liver tissue homogenates by the method of *Marklund and Marklund (1974)*. Enzyme kinetic activity was recorded at 540 nm for 3 minutes and change in optical density (OD) per minute (Δ OD) was used to calculate % auto-oxidation inhibition to derive SOD units.

7.8. Gene expression for detection of MAPK, JNK, IL 8, NF- κ B1 and BAX

Trizol reagent (Thermo Fisher Scientific; Waltham, MA, United States) was used to extract total RNA. The concentration and purity of the extracted RNA were assessed using the Nanodrop spectrophotometer by measuring the OD at 260 and 280 nm and accepting A₂₆₀/A₂₈₀ at a ratio of 1.8–2.1, followed by a two-step real-time PCR to evaluate gene expression with specific primers illustrated in **Table (1)**. The relative expression level of the target genes was normalized to that of the housekeeping GAPDH, and the relative fold changes in gene expression were calculated based on the method described by *Livak and Schmittgen (2001)*.

Table (1): Primer sequence of MAPK, JNK, NF- κ B1, IL-8, BAX and GAPDH.

Gene	Sequence	Product size
MAPK	F: AGTGGCTGACCCTTATGAC	418
	R: CACAGTGAAGTGGGATGGA	
JNK	F: ATTTGGAGGAGCGAACTAAG	182
	R: ATTGACAGACGGCGAAGA	
NF- κ B1	F: CCACTGTCAACAGATGGCCC	177
	R: CTTTGCAGGCCCCACATAGT	
IL8	F: ACAGGCAGGCTGTAGTTGTC	70
	R: ATCACCAGCGAGTTTCCAG	
BAX	F: CCCTGTGCACTAAAGTGCCC	109
	R: CTTCTTCACGATGGTGAGCG	
GAPDH	F: GGCACAGTCAAGGCTGAGAATG	143
	R: ATGGTGGTGAAGACGCCAGTA	

MAPK mitogen-activated protein kinase, JNK Jun N-terminal kinase, IL8 interleukin 8 and NF- κ B1 nuclear factor kappa B, BAX B-cell lymphoma protein 2 (Bcl-2)-associated X.

Histopathological method

8.1. Hematoxylin and Eosin (H&E) sections

The right kidney and part of the liver were submerged in buffered formalin 10% for 2 days, dehydrated with ascending grades of ethanol (70%-100%), cleared in xylene, embedded in paraffin wax, segmented to 5 μ m thickness by utilizing automated microtome and stained by Hematoxylin and Eosin (H&E) then examined by light microscopy (*Suvarana et al., 2018*).

Hepatic necroinflammation score in each section was graded according to the criteria explained by *Brunt et al. (1999)* from 0 to 3 as follow; No hepatocyte injury/inflammation = Score 0; Mild focal zone 3 hepatocyte injury/inflammation =Score 1; Noticeable zone 3 hepatocyte injury/inflammation = Score 2; Severe zone 3 hepatocyte injury/inflammation = Score 3. Normal renal histological features showed renal corpuscles and tubules in the renal cortex.

8.2. Immunohistochemical sections

Apoptosis was demonstrated by Immunohistochemical analysis of P53. Paraffin sections from rat liver and kidney sections were stained by immunohistochemistry according to *Hsu et al. (1981)* using Rabbit polyclonal anti-p53 antibody (ab131442) at 1/100 dilution. The tissue sections from all experimental groups were dewaxed and hydrated. Staining was then performed according to manufacturer protocols and by using the DAB chromogenic agent (Expose mouse and rabbit specific HRP/DAB detection kit, Abcam; Ready-to-use; Cat. #: ab80436). Counterstaining by hematoxylin was done. The intensity of P53 expression in positively stained cells (5–7 microscopic fields from well labelled areas and not overlapping were randomly used at $\times 200$ magnification) was quantified by using NIH Image J1047v software. The expression of p53 was scored for percentage and intensity of immunostaining as follows: less than 10% stained cells is weak, 10- 20 % stained cells is mild, moderate for staining 20- 45%, moderate to high for 45- 65%, stained cells. A high expression for staining in more than 65% of cells (*Akhter et al., 2019*).

Statistical Analysis:

Data were collected and studied by using SPSS software (Version 22.0) (SPSS Inc, Chicago, USA). The data were expressed as mean \pm standard deviation (SD). One-way analysis of variances (one-way ANOVA) was used to compare the examined groups statistically, and post hoc least significant difference (LSD) tests for multiple comparisons were then performed. Differences were deemed statistically significant when the p-value was <0.05 .

RESULTS

Biochemical results:

Effect of Spirulina, BHT and Cilostazol on paracetamol-triggered elevation of serum liver enzymes ALT, AST, and ALP

The biochemical findings of control group, Spirulina group, BHT group and Cilostazol group were within normal values as regard serum liver enzymes ALT, AST, and ALP. There was no statistically significant difference observed between them. Paracetamol group provoked a meaningful ($P<0.05$) elevation in serum hepatic enzymes when compared to the control group, indicating impairment of liver functions. Spirulina, BHT, and Cilostazol administration with paracetamol (Paracetamol + Spirulina preventive group, Paracetamol+ BHT preventive group, Paracetamol+ Spirulina+ BHT preventive group and Paracetamol+ Cilostazol treatment group) significantly ameliorated the impairment

of liver functions as there was a significant ($P<0.05$) decrease in levels of hepatic enzymes when compared with the Paracetamol group which not returned to normal levels when compared with control group as shown in **Table (2)**.

Effect of Spirulina, BHT and Cilostazol on paracetamol-triggered elevation of serum Urea, and Creatinine

The biochemical findings of control group, Spirulina group, BHT group and Cilostazol group were within normal values as regard serum urea, and creatinine. There was no statistically significant difference observed between them. Paracetamol group exhibited considerable high levels when compared to control group ($P<0.05$), demonstrating the expected effects of the overdose. Spirulina, BHT, and Cilostazol administration with paracetamol (Paracetamol + Spirulina preventive group, Paracetamol+ BHT preventive group, Paracetamol+ Spirulina+ BHT preventive group and Paracetamol+ Cilostazol treatment group), significantly ($P<0.05$) lower these levels when compared with the Paracetamol group, suggesting their ameliorative effects on kidney functions. Additionally, Creatinine in the Paracetamol+ Spirulina+ BHT preventive, and the Paracetamol+ Cilostazol treatment groups returned to normal levels when compared with control group (**Table 3**).

Effect of Paracetamol, Spirulina, BHT, and Cilostazol on oxidative stress and antioxidant biomarkers

There was no statistically significant difference observed between control group, Spirulina group, BHT group and Cilostazol group as regard serum MDA, hepatic GST, SOD in the liver, and catalase in the kidney. Paracetamol administration induced a substantial rise in serum MDA when compared to control group ($P<0.05$). However, the antioxidant enzyme activity was drastically depressed (hepatic GST, SOD in the liver, and catalase in the kidney), indicating oxidative stress. Administration of Spirulina, BHT, and Cilostazol with paracetamol (Paracetamol + Spirulina preventive group, Paracetamol+ BHT preventive group, Paracetamol+ Spirulina+ BHT preventive group and Paracetamol+ Cilostazol treatment group) diminished the levels of MDA with elevation of GST, SOD, and catalase enzyme activity when compared with the Paracetamol group ($p<0.05$) indicating their role in the protection of hepatic and renal tissues from oxidative injury as displayed in **Table (4)**.

Effect of Spirulina, BHT, and Cilostazol on paracetamol-triggered MAPK, JNK, IL8 and NF-κB1 gene expression.

There was no statistically significant difference observed between control group, Spirulina group, BHT group and Cilostazol group as regard MAPK, JNK, IL8 and NF-κB1 gene expression. Paracetamol overdose induced gene expression of MAPK, JNK, IL8, and NF-κB1 (inflammatory markers) when compared to control group ($P<0.05$) which means that paracetamol triggers inflammation. Administration of Spirulina, BHT, and Cilostazol with paracetamol (Paracetamol + Spirulina preventive group, Paracetamol + BHT preventive group, Paracetamol+ Spirulina+ BHT preventive group and Paracetamol + Cilostazol treatment group) significantly ($p<0.05$) decreased these parameters when compared to the Paracetamol group, signifying that tissues were safeguarded from their hazardous effects (Table 5).

Effect of Spirulina, BHT, and Cilostazol on paracetamol-triggered BAX gene expression.

There was no statistically significant difference observed between control group, Spirulina group, BHT group and Cilostazol group as regard the expression of BAX (the pro-apoptotic member). Paracetamol overdose increased the expression of BAX when compared to control group ($P<0.05$) which means that paracetamol triggers apoptosis. Administration of Spirulina, BHT, and Cilostazol with paracetamol (Paracetamol + Spirulina preventive group, Paracetamol+ BHT preventive group, Paracetamol+ Spirulina+ BHT preventive group and Paracetamol+ Cilostazol treatment group) significantly ($P<0.05$) decreased BAX expression when compared with the Paracetamol group, signifying that tissues were safeguarded from its hazardous effect as displayed in Table (6).

Table (2): Effect of Spirulina, BHT, and Cilostazol on paracetamol-triggered elevation of serum liver enzymes ALT, AST, and ALP.

Group (N=6)	ALT (U/L)	AST (U/L)	ALP (U/L)
I. Control group	27.21±0.974 ^A	40.68±0.400 ^A	42.71±1.115 ^A
II. Paracetamol group	77.76±4.154 ^B	76.56 ±1.625 ^B	89.54±1.722 ^B
III. Spirulina group	27.39±1.035 ^A	40.61±1.037 ^A	42.71±1.704 ^A
IV. BHT group	26.82±1.475 ^A	40.90±1.561 ^A	42.85±1.704 ^A
V. Cilostazol group	26.79±2.875 ^A	40.83±2.476 ^A	41.54±2.220 ^A
VI. Paracetamol + Spirulina preventive group	56.29±3.032 ^C	62.88±2.781 ^C	81.80±1.492 ^C
VII. Paracetamol+ BHT preventive group	44.84±2.285 ^D	55.25±2.256 ^D	72.31±2.461 ^D
VIII. Paracetamol+ Spirulina+ BHT preventive group	35.51±3.587 ^E	46.54±1.842 ^E	58.22±1.843 ^E
IX. Paracetamol+ Cilostazol treatment group	33.00±3.033 ^E	47.87±2.172 ^E	55.7±33.528 ^E

Values represent Mean±SD. The capital letters (A to E) represents the interpretation of SPSS output concerning Multiple Comparison procedure (LSD). Within the same column, values without common superscript capital letters are significantly different ($p<0.05$). BHT Butylated hydroxytoluene, ALT alanine transaminase, AST aspartate transaminase, ALP alkaline phosphatase.

Table (3): Effect of Spirulina, BHT, and Cilostazol on paracetamol-triggered elevation of serum Urea and Creatinine.

Group (N=6)	Urea (mg/dl)	Creatinine (mg/dl)
I. Control group	23.77±0.985 ^A	0.43±0.043 ^A
II. Paracetamol group	67.34±2.667 ^B	2.48±0.368 ^B
III. Spirulina group	23.48±1.812 ^A	0.45±0.096 ^A
IV. BHT group	23.30±1.811 ^A	0.44±0.064 ^A
V. Cilostazol group	25.14 ±2.620 ^A	0.45±0.061 ^A
VI. Paracetamol + Spirulina preventive group	56.57±3.596 ^C	1.75±0.161 ^C
VII. Paracetamol+ BHT preventive group	42.38±1.447 ^D	1.08±0.447 ^D
VIII. Paracetamol+ Spirulina+ BHT preventive group	33.30±2.515 ^E	0.69±0.087 ^{AD}
IX. Paracetamol+ Cilostazol treatment group	35.10± 3.904 ^E	0.66±0.077 ^A

Values represent Mean±SD, The capital letters (A to E) in the tables represents the interpretation of SPSS output concerning Multiple Comparison procedure (LSD). Within the same column, values without common superscript capital letters are significantly different ($p<0.05$). BHT Butylated hydroxytoluene.

Table (4): Effect of Paracetamol, Spirulina, BHT, and Cilostazol on oxidative stress, and antioxidant biomarkers

Group (N=6)	Serum MDA (nmol/L)	Hepatic GST (μ /gm tissue)	Hepatic SOD (U/gm tissue)	Renal catalase (U/gm tissue)
I. Control group	0.33 \pm 0.069 ^A	88.55 \pm 1.857 ^A	12.57 \pm 0.329 ^A	119.10 \pm 4.229 ^A
II. Paracetamol group	2.50 \pm 0.130 ^B	61.42 \pm 2.449 ^B	4.98 \pm 0.201 ^B	63.98 \pm 2.710 ^B
III. Spirulina group	0.34 \pm 0.040 ^A	89.07 \pm 1.138 ^A	12.21 \pm 0.382 ^A	118.70 \pm 3.683 ^{AC}
IV. BHT group	0.32 \pm 0.069 ^A	88.31 \pm 1.878 ^A	12.25 \pm 0.336 ^A	117.70 \pm 5.409 ^A
V. Cilostazol group	0.34 \pm 0.057 ^{AE}	82.02 \pm 2.681 ^{FA}	14.15 \pm 1.765 ^A	119.60 \pm 5.361 ^{AC}
VI. Paracetamol+Spirulina preventive group	2.01 \pm 0.559 ^C	70.88 \pm 3.783 ^C	9.10 \pm 0.179 ^C	83.23 \pm 5.135 ^D
VII. Paracetamol+BHT preventive group	1.40 \pm 0.222 ^D	76.33 \pm 4.240 ^D	9.99 \pm 0.519 ^{DC}	94.35 \pm 3.261 ^E
VIII. Paracetamol+Spirulina+BHT preventive group	0.77 \pm 0.085 ^E	88.19 \pm 1.868 ^E	11.00 \pm 0.171 ^{EAD}	108.5 \pm 2.798 ^{FC}
IX. Paracetamol+Cilostazol treatment group	0.66 \pm 0.153 ^{AE}	88.97 \pm 2.008 ^{AEF}	10.11 \pm 1.794 ^{CDE}	110.7 \pm 9.093 ^{ACF}

Values represent Mean \pm SD, the capital letters (A to E) in the tables represents the interpretation of SPSS output concerning Multiple Comparison procedure (LSD). Within the same column, values without common superscript capital letters are significantly different ($p < 0.05$). BHT Butylated hydroxytoluene, MDA malondialdehyde, GST glutathione transferase, SOD superoxide dismutase.

Table (5): Effect of Spirulina, BHT, and Cilostazol on paracetamol triggered MAPK, JNK, IL8 and NF- κ B1 gene expression.

Group (N=6)	MAPK	JNK	IL-8	NF- κ B1
I. Control group	1.01 \pm 0.013 ^A	1.07 \pm 0.078 ^A	1.24 \pm 0.104 ^A	1.02 \pm 0.015 ^A
II. Paracetamol group	5.51 \pm 0.995 ^B	3.78 \pm 0.546 ^B	6.80 \pm 0.519 ^B	7.51 \pm 0.490 ^B
III. Spirulina group	1.19 \pm 0.407 ^A	1.11 \pm 0.131 ^{CA}	1.28 \pm 0.513 ^A	1.15 \pm 0.183 ^A
IV. BHT group	1.04 \pm 0.032 ^{AC}	1.37 \pm 0.437 ^A	1.24 \pm 0.127 ^A	1.04 \pm 0.039 ^A
V. Cilostazol group	1.04 \pm 0.040 ^{GACF}	1.15 \pm 20.168 ^{ACEF}	1.32 \pm 0.063 ^A	1.04 \pm 0.037 ^A
VI. Paracetamol + Spirulina preventive group	3.12 \pm 0.229 ^D	2.82 \pm 0.103 ^D	3.00 \pm 0.084 ^C	5.11 \pm 0.714 ^C
VII. Paracetamol+ BHT preventive group	2.00 \pm 0.661 ^{EC}	1.84 \pm 0.409 ^{DC}	2.87 \pm 0.628 ^C	3.26 \pm 1.387 ^D
VIII. Paracetamol+ Spirulina+ BHT preventive group	1.42 \pm 0.273 ^{FACE}	1.38 \pm 0.335 ^{ACDE}	1.64 \pm 0.133 ^A	2.06 \pm 0.420 ^A
IX. Paracetamol+ Cilostazol treatment group	1.53 \pm 0.272 ^{ACEFG}	1.44 \pm 0.417 ^{ACDEF}	1.65 \pm 0.106 ^A	3.23 \pm 1.039 ^A

Values represent Mean \pm SD, the capital letters (A to E) in the tables represents the interpretation of SPSS output concerning Multiple Comparison procedure (LSD). Within the same column, values without common superscript capital letters are significantly different ($p < 0.05$). BHT Butylated hydroxytoluene, MAPK mitogen-activated protein kinase, JNK Jun N-terminal kinase, IL-8 interleukin 8 and NF- κ B1 nuclear factor kappa B.

Table (6): Effect of Spirulina, BHT, and Cilostazol on paracetamol-triggered increased BAX expression.

Group (N=6)	BAX
I. Control group	1.04 \pm 0.042 ^A
II. Paracetamol group	8.36 \pm 0.542 ^B
III. Spirulina group	1.07 \pm 0.079 ^A
IV. BHT group	1.09 \pm 0.119 ^A
V. Cilostazol group	2.19 \pm 0.473 ^A
VI. Paracetamol + Spirulina preventive group	4.48 \pm 0.339 ^C
VII. Paracetamol+ BHT preventive group	3.78 \pm 0.235 ^D
VIII. Paracetamol+ Spirulina+ BHT preventive group	1.69 \pm 0.313 ^E
IX. Paracetamol+ Cilostazol treatment group	1.05 \pm 0.051 ^A

Values represent Mean \pm SD, the capital letters (A to E) in the tables represents the interpretation of SPSS output concerning Multiple Comparison procedure (LSD). Within the same column, values without common superscript capital letters are significantly different ($p < 0.05$). BHT Butylated hydroxytoluene, BAX B-cell lymphoma protein 2 (Bcl-2)-associated X.

Histopathological findings:**A. Liver H&E results:**

The normal architecture of hepatic cells, sinusoids, portal triads, and central veins was observed in the control group (**Figure 1A**), the spirulina group (**Figure 1B**), the BHT group (**Figure 1C**), and the cilostazol group (**Figure 1D**). However, the paracetamol group revealed diffusely distributed degenerative changes primarily micro-vesicular steatosis beside unicellular hepatic necrosis (**Figure 1E**) (**Score 3**). Engorged hepatic vasculatures with the presence of minute focal areas of round cell infiltrates were seen in some examined sections of the paracetamol group (**Figure 1F**). Moreover, few scattered areas of prominent ballooning degeneration were detected in the Paracetamol + Spirulina preventive group (**Figure 1G**) with partial protection of hepatic structures compared to the paracetamol group. However, few numbers of hydropic degenerated cells particularly within centio-lobular areas were seen in the Paracetamol + BHT preventive group (**Figure 1H**) (**Score 2**) involves significant improvement in the hepatocyte architecture in many regions near the central veins and portal tracts. The Paracetamol + Spirulina + BHT preventive group (**Figure 1I**) (**Score 1**) showed marked improvement in hepatic cord arrangement, central veins, and portal tracts. Furthermore, the Paracetamol + Cilostazol treatment group (**Figure 1J**) showed preserved structures of hepatocytes, sinusoids, and central veins with the presence of minute perivascular round cell infiltrates. Hepatic necroinflammation score is shown in **Table (7)**.

B. Kidney H&E results:

The Control group (**Figure 2A**), The Spirulina (**Figure 2B**), The BHT (**Figure 2C**), and the Cilostazol group (**Figure 2D**) showed normal morphology of renal tubules, renal corpuscles, and stroma. However, the common observed lesions in the Paracetamol group (**Figure 2E**) were coagulative necrosis of some renal tubular epithelium with pyknotic nuclei, atrophied glomerular tufts, and interstitial inflammatory cell aggregates. As well, dilated renal capillaries and eosinophilic hyaline casts within some tubular lumina were also detected (**Figure 2F**). The Paracetamol + Spirulina preventive group (**Figure 2G**) showed a reduction of renal damage compared with the paracetamol group. Also, dilatation of some renal tubular lumina with flattened epithelium was seen. Marked improvements in renal tissues were noticed in the Paracetamol + BHT preventive group, the

Paracetamol + Spirulina + BHT preventive group, and the Paracetamol+ Cilostazol treatment group as there were only a few hydropic degenerated renal tubular epithelial in the Paracetamol + BHT preventive group (**Figure 2H**). Additionally, the number of degenerating renal corpuscles has significantly decreased, and the cortical tubules have normal epithelial lining and lack intraluminal casts, but cloudy swelling was seen in some renal epithelium with star-shaped lumina in the Paracetamol + Spirulina + BHT preventive group (**Figure 2I**). The Paracetamol+ Cilostazol treatment group (**Figure 2J**) revealed apparent normal histological structures of renal corpuscles and tubular epithelium.

C. Immunohistochemical findings of P53 among liver tissues:

Immuno-stained sections of the liver against P53 demonstrated nearly non-observed immune-reacted cells in the Control group (**Figure 3A**), the Spirulina group (**Figure 3B**), the BHT group (**Figure 3C**), and the Cilostazol group (**Figure 3D**). While high nuclear expression of P53 was seen in the paracetamol group (**Figure 3E**) compared with other groups. A moderate expression of positively stained cells was detected in the Paracetamol + Spirulina preventive group (**Figure 3F**). Mild number of immune-positive cells were seen in both the Paracetamol + BHT preventive group (**Figure 3G**), and the Paracetamol + Spirulina + BHT preventive group (**Figure 3H**). On the other hand, weak nuclear expression with few positive nuclear staining was seen in the Paracetamol+ Cilostazol treatment group (**Figure 3I**).

D. Immunohistochemical findings of P53 among kidney tissues:

Immuno-stained sections of kidney for P53 showed nearly no renal nuclear expression in the Control group (**Figure 4A**), the Spirulina group (**Figure 4B**), the BHT group (**Figure 4C**), and the Cilostazol group (**Figure 4D**). While the paracetamol group (**Figure 3E**) displayed high nuclear expression in large number of renal tubular epithelium in compared with other groups. Moderate expression of number of positive stained cells were detected in the Paracetamol + Spirulina preventive group (**Figure 3F**). Mild nuclear expression was seen in renal epithelia in the Paracetamol + BHT preventive group (**Figure 4G**), the Paracetamol + Spirulina + BHT preventive group (**Figure 4H**), and the Paracetamol+ Cilostazol treatment group (**Figure 4I**).

Table (7): Effect of Spirulina, BHT, and Cilostazol on paracetamol-triggered hepatic necroinflammation score

Group (N=6)	Score 0	Score 1	Score 2	Score 3
I. Control group	+			
II. Paracetamol group	+			
III. Spirulina group	+			
IV. BHT group	+			
V. Cilostazol group				+
VI. Paracetamol + Spirulina preventive group			+	
VII. Paracetamol+ BHT preventive group			+	
VIII. Paracetamol+ Spirulina+ BHT preventive group		+		
IX. Paracetamol+ Cilostazol treatment group	+			

BHT: Butylated hydroxytoluene. Findings are expressed as Hepatic necroinflammation score in each section was graded according to the criteria described by **Brunt et al, 1999** from 0 to 3 as follow; Score 0: No hepatocyte injury/inflammation; Score 1: Mild focal zone 3 hepatocyte injury/inflammation; Score 2: Noticeable zone 3 hepatocyte injury/inflammation; Score 3: Severe zone 3 hepatocyte injury/inflammation. 0 = None; 1 = Mild; 2 = Moderate; 3 = Severe.

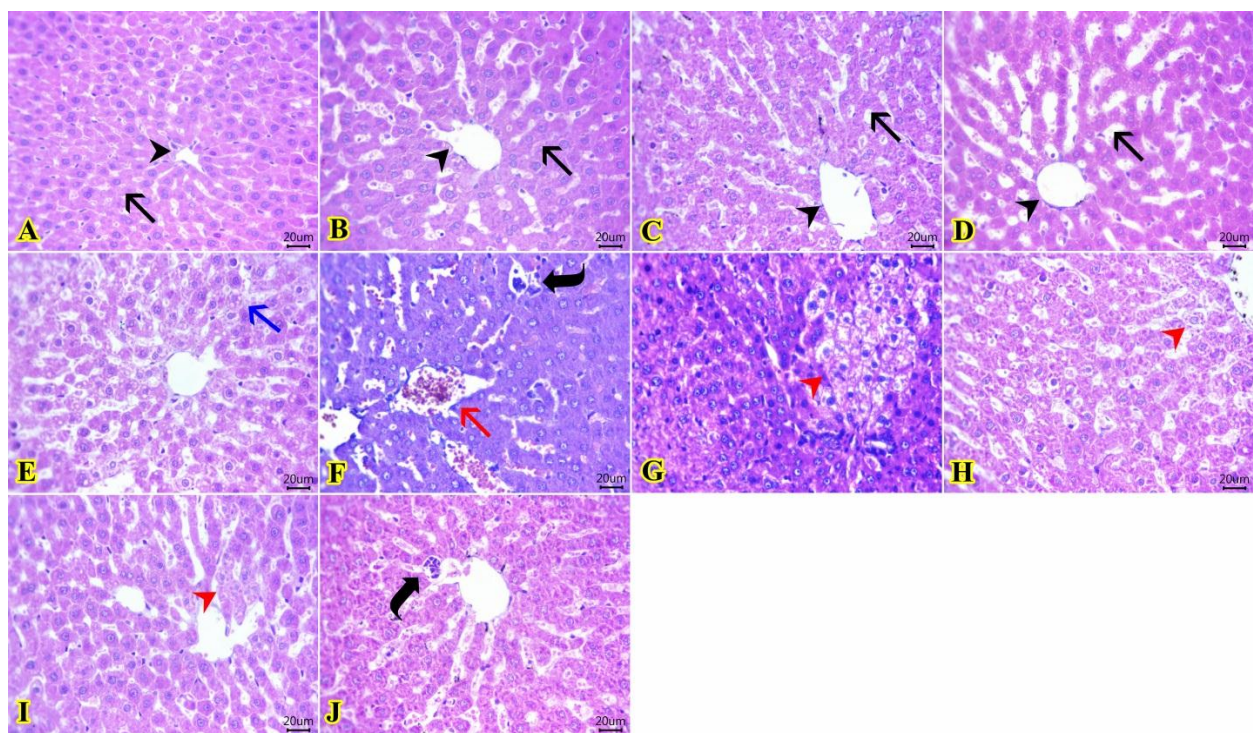


Fig.(1): Photomicrograph of H&E-stained sections from the liver displaying architecture of hepatic cells (**black arrows**), sinusoids, and central vein (**black arrowhead**) in the Control group (A), the Spirulina group (B), the BHT group (C), and the Cilostazol group (D). Diffusely distributed micro-vesicular steatosis (**blue arrow**), Engorged central vein (**red arrow**), and minute focal areas of round cell infiltrates (**curved arrow**) in the Paracetamol group (E, F). Area of prominent ballooning degeneration (**red arrowhead**) in the Paracetamol + Spirulina preventive group (G). Few numbers of hydropic degenerated cells (**red arrowhead**) in the Paracetamol + BHT preventive group (H), and the Paracetamol + Spirulina + BHT preventive group (I). Minute perivascular round cell infiltrates (**curved arrow**) in the Paracetamol+ Cilostazol treatment group (J) [Scale bar $\times 20\mu\text{m}$; H&E $\times 400$].

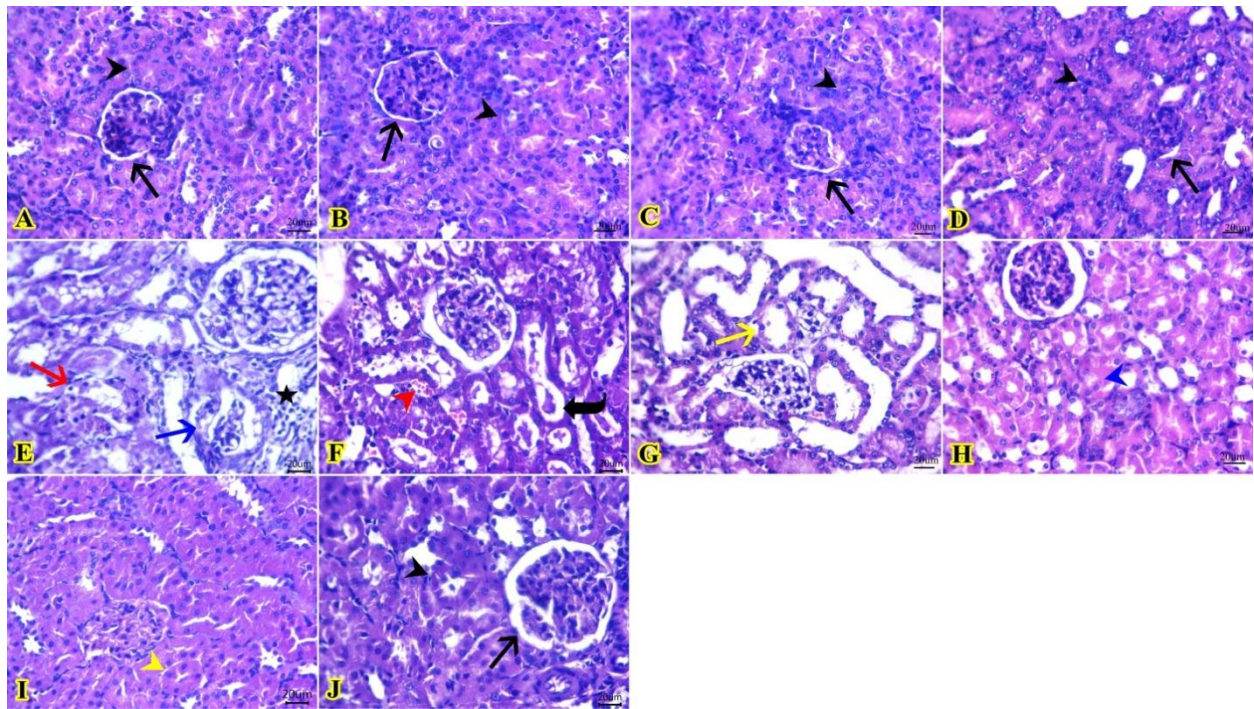


Fig.(2): Photomicrograph of H&E-stained sections from kidney exhibiting normal morphology of renal tubules (**black arrowheads**), and renal corpuscles (**black arrows**) in the Control group (A), the Spirulina group (B), the BHT group (C), and the Cilostazol group (D). Coagulative necrosis of some renal tubular epithelium with pyknotic nuclei (**red arrow**), atrophied glomerular tufts (**blue arrow**), and interstitial inflammatory cell aggregates (**star**). As well, dilated renal capillaries (**red arrowhead**) and eosinophilic hyaline cast within some tubular lumina (**curved arrow**) in the Paracetamol + Spirulina preventive group (E, F). Dilatation of some renal tubular lumina with flattened epithelium (**yellow arrow**) in the Paracetamol + Spirulina preventive group (G). Few hydropic degenerated renal tubular epithelial (**blue arrowhead**) in the Paracetamol + BHT preventive group (H). Cloudy swelling in some renal epithelium with star-shaped lumina (**yellow arrowhead**) in the Paracetamol + Spirulina + BHT preventive group (I). Apparent normal histological structures of renal corpuscle (**black arrow**) and tubular epithelium (**black arrowhead**) in the Paracetamol+ Cilostazol treatment group (J) [Scale bar×20µm; H&E×400].

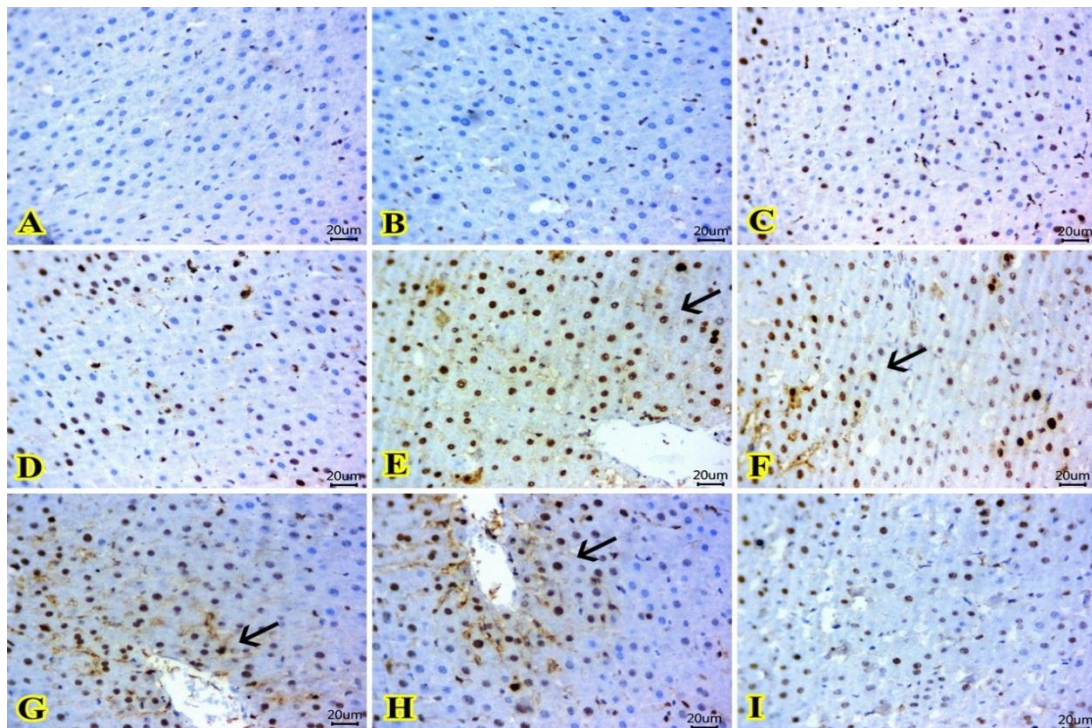


Fig.(3): Photomicrographs of immune-stained liver sections for P53 showing non-observed immune-reacted cells in the Control group (A), the Spirulina group (B), the BHT group (C), and the Cilostazol group (D). High nuclear expression was seen in the paracetamol group (E), and a moderate expression of positively stained cells in the Paracetamol + Spirulina preventive group (F). Mild number of immune-positive cells in both the Paracetamol + BHT preventive group (G), and the Paracetamol + Spirulina + BHT preventive group (H). Weak nuclear immuno-staining with few positive nuclear staining in the Paracetamol+ Cilostazol treatment group (I). (The positive stained cells exhibited brown color "arrows") [IHC counterstaining with Mayer's hematoxylin; Scale bar×20µm].

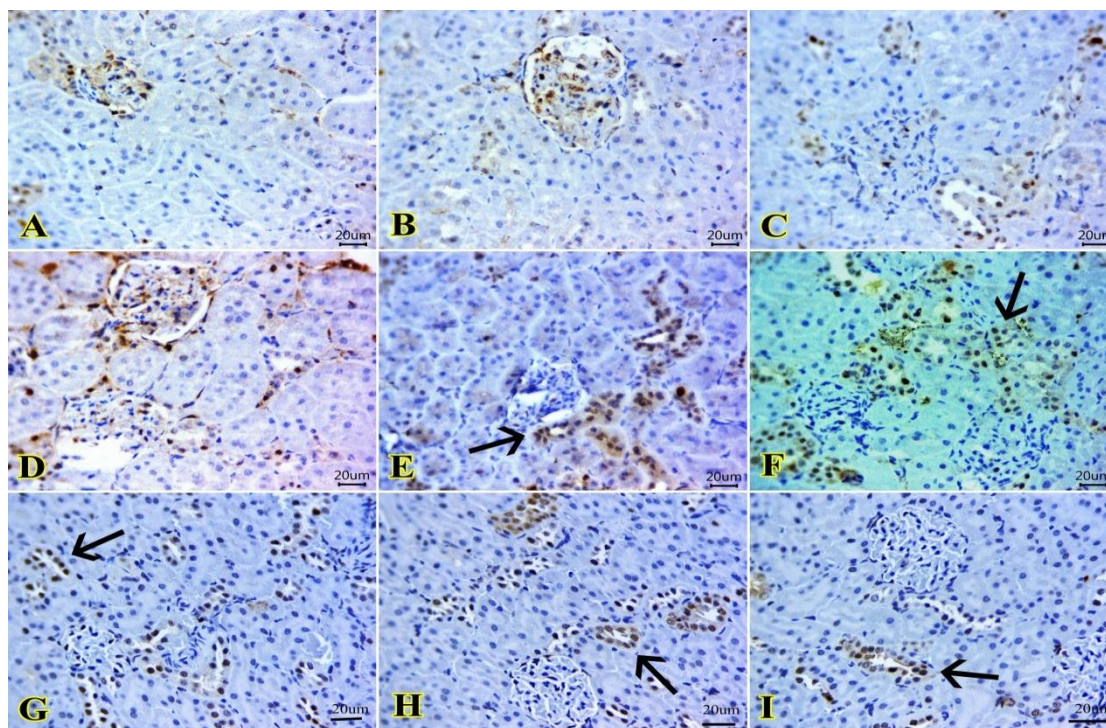


Fig.(4): Photomicrographs of immune-stained kidney sections for P53 showing no renal nuclear expression in the Control group (A), the Spirulina group (B), the BHT group (C), and the Cilostazol group (D). High nuclear expression in large number of renal tubular epithelium in the paracetamol group (E) and Moderate expression of positive stained cells in the Paracetamol + Spirulina preventive group (F). Weak nuclear expression in mild number of renal epithelia in the Paracetamol + BHT preventive group (G), the Paracetamol + Spirulina + BHT preventive group (H), and the Paracetamol+ Cilostazol treatment group (I) (The positive stained cells exhibited brown color "arrows") [IHC counterstaining with Mayer's hematoxylin; Scale bar $\times 20\mu\text{m}$].

DISCUSSION

Acetaminophen, also known as paracetamol, is an analgesic and antipyretic medication that, when used in excess, can cause hepatotoxicity and nephrotoxicity (*Britza et al., 2020*). The toxic reactive metabolite of paracetamol, NAPQI, prompts the formation of reactive oxygen species (ROS) in the liver and kidney which often results in abrupt hepatic and renal failure due to oxidative stress, altered mitochondrial pore permeability, DNA damage, and cell death (*Bunchorntavakul and Reddy 2018*).

The outcomes of this study showed that Paracetamol toxicity promoted oxidative stress, triggered inflammation, and produced apoptosis in hepatic and renal tissues with evident pathology. Paracetamol induced a substantial elevation in serum liver enzymes, urea, creatinine, and BUN demonstrating impairment of hepatic and renal functions.

In concordance with this study, many studies documented liver or kidney toxicity or both by paracetamol (*Chun et al., 2009; Yousef et al., 2010; Yoon et al., 2016; Canayakin et al., 2016; Bunchorntavakul and Reddy, 2018; Kamel et al., 2021*).

Paracetamol hepatotoxicity is caused mainly by its toxic metabolite N-acetyl-p-benzo quinoneimine (NAPQI), which overwhelms the level of glutathione, resulting in lipid peroxidation, liver damage, and DNA fragmentation. The elevated level of transaminases and their discharge from liver cell cytoplasm into the bloodstream indicate harm to liver cell membranes due to paracetamol toxicity (*Bairwa et al., 2010; Coen, 2014*). Liver ischemia, necrosis, and apoptosis are caused by ROS, resulting in alterations in the expression of genes and severe liver impairment (*Cichoż-Lach and Michalak, 2014*).

Unlike hepatotoxicity, the mechanism of renal toxicity by paracetamol isn't well described. Paracetamol renal toxicity may be attributed to the cytochrome P-450 pathway, prostaglandin synthesis, and N-deacetylase enzymes (*Bessem and Vermeulen, 2001*).

Paracetamol has been documented to affect renal function by reducing renal blood flow, glomerular filtration rate, salt excretion, and prostaglandin E2 excretion in both rodents and humans at dosages that are within the

therapeutic range (*Prescott et al., 1989; Tumper et al., 1998*).

Paracetamol has both immediate and long-term harmful impacts on the kidneys. Ingesting large doses (10-15 g) can cause acute toxicity, leading to necrosis of the proximal tubule. Meanwhile, regularly taking smaller doses (500-1000 mg) can cause renal injury (*Blantz, 1996*). This condition occurs when an individual habitually takes an analgesic, which gradually causes renal papillary necrosis and long-term interstitial nephritis, ultimately leading to advanced renal failure (*Henrich, 1998*).

An imbalance between the antioxidant capacity of cells and the level of ROS is a mechanism that contributes to Paracetamol toxicity. In addition, many inflammatory mediators that modify the toxicity are released by various mechanisms (*Hinson et al., 2010*).

In our context, a substantial rise in serum MDA, a marker of lipid peroxidation, significant inhibition in the activity of GST and SOD in the liver, and catalase in the kidney were indicators of oxidative stress brought on by paracetamol toxicity.

The rise in MDA level serves as an indication of lipid peroxidation, which has been proposed to have a close correlation with tissue damage caused by paracetamol (*Sener et al., 2003*). The decline in the levels of SOD and catalase points towards a reduction in the antioxidative potential. Studies have revealed that the decreased functioning of SOD may be linked to the usage of these enzymes in the detoxification of ROS. Additionally, it is a well-known fact that lipid peroxides and ROS can deactivate antioxidant enzymes (*Halliwell and Gutteridge, 1984*).

In addition, our study revealed that Paracetamol increased the expression of MAPK, JNK, IL8, and NF- κ B1 inflammatory markers and BAX, the pro-apoptotic member, and in this context, Paracetamol toxicity in a murine model of hepatotoxicity showed ludes mitochondrial translocation of Bax (*El-Hassan et al., 2003*), and discharge of cytochrome C (*Liu et al., 2020*) which are signaling mechanisms associated with apoptosis.

Furthermore, the hepatic MAPK family protein, including ERK, JNK, and p38 kinase, and NF- κ B expressions were raised with paracetamol (300 mg/kg) in a mouse model of hepatotoxicity (*Kafantaris et al., 2018*).

In this context, many papers supported our study regarding the effect of paracetamol on oxidative stress, inflammatory and apoptotic markers. *Ayres et al. (2020)* stated that, paracetamol, given in a dose of 400mg/kg, increased MDA level, decreased GST, catalase, and SOD levels in a rat model of paracetamol-induced metabolic and cardiovascular changes. Also, SOD and GSH levels were found to increase while MDA level was found to increase in kidney tissues with paracetamol toxicity (*Canayakin et al., 2016*).

Kamel et al. (2022) documented the increase in the hepatic MDA levels and marked decrease in GSH, SOD, and CAT levels after administration of a single paracetamol dose. *Soliman et al. (2014)* stated that, paracetamol, given in a single dose in a rat model, increased the expression of the Pro-inflammatory chemotactic cytokine, IL-8.

Abdallah et al. (2023) stated that, paracetamol toxicity caused significant changes in oxidative stress markers in the serum (increased malondialdehyde, decreased catalase and decreased total antioxidant capacity). He also documented significant increase in the serum inflammatory markers (increased IL6) and significant damaging effect (increased LDH).

Another recent study showed a significant increase in the tissue level of oxidative markers (4-Hydroxynonenal) accompanied by a significant decrease in the antioxidant markers (Paraoxonase and Catalase). Immunohistochemical study for the nuclear factor-kappa as a marker for inflammatory response showed strong positive expression in hepatocyte nuclei (*Ahmed et al., 2023*).

Long et al. (2020) stated that, paracetamol significantly increased hepatic NF- κ B p65 expression when compared to the control. *Jiang et al. (2021)* concluded that, the phosphorylation of NF- κ B was increased by paracetamol. *Wang et al. (2019)* found out that paracetamol toxicity resulted in high levels of phosphorylated NF- κ B.

Spirulina (1000mg/kg/day), BHT (0.8 mg/kg/day), and Cilostazol (30mg/kg/day) administration, in our current study, ameliorated Paracetamol promoted hepatotoxicity and nephrotoxicity through anti-inflammatory, antioxidant, and anti-apoptotic properties. They induced a substantial diminish in serum liver enzymes, serum urea, creatinine, and BUN indicating improvement of hepatic and renal functions. They also induced a significant decrease in serum MDA and a meaningful upsurge in the levels of hepatic GST, SOD, and catalase in the kidney. They decreased the genetic expression of MAPK, JNK, IL8, NF- κ B1, and BAX.

Many studies recommended that food supplementation rich in antioxidants depresses the lipid peroxidation level (*Makri et al., 2017*). For numerous years, the blue-green alga known as Spirulina plantensis has been ingested by humans due to its nutritional value (*Iwata et al., 1990*).

Studies have revealed that the administration of Spirulina can decrease rats' liver injury in humans through activation of the innate system and augmentation of interferon production (*Hirahashi et al., 2002*). Spirulina is comprised of several active ingredients, such as superoxide dismutase, vitamin E, and B complex vitamins which may be responsible for its protective characteristics (*Becker, 1998*).

Going hand in hand with our study, *El-Naggar et al. (2018)* concluded that, the pre-treatment with *S. platensis* by a dose of 1000 mg/kg alleviated the hepatic and renal toxicity induced by cyclophosphamide. Furthermore, *Bin-Jumah et al. (2021)* confirmed that spirulina, given orally SP by a dose of 500 and 1000 mg/kg orally for 21 days abrogated ALT, AST, ALP, urea, creatinine, and MDA levels with the elevation of GSH, SOD, and CAT in acrylamide-intoxicated rats in a dose dependent manner.

In addition, the protein-bound pigment C-phycoyanin, which is present in Spirulina, hinders renal damage by hindering oxalate-induced lipid peroxidation in a rat model of chloroacetaldehyde and acrolein-induced death of proximal kidney tubules (*Schwerdt et al., 2006*). Additionally, it suppresses

pancreatic cell apoptosis by enhancing the GSH and SOD peroxidase enzymes, which reduces the overproduction of ROS (*Muthuraman et al., 2009*).

Furthermore, *Sadek et al. (2017)* stated that, spirulina by a dose of 500 mg/kg orally twice weekly for 2 months downregulated the MAPK pathway and genetic expression of BAX in hyperglycemic rats with modulation of oxidative stress.

BHT is a man-made derivative of vitamin E and acts comparably to the natural vitamin. This compound transforms into its respective radical form and interrupts the lipid peroxidation process by scavenging the free radicals (*Kanath et al., 2016*). Reactive species are constantly created in healthy cells and are scavenged by intracellular antioxidant enzymes (*Martinez-Cayueta, 1995*).

In this aspect, *Al-Qahtani and Abdulaziz (2019)* exhibited that treatment with different doses of Spirulina (3%, 6% and 9% mixed with diet), and BHT (0.5% mixed with diet) secured rats' livers in contradiction of d-galactosamine provoked hepatotoxicity. The co-administration of different doses of spirulina and BHT decreased the inflammatory markers which were related to the activation of macrophages. They, furthermore, enhanced the liver's antioxidant capacity through SOD, CAT, and GST elevation.

Furthermore, *Dassarmaa et al. (2019)* showed that administration of BHT (0.5 mg/kg) guarded the liver cells against the injurious effects of carbon tetrachloride, helped in restoring the damaged liver tissue, and inhibited the leakage of transaminases into the serum with the abrogation of MDA, AST, and ALT levels. Furthermore, *Fahim et al. (2023)* confirmed that BHT (0.8 mg/kg) diminished BAX expression in a rat model of N-nitroso diethylamine-induced hepatocellular carcinoma.

A common anti-platelet drug used for the treatment of peripheral vascular diseases is cilostazol, a selective phosphodiesterase III (PDE III) inhibitor. In the *El Awdan et al. (2018)* study, the thioacetamide-induced rise in hepatic enzyme levels (AST and ALT), MDA levels, and NF- κ B1 was effectively reduced by administrating cilostazol (50 and

100 mg/kg/day) with an elevation of GSH with preference to higher dose. These findings are consistent with previous research which demonstrated cilostazol's ability to decrease liver enzymes in rats with common bile duct ligation, given in a dose of 9 mg/kg daily for 21 days (*Abdel Kawy, 2015*).

In the same context, *Saeed et al. (2020)* study demonstrated that administration of cilostazol 10 mg/kg diminished urea, creatinine, MDA, IL6, TNF- α levels, NF- κ B1, and BAX expression in amikacin induced-nephrotoxicity with the elevation of GSH, catalase and SOD. Additionally, in dystrophic diaphragm muscle, *Hermes et al. (2016)* found that an oral dose of cilostazol 100 mg/kg for 14 days reduced NF- κ B1 and TNF- α . By suppressing extracellular signal-regulated kinases 1 and 2 (ERK1/2) and c-Jun N-terminal kinase (JNK). Cilostazol can also stop the generation of nitric oxide (NO), prostaglandin E2 (PGE2), cytokines as IL1, and monocyte chemoattractant protein-1 (MCP-1) in lipopolysaccharide-induced murine BV2 microglia (*Jung et al., 2010*).

Furthermore, cilostazol decreases the release of cytochrome c from mitochondria and down-regulates BAX expression via a peroxisome proliferator activator receptor-dependant pathway (*Park et al., 2011*). In the same context, *Wang et al. (2020)* stated that, Cilostazol alleviated nicotine-induced cardiomyocyte hypertrophy through modulation of autophagy by CTSB/ROS/p38MAPK/JNK feedback loop.

In this study, analysis showed histopathological changes in rats' livers bared to paracetamol toxicity including diffusely distributed degenerative changes, primarily micro-vesicular steatosis, unicellular hepatic necrosis, engorged hepatic vasculatures with the presence of minute focal areas of round cell infiltrates and these results are consistent with *El-Bakry et al. (2017)* study. Spirulina can keep partial protection from the toxic effect of paracetamol as the liver showed an area of prominent ballooning degeneration, and this effect may be because spirulina has essential amino acids and the pigments chlorophyll and phycocyanin which aid detoxification (*Eltantawy et al., 2018*).

These results are coherent with *Al-Qahtani et al. (2019)* who studied the protective effects of Spirulina platensis against d-galactosamine-induced hepatotoxicity.

Furthermore, the Paracetamol + BHT group, and the Paracetamol + Spirulina + BHT group showed marked protective effects as there were few numbers of hydropic degenerated cells, while most exhibited normal architecture only. This agrees with *Dassarmaa et al. (2018)* who found that synthetic antioxidants like BHT abated tetrachloride-induced hepatotoxicity. As regards the Paracetamol + cilostazol treated group, there were minute perivascular round cell infiltrates. Histopathologic evidence that cilostazol medication considerably reduced the degree of vascular dilatation and prevented necrosis and congestion backs up this theory. Additionally, our findings are supported by earlier research that suggests cilostazol has some anti-inflammatory properties (*Abdel Kawy, 2015; Hermes et al., 2016; Jung et al., 2010; Park et al., 2011; Wang et al., 2020*).

The histopathology of the kidneys of the paracetamol-treated group displayed coagulative necrosis of some renal tubular epithelium with pyknotic nuclei, atrophied glomerular tufts, and interstitial inflammatory cell aggregates. Also, dilated renal capillaries, and eosinophilic hyaline cast within some tubular lumina are like *Canayakin et al. (2016)*. The prostaglandin production pathway, the cytochrome P-450 pathway, and N-deacetylase enzymes are examples of possible nephrotoxic pathways (*Bassem and Vermeulen, 2001*). The administration of Spirulina significantly reduced the toxic effects of paracetamol on the kidneys, and this could be related to the property of free radical scavenging (*de Conti et al., 2015*). Spirulina's antioxidant qualities probably offered considerable defense and repaired the liver's and kidney's altered tissue architecture, demonstrating its effectiveness in repairing damage caused by paracetamol. Because antioxidants, whether synthetic or natural, act as scavenging molecules against ROS, slow down the pace of lipid peroxidation and MDA generation, and eventually serve as protective agents, BHT can have protective effects

(*Kanath et al., 2016*). So, there is marked improvement in renal tissues was noticed in groups treated with BHT.

Due to its control over the cell cycle and apoptosis, P53 has an anti-cancer effect. The "guardian of the genome" is a term that refers to its significant function as a tumor suppressor (*Kandoth et al., 2013*). Several target genes are transactivated by p53. One of these, called p21, is essential for cell-cycle arrest and the activation of apoptosis in response to stress (*Barboza et al., 2006*). When a stress signal reaches p53, mechanisms that control protein stability, coactivator and inhibitor recruitment, and posttranslational modifications like acetylation, methylation, phosphorylation, ubiquitination, sumoylation, and neddylation 3 are used to fine-tune the protein's activity.

Target genes and microRNAs involved in cellular processes such as cell growth arrest, apoptosis, autophagy, ferroptosis, senescence, aging, and metabolism, especially the maintenance of oxidative balance, are transcriptionally induced by activated p5 (*Kaiser and Attardi, 2018*).

P53 marker can be utilized to assess the rate of apoptosis (*Kandoth et al., 2013*). In the existing experiment, paracetamol considerably upregulated the P53 immunoexpression in the hepatic and renal tissues contrary to the control. Spirulina, BHT, and cilostazol groups signifying that P53 substantially elevated the apoptotic index in Paracetamol-treated rats. Typically, the activation of p53 acts as a cytotoxic pro-death signal and these results are in line with earlier studies done on animals (*Huo et al., 2017*). The hepatotoxicity of APAP is significantly influenced by oxidative stress, which can activate the p53 gene. The immunoexpression of P53 was downregulated by both spirulina and BHT co-administration with paracetamol, indicating a greater replicative and protective function. This may be related to cellular regeneration (regenerative proliferation). Additionally, cilostazol boosted cell regeneration and reduced cellular damage when provided with paracetamol (*da Motta and de Brito, 2016*). Additionally, Cilostazol suppressed the CYP-induced up-regulation of p53 in a rat model of

cyclophosphamide -induced cardiotoxicity (*Elrashidy and Hasan, 2021*).

Regarding applicability to humans, Spirulina, even at higher doses, is documented to be safe unless contaminated. In *Al-Dhabi, (2013)* study, the heavy metals in 25 marketed Spirulina were quantified and showed that the contents of Ni, Zn, Hg, Pt, Mg and Mn in were all within the daily intake levels. Butylated hydroxytoluene (BHT) is widely used as an antioxidant food additive. Many studies were done to evaluate their potential toxicity.

Experimental studies on BHT documented its reproductive toxicity and carcinogenicity but regarding human, there was no cancer hazard but instead, it is documented to be anticarcinogenic as food additive (*Williams et al., 1999*). According to Scientific Committee on Consumer Safety (SCCS), BHT is considered safe for use as a mouthwash at a concentration of 0.001%, toothpaste at a concentration of 0.1% and other rinse off products at the concentration of 0.8% (*SCCS, 2021*).

Cilostazol was approved by the US Food and Drug Administration (FDA) in 1999 for intermittent claudication (*Miller, 1999*). Recent guidelines recommended the addition of cilostazol (200 mg once daily) for protection against stroke, either as a combined therapy with aspirin or clopidogrel or as monotherapy. Cilostazol was shown to be neuroprotective without increasing the bleeding risk (*Mikhailidis et al., 2022*).

CONCLUSION

Hepatotoxicity and nephrotoxicity caused by Paracetamol can be ameliorated by the combined administration of Spirulina, BHT and cilostazol for 7 days through antioxidant, anti-inflammatory, and anti-apoptotic impacts which was evidenced by the high improvement of the kidney functions, liver functions, oxidative stress markers, inflammatory markers, and histopathological findings. The results of the use of spirulina and BHT together for protection in this combined therapy were better than the use of every drug alone. Further studies are recommended to evaluate the use of this combined therapy for prolonged periods and

clinical trials are needed to evaluate its use on humans.

Author contributions:

All authors wrote, prepared the original draft, shared in methodology and investigations, and approved the manuscript. All data was generated in-house, and no paper mill was used.

Ethical Statement:

The study plan received approval from the Zagazig University's Ethics Committee for Animal Experimental Research (ZU-IACUC/3/F/32/2021) and the study followed the National Institutes of Health's guidelines for the proper care and use of laboratory animals (NIH Publications "No.8023, revised 1996"). The experimental methods adhered to the recommendations outlined in the ARRIVE guidelines.

Conflict of interest:

There is no conflict of interest.

Funding:

No fund was received.

Consent to publish:

All authors revised and approved the final manuscript for approval.

Availability of data and material:

The data that support the findings of this study are available from the corresponding author upon request.

REFERENCES

1. **Abdallah, A. A. M.; Bafail, R.; Zaman, A.Y.; et al. (2023):** Acute paracetamol toxicity-induced inflammatory and oxidative effects are relieved by Aleppo galls: a novel experimental study. *Int. J. Physiol. Pathophysiol. Pharmacol.*, 15(1):1-11.
2. **Abdel Kawy, H. S. (2015):** Cilostazol attenuates cholestatic liver injury and its complications in common bile duct ligated rats. *Eur. J. Pharmacol.*, 752: 8–17.
3. **Aebi, H. (1984):** Catalase in vitro. *Methods Enzymol.*, 105: 121-126.
4. **Ahmed, H. M.; Shehata, H.; El-Saeed, G. S.; et al. (2023):** Paracetamol Overdose Induces Acute Liver Injury accompanied by oxidative stress and inflammation Egypt. *J. Chem.*, 66: (3): 399 – 408.
5. **Akhter, M. S.; Uddin, M. A. and Barabutis, N. (2019):** Unfolded protein response regulates P53 expression in the pulmonary endothelium. *J. Biochem. Molec. Toxicol.*, 33(10): 1-5.
6. **Al-Dhabi, N. A. (2013):** Heavy metal analysis in commercial Spirulina products for human consumption. *Saudi J. Biol. Sci.*, 20 (4):383-388.
7. **Al-Qahtani, W. H. and Abdulaziz, M. (2019):** Anti-inflammatory, antioxidant and antihepatotoxic effects of Spirulina platensis against D-galactosamine induced hepatotoxicity in rats. *Saudi J. Biol. Sci.*, 26: 647–652.
8. **Al-Qahtani, W. H. and Binobeid, M. A. (2019):** Anti-inflammatory, antioxidant and antihepatotoxic effects of Spirulina platensis against d-galactosamine induced hepatotoxicity in rats. *Saudi J. Biol. Sci.*, 26(4): 647-652.
9. **Ansari, N. H. and Rajaraman, S. (1992):** Allopurinol-induced nephrotoxicity: protection by the antioxidant, butylated hydroxytoluene. *Res. Commun. Chem. Pathol. Pharmacol.*, 75(2):221-229.
10. **Ayres, J. C.; Paes Porto, H. K.; Junior, J. B.; et al. (2020):** Paracetamol-induced metabolic and cardiovascular changes are prevented by exercise training. *Basic Clin. Pharmacol. Toxicol.*, 127(6), 516-524.
11. **Bairwa, N. K.; Sethiya, and Mishra, S. (2010):** Protective effect of stem bark of Ceiba pentandra against paracetamol-induced hepatotoxicity in rats. *Pharm. Res.*, 2: 26–30.
12. **Baponwa, O.; Amang, A. P.; Mezui, C.; et al. (2022):** Antioxidant Mechanism of Renal and Hepatic Failure Prevention Related to Paracetamol Overdose by the Aqueous Extract of Amblygonocarpus andongensis Stem Bark. *Biomed. Res. Int.*, 1846558.
13. **Barboza, J. A.; Liu, G.; Ju, Z.; et al. (2006):** p21 delays tumor onset by preservation of chromosomal stability. *Proc. Natl. Acad. Sci. U S A.*, 103(52): 19842-1987.
14. **Becker, E. W. (1988):** Microalgae. In: Nutrition. Cambridge: Cambridge University, 196–249.
15. **Bessemis, J. G. and Vermeulen, N. P. (2001):** Paracetamol (acetaminophen)-induced toxicity: molecular and biochemical mechanisms, analogues, and protective approaches. *Crit. Rev. Toxicol.*, 31: 55–138.
16. **Bin-Jumah, M. N.; Al-Huqail, A. A.; Abdelnaeim, N.; et al. (2021):** Potential protective effects of Spirulina platensis on liver, kidney, and brain acrylamide toxicity in rats. *Environ. Sci. Pollut. Res. Int.*, 28(21): 26653-26663.

17. **Blantz, R. C. (1996):** Acetaminophen: Acute and chronic effects on renal function. *Am. J. Kidney Dis.*, 28: S3–S6.
18. **Britza, S. M.; Musgravea, I. F. and Byard, R. W. (2020):** Paracetamol (acetaminophen) hepatotoxicity increases in the presence of an added herbal compound. *Legal Med.*, 47: 101740.
19. **Brunt, E. M; Janney, C. G.; Di Bisceglie, A. M.; et al. (1999):** R. Nonalcoholic steatohepatitis: a proposal for grading and staging the histological lesions. *Am. J. Gastroenterol.*, 94: 2467–2474.
20. **Bunchorntavakul, C. and Reddy, K. R. (2018):** Acetaminophen (APAP or N-acetyl-p-aminophenol) and acute liver failure. *Clin. Liver Dis.*, 22(2): 325–346.
21. **Canayakin, D.; Bayir, Y.; Baygutalp, N. K.; et al. (2016):** Paracetamol-induced nephrotoxicity and oxidative stress in rats: the protective role of *Nigella sativa*. *Pharmaceut. Biol.*, 54 (10): 2082–2091.
22. **Chinnappan, S. M.; George, A.; Thaggikuppe, P.; et al. (2019):** Nephroprotective Effect of Herbal Extract *Eurycoma longifolia* on Paracetamol-Induced Nephrotoxicity in Rats. *Evid. Based Complement Alternat. Med.*, 13: 4916519.
23. **Chun, L. J.; Tong, M. J.; Busuttill, R. W.; et al. (2009):** Acetaminophen hepatotoxicity and acute liver failure. *J. Clin. Gastroenterol.*, 43: 342–349.
24. **Cichoż-Lach, H. and Michalak, A. (2014):** Oxidative stress as a crucial factor in liver diseases. *World J. Gastroenterol.*, 20: 8082.
25. **Coen, M. (2014):** Metabolic phenotyping applied to pre-clinical and clinical studies of acetaminophen metabolism and hepatotoxicity. *Drug Metab. Rev.*, 23: 1–16.
26. **da Motta, N. A. and de Brito, F. C. (2016):** Cilostazol exerts antiplatelet and anti-inflammatory effects through AMPK activation and NF-κB inhibition on hypercholesterolemic rats. *Fundam. Clin. Pharmacol.*, 30(4): 327–337.
27. **Dassarmaa, B.; Nandib, D.K.; Gangopadhyay, S. et al. (2018):** Hepatoprotective effect of food preservatives (butylated hydroxyanisole, butylated hydroxytoluene) on carbon tetrachloride-induced hepatotoxicity in rat. *Toxicol. Reports*, 5: 31–37.
28. **de Conti, A.; Kobets, T.; Tryndyak, V.; et al. (2015):** Persistence of furan-induced epigenetic aberrations in the livers of F344 rats. *Toxicol. Sci.*, 144: 217–222.
29. **El-Aaser, A. A. and El-Merzabani, M. M. (1975):** Simultaneous determination of 5'-nucleotidase and alkaline phosphatase activities in serum. *Z. Klin Chem. Klin Biochem.*, 13(10): 453.
30. **El Awdan, S. A.; Amin, M. M. and Hassan, A. (2018):** Cilostazol attenuates indices of liver damage induced by thioacetamide in albino rats through regulating inflammatory cytokines and apoptotic biomarkers. *Eur. J. Pharmacol.* 822: 168–176.
31. **El-Bakry, H. A.; El-Sherif, G. and Rostom, R. M. (2017):** Therapeutic dose of green tea extract provokes liver damage and exacerbates paracetamol-induced hepatotoxicity in rats through oxidative stress and caspase 3-dependent apoptosis. *Biomed. Pharmacother.*, 96: 798–811.
32. **El-Hassan, H.; Anwar, K.; Macanas-Pirard, P.; et al. (2003):** Involvement of mitochondria in acetaminophen-induced apoptosis and hepatic injury: roles of cytochrome c, Bax, Bid, and caspases. *Toxicol. Appl. Pharmacol.*, 191: 118–129.
33. **El-Naggar, S. A.; Ibrahim, M. A.; El-Tantawi, H.G.; et al. (2018):** Pretreatment with the Micro-alga, *Spirulina Platensis* Ameliorates Cyclophosphamide -Induced Hematological, Liver and Kidney Toxicities in Male Mice. *Ain Shams J. Forensic Med. Clin. Toxicol.*, 30: 1–7.
34. **Elrashidy, R. A. and Hasan, R. A. (2021):** Cilostazol preconditioning alleviates cyclophosphamide-induced cardiotoxicity in male rats: Mechanistic insights into SIRT1 signaling pathway. *Life Sci.*, 266: 118822.
35. **Eltantawy, F. M.; Ali Sobh, M. A.; EL-Waseef, A. M.; et al. (2018):** Protective effect of *Spirulina* against cyclophosphamide-induced urotoxicity in mice. *Egypt. J. Basic App. Sci.*, 5: 191–196.
36. **Fahim, S. A.; Ibrahim, S.; Tadros, S. A.; et al. (2023):** Protective effects of butylated hydroxytoluene on the initiation of N-nitrosodiethylamine-induced hepatocellular carcinoma in albino rats. *Hum. Exp. Toxicol.*, 42: 9603271231165664.
37. **Fujii, T.; Obara, H.; Matsubara, K.; et al. (2017):** Oral administration of cilostazol improves survival rate after rat liver ischemia/reperfusion injury. *J. Surg. Res.*, 213: 207–214.
38. **Halliwell, B. and Gutteridge, J. M. (1984):** Oxygen toxicity, oxygen radicals, transition metals and disease. *Biochem. J.*, 219: 1–14.

39. **Henrich, W. L. (1998):** Analgesic nephropathy. *Trans. Am. Clin. Climatol. Assoc.*, 109: 147–158.
40. **Hermes, T. A.; Macedo, A. B.; Foga, A. R.; et al. (2016):** Beneficial cilostazol therapeutic effects in mdx dystrophic skeletal muscle. *Clin. Exp. Pharmacol. Physiol.*, 43(2): 259–67.
41. **Hinson, J. A.; Roberts, D. W. and James, L. P. (2010):** Mechanisms of acetaminophen-induced liver necrosis. *Handb. Exp. Pharmacol.*, 196:369-405.
42. **Hirahashi, T.; Matsumoto, M.; Hazeki, K.; et al. (2002):** Activation of the human innate immune system by Spirulina: augmentation of interferon production and NK cytotoxicity by oral administration of hot water extract of *Spirulina platensis*. *Int. Immunopharmacol.*, 2 (4): 423–434.
43. **Hsu, S. M.; Raine, L. and Fanger, H. (1981):** Use of avidin-biotin-peroxidase complex (ABC) in immunoperoxidase techniques: a comparison between ABC and unlabeled antibody (PAP) procedures. *J. Histochem. Cytochem.*, 29(4): 577–580.
44. **Huo, Y.; Yin, S.; Yan, M.; et al. (2017):** Protective role of p53 in acetaminophen hepatotoxicity. *Free Radic. Biol. Med.*, 106:111-117.
45. **Iwata, K.; Inayama, T. and Kato, T. (1990):** Effects of *Spirulina platensis* on plasma lipoprotein lipase activity in fructose-induced hyperlipidemic rats. *J. Nutr. Sci. Vitaminol.* 36 (2): 165–171.
46. **Jiang, W. P.; Deng, J. S.; Huang, S. S.; et al. (2021):** Sanghuangporussanghuang Mycelium Prevents Paracetamol-Induced Hepatotoxicity through Regulating the MAPK/NF- κ B, Keap1/Nrf2/HO1, TLR4/PI3K/Akt, and CaMKK β /LKB1/AMPK Pathways and Suppressing Oxidative Stress and Inflammation. *Antiox.*, (Basel, Switzerland), 10(6): 897.
47. **Jung, W. K.; Lee, D. Y.; Park, C.; et al. (2010):** Cilostazol is anti-inflammatory in BV2 microglial cells by inactivating nuclear factor-kappa and inhibiting mitogen-activated protein kinases. *British J. Pharmacol.*, 159(6): 1274–1285.
48. **Kabil, S. L. (2018):** Beneficial effects of cilostazol on liver injury induced by common bile duct ligation in rats: Role of SIRT1 signaling pathway. *Clin. Exp. Pharmacol. Physiol.*, 45(12):1341-1350.
49. **Kafantaris, I.; Stagos, D.; Kotsampasi, B.; et al. (2018):** Grape pomace improves performance, antioxidant status, fecal microbiota, and meat quality of piglets. *Animal*, 12(2): 246-255.
50. **Kaiser, A. M. and Attardi, L. D. (2018):** Deconstructing networks of p53-mediated tumor suppression in vivo. *Cell Death Different.*, 25: 93.
51. **Kamel, M. G. A.; Harahsheh, E.; Hussein, S. (2022):** Diacerein ameliorates acetaminophen hepatotoxicity in rats via inhibiting HMGB1/TLR4/NF- κ B and upregulating PPAR- γ signal. *Mol Biol Rep* 49: 5863–5874.
52. **Kanath, M. K.; Kumari, A.; He, F.; et al. (2016):** An orally bioavailable glutathione based hepatoprotective compound in experimental acute liver injury: More effective than silymarin and YHK. *J. Gastrointest. Diag. Syst.*, 6 (4): 462.
53. **Kandath, C.; McLellan, M. D.; Vandin, F.; et al. (2013):** Mutational landscape and significance across 12 major cancer types. *Nature.*, 502: 333.
54. **Khalila, S. R.; Salemb, H. F.; Metwally, M. M.; et al. (2020):** Protective effect of *Spirulina platensis* against physiological, ultrastructural and cell proliferation damage induced by furan in kidney and liver of rat. *Ecotoxicol. Environ. Safety*, 192: 110256.
55. **Lancaster, E. M.; Hiatt, J. R. and Zarrinpar, A. (2015):** Acetaminophen hepatotoxicity: an updated review. *Arch. Toxicol.*, 89 (2): 193–199.
56. **Lee, Y. J.; Shu, M.; Kim, J.; et al. (2019):** Cilostazol protects hepatocytes against alcohol-induced apoptosis via activation of AMPK pathway. *PLOS ONE*, 14(1): e0211415.
57. **Liu, F. C.; Yu, H. P.; Chou, A. H.; et al. (2020):** Corilagin reduces acetaminophen-induced hepatotoxicity through MAPK and NF- κ B signaling pathway in a mouse model. *Am. J. Transl. Res.* 12(9): 5597-5607.
58. **Livak, K. J. and Schmittgen, T. D. (2001):** Analysis of relative gene expression data using real-time quantitative PCR and the 2- $\Delta\Delta$ CT Method. *Methods*, 25(4): 402-408.
59. **Long, X.; Song, J.; Zhao, X.; et al. (2020):** Silkworm pupa oil attenuates acetaminophen-induced acute liver injury by inhibiting oxidative stress-mediated NF- κ B signaling. *Food Sci. Nutr.*, 8(1), 237-245.
60. **Makri, S.; Kafantaris, I.; Stagos, D.; et al. (2017):** Novel feed including bioactive compounds from winery wastes improved broilers' redox. Status in blood and tissues of vital organs. *Food Chem. Toxicol.*, 102: 24–31.

61. **Manolis, A. A.; Manolis, T.A.; Melita, H.; et al. (2022):** Update on Cilostazol: A Critical Review of Its Antithrombotic and Cardiovascular Actions and Its Clinical Applications. *J. Clin. Pharmacol.*, 62(3):320-358.
62. **Marklund, S. and Marklund, G. (1974):** Involvement of the Superoxide Anion Radical in the Autoxidation of Pyrogallol and a Convenient Assay for Superoxide Dismutase. *Eur. J. Biochem.*, 47, 469-474.
63. **Martinez-Cayuella, M. (1995):** Oxygen free radicals and human disease. *Biochim.*, 77: 147-161.
64. **Mayne, P. D. (1994):** The kidneys and renal calculi. In: Clinical chemistry in diagnosis and treatment. 6th edition. London: Edward Arnold Publications, pp.2-24.
65. **Miller J. L. (1999):** Cilostazol approved for use in intermittent claudication. *Am. J. Health Syst. Pharm.*; 56: 404.
66. **Moss, D. W. (1982):** Alkaline phosphatase isoenzymes. *Clin. Chem.*, 28(10): 2007-2016.
67. **Muthuraman, P.; Senthilkumar, R. and Srikumar, K. (2009):** Alterations in beta islets of langerhans in alloxan-induced diabetic rats by marine Spirulina platensis. *J. Enzyme Inhib. Med. Chem.*, 24(6):1253-1256.
68. **Nakata, H.; Nakayama, S. M.; Kataba, A.; et al. (2021):** Evaluation of the ameliorative effect of Spirulina (Arthrospira platensis) supplementation on parameters relating to lead poisoning and obesity in C57BL/6J mice. *J.Func.Foods*, 77: 104344.
69. **Ohkawa, H.; Ohishi, W. and Yagi, K. (1979):** Assay for lipid peroxides in animal tissues by thiobarbituric acid reaction. *Anal. Biochem.*, 95: 351.
70. **Park, S. Y.; Bae, J. U.; Hong, K. W. et al. (2011):** HO-1 induced by cilostazol protects against TNF- α -associated cytotoxicity via a PPAR- γ -dependent pathway in human endothelial cells. *Korean J. Physiol. Pharmacol.*, 15(2): 83-88.
71. **Patterson, J. W. and Lazarow, A. (1955):** Determination of glutathione. *Methods Biochem. Anal.*, 2: 259-278.
72. **Prescott, L. F.; Speirs, G. C.; Critchley, J. A. et al. (1989):** Paracetamol disposition and metabolite kinetics in patients with chronic renal failure. *Eur. J. Clin. Pharmacol.* 36: 291-297.
73. **Rang, H. D.; Dale, M. M.; Ritter, J. M.; et al. (2020):** Rang and Dale's Pharmacology. 9th Edition. Elsevier.
74. **Sadek, K. M.; Lebda, M. A.; Nasr, S. M. et al. (2017):** Spirulina platensis prevents hyperglycemia in rats by modulating gluconeogenesis and apoptosis via modification of oxidative stress and MAPK-pathways. *Biomed. Pharmacother.*, 92: 1085-1094.
75. **Saeed, Z. M.; Khatlab, M. I.; Khorshid, N. E. et al. (2020):** Ellagic acid and cilostazol ameliorate amikacin-induced nephrotoxicity in rats by downregulating oxidative stress, inflammation, and apoptosis. *PLOS ONE*, 17(7): e0271591.
76. **Saggi, S. and Kumar, R. (2008):** Effect of sea buckthorn leaf extracts on circulating energy fuels, lipid peroxidation and antioxidant parameters in rats during exposure to cold, hypoxia and restraint (C-H-R) stress and post stress recovery. *Phytomed.*, 15:437-446.
77. **Scientific Committee on Consumer Safety (SCCS) (2021):** Scientific opinion on Butylated hydroxytoluene (BHT), SCCS/1636/21
78. **Schwerdt, G.; Gordjani, N. and Benesic, A. (2006):** Chloro-acetaldehyde and acrolein-induced death of human proximal tubule cells. *Pediatr. Nephrol.*, 21(1): 60-67.
79. **Sener, G.; Sehirli, A. O. and Ayanoglu-Dülger, G. (2003):** Protective effects of melatonin, vitamin E and N-acetylcysteine against acetaminophen toxicity in mice. A comparative study. *J. Pineal. Res.*, 35: 61-68.
80. **Soliman, M. M.; Abdo Nassan, M. and Ismail, T. A. (2014):** Immunohistochemical and molecular study on the protective effect of curcumin against hepatic toxicity induced by paracetamol in Wistar rats. *BMC Complement. Altern. Med.*, 29 (14):457.
81. **Sorg, D. A. and Buckner, B. A. (1964):** Simple method of obtaining venous blood from small laboratory animals. *Proc. Soc. Exp. Biol. Med.*, 115: 1131-1132.
82. **Sun, Y.; Oberley, L. W. and Li, Y. (1988):** A simple method for clinical assay of superoxide dismutase. *Clin. Chem.*, 34(3): 497-500.
83. **Suvarana, S. K.; Layton, C. and Bancroft, J. D. (2018):** Bancroft's theory and practice of Histological techniques. 8th edition. Churchill Livingstone. Elsevier, England.
84. **Tabacco, A.; Meiattini, F.; Moda, E. et al. (1979):** Simplified enzymic/colorimetric serum urea nitrogen determination. *Clin. Chem.*, 25(2): 336-337.
85. **Tumper, L.; Monasterolo, L. A. and Elias, M. M. (1998):** Probenecide protects against in vivo acetaminophen-induced nephrotoxicity

- in male wistar rats. *J. Pharm. Exp. Ther.*, 248:606-610.
86. **Wang, Z.; Hao, W.; Hu, J.; et al. (2019):** Maltol Improves APAP-Induced Hepatotoxicity by Inhibiting Oxidative Stress and Inflammation Response via NF- κ B and PI3K/Akt Signal Pathways. *Antiox.*, 8(9): 395.
87. **Wang, S. Y.; Ni, X.; Hu, K. Q.; et al. (2020):** Cilostazol alleviate nicotine induced cardiomyocytes hypertrophy through modulation of autophagy by CTSB/ROS/p38MAPK/JNK feedback loop. *Int. J. Biol. Sci.*, 16(11):2001-2013.
88. **Williams, G. M.; Iatropoulos M. J. and Whysner, J. (1999):** Safety Assessment of Butylated Hydroxyanisole and Butylated Hydroxytoluene as Antioxidant Food Additives. *Food Chem. Toxicol.*, 37: (9-10): 1027-1038
89. **Yoon, E.; Babar, A.; Choudhary, M. et al. (2016):** Pysopoulos, Acetaminophen-induced hepatotoxicity: a comprehensive update. *J. Clin. Transl. Hepatol.*, 4: 131-142.
90. **Young, D. (1995):** Effects of drugs on clinical lab. Tests. 4th ed. AACCC Press.
91. **Yousef, M. I.; Omar, S. A.; El-Guendi, M. I. et al. (2010):** Potential protective effects of quercetin and curcumin on paracetamol-induced histological changes, oxidative stress, impaired liver, and kidney functions and haematotoxicity in rat. *Food Chem. Toxicol.*, 48:3246-3261.