

DOES CBCT PROVIDE AN ACCURATE METHOD FOR ASSESSMENT OF THE SOFT TISSUE THICKNESS AROUND IMMEDIATE IMPLANTS IN THE ESTHETIC ZONE? A RETROSPECTIVE COHORT STUDY

Sarah Moussa* , Ramy Mubarak*  and Sherif Amer* 

ABSTRACT

Objective: To assess cone-beam computerized tomography (CBCT) accuracy in measuring the facial soft tissue thickness around immediate implants before and after connective tissue grafting.

Methods: 20 patients received immediate implants and connective tissue grafts in the esthetic zone. Facial soft tissue thickness was evaluated at 2mm, 4mm and 6mm from free gingival margin by bone sounding using endodontic file with silicone stopper and digital caliper and by CBCT after putting lip retractor.

Results: Paired t test showed a significant difference between base line and 6 months follow up readings in both methods. No significant difference was reported between both methods. On the other hand, Pearson correlation coefficient showed an inverse correlation between both methods.

Conclusion: CBCT provided noninvasive, accurate and reliable data for measuring the facial soft tissue thickness and can be used for the analysis and planning of immediate implants placement in the esthetic zone.

Clinical significance: Using CBCT in soft tissue assessment at the time of implant/bone evaluation can aid in saving the clinician and patient time and prevents the painful invasive bone sounding process.

KEYWORDS: CBCT, esthetic zone, direct bone sounding, soft tissue thickness

INTRODUCTION

The key to successful immediate implant placement (IIP) is evaluating the prospects of the surrounding soft tissues and the primary alveolar crest gingival thickness has a significant impact

on the stability of the marginal bone around dental implants. During the 1st year of function, crestal bone loss of up to 1.45mm will occur if the tissue thickness was ≤ 2.5 mm, regardless of a supracrestal location of the implant–abutment interface ⁽¹⁾.

* Lecturer of Oral Medicine, Periodontology, and Diagnosis, Faculty of Oral and Dental Medicine, Future University Cairo, Egypt.

Since labial/buccal gingival recession is frequent following immediate tooth replacement^(2,3), implant placement with simultaneous soft tissue grafting may possibly minimize the facial gingival recession. Autogenic soft tissue grafts are used broadly to boost tissue volume and width of keratinized gingiva, in addition to enhancing the aesthetic outcomes⁽⁴⁾. In addition, studies have reported that mucosal recession was less significant when associated with a thick mucosa, compared to a thin mucosa⁽⁵⁾.

The use of the connective tissue graft (CTG) was suggested to partly preserve hard tissues and thickens the peri-implant mucosa leading to improvement of the esthetic outcomes⁽⁶⁾. Moreover, applying CTG has been anticipated to compensate for ridge resorption following tooth extraction and IIP⁽⁷⁾ and therefore improving the esthetic outcomes⁽⁸⁻¹⁰⁾.

Bucco-palatal soft tissue thickness is considered a key aspect of the gingival biotype, and a vital factor in determining the long term stability of the soft tissue that can significantly affect the final esthetic outcome of the implant therapy⁽¹¹⁾.

Knowing the soft tissue thickness is imperative especially in cases of thin tissue biotype that is considered as a major hazard for progressive mid-buccal recession in IIP^(12,13). Therefore multiple methods for soft tissue thickness measurements have been suggested and classified into invasive and noninvasive⁽¹⁴⁾. The invasive methods comprise histological sections⁽¹⁵⁾ and direct bone sounding (DBS) via an endodontic reamer, a periodontal probe, or an injection needle following local anesthesia⁽¹⁶⁻¹⁹⁾. Noninvasive methods such as ultrasound devices⁽²⁰⁻²²⁾ and cone-beam computed tomography (CBCT)⁽²³⁻²⁵⁾ have been developed for measuring soft tissue thickness.

Though CBCT was primarily used for imaging hard maxillofacial tissues, in the past years it was utilized to examine facial soft tissues and was proved to be a noninvasive and a precise technique for soft maxillofacial tissue imaging⁽²⁶⁻²⁹⁾. However, the major drawback of CBCT soft tissue measurements is the presence of neighboring soft tissues that

interfere with gingival tissue imaging. Aiming to overcome this disadvantage, wooden spatulas or acrylic lip retractors may be used to retract lip and cheek tissues to allow and improve the visibility of gingival soft tissues during CBCT imaging⁽³⁰⁻³³⁾.

Despite that multiple studies were conducted to evaluate and measure the oral soft tissue thickness using CBCT^(28,29, 34-38), only few studies assessed the accuracy of CBCT in measuring the soft tissue thickness^(26,39) and none of them was applied on IIP cases with soft tissue grafting in the esthetic zone. Hence, this retrospective study was aimed to estimate and assess the accuracy of CBCT compared to direct bone sounding in measuring the facial soft tissue thickness pre and post IIP and CTG placement.

MATERIAL AND METHODS

This retrospective research was performed on 20 patients who had received immediate implants in the faculty of oral and dental medicine, Future University in Egypt, between June 2015 and December 2019.

The inclusion criteria were immediately inserted implants in the maxillary esthetic zone that were placed in EDS-1 extraction sockets, flapless procedure, patients who didn't experience periodontal disease or gingival recession two teeth to right and left of the implant, and a pre and 6 months post-treatment CBCT of the maxilla.

Exclusion criteria included patients on medications that could cause gingival hyperplasia, patients with bleeding disorders or on anticoagulant therapy, history of head and neck radiation therapy, patients with parafunctional habits such as bruxism or clenching, in addition to smokers and alcoholics. This study was permitted by the Ethical Committee of Faculty of Oral and dental medicine, Future University in Egypt (FUE.REC (16)/4-2023).

Surgical procedures:

- After administration of local anesthesia, the teeth were extracted atraumatically using

periotomes and forceps. Careful curettage and alveolar cleaning were followed to remove any trace of infected or granulated tissue together with remains of the periodontal ligament. The sockets were then irrigated with saline for 30 seconds and the integrity of the socket walls was verified by a periodontal probe.

- The CTG was obtained by using the single-incision palatal harvest technique ⁽⁴⁰⁾ where; Following administration of local anesthesia, A single incision was made to the bone in a horizontal direction nearly 2 to 3 mm apical to the palatal gingival margin of the maxillary teeth. The incision length was set based on the extents of the required graft. A partial-thickness separation was then completed within the single incision, leaving an adequate thickness of intact palatal flap to diminish the chance of the overlying tissue sloughing. The dissection was made apically as far as required to acquire the desired extents then cautiously elevated from the palate using a small Molt or Buser elevator. Primary closure was attained by means of 5.0 chromic gut suture.
- Healing abutments were screwed following implant placement, and a full-thickness envelope flap was created between the gingiva and the facial bone plate. The connective tissue grafts were introduced into the prepared envelope and secured with 5.0 chromic gut suture.

Post –Surgical Instructions

Patients were instructed to use antibiotics (Augmentin 1 gram, b.i.d for 5 days) and analgesics (Ibuprofen) tablets to avoid the possibility of postsurgical pain and infection. Participants were advised to rinse with 0.1% chlorohexidine gluconate solution (b.i.d) and to avoid brushing the area of the surgery and to keep on soft diet for 2 weeks following the surgery.

Prosthetic phase :

Following a healing period of 3 months, a screw-retained transfer coping was connected to the implant and impressions were taken. The final restorations were then checked for shade matching, marginal fitness and occlusion then cemented using calcium hydroxide cement.

Clinical evaluation:

Direct bone sounding (DBS) used for measuring the facial soft tissue thickness (STT) using an endodontic file with stopper, which was placed horizontally, perpendicular to the long axis of the tooth to be extracted, at 2, 4 and 6 mm from the free gingival margin (FGM). After 6 months the same procedure was done to measure the facial STT at the same measurement points perpendicular to the long axis of the inserted dental implant. A digital caliper with fine pointed jaws was utilized to measure the distance from the endodontic file tip to the stopper (Figure 1).

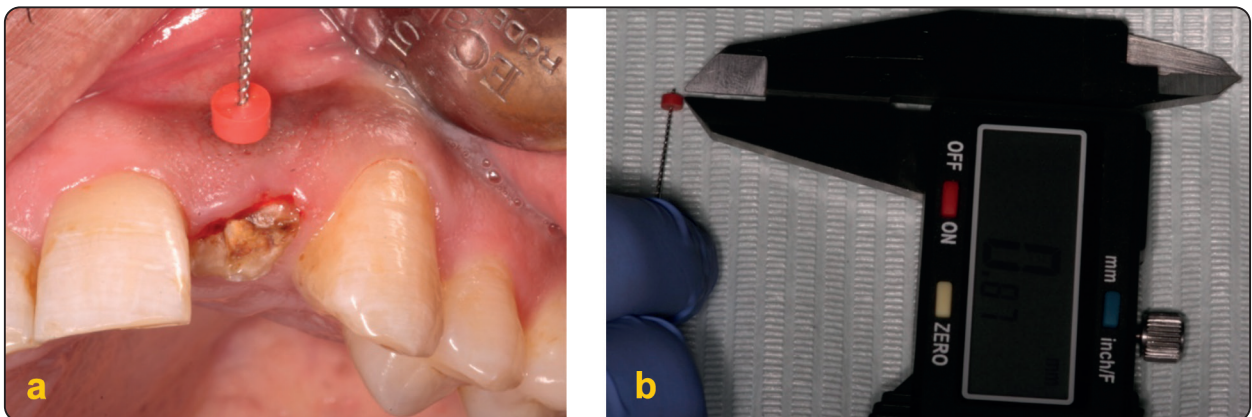


Fig. (1) (a) measuring soft tissue thickness via bone sounding using endodontic file with silicone stopper. (b) Digital caliper was used to accurately read the measurements.

CBCT imaging and analysis:

CBCT images of the 20 participants were attained via VATECH PAX I 3D green CBCT unit (Vatech, south korea). Exposure was achieved at 90 kVp, 8 mA, and a 0.3 mm voxel size using 80×80 mm limited FOV for 18 s as recommended by the manufacturer. Lip retractor (Angle Wider, Swedish Dental Supplies AB, AKARP, Sweden) was used for soft tissue imaging. For each surgical site the gingival thickness was measured perpendicular to the alveolar process at 2 mm, 4mm and 6 mm from the FGM, following 6 months of IIP, facial STT measurements were accomplished at the same

three different points from the free mucosal margin (FMM) (Figure 2).

Statistical analyses:

Statistical analyses were achieved using Statistical Package for Social Sciences (IBM SPSS Statistics version 26). Numerical variables were stated by mean, standard deviation (SD) and range, via the independent t-test, paired t-test, and Pearson correlation (r). Significant difference of P value <0.05 was expressed as (*) while highly significant difference of P-value <0.001 was expressed as (**).

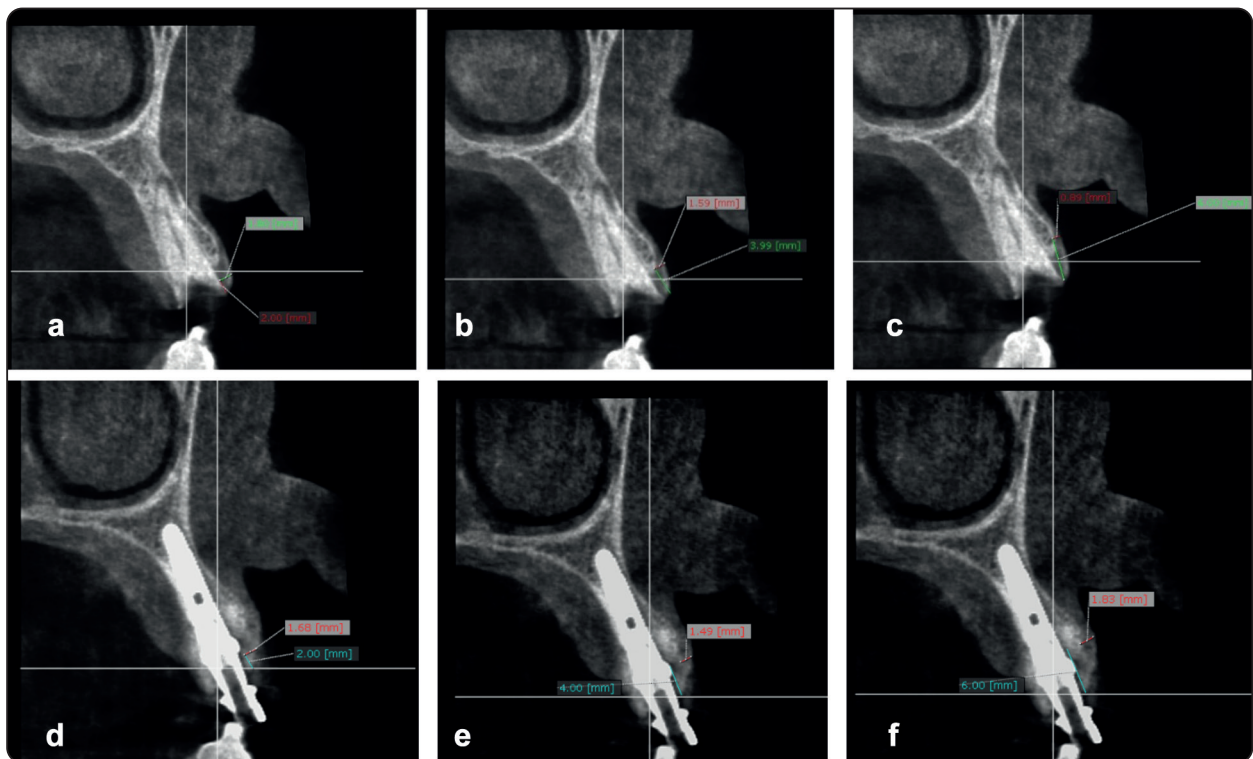


Fig. (2) (a) Pre-surgical measurement of the facial gingival thickness at 2 mm from the FGM (1.30mm), (b) Pre-surgical measurement of the facial gingival thickness at 4 mm from the FGM (1.59mm), (c) Pre-surgical measurement of the facial gingival thickness at 6 mm from the FGM (0.89mm), (d) Post-surgical measurement of the facial STT at 2 mm from the FMM (1.68mm), (e) Post-surgical measurement of the facial STT at 4 mm from the FMM (1.49mm), (f) Post-surgical measurement of the facial STT at 6 mm from the FMM (1.83mm)

RESULTS

Mean age was 36.5±10.94 (minimum 20 and maximum 53) for female participants and 41.9±10.4 (minimum 23 and maximum 56) for male participants. Descriptive statistics for facial STT measurements attained from different points using both methods were presented as “Mean ±SD”. Pre surgical clinical measurements of gingival thickness ranged between 1.06 and 1.89 mm, 0.81 and 2.83mm and 0.84 and 2.26mm for 2mm, 4mm, 6mm readings respectively. CBCT

pre surgical measurements ranged between 1.02 and 2.21mm, 0.61 and 2.21mm and 0.77 and 2.76 respectively for 2mm, 4mm and 6mm. On the other hand, post-surgical measurements at 2mm from FGM ranged between 1.61 and 2.27 mm for clinical measurements and 1.31 and 2.13 for CBCT, at 4mm ranged between 0.73 and 4.32 mm for clinical measurements and 1.27 and 2.57 mm for CBCT, and at 6 mm the measurements ranged between 0.99 and 2.43 mm for clinical measurements and 1.01 and 2.98mm for CBCT (Table 1)(Figure 3).

TABLE (1) Descriptive statistics as mean and standard Deviation (S.D.) of facial STT measurements at different points for both methods

Measurements	Pre			Post			P-value
	Mean	S. D	Limits of agreements	Mean	S. D	Limits of agreements	
CBCT 2 mm	1.36	0.32	1.21 to 1.51	1.95	0.26	1.83 to 2.07	0.000**
DBS 2 mm	1.39	0.19	1.30 to 1.48	1.85	0.16	1.77 to 1.93	0.000**
P-value			0.714			0.146	
CBCT 4 mm	1.14	0.51	0.89 to 1.37	1.73	0.42	1.53 to 1.93	0.000**
DBS 4 mm	1.26	0.45	1.05 to 1.47	1.61	0.91	1.18 to 2.03	0.030*
P-value			0.407			0.586	
CBCT 6 mm	1.54	0.63	1.25 to 1.84	1.65	0.66	1.06 to 1.43	0.000**
DBS 6 mm	1.24	0.39	1.34 to 1.96	1.84	0.33	1.69 to 1.99	0.000**
P-value			0.082			0.245	

(*) P-value < 0.05 is significant.

(**) P-value < 0.001 is highly significant.

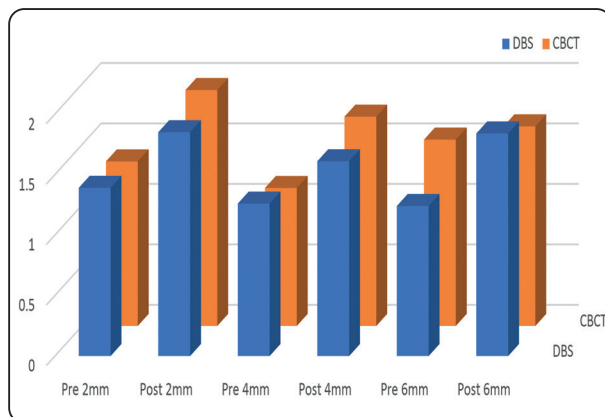


Fig. (3) Analysis of mean differences between both methods before and after IIP at the three different measuring points.

Pearson correlation coefficient showed an inverse correlation between direct bone sounding and CBCT at 2mm and 6mm and a weak positive correlation between both methods at 4mm in the pre surgical readings while the post-surgical readings showed an inverse correlation in all measuring points (Table 2) (Figure 4,5).

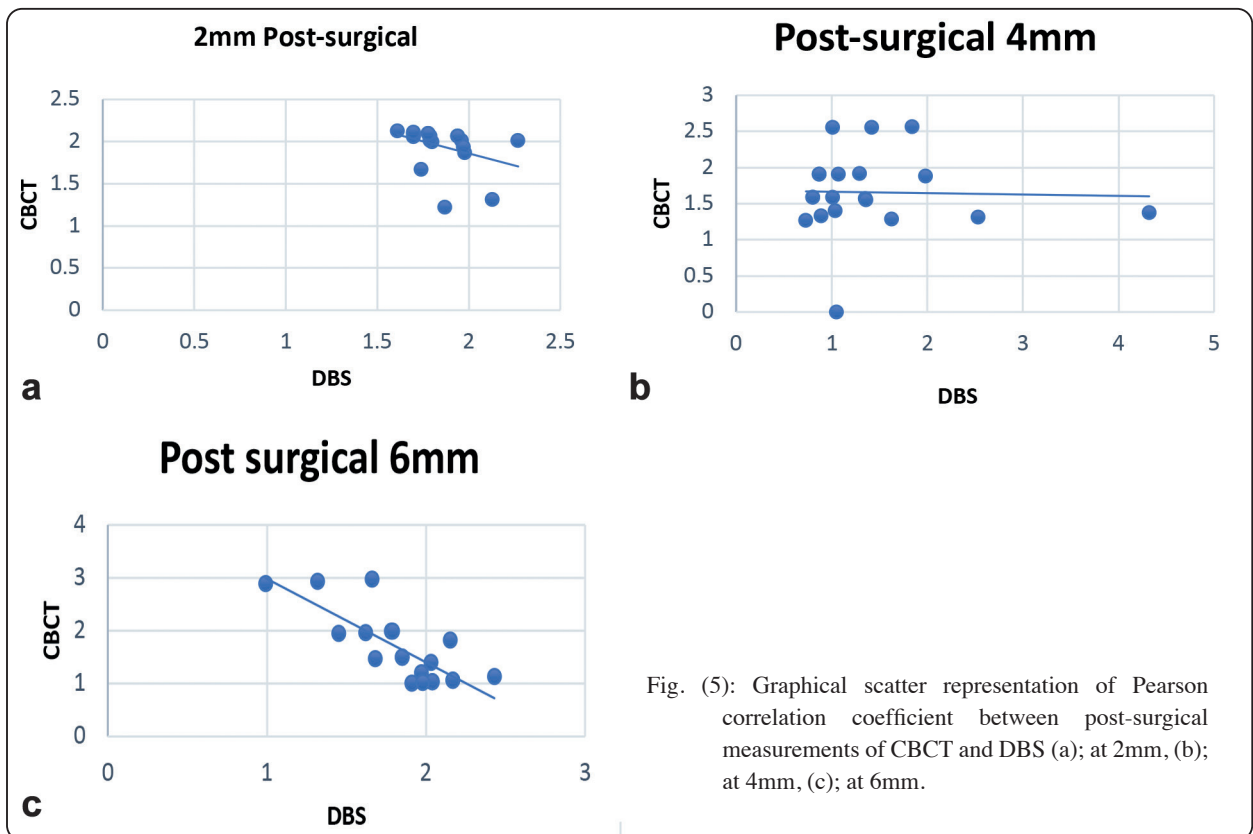
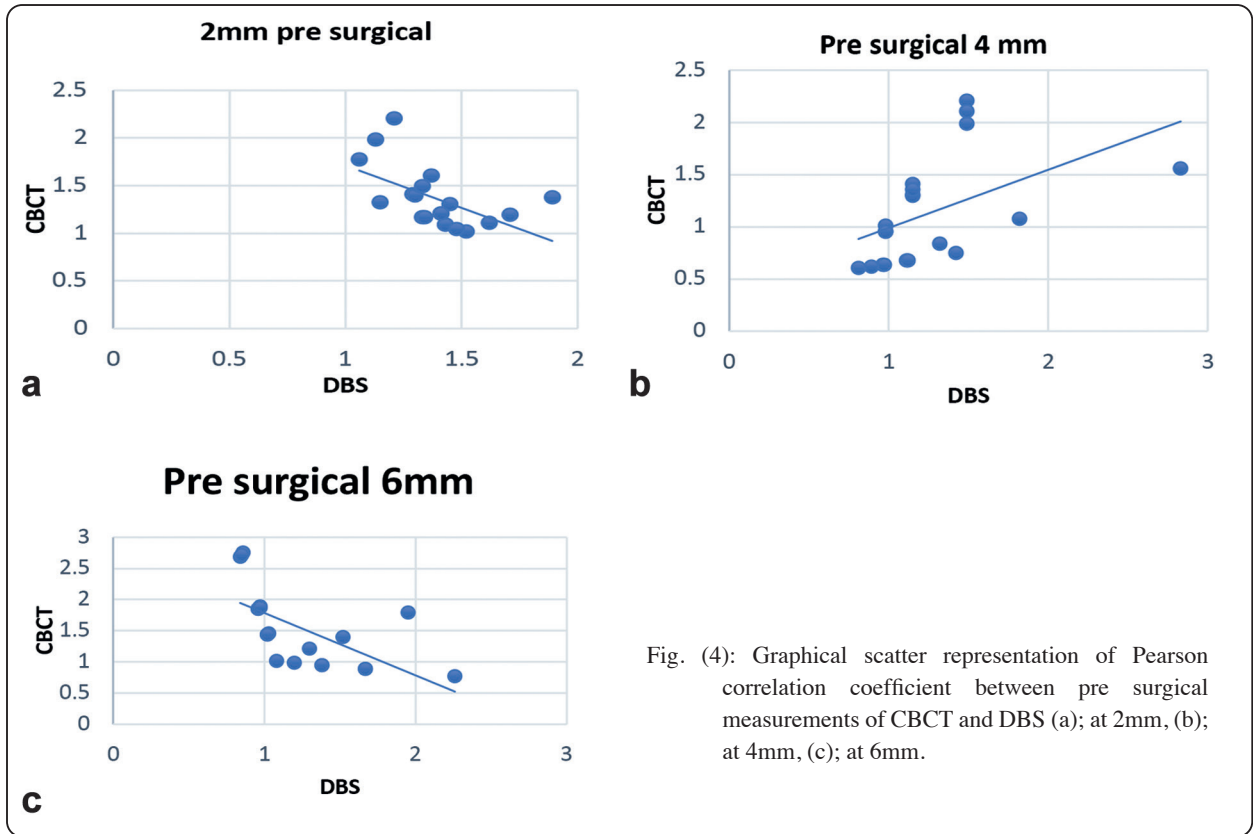


TABLE (2) Pearson correlation coefficient between CBCT and DBS at different points before and after IIP.

		r (p-value)
Pre	(CBCT & DBS)2mm	-0.545 (0.013*)
	(CBCT & DBS) 4mm	0.488 (0.029*)
	(CBCT & DBS) 6 mm	-0.627 (0.003*)
Post	(CBCT & DBS)2mm	-0.362 (0.117)
	(CBCT & DBS) 4mm	-1.94 (0.412)
	(CBCT & DBS) 6 mm	-0.793 (0.000**)

(*) P-value < 0.05 is significant.

(**) P-value < 0.001 is highly significant.

DISCUSSION

In dental implantology field, evaluating the bone & soft tissue quality and quantity had become essential to guarantee implant success and peri-implant esthetics (30). Gingival phenotype is a key factor that significantly impacts the success of the aesthetic outcomes of dental implants, specifically immediate implants in esthetic areas (41-43). It is affected by several factors such as dental arch, age, sex, and race (44). Peri-implant marginal mucosal recession is still a concern and may have a negative effect on the final esthetics especially around implants placed immediately in the esthetic zone (45). In order to decrease the chances of mid-facial peri-implant recession soft tissue grafts were used and proved to increase the facial peri-implant STT and decrease the mid-facial recession (46). Hence, CTG were used in the present study to improve the gingival thickness around the immediately placed implants in the esthetic zone.

Multiple methods were applied to assess the gingival thickness, though the invasive transgingival probing is still believed to be the gold standard to measure the gingival/soft tissue thickness(44). Transgingival probing is done via directly piercing the periodontal soft tissue till

reaching the underlying root or alveolar bone using an endodontic file with silicon stopper and then measuring the distance between the tip and the stopper. In spite of the easiness of this technique, patient discomfort and the requirement of local anesthesia that may increase the soft tissue volume are the common adverse effects of this technique (47).

On the other hand, CBCT has been broadly used in the maxillofacial and dental regions, and its use in periodontal soft tissue assessment have been stated in multiple published studies (48) (49) (50). Difficulty in distinguishing the fine soft tissue structures because of the overlapping between Lips and gingiva is considered a key significant disadvantage of using CBCT in oral soft tissue assessments. Hence, radiopaque materials (51-53), acrylic lip retractors (54,55) and mouth inflation (56) were applied to improve the oral cavity soft tissue resolution.

Considering the raising applications of CBCT in dental implant planning and aiming to expand its use to serve for bone and soft tissues assessment, this study was conducted. This would guarantee better use of CBCT images and allow sparing the patient from the discomfort of the direct bone sounding.

In the present study, immediate implants were placed in the upper maxillary esthetic zone. All implant sites received facial connective tissue grafts at the time of implant placement and the thickness of the peri-implant soft tissues was evaluated before implant and CTG placement and 6 months following their placement at 3 points; 2mm, 4mm and 6 mm. Facial STT was assessed using two methods; direct bone sounding using endodontic file with stopper and CBCT.

Clinical bone sounding readings of the facial STT showed significant increase from 1.39±0.19, 1.26 ±0.45 and 1.24±0.39 at 2mm, 4mm and 6mm respectively to 1.85±0.16, 1.61±0.91 and 1.84 ±0.33 at 2mm, 4mm and 6mm respectively. CBCT readings also showed significant increase from 1.36 ±0.32 to 1.95 ±0.26 at 2mm, 1.14 ±0.51 to 1.73±0.42 at 4mm and 1.54±0.63 to 1.65 ±0.66 at 6mm. On the other

hand, no significant differences were noted when the two measuring methods were compared.

The results of the present study was in accordance with Gupta et al., who used an acrylic stent to measure the palatal tissue thickness at three significant points clinically using a standardized UNC-15 probe and radiographically using CBCT on 20 patients and reported no significant difference between the two methods⁽³⁹⁾. Silva et al., assessed CBCT accuracy in measuring the gingival thickness in the anterior segment and reported a correlated results with the measurements obtained from clinical probing⁽³⁰⁾. Moudi et al., used a baseplate wax representing the soft tissue on jaws of dry human skull and compared the different thicknesses using digital caliper and CBCT and reported that CBCT accuracy in measuring soft tissue thickness was 0.1 mm.⁽²⁶⁾ A novel CBCT technique by Lu et al., required patients to actively close their lips and inflate their vestibules in order to separate the lips and cheeks from the gingiva during imaging and proved its accuracy compared to direct bone sounding⁽⁵⁷⁾. On the other hand, a study on fresh cadavers reported a significant difference between CBCT and transgingival probing measurements for the palatal STT and a non-significant difference between the two methods for the facial STT⁽⁵⁸⁾.

In the present study, though there was no significant difference between both methods, there was an inverse correlation between direct bone sounding and CBCT readings. In contrast, Borges et al., reported a significant difference between transgingival probing and CBCT in gingival tissue measurements in gummy smile cases, and a positive correlation between both methods⁽⁵²⁾. Sönmez et al., delineated no significant difference and a high correlation between CBCT and clinical measurements in assessing the gingival thickness in edentulous patients before, in addition they found that the distribution of differences between both methods showed a statistically significant difference unlike the distribution of differences between high resolution ultrasound (US) and

clinical measurements that showed a statistically non-significant difference⁽⁵⁵⁾.

As a known fact, the radiation caused by CBCT is considered a major disadvantage of this technique. Therefore, this technique could be primarily used where obligatory radiological evaluation is needed as in implant and hard tissue augmentation surgeries rather than plastic periodontal surgeries.

CONCLUSION

CBCT proved to be an accurate and a practical device for oral soft tissue thickness measurement with multiple advantages including less invasiveness, reduced radiation exposure, high resolution, affordability and speed of data collection and archiving.

REFERENCES

1. Linkevicius T, Apse P, Grybauskas S, Puisys A. The influence of soft tissue thickness on crestal bone changes around implants: a 1-year prospective controlled clinical trial. *Int J Oral Maxillofac Implants.* 2009;24(4):712–9.
2. Groisman M, Frossard WM, Ferreira HMB, de Menezes Filho LM, Touati B. Single-tooth implants in the maxillary incisor region with immediate provisionalization: 2-year prospective study. *Pract Proced Aesthet Dent.* 2003 Mar;15(2):115–22, 124; quiz 126.
3. De Rouck T, Collys K, Cosyn J. Immediate single-tooth implants in the anterior maxilla: A 1-year case cohort study on hard and soft tissue response. *J Clin Periodontol.* 2008;35(7):649–57.
4. Poskevicius L, Sidlauskas A, Galindo-Moreno P, Juodzbaly G. Dimensional soft tissue changes following soft tissue grafting in conjunction with implant placement or around present dental implants: a systematic review. *Clin Oral Implants Res.* 2017;28(1):1–8.
5. Zigdon H, Machtei EE. The dimensions of keratinized mucosa around implants affect clinical and immunological parameters. *Clin Oral Implants Res.* 2008 Apr;19(4):387–92.
6. Caneva M, Botticelli D, Viganò P, Morelli F, Rea M, Lang NP. Connective tissue grafts in conjunction with implants installed immediately into extraction sockets. An experimental study in dogs. *Clin Oral Implants Res.* 2013 Jan;24(1):50–6.

7. Tan WL, Wong TLT, Wong MCM, Lang NP. A systematic review of post-extraction alveolar hard and soft tissue dimensional changes in humans. *Clin Oral Implants Res.* 2012 Feb;23:1–21.
8. Khoury F, Happe A, Hoppe A. Soft tissue management in oral implantology: a review of surgical techniques for shaping an esthetic and functional peri-implant soft tissue structure. *Quintessence Int.* 2000;31(7):483–99.
9. Bianchi AE, Sanfilippo F. Single-tooth replacement by immediate implant and connective tissue graft: a 1-9-year clinical evaluation. *Clin Oral Implants Res.* 2004 Jun;15(3):269–77.
10. Covani U, Marconcini S, Galassini G, Cornelini R, Santini S, Barone A. Connective Tissue Graft Used as a Biologic Barrier to Cover an Immediate Implant. *J Periodontol.* 2007 Aug;78(8):1644–9.
11. Zweers J, Thomas RZ, Slot DE, Weisgold AS, Van der Weijden FGA. Characteristics of periodontal biotype, its dimensions, associations and prevalence: a systematic review. *J Clin Periodontol.* 2014 Oct;41(10):958–71.
12. Silva JNN, Andrade PF de, Sotto-Maior BS, Souza Picorelli Assis NM, Pires Carvalho AC, Devito KL. Influence of lip retraction on the cone beam computed tomography assessment of bone and gingival tissues of the anterior maxilla. *Oral Surg Oral Med Oral Pathol Oral Radiol.* 2017;123(6):714–20.
13. Kan JYK, Rungcharassaeng K, Lozada JL, Zimmerman G. Facial gingival tissue stability following immediate placement and provisionalization of maxillary anterior single implants: a 2- to 8-year follow-up. *Int J Oral Maxillofac Implants.* 2011;26(1):179–87.
14. Eghbali A, De Bruyn H, Cosyn J, Kerckaert I, Van Hoof T. Ultrasonic Assessment of Mucosal Thickness around Implants: Validity, Reproducibility, and Stability of Connective Tissue Grafts at the Buccal Aspect. *Clin Implant Dent Relat Res.* 2016;18(1):51–61.
15. Anderegg CR, Metzler DG, Nicoll BK. Gingiva Thickness in Guided Tissue Regeneration and Associated Recession at Facial Furcation Defects. *J Periodontol.* 1995 May;66(5):397–402.
16. Olsson M, Lindhe J, Marinello CP. On the relationship between crown form and clinical features of the gingiva in adolescents. *J Clin Periodontol.* 1993;20(8):570–7.
17. Eger T, Müller HP, Heinecke A. Ultrasonic determination of gingival thickness. Subject variation and influence of tooth type and clinical features. *J Clin Periodontol.* 1996;23(9):839–45.
18. Studer SP, Allen EP, Rees TC, Kouba a. The thickness of masticatory mucosa in the human hard palate and tuberosity as potential donor sites for ridge augmentation procedures. *J Periodontol.* 1997;68(2):145–51.
19. Wara-Aswapati, N, Pitiphat W, Chandrapho N, Rattanayatikul C, Karimbux N. Thickness of Palatal Masticatory Mucosa Associated With Age; Thickness of Palatal Masticatory Mucosa Associated With Age [Internet]. Vol. 72, *J Periodontol.* Wiley; 2001 Oct [cited 2021 Apr 1]. Available from: <https://aap.onlinelibrary.wiley.com/doi/abs/10.1902/jop.2001.72.10.1407>
20. Uchida H, Kobayashi K, Nagao M. Measurement in vivo of masticatory mucosal thickness with 20 MHz B-mode ultrasonic diagnostic equipment. *J Dent Res.* 1989;68(2):95–100.
21. Müller HP, Schaller N, Eger T. Ultrasonic determination of thickness of masticatory mucosa: a methodologic study. *Oral Surg Oral Med Oral Pathol Oral Radiol Endod.* 1999;88:248–53.
22. Younes F, Eghbali A, Raes M, De Bruyckere T, Cosyn J, De Bruyn H. Relationship between buccal bone and gingival thickness revisited using non-invasive registration methods. *Clin Oral Implants Res.* 2016;27(5):523–8.
23. Song J-E, Um Y-J, Kim C-S, Choi S-H, Cho K-S, Kim C-K, et al. Thickness of Posterior Palatal Masticatory Mucosa: The Use of Computerized Tomography. *J Periodontol* [Internet]. 2008 Mar 1 [cited 2021 Apr 1];79(3):406–12. Available from: <http://doi.wiley.com/10.1902/jop.2008.070302>
24. Slak B, Daabous A, Bednarz W, Strumban E, Maev RG. Assessment of gingival thickness using an ultrasonic dental system prototype: A comparison to traditional methods. *Ann Anat.* 2015;199:98–103.
25. Nikiforidou M, Tsalikis L, Angelopoulos C, Menexes G, Vouros I, Konstantinides A. Classification of periodontal biotypes with the use of CBCT. A cross-sectional study. *Clin Oral Investig.* 2016 Nov;20(8):2061–71.
26. Moudi E, Haghanifar S, Johari M, Gholinia H, Ghanbarabadi M. Evaluation of the cone-beam computed tomography accuracy in measuring soft tissue thickness in different areas of the jaws. *J Indian Soc Periodontol* [Internet]. 2019 Jul 1 [cited 2023 Jul 5];23(4):334–8. Available from: https://journals.lww.com/jisp/Fulltext/2019/23040/Evaluation_of_the_cone_beam_computed_tomography.9.aspx
27. Furtado Á, Furtado G-C, Haje O El, Rosário H-D, Franco A, Makeeva I, et al. Soft-tissue cone-beam computed tomography (ST-CBCT) technique for the analysis of skeletal, dental and periodontal effects of orthopedic rapid max-

- illary expansion. *J Clin Exp Dent* [Internet]. 2018 [cited 2023 Jul 5];10(9):883–90. Available from: <http://dx.doi.org/10.4317/jced.55139>
28. Siqueira de Lima L, Brunetto DP, da Cunha Gonçalves Nojima M. Evaluation of facial soft tissue thickness in symmetric and asymmetric subjects with the use of cone-beam computed tomography. *Am J Orthod Dentofac Orthop* [Internet]. 2019 Feb 1 [cited 2023 Jul 5];155(2):216–23. Available from: <http://www.ajodo.org/article/S0889540618308709/fulltext>
 29. Chaturvedi S, Haralur SB, Addas MK, Alfarsi MA. CBCT analysis of schneiderian membrane thickness and its relationship with gingival biotype and arch form. *Niger J Clin Pract* [Internet]. 2019 Oct 1 [cited 2023 Jul 5];22(10):1448–56. Available from: https://journals.lww.com/njcp/Fulltext/2019/22100/CBCT_Analysis_of_Schneiderian_Membrane_Thickness.22.aspx
 30. Silva JNN, Andrade PF de, Sotto-Maior BS, Souza Picorelli Assis NM, Pires Carvalho AC, Devito KL. Influence of lip retraction on the cone beam computed tomography assessment of bone and gingival tissues of the anterior maxilla. *Oral Surg Oral Med Oral Pathol Oral Radiol* [Internet]. 2017 Jun 1 [cited 2023 Jul 5];123(6):714–20. Available from: <http://www.oooojournal.net/article/S2212440317300640/fulltext>
 31. Januário AL, Barriviera M, Duarte WR. Soft Tissue Cone-Beam Computed Tomography: A Novel Method for the Measurement of Gingival Tissue and the Dimensions of the Dentogingival Unit. *J Esthet Restor Dent* [Internet]. 2008 Dec 1 [cited 2023 Jul 5];20(6):366–73. Available from: <https://onlinelibrary.wiley.com/doi/full/10.1111/j.1708-8240.2008.00210.x>
 32. Ueno D, Sekiguchi R, Morita M, Jayawardena A, Shinpo S, Sato J, et al. Palatal Mucosal Measurements in a Japanese Population Using Cone-Beam Computed Tomography. *J Esthet Restor Dent* [Internet]. 2014 Jan 1 [cited 2023 Jul 5];26(1):48–58. Available from: <https://onlinelibrary.wiley.com/doi/full/10.1111/jerd.12053>
 33. Fu J-H, Yeh C-Y, Chan H-L, Tatarakis N, Leong DJM, Wang H-L. Tissue Biotype and Its Relation to the Underlying Bone Morphology. *J Periodontol* [Internet]. 2010 Apr 1 [cited 2023 Jul 5];81(4):569–74. Available from: <https://onlinelibrary.wiley.com/doi/full/10.1902/jop.2009.090591>
 34. Song J-E, Um Y-J, Kim C-S, Choi S-H, Cho K-S, Kim C-K, et al. Thickness of Posterior Palatal Masticatory Mucosa: The Use of Computerized Tomography. *J Periodontol* [Internet]. 2008 Mar 1 [cited 2023 Jul 6];79(3):406–12. Available from: <https://onlinelibrary.wiley.com/doi/full/10.1902/jop.2008.070302>
 35. Dong J, Zhang FY, Wu GH, Zhang W, Yin J. Measurement of mucosal thickness in denture-bearing area of edentulous mandible. *Chin Med J (Engl)* [Internet]. 2015 [cited 2023 Jul 6];128(3):342–7. Available from: www.cmj.org
 36. Esfahanizadeh N, Daneshparvar N, Askarpour F, Akhondi N, Panjnoush M. Correlation Between Bone and Soft Tissue Thickness in Maxillary Anterior Teeth. *J Dent (Tehran)* [Internet]. 2016 Sep [cited 2023 Jul 6];13(5):302. Available from: <http://pmc/articles/PMC5250627/>
 37. Mallikarjun S, Babu H, Das S, Neelakanti A, Dawra C, Shinde S. Comparative evaluation of soft and hard tissue dimensions in the anterior maxilla using radiovisiography and cone beam computed tomography: A pilot study. *J Indian Soc Periodontol* [Internet]. 2016 Mar 1 [cited 2023 Jul 6];20(2):174. Available from: <http://pmc/articles/PMC4847464/>
 38. Cassiano L, Barriviera M, Nascimento G, Januario A. Soft tissue cone beam computed tomography (ST-CBCT) for the planning of esthetic crown lengthening procedures Evaluation of osteoinductive potencial of local use of simvastatin View project Oral health nested in Pelotas population-based cohort studies Vie. *Artic Int J Esthet Dent* [Internet]. 2016 [cited 2023 Jul 6]; Available from: <https://www.researchgate.net/publication/318508620>
 39. Gupta P, Jan SM, Behal R, Mir RA, Shafi M. Accuracy of cone-beam computerized tomography in determining the thickness of palatal masticatory mucosa. *J Indian Soc Periodontol* [Internet]. 2015 Jul 1 [cited 2023 Jul 6];19(4):396. Available from: <http://pmc/articles/PMC4555796/>
 40. Hürzeler M, & DW-IJ of P, 1999 undefined. A single-incision technique to harvest subepithelial connective tissue grafts from the palate. *quintpub.com* [Internet]. [cited 2021 May 29]; Available from: http://www.quintpub.com/user-home/prd/prd_19_3_hurzeler_8.pdf
 41. Kim DM, Bassir SH, Nguyen TT. Effect of gingival phenotype on the maintenance of periodontal health: An American Academy of Periodontology best evidence review. *J Periodontol* [Internet]. 2020 Mar 1 [cited 2023 Apr 20];91(3):311–38. Available from: <https://onlinelibrary.wiley.com/doi/full/10.1002/JPER.19-0337>
 42. Tavelli L, Barootchi S, Avila-Ortiz G, Urban IA, Giannobile W V., Wang HL. Peri-implant soft tissue phenotype modification and its impact on peri-implant health: A systematic review and network meta-analysis. *J Periodontol* [Internet]. 2021 Jan 1 [cited 2023 Apr 20];92(1):21–44. Available from: <https://onlinelibrary.wiley.com/doi/full/10.1002/JPER.19-0716>

43. Malpartida-Carrillo V, Tinedo-Lopez PL, Guerrero ME, Amaya-Pajares SP, Özcan M, Rösing CK. Periodontal phenotype: A review of historical and current classifications evaluating different methods and characteristics. *J Esthet Restor Dent* [Internet]. 2021 Apr 1 [cited 2023 Apr 20];33(3):432–45. Available from: <https://onlinelibrary.wiley.com/doi/full/10.1111/jerd.12661>
44. Wang J, Sa DI, Dds C, Zhao Q, Bai D. Methods to assess tooth gingival thickness and diagnose gingival phenotypes: A systematic review. 2022 [cited 2023 Apr 20]; Available from: <https://onlinelibrary.wiley.com/doi/10.1111/jerd.12900>
45. Arora H, Ivanovski S. Correlation between pre-operative buccal bone thickness and soft tissue changes around immediately placed and restored implants in the maxillary anterior region: A 2-year prospective study. *Clin Oral Implants Res* [Internet]. 2017 Oct 1 [cited 2023 Jul 7];28(10):1188–94. Available from: <https://onlinelibrary.wiley.com/doi/full/10.1111/clr.12939>
46. Moussa S, Ragy N, Ghaffar KA. Evaluation of Muco-graft® in increasing the peri-implant soft tissue thickness in the esthetic zone. *Futur Dent J* [Internet]. 2021 May 30 [cited 2023 Jul 7];6(2). Available from: <https://digitalcommons.aaru.edu.jo/fdj/vol6/iss2/5>
47. Ronay V, Sahrman P, Bindl A, Attin T, Schmidlin PR. Current Status and Perspectives of Mucogingival Soft Tissue Measurement Methods. *J Esthet Restor Dent* [Internet]. 2011 Jun 1 [cited 2023 Apr 20];23(3):146–56. Available from: <https://onlinelibrary.wiley.com/doi/full/10.1111/j.1708-8240.2011.00424.x>
48. Chaturvedi S, Haralur SB, Addas MK, Alfarsi MA. CBCT analysis of schneiderian membrane thickness and its relationship with gingival biotype and arch form. *Niger J Clin Pract* [Internet]. 2019 Oct 1 [cited 2023 Apr 20];22(10):1448–56. Available from: https://journals.lww.com/njcp/Fulltext/2019/22100/CBCT_Analysis_of_Schneiderian_Membrane_Thickness.22.aspx
49. Cha S, Lee SM, Zhang C, Tan Z, Zhao Q. Correlation between gingival phenotype in the aesthetic zone and craniofacial profile—a CBCT-based study. *Clin Oral Investig* [Internet]. 2021 Mar 1 [cited 2023 Apr 20];25(3):1363–74. Available from: <https://link.springer.com/article/10.1007/s00784-020-03444-9>
50. Amid R, Mirakhori M, Safi Y, Kadkhodazadeh M, Namdari M. Assessment of gingival biotype and facial hard/soft tissue dimensions in the maxillary anterior teeth region using cone beam computed tomography. *Arch Oral Biol*. 2017 Jul 1;79:1–6.
51. Gürlek Ö, Sönmez Ş, Güneri P, Nizam N. A novel soft tissue thickness measuring method using cone beam computed tomography. *J Esthet Restor Dent* [Internet]. 2018 Nov 1 [cited 2023 Apr 20];30(6):516–22. Available from: <https://onlinelibrary.wiley.com/doi/full/10.1111/jerd.12428>
52. Borges GJ, Ruiz LFN, Alencar AHG De, Porto OCL, Estrela C. Cone-beam computed tomography as a diagnostic method for determination of gingival thickness and distance between gingival margin and bone crest. *Sci World J*. 2015;2015.
53. Shao Y, Yin L, Gu J, Wang D, Lu W, Sun Y. Assessment of Periodontal Biotype in a Young Chinese Population using Different Measurement Methods. [cited 2023 Apr 20]; Available from: www.nature.com/scientificreports
54. Chen ZY, Zhong JS, Ouyang XY, Zhou SY, Xie Y, Lou XZ. [Gingival thickness assessment of gingival recession teeth]. *Beijing Da Xue Xue Bao* [Internet]. 2020 Apr 1 [cited 2023 Apr 20];52(2):339–45. Available from: <https://europepmc.org/articles/PMC7433469>
55. Sönmez G, Kamburoğlu K, Gülşahi A. Accuracy of high-resolution ultrasound (US) for gingival soft tissue thickness measurement in edentulous patients prior to implant placement. *Dentomaxillofacial Radiol* [Internet]. 2021 Nov 30 [cited 2023 Apr 20];50(5):50. Available from: <https://www.birpublications.org/doi/10.1259/dmfr.20200309>
56. Henry P, Alves M, Thereza I, Lira C, Alves P, Thiago I, et al. Measurement properties of gingival biotype evaluation methods. [cited 2023 Apr 20]; Available from: <https://onlinelibrary.wiley.com/doi/10.1111/cid.12583>
57. Lu JW, Shi X, Huang SH, Yan XZ, Hu CJ, Shi MY, et al. A novel cone-beam CT scanning technique for measuring periodontal soft tissues in the esthetic area. *J Oral Sci*. 2022;64(3):212–7.
58. Fu J-H, Yeh C-Y, Chan H-L, Tatarakis N, Leong DJM, Wang H-L. Tissue Biotype and Its Relation to the Underlying Bone Morphology. *J Periodontol* [Internet]. 2010 Apr 1 [cited 2023 Jul 10];81(4):569–74. Available from: <https://onlinelibrary.wiley.com/doi/full/10.1902/jop.2009.090591>
59. Guentsch A, Preshaw PM, Bremer-Streck S, Klinger G, Glockmann E, Sigusch BW. Lipid peroxidation and antioxidant activity in saliva of periodontitis patients: effect of smoking and periodontal treatment. *Clin Oral Investig* 2008 124 [Internet]. 2008 May 29 [cited 2021 Oct 29];12(4):345–52. Available from: <https://link.springer.com/article/10.1007/s00784-008-0202-z>