

## **Bone Marrow Mesenchymal Stem Cells Alleviate Methotrexate-Induced Renal Toxicity in leukemia Rats**

**Hanan. M. Abd El-Latief**

Zoology Department, Women's College for Arts, Science and Education, Ain Shams University, Cairo, Egypt.

**Submit Date :** 01 Aug. 2023

**Revise Date :** 25 Aug. 2023

**Accept Date:** 01 Sept. 2023

### **Keywords**

- Mesenchymal Stem Cells
- Methotrexate
- Renal toxicity
- Transforming growth factor- $\beta$ 1

### **Abstract**

**Background:** The chemotherapeutic drug methotrexate (MTX) is administered for managing multiple kinds of cancer. **Aim:** To determine if bone marrow mesenchymal stem cells (BM-MSCs) might protect rats against renal damage brought on by MTX. **Materials and Methods:** Rats were divided into five groups : (i) Control group received 2.5 ml saline. (ii) group received MTX as a single IP of 20 mg/Kg body weight. (iii) LEUK group: Benzene-induced leukemia group was injected intravenously every 2 days for 3 consecutive weeks by 0.2 ml benzene. (iv) LEUK/MTX group was injected intravenously every 2 days for 3 consecutive weeks by 0.2 ml benzene and treated by intraperitoneal injection of 2.5 mg/kg.bw/week MTX for 4 consecutive weeks. (v) (LEUK/ MTX/MSCs) group was injected intravenously every 2 days for 3 consecutive weeks by 0.2 ml benzene and treated by intraperitoneal injection of 2.5 mg/kg.bw/week MTX for 4 consecutive weeks. This group was also left for 8 days for kidney injury induction then injected intravenously with a single dose of  $3 \times 10^6$  MSCs. After 4 weeks of MSCs transplantation. Kidney histopathology, Catalase and Superoxide dismutase activities as well as Capase-3 expression levels were examined. **Results:** Methotrexate induced marked pathological lesion which characterized by focal necrosis, cell infiltration and high immuno-expression of TGF- $\beta$ 1. Besides, treatment with MSCs successfully improved the severe effects of MTX on the kidney and restored histological architecture which confirmed by oxidative enzymes and apoptosis marker detection. **Conclusion:** MSCs have the capacity to protect against kidney fibrosis and might be employed as adjuvant treatment.

## 1. Introduction

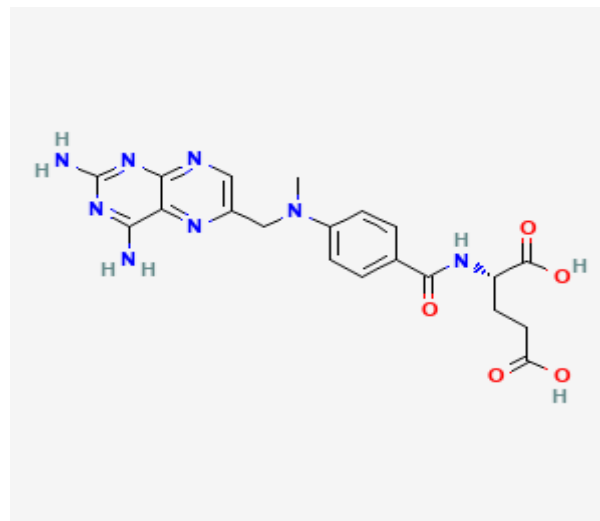
A multiphase condition, acute kidney damage (AKI) is a cause for worry on a worldwide scale. The chance of developing end-stage renal disease (ESRD) or chronic kidney disease (CKD) rises when AKI first appears. Additionally, CKD affects up to 16% of the world's population, and having CKD raises the chance of developing new AKI Episodes [1, 2].

Mesenchymal stem cells (MSCs) are stromal cells with multi-lineage differentiation and the capacity to self-renew. They may be extracted from a number of tissues, including adipose tissue, bone marrow, and the umbilical cord. MSCs are a cutting-edge alternative for clinical studies due to their multipotent qualities [3]. Mesenchymal stem cells (BM-MSCs) are stem cells that live in the microenvironment of the bone marrow. [3].

Convenient collection, quick proliferation, growth in vitro, durable self-renewal capacity in vivo, and a lack of ethically dubious concerns are all positive characteristics of BM-MSCs [4]. As a viable alternative to conventional pharmaceutical therapy, cell-based medicines are emerging. Bone marrow mesenchymal stem cells (BM-MSCs) stand out among the options for cell therapy because of their multi-lineage potential, anti-inflammatory effects, ability to avoid immune system detection by the host, and relative ease of expansion in culture. [5].

Mesenchymal stem cells (MSCs) are exceptional multipotent cells with strong immunomodulatory abilities [6]. For a number of pathologic illnesses, including graft versus host disease, inflammatory airway diseases, and inflammatory bowel diseases, MSCs are now

being investigated in clinical studies at various stages. [7, 8].



### Chemical structure of MTX

An odorless yellow to orange-brown crystalline powder is methotrexate. It is a chemotherapeutic medication that prevents the production of DNA and RNA. A folic acid antagonist known as methotrexate (MTX), which has the molecular formula C<sub>20</sub>H<sub>22</sub>N<sub>8</sub>O<sub>5</sub>, is frequently used to treat a variety of cancers, including acute lymphoblastic leukemia, as well as inflammatory diseases. It also has immunomodulating properties [9]. It has been documented that the injection of MTX can cause fibrosis in various organs, including the lung [10]. One of the folic acid antagonists that is frequently utilized in the treatment of several disorders is methotrexate (MTX). The following conditions are treated with it: psoriasis [11], psoriatic arthritis [12], rheumatoid arthritis in elderly and younger patients [13], acute lymphoblastic leukemia [14], ectopic pregnancy [15], inflammatory bowel diseases like Crohn's disease and ulcerative colitis [16], chronic inflammatory demyelinating polyradiculoneuropathy [17], and acute lymphoblastic leukemia. The purpose of the

current study was to determine if BM-MSCs could treat rats with renal damage brought on by MTX.

## **MATERIALS AND METHODS**

### **Methotrexate (MTX)**

MTX was bought from the Australian subsidiary of Pfizer Pharmaceuticals Ltd. For the purpose of inducing kidney damage in rats, a single intraperitoneal injection of 20 mg/kg body weight was administered [18].

### **Leukemia induction**

Leukemia was induced in rats by intravenous injection of 0.2 ml of 1:10 diluted benzene solution (Chromasolv, in water/2-propanol [50/50] v/v). Benzene was given every 2 days for 3 consecutive weeks according to [19].

### **Preparation of MSCs**

In order to prepare stem cells, 6-week-old male albino rats were employed. Bone marrow was obtained by flushing the tibiae and femurs with DMEM, which was then augmented with 10% fetal bovine serum (GIBCO/BRL). The isolated nucleated cells were suspended in a full culture medium containing 1% penicillin-streptomycin (GIBCO/BRL) after being separated by a density gradient using Ficoll/Paque (Pharmacia). The cells were incubated at 37°C in 5% humidified CO<sub>2</sub>. Cultures were trypsinized using 0.25% trypsin 1 mM EDTA (GIBCO/BRL) for 5 min at 37°C after cells reached 80–90% confluence. Phosphate buffer saline (PBS; Lonza Company, Swiss) was used to wash cultures after trypsinization. Cells were centrifuged, suspended in media with added serum, and cultured in flasks measuring 50 cm<sup>2</sup> (Falcon)[2].

### **Labeling of MSCs**

PKH26 fluorescent dye was used to mark MSCs in accordance with the Sigma procedure (Saint Louis, Missouri, USA). In a nutshell, cells were

centrifuged and twice-washed in media devoid of serum. Intravenously, cells were injected into a rat tail vein after being pelleted and suspended in a dye solution. [20].

### **Experimental Animals**

Before the trial began, male albino rats (weighing between 100 and 120 g) were acclimated to the laboratory environment for one week. The temperature was regulated between 23 and 25 degrees Celsius, and the animals had unfettered access to food and water. The investigations were authorized by the Regional Centre for Mycology and Biotechnology's ethics committee (RCMB 1500102023).

### **Experimental Design**

Fifty male albino rats were equally divided into five groups (10 rats each) according to the following protocol: (group 1) C: Control group received an intraperitoneal injection of 2.5 ml saline. (group 2) (MTX) group received MTX as a single intraperitoneal injection of 20 mg/Kg body weight. (group 3) LEUK group: Benzene-induced leukemia group was injected intravenously every 2 days for 3 consecutive weeks by 0.2 ml benzene. (group 4) LEUK/MTX group was injected intravenously every 2 days for 3 consecutive weeks by 0.2 ml benzene and treated by intraperitoneal injection of 2.5 mg/kg.bw/week MTX for 4 consecutive weeks. (group 5) (LEUK/MTX/MSCs) group was injected intravenously every 2 days for 3 consecutive weeks by 0.2 ml benzene and treated by intraperitoneal injection of 2.5 mg/kg.bw/week MTX for 4 consecutive weeks. This group was also left for 8 days for kidney injury induction then injected intravenously with a single dose of  $3 \times 10^6$  MSCs. After 4 weeks of MSCs transplantation, all rats in all experimental groups were sacrificed under ether anesthesia.

Kidney histopathology were examined and homogenates were kept for further experiments.

### Histological studies

Kidney slices from all groups were fixed in formalin and embedded in paraffin before experimental estimates from each group were made for histological examinations utilizing hematoxylin and eosin (H&E) staining. Hematoxylin and eosin was used to stain sections of 5  $\mu\text{m}$  thick using the prescribed method[21].

### Immunohistochemical studies

The techniques of immunochemistry tints are applied to demonstrate the localizing process of proteins in tissues by exploiting antibodies associated with antigens. by applying the transforming growth factor  $-\beta$  (TGF- $\beta$ ) technique, in the process of localizing proteins in tissues by exploiting the principle of antibodies binding specifically to antigens. The visualization of the antibody is commonly accomplished by conjugating an enzyme to the antibody. This can produce a color changing reaction. The advantage of this method is the ability to show exactly where a given protein is located. The expression of TGF- $\beta$  (bs1957R) from Biocompare Company, South San Francisco, USA) in kidney sections was incubated at 4°C overnight. Endogenous peroxidase activity was blocked with 1% hydrogen peroxide for 20 min. To improve the quality of staining, microwave oven based antigen retrieval was performed. Slides probed with anti-TGF- $\beta$  (1:200). Sections were washed 3 times with PBS

and incubated with biotin-labeled anti-mouse IgG then stained with a 4- chloro-1-naphthol, which gives a blue-grey color according to the manufactured instructions. Control slides showed no staining when the primary antibody was omitted. Five different fields were examined and color the difference in color intensity for the expression area % of TGF- $\beta$ 1 was analyzed using ImageJ software[22].

### Oxidative markers detection

The activity of the enzymes: catalase (CAT) and superoxide dismutase (SOD) in the homogenates of the renal tissue in accordance to manufacturer's procedure for the kits (Thermo Fisher Scientific, USA[23].

### Gene expression assay

RNA was extracted from kidney specimen by the QIAamp RNeasy Mini kit (Qiagen, Germany, GmbH) though mixing 200  $\mu\text{l}$  of the specimen with 600  $\mu\text{l}$  of RLT buffer, which included 10 ml of mercaptoethanol per 1 ml, and allowing the mixture to sit at room temperature for 10 min. The cleaned lysate was mixed with one litre of 70% ethanol. The primers used for the experiment are listed in Table 1 and were provided by (Metabion Germany). A 20  $\mu\text{l}$  experiment contained 10  $\mu\text{l}$  of the 2x HERA SYBR® Green RT-qPCR Master Mix (Willowfort, UK), 1  $\mu\text{l}$  of RT Enzyme Mix (20X), and 1  $\mu\text{l}$  of water was added. The reaction was run using a one-step real-time PCR apparatus. Amplification curves and ct values were determined by the used program[23].

**Table (1) The used primers:**

Gene name	Sequence of the used primer
$\beta$ -actin( Housekeeping gene )	F: 5'-AAGATCCTGACCGAGCGTGG-3'and R: 5'-CAGCACTGTGTTGGCATAGAGG-3'
Caspase-3( Apoptotic marker)	F: 5'-GTGGAAGTACTGACGATGATATGGC-3'and R: 5'- CGCAAAGTGACTGGATGAACC-3'

### Statistical analysis

Data are represented as means  $\pm$  SD where \*\*\*  $P \leq 0.001$  using GraphPad Prism V.5 SAN DIEGO, CA, USA where student t-test where applied to compare the different groups

### RESULTS

Histological examination of the kidney sections of control rats showed that each kidney consists of an outer granular appearing cortex and an inner striated appearing medulla and composed of huge number of nephron. Each nephron consists of Malpighian corpuscle and three segments; a proximal convoluted tubule, loop of Henle and a distal convoluted tubule. The Malpighian corpuscles are spherical in shape and each consists of a glomerular tuft of capillaries and a double-walled epithelial capsule known as Bowman's capsule. The outer layer of the Malpighian corpuscles is the parietal layer and the inner layer envelops the glomerular corpuscle and is known as the visceral layer, both layer are separated by a distinct space known as the urinary space. The parietal layer is continuous with the beginning of the proximal convoluted tubules. The proximal convoluted tubules are lined with cuboidal or low columnar epithelial cells and exhibit brush borders at their apices and so the lumina appear narrow. The distal convoluted tubules are lined with simple cuboidal epithelial cells with no brush borders and acquiring wider lumina (group 1) (Fig. 1).

On the other hand, the MTX group (group 2), showing epithelial desquamation into the lumen of the tubules, vacuolization in tubular cells, focal necrosis and cell infiltration (Fig. 2). Besides, (Fig. 3) illustrated kidney section from the same group showing glomerular damage and vacuolization in tubular cells. Whereas kidney section from group

3, (LEUK group) showing glomerular damage and renal corpuscles with obscure Bowmans space (Fig. 4).

Microscopic examination of kidney sections from group 4 (LEUK/MTX group), showing, renal tubular damage and, proteinaceous material in the renal tubules, glomerular damage and renal corpuscles with obscure Bowmans space, dilatation, and congestion of the peritubular vessels (Figs. 5, 6, 7). Figure 8 section from group 4 also, showing severe loss of kidney architecture, marked disturbance in glomeruli with strong inflammatory infiltration Glomerulosclerosis.

Examination of kidney sections from group 5 (LEUK/MTX/MSCs group) showed most of the previous mentioned alterations in the renal tissue were almost disappeared (Figs. 9, 10, 11). In this condition, the renal tissue comprising Malpighian corpuscles and renal tubule cells (group 5) appears more or less similar to that described in the control untreated rats.

The Immunohistochemical investigation explained that the transforming growth factor  $-\beta 1$  (TGF- $\beta 1$ ) expression showed normally distribution in kidney tissue (Fig. 12) as control rats. But an intense reaction for TGF- $\beta 1$  was observed in Figure 13 in kidney tissue as a result of MTX administration. While the kidney tissue of rats treated with Benzene-induced leukemia group 3 illustrate the TGF- $\beta 1$  reaction sites relatively intense (Fig. 14). While the tissue from rat kidney treated with benzene and MTX (group 4) showing very intense reaction for TGF- $\beta 1$  (Figs 15, 16). Finally, the investigated of TGF- $\beta 1$  expression, showing the relatively to normal reaction sites distribution in kidney in group five (Fig. 17). There is a dramatic elevation in TGF- $\beta 1$

in methotrexate group relative to control ( $P \leq 0.001$ ). Besides, a decrease in expression could be seen in other groups, where the maximal decreases could be seen in the last group to be in the same level relative to control (**Fig. 18**). There is a significant difference ( $P \leq 0.001$ ) between group 3 and group 5 as well as a notable difference ( $P \leq 0.001$ ) between group 4 and group 5. SOD and CAT levels were assessed in order to determine how MSC may influence and mitigate the damage caused by oxidative stress in renal tissue in leukemia rats. In comparison to the

control group, the SOD and CAT activities significantly decreased in the MTX, LEUK, and LEUK/MTX group of rats ( $P < 0.05$ ). MSC treatment increased antioxidant enzyme activity, demonstrating that MSC restored antioxidant capability in rat renal tissue (**Fig. 19**).

Capase-3 apoptotic marker were assessed in order to determine how MSC impact renal tissue in leukemia rats. MSC treatment significantly decreased the gene expression level ( $P < 0.05$ ) in LEUK/MTX group of rats (**Fig. 20S**).

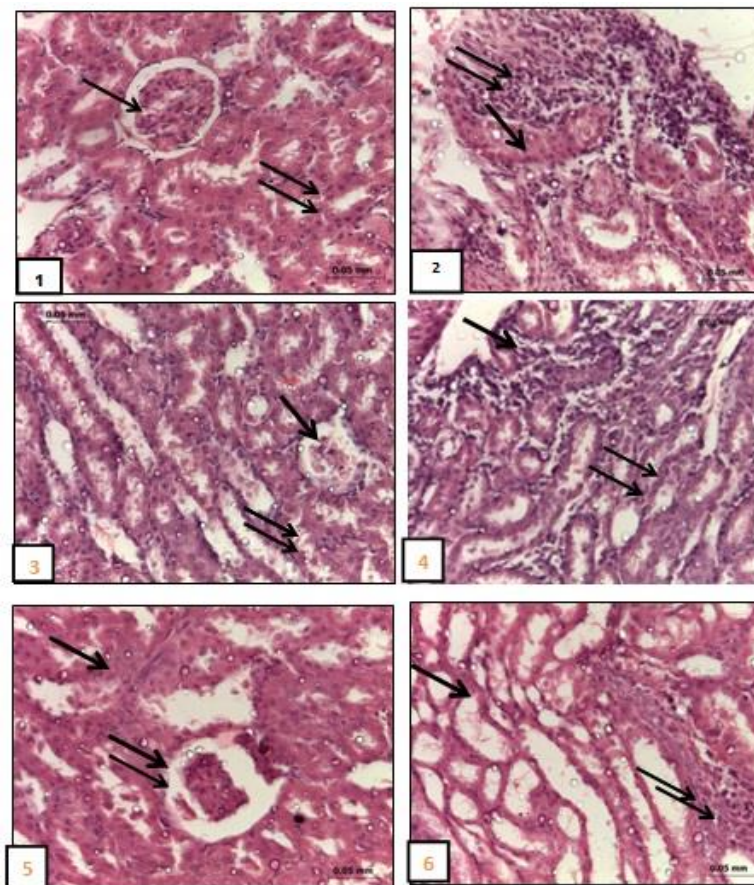


Figure (1) : Photomicrograph of normal kidney section from group 1(control group), showing normal renal architecture . Glomeruli(arrow) and renal tubules ( double arrows) was observed; Figure (2) : Photomicrograph of kidney section from group 2 (MTXgroup), showing epithelial desquamation into the lumen of the tubules (arrow) vacuolization in tubular cells, focal necrosis and cell infiltration(double arrows); Figure (3) : Photomicrograph of kidney section from group 2(MTXgroup), showing glomerular damage (arrow), and vacuolization in tubular cells(double arrows); Figure (4) : Photomicrograph of kidney section from group 3,( LEUKgroup), showing glomerular damage (arrow), and showing epithelial desquamation into the lumen of the tubules .(double arrows); Figure (5) : Photomicrograph of kidney section from group 4( LEUK/MTX group), showing, renal tubular damage and , proteinoeous material in the renal tubules (arrow), glomerular damage with obscure Bowmans space(double arrows); Figure (6) : Photomicrograph of kidney section from group 4( LEUK/MTX group), showing, renal tubular damage and vacuolization in tubular cells (arrow), focal necrosis and cell infiltration(double arrows);

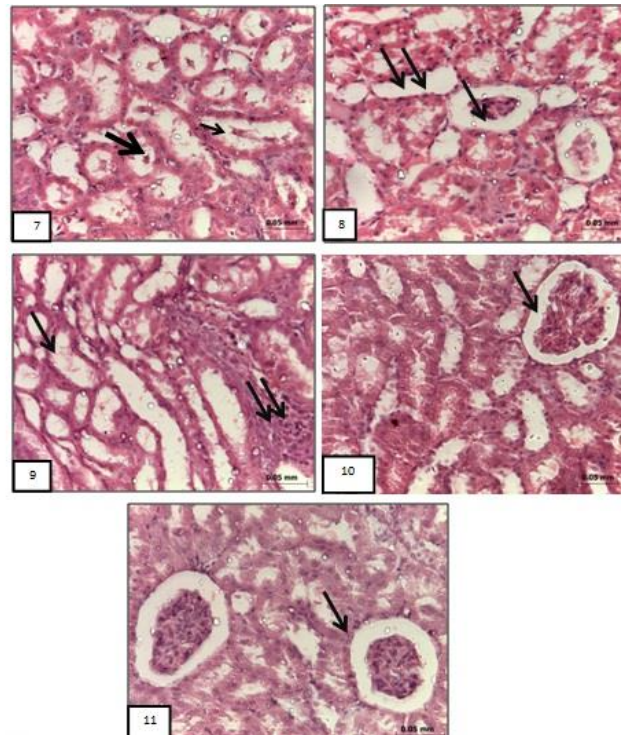


Figure (7) : Photomicrograph of kidney section from group 4, showing, renal tubular damage and , proteineous material in the renal tubules ( thick arrow), vacuolization in tubular cells(arrow); Figure (8) : Photomicrograph of kidney section from group 4( LEUK/MTX group), showing severe lose of kidney architecture, marked disturbance in glomeruli with strong inflammatory infiltration Glomerulosclerosis(arrow) , renal tubular (double arrows); Figure (9) : Photomicrograph of kidney section from group 5(LEUK/ MTX/MSCs group), showing a moderate degree of improvement glomerular damage with minimal vacuolization(arrow) in tubular cells and mild inflammatory infiltration ( double arrows); Figure (10) : Photomicrograph of kidney section from group 5(LEUK/ MTX/MSCs group), showing moderate organized tubular and glomerular ( arrow); Figure (11) : Photomicrograph of kidney section from group 5(LEUK/ MTX/MSCs group), showing a good degree of improvement glomerular damage(arrow) .Nearly to normal kidney architecture was observed (H&E X 400).

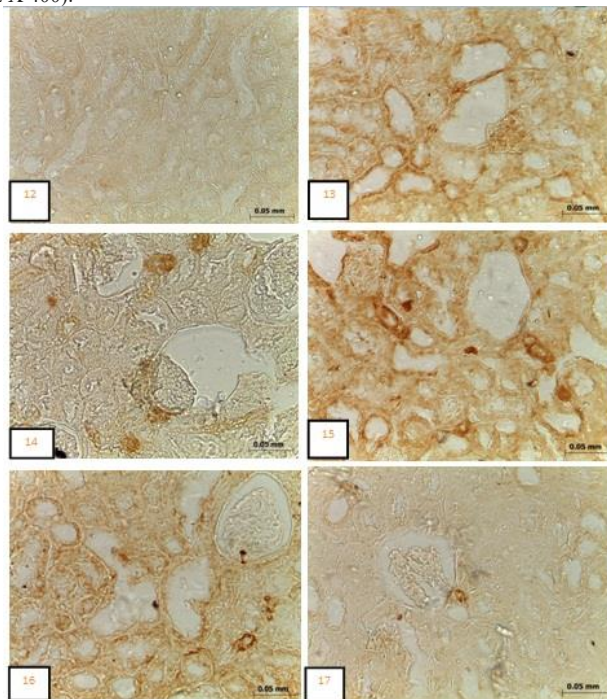
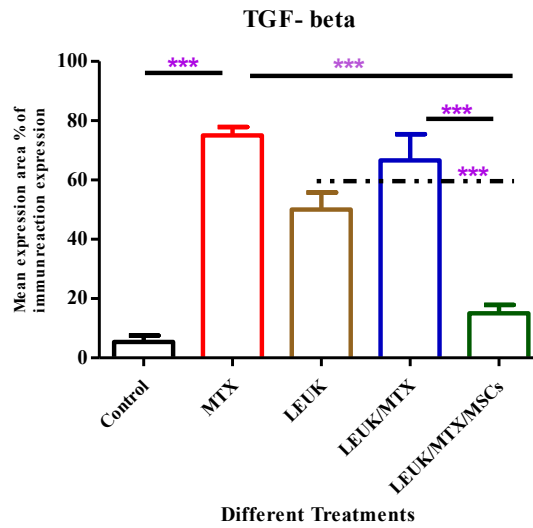


Figure (12) : Photomicrograph of normal kidney section from group 1(control group), showing the normal distribution of transforming growth factor  $\beta$ 1 (TGF- $\beta$ 1) expression in kidney tissue; Figure (13) :Photomicrograph of kidney section from group 2(MTXgroup), showing intense reaction distribution of transforming growth factor  $\beta$ 1 (TGF- $\beta$ 1) expression in kidney tissue ; Figure (14) : Photomicrograph of kidney section from group 3,( LEUKgroup), showing intense reaction distribution of transforming growth factor  $\beta$ 1 (TGF- $\beta$ 1) expression in kidney tissue; Figure (15) : Photomicrograph of kidney section from group 4 (LEUK/MTX group), showing very intense reaction distribution of transforming growth factor  $\beta$ 1 (TGF- $\beta$ 1) expression in kidney tissue ; Figure (16) : Photomicrograph of kidney section from group 4(LEUK/MTX group), showing very intense reaction distribution of transforming growth factor  $\beta$ 1 (TGF- $\beta$ 1) expression in kidney tissue (Figure (17) : Photomicrograph of kidney section from group 5(LEUK/ MTX/MSCs group), showing near normal distribution of transforming growth factor  $\beta$ 1 (TGF- $\beta$ 1) expression in kidney tissue (TGF- $\beta$ 1- immunostaining,x400).



Figure(18): Data are represented as means  $\pm$  SD where \*\*\*  $P \leq 0.001$  using GraphPad Prism V.5 SAN DIEGO, CA, USA where student t-test where applied to compare the different groups

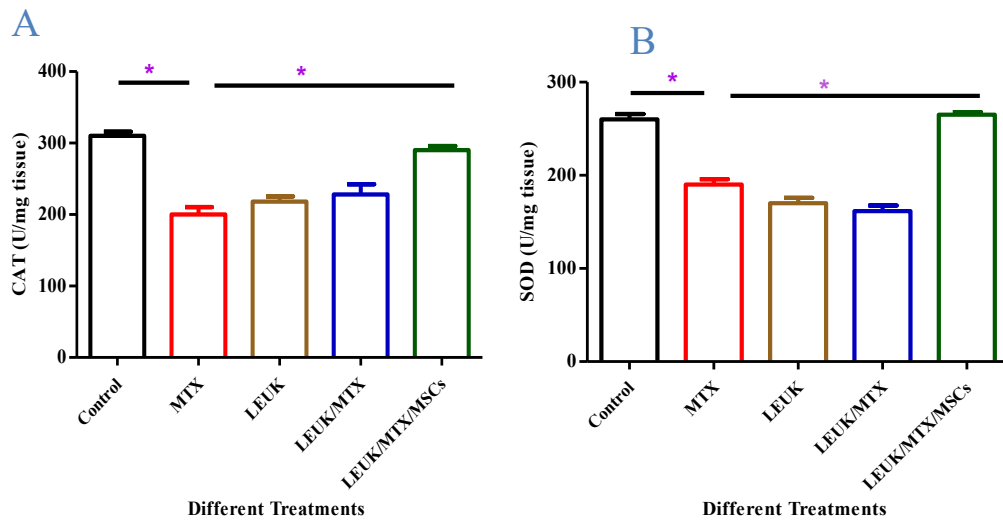


Figure (19): Impact of MSCs on the levels of oxidative enzymes markers in the renal tissues of experimental leukemia rats. n = 3 rats/group. Data are represented as mean  $\pm$  SD. (\*) considered as significant at  $p < 0.05$  (A) Catalase; (B) SOD.

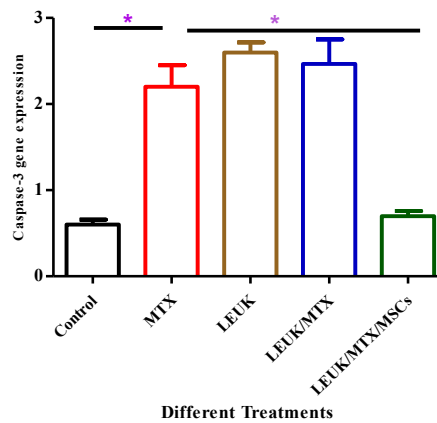


Figure (20): Impact of MSCs on the apoptotic gene markers (caspase-3-) in the renal tissues of experimental leukemia rats. n = 3 rats/group. Data are represented as mean  $\pm$  SD. (\*) considered as significant at  $p < 0.05$ .



## DISCUSSION

An odorless yellow to orange-brown crystalline powder is methotrexate. It is a chemotherapeutic medication that prevents the production of DNA and RNA. A folate derivative called MTX blocks numerous nucleotide synthesis-related enzymes. Both cell division and inflammation are suppressed as a result of this inhibition. Methotrexate is frequently used to treat arthritic inflammation and to limit cell development in neoplastic disorders such as breast cancer and non-Hodgkin's lymphoma because of these properties. MTX is a widely used medication that is utilized to treat a variety of autoimmune disorders at moderate dosages as well as malignancies at high doses, mostly due to its effects on inflammation and proliferation [23, 24]. By inhibiting the tetrafolate enzyme, the anti-metabolite pharmacological property of MTX is able to impede cell metabolism, stopping the creation of protein, DNA, RNA, and adenosine triphosphate. Cell death arises from this, and cell regeneration is difficult [25]. Its medicinal and harmful effects are both caused by this mechanism. The amount and frequency of delivery affect how hazardous MTX is in humans. Damage to the kidneys, liver, and gastrointestinal system are frequent side effects. One frequent factor that limits the therapeutic usage of MTX has been identified as renal impairment caused by the drug [26].

There are two pathways that contribute to the renal damage caused by MTX. The first mechanism involves the direct precipitation of MTX and its metabolite in the renal tubule lumen, which causes necrosis. Oxidative damage is a different mechanism that has been examined in a number of research [27, 28]. Increased reactive oxygen

species (ROS) as a result of MTX causes tissue damage [29].

It is widely recognised that ROS play significant regulatory roles in the organism under normal physiological settings [30–32]. However, when ROS production is unchecked, they interact with biomolecules and cause oxidative changes. The present study clarified the therapeutic function of (BM-MSCs) MCs in protecting against renal damage brought on by MTX in rats. In the current study, MTX treatment resulted in several histopathological changes in the kidney of albino rats, including renal tubular damage, protein-containing material in the renal tubules, glomerular damage, renal corpuscles with obscured Bowman's space, dilatation and congestion of the peritubular vessels, severe loss of kidney architecture, and marked disturbance in glomeruli with strong inflammatory infiltration and Glomerulosclerosis. Numerous theories on the processes behind the toxicity of MTX have been put forth, including the participation of oxidative stress, inflammation, and apoptosis [33]. Because MTX toxicity causes an increase in NOx in the tissues, peroxynitrite radicals are produced, which harm cells [34]. The oxidative stress brought on by the MTX treatment is consistent with earlier research [35].

The current study supports Vardi et al.'s [36] findings that oxygen radicals and hydrogen peroxides have been linked to the myriad of MTX side effects. These free radicals cause cell damage by attaching to cellular macromolecules, particularly membrane lipids, which releases ALT and AST from the cells into the serum. By inducing DNA fragmentation and denaturation, which are crucial for the start of apoptosis, the

increased oxidative stress may alter the shape and structure of the nucleus [37]. Oxidative stress serves as a marker for the harm caused when the ratio of oxidants to antioxidants shifts in favor of oxidants. Many pathological alterations leading to cellular damage occur if the delicate balance between oxidants and anti-oxidants in tissues cannot be maintained. The hallmarks of MTX toxicity are oxidative stress or oxidative cellular damage with its combination of free radical production and severe lipid peroxidation [38].

According to the findings of the current study, mice treated with MTX for leukaemia showed a considerable rise in TGF $\beta$ -1 in the BIL/MTX group compared to the control group. The stimulation of TGF $\beta$ -1, the most potent profibrotic cytokine, may be one of the probable pathways behind methotrexate-induced kidney fibrosis [39]. As a result, increasing vascular inflammation and fibrosis have been linked to inflammatory cells, pro-inflammatory cytokines, and profibrotic growth factors in the etiology of progressive renal disease [40].

TGF- $\beta$ , which has three isoforms (TGF  $\beta$  -1, TGF  $\beta$  -2, and TGF  $\beta$  -3) and primarily affects fibroblasts, mesangial cells, and tubular cells, is often recognized for its function in fibrosis [41]. Numerous cell types express and release TGF  $\beta$  - after damage [42]. TGF  $\beta$  - also has significant effects on immune cell signaling, tissue healing, stem cell differentiation, and embryonic development [43]. Renal tissue, monocyte and macrophage populations, lymphocytes, and platelets all exhibit high levels of TGF  $\beta$  - expression [44]. TGF- $\beta$  expression in renal pathology promotes remodeling of the extracellular matrix (ECM) and growth of pro-

fibrotic cell types such fibroblasts and myofibroblasts [45, 46]. In actuality, renal tubular cell autophagy and consequent fibrosis are brought on by TGF- $\beta$  overexpression under dormant circumstances [47]. TGF $\beta$ -RII is specifically deleted in PT cells to lessen damage and apoptosis, while AKI increases TGF- $\beta$  signaling in mice [48]. TGF- $\beta$  activity is extremely complicated in nature and, depending on the illness state, can either be advantageous or harmful. Therefore, it is yet unclear if therapeutic intervention with TGF- will be effective in reducing inflammation and fibrosis [49].

The majority of the previously mentioned alterations in the renal tissue were almost completely absent when kidney sections from group 5 (the LEUK/MTX/MSCs group) were examined in the current study. The renal tissue, which contains Malpighian corpuscles and renal tubule cells, appears to be more or less similar to that described in the control rats. MSCs can locate injured renal tissue locations and settle there. The process by which MSCs are transferred to wounded tissues is known as homing. According to Lin et al.'s research [50], administering MSCs to the ischemic kidney improved renal function, accelerated the mitogenic response, and decreased cell death. Additionally, MSCs are therapeutic against renal tissue damage and an increase in iNOS expression brought on by hypoxia, according to Ibrahim and AbdEl-Latief [51].

MSCs may be effective in the therapy of idiopathic pulmonary fibrosis (IPF) because they exhibit immunomodulatory, anti-inflammatory, and maybe antifibrotic capabilities, according to preclinical research [52].

There are Different models of MSCs treatment [53, 54]. MSCs exhibited the capacity to go to wounded areas and release a variety of paracrine factors, which in turn controlled endothelial and epithelial permeability and reduced lung inflammation [55]. Additionally, according to Zakaria et al. [56], MSCs were found in lung tissues and caused downregulation in inflammatory and coagulation markers in MTX-induced lung injury rats.

Examining kidney sections from group 5 (the LEUK/MTX/MSCs group) in the current investigation revealed that the distribution of TGF- $\beta$  1 expression in the kidney was comparable near normal. Additionally, Park et al., [57] Even though it has previously been noted that MSCs lower inflammatory mediator levels like IL-4 and TGF- $\beta$  1. We contend that stem cells' antiapoptotic benefits are mostly due to their antioxidant capacity rather than their anti-inflammatory properties. In fact, it is widely believed that MSCs exercise their immunomodulatory effects through promoting the release of cytokines like TGF- $\beta$  1 [58, 59].

According to Qiming et al. [60], 20% to 30% of patients do not react to MTX, and it causes a number of side effects. Therefore, it is critical to improve the therapeutic efficacy of MTX while lowering its negative effects. Mesenchymal stem cells (MSCs) were found to be involved in tissue regeneration, immunoregulation, and anti-inflammation in recent investigations. In present work the renal tissue of the MTX, LEUK, and LEUK/MTX rats, the levels of antioxidants like SOD and CAT were considerably reduced, but the injection of MSCs boosted these antioxidant enzymes in accordance with Gad et al.'s work [61]

revealed similar alterations in the oxidant and antioxidant profiles. The focus of the current investigation was on Caspase-3's crucial function in apoptosis. Besides, as a promoter and end effector in the apoptotic cascade, caspase-3 which has been regulated by MSCs in the present study and plays a significant part. Bax and caspase-3, which are pro-apoptotic proteins, may be upregulated by ROS to start cell death [62].

## CONCLUSIONS

The findings reported in the present context indicate that BM-MSCs act as antioxidant, antiapoptotic, and antifibrotic agents in MTX-induced rat renal fibrosis.

## REFERENCES

1. **Chawla LS, Eggers PW, Star RA, Kimmel PL:** Acute kidney injury and chronic kidney disease as interconnected syndromes. *N Engl J Med* 371(1):58–66, 2014.
2. **Abdel Aziz MT, Atta HM, Mahfouz S, Fouad HH, Roshdy NK, Ahmed HH, Rashed LA, Sabry D, Hassouna AA, Hasan NM:** Therapeutic potential of bonemarrow-derived mesenchymal stem cells on experimental liver fibrosis. *CLINBIOCHEM* 40: 893-899, 2007.
3. **Ding DC, Shyu WC, Lin SZ:** Mesenchymal stem cells. *Cell Transplant* 20(1):5–14, 2011
4. **Yang S, Piao J, Jin L, Zhou Y:** Does pretreatment of bonemarrow mesenchymal stem cells with 5-azacytidine or double intravenous

- infusion improve their therapeutic potential for dilated cardiomyopathy? *Med Sci Monit Basic Res* 19:20–31, 2013
- 5. Yang JD, Cheng-Huang, Wang JC, Feng XM, Li YN, Xiao HX:** The isolation and cultivation of bone marrow stem cells and evaluation of differences for neural-like cells differentiation under the induction with neurotrophic factors. *Cytotechnology* 66(6):1007-19, 2014.
- 6. Bhaskar B, Mekala NK, Baadhe RR, Rao PS:** Role of signaling pathways in mesenchymal stem cell differentiation. *Curr Stem Cell Res Ther* 9(06):508–512, 2014
- 7. Oh JY, Ko JH, Lee HJ, et al:** Mesenchymal stem/stromal cells inhibit the NLRP3 inflammasome by decreasing mitochondrial reactive oxygen species. *Stem Cells* 32(06):1553–1563, 2014.
- 8. Sangiorgi B, Panepucci RA:** Modulation of immunoregulatory properties of mesenchymal stromal cells by toll-like receptors: potential applications on GVHD. *Stem Cells Int*, 943425, 2016.
- 9. Uzar, E., Koyuncuoglu, H.R., Uz, E. et al:** The Activities of Antioxidant Enzymes and the Level of Malondialdehyde in Cerebellum of Rats Subjected to Methotrexate: Protective Effect of Caffeic Acid Phenethyl Ester. *Mol Cell Biochem* 291, 63–68, 2006.
- 10. Chhabra P, Law AD, Suri V, Malhotra P, Varma S:** Methotrexate induced lung injury in a patient with primary CNS lymphoma: a case report. *Mediterr J Hematol Infect Dis* 4(1): e2012020, 2012.
- 11. Thomas, JA, Aithal, GP:** Monitoring liver function during methotrexate therapy for psoriasis: are routine biopsies necessary? *Am. J. Clin. Dermatol* 6(6):357-63, 2005.
- 12. Wollima U, Stander K, Barta U:** Toxicity of methotrexate treatment in psoriasis and psoriatic arthritis-short- and long-term toxicity in 104 patients. *Clin. Rheumatol* 20(6):406-10, 2001.
- 13. Padeh S, Sharon N, Schiby G, Rechavi G, Passwell JH:** Hodgkin's lymphoma in systemic onset juvenile rheumatoid arthritis after treatment with low dose methotrexate. *J Rheumatol* 24(10):2035-7, 1997.
- 14. Aytac S, Yetgin S, Tavit B:** Acute and long-term neurologic complications in children with acute lymphoblastic leukemia. *Turk. J. Pediatr* 48(1):1-7, 2006.
- 15. Chen YX, Mao YY, Xie X:** Efficacy and side effects of methotrexate in the treatment of ectopic pregnancy. *Zhonghua Fu Chan Ke Za Zhi* 38(12):749-51, 2003.
- 16. Siegel CA, Sands BE:** Review article: practical management of inflammatory bowel disease patients taking immunomodulators. *Aliment. Pharmacol. Ther* 22(1):1-16, 2005.
- 17. Fialho D, Chan YC, Allen DC, Reilly MM, Hughes RA.** Treatment of chronic inflammatory demyelinating polyradiculoneuropathy with

- methotrexate. *J. Neurol. Neurosurg. Psychiatry* 77(4):544-7, 2006.
- 18. Şen HS, Şen V, Bozkurt M, Türkçü G, Güzel A, Sezgi C, Abakay Ö, Ibrahim K.** Carvacrol and pomegranate extract in treating methotrexate-induced lung oxidative injury in rats. *Med Sci Monit* 20, 1983-1990, 2014.
- 19. Olufemi, A.O. Terry, O.J. Kola:** Anti-leukemic and immunomodulatory effects of fungal metabolites of *Pleurotus pulmonarius* and *Pleurotus ostreatus* on benzene induced leukemia in Wistar rats. *Korean J Hematol* 47 (1): 67–73, 2012.
- 20. Morigi M, Introna M, Imberti B, Corna D, Abbate M, Rota C, Rottoli D, Benigni A, Perico N, Zoja C, Rambaldi A, Remuzzi A. Remuzzi G:** Human bone marrow mesenchymal stem cells accelerate recovery of acute renal injury and prolong survival in mice. *Stem Cells* 26, 2075-2082, 2008.
- 21. Bancroft J, Gamble MA:** Theory and practice of histological techniques 6<sup>th</sup> ed Churchill Livingstone: New York, London 165-175, 2007.
- 22. Cizkova K, Foltynkova T, Gachechiladze M, Tauber Z:** Comparative Analysis of Immunohistochemical Staining Intensity Determined by Light Microscopy, ImageJ and QuPath in Placental Hofbauer Cells. *Acta Histochem Cytochem* 54(1):21-29, 2021.
- 23. Wani FA, Ibrahim MA, Ameen SH, Farage AE, Ali ZA, Saleh K, Farag MM, Sayeed MU, Alruwaili MAY, Alruwaili AHF, Aljared AZA, Galhom RA:** Platelet Rich Plasma and Adipose-Derived Mesenchymal Stem Cells Mitigate Methotrexate-Induced Nephrotoxicity in Rat via Nrf2/Ppar $\gamma$ /HO-1 and NF-Kb/Keap1/Caspase-3 Signaling Pathways: Oxidative Stress and Apoptosis Interplay. *Toxics* 11(5):398, 2023.
- 24. Widemann BC, Balis FM, Kempf-Bielack B, et al:** High-dose methotrexate-induced nephrotoxicity in patients with osteosarcoma. *Cancer* 100(10): 2222–2232, 2004.
- 25. Dalaklioglu S, Genc GE, Aksoy NH, et al.** Resveratrol ameliorates methotrexate-induced hepatotoxicity in rats via inhibition of lipid peroxidation. *Hum Exp Toxicol* 32(6): 662–671, 2013.
- 26. Miyazono Y, Gao F and Horie T:** Oxidative stress contributes to methotrexate-induced small intestinal toxicity in rats. *Scand J Gastroenterol* 39(11): 1119–1127, 2004.
- 27. Tabassum H, Parvez S, Pasha ST, et al:** Protective effect of lipoic acid against methotrexate-induced oxidative stress in liver mitochondria. *Food Chem Toxicol* 48(7): 1973–1979, 2010.
- 28. Babiak RM, Campello AP, Carnieri EG, et al:** Methotrexate: pentose cycle and oxidative stress. *Cell Biochem Funct* 16(4): 283–293, 1998.
- 29. Vardi N, Parlakpınar H, Ates B, et al:** The protective effects of *Prunus armeniaca*

- L(apricot) against methotrexate-induced oxidative damage and apoptosis in rat kidney. *J PhysiolBiochem*69(3): 371–381, 2013.
- 30. Lin MT, Beal MF:** Mitochondrial dysfunction and oxidative stress in neurodegenerative diseases. *Nature*443(7113):787–795, 2006.
- 31. Halliwell B., Gutteridge JMC:** Free Radicals in Biology and Medicine. 4th. Oxford, UK: Clarendon Press; 2007.
- 32. Valko M, Leibfritz D, Moncol J, Cronin MTD, Mazur M, Telser J:** Free radicals and antioxidants in normal physiological functions and human disease. *International Journal of Biochemistry and Cell Biology*39(1):44–84, 2007.
- 33. Ali N, Rashid S, Nafees S, Hasan SK, Sultana S:** Beneficial effects of chrysin against methotrexate-induced hepatotoxicity via attenuation of oxidative stress and apoptosis. *Mol Cell Biochem*385(1-2):215–223, 2014.
- 34. Abdel-Raheem IT, Khedr NF:** Renoprotective effects of montelukast, a cysteinyl leukotriene receptor antagonist, against methotrexate-induced kidney damage in rats. *NaunynSchmiedebergs Arch Pharmacol*.387(4):341-53, 2014.
- 35. Morsy MA, Ibrahim SA, Amin EF, Kamel MY, Rifaai RA, Hassan MK:** Curcumin ameliorates methotrexate-induced nephrotoxicity in rats. *AdvPharmacolSci*2013:387071, 2013.
- 36. Vardi A, Bosviel R, Rabiau N, Adjakly M, Satih S, Dechelotte P:** Soy phytoestrogens modify DNA methylation of GSTP1, RASSF1A, EPH2 and BRCA1 promoter in prostate cancer cells. *In Vivo* 2010; 24: 393-400, 2010.
- 37. Prahalathan C, Selvakumar E, Varalakshmi P:** Protective effect of lipoic acid on adriamycin-induced testicular toxicity. *ClinicaChimicaActa*360: 160-166, 2005.
- 38. Jahovic N, Sener G, Cevic H, Ersoy Y, Arbak S, Yegen BC:** Amelioration of methotrexate-induced enteritis by melatonin in rats. *Cell BiochemFunct.* 22-28, 2004.
- 39. Meng P.M., Tang, J. Li, H.Y. Lan:** TGF-beta/Smad signaling in renal fibrosis. *Front. Physiol* 6, 82, 2015.
- 40. Qiao Y., Liu Z, Jiang Y., Yang W., Liu BH:** Preparation and renoprotective effects of carboxymethyl chitosan oligosaccharide on Adriamycin nephropathy. *Carbohydr. Polym*201, 347–356, 2018.
- 41. Lv W, Booz GW, Wang Y, Fan F, Roman RJ:** Inflammation and renal fibrosis: recent developments on key signaling molecules as potential therapeutic targets. *Eur J Pharmacol*820:65–76, 2018.
- 42. Bottinger EP:** TGF-beta in renal injury and disease. *SeminNephrol*27(3):309–20, 2007.
- 43. Santibanez JF, Quintanilla M, Bernabeu C:** TGF-beta/ TGF-beta receptor system and its role in physiological and

- pathological conditions. *ClinSci*121(6): 233–51, 2011.
44. **Branton MH, Kopp JB:** TGF-beta and fibrosis. *Microb Infect*1(15):1349–65, 1999.
45. **Boor P, Ostendorf T, Floege J:** Renal fibrosis: novel insights into mechanisms and therapeutic targets. *Nat Rev Nephrol*6(11):643–56, 2010.
46. **Gewin L, Vadivelu S, Neelisetty S, Srichai MB, Paueksakon P, Pozzi A, Harris RC, Zent R:** Deleting the TGF- $\beta$  receptor attenuates acute proximal tubule injury. *J Am Soc Nephrol*23(12):2001–11, 2012.
47. **Koesters R, Kaissling B, Lehir M, Picard N, Theilig F, Gebhardt R, Glick AB, Hahnel B, Hosser H, Grone HJ, Kriz W:** Tubular overexpression of transforming growth factor-beta1 induces autophagy and fibrosis but not mesenchymal transition of renal epithelial cells. *Am J Pathol*177(2):632–43, 2010.
48. **Gewin L, Zent R:** How does TGF-beta mediate tubulointerstitial fibrosis. *Semin Nephrol*32(3):228–35, 2012.
49. **Laurence MB, Jeremie M, Lever AA:** Renal Inflammation and Fibrosis: A Double-edged Sword. *Journal of Histochemistry&Cytochemistry*67(9):663–681, 2019.
50. **Lin X, Jiang C, Luo Z, Qu S:** Protective effect of erythropoietin on renal injury induced in rats by four weeks of exhaustive exercise. *BMC Nephrol*14:130, 2013.
51. **Ibrahim A, AbdEl-Latief A:** The therapeutic effect of mesenchymal stem cells on kidney and iNOS expression in hypoxic male rats. *CienciaeTeenicaVitivinicola*32, 10, 2017.
52. **Argyrios TRT, Theodoros K, Kantha M, Ioanna N, Vasilis A, Demosthenes B, Marilyn K:** Glassberg: Mesenchymal Stem Cells for the Treatment of Idiopathic Pulmonary Fibrosis, 2018.
53. **Zhang R, Liu Y, Yan K, Chen L, Chen X, Li, P, Chen F, Xiao-Dan J:** Antiinflammatory and immunomodulatory mechanisms of mesenchymal stem cell transplantation in experimental traumatic brain injury. *J NEUROINFLAMM*10, 871, 2013.
54. **Wang B, Wu S, Wang T, Ma Z, Liu K:** Bone Marrow-Derived Mesenchymal Stem Cells-Mediated Protection Against Organ Dysfunction in Disseminated Intravascular Coagulation Is Associated with Peripheral Immune Responses. *J Cell Biochem*118, 3184–3192, 2017.
55. **Li X, Yue S, Luo Z:** Mesenchymal stem cells in idiopathic pulmonary fibrosis. *Oncotarget*8, 102600–102616, 2017.
56. **Zakaria NH, Nashwa AE, Sahar SA, Laila AR:** Bone Marrow Mesenchymal Stem Cells Regulate Coagulation and Inflammation Together in Methotrexate Induced Lung Injury Rat Model. *Brazilian Archives of Biology and Technology*, 2019.

57. **Park HK, Cho KS, Park HY, Shin DH:** Adipose-derived stromal cells inhibit Allergic airway inflammation in mice. *Stem Cells Dev*19(11):1811–1818, 2010.
58. **Melief SM, Zwaginga JJ, Fibbe WE, Roelofs H:** Adipose tissue-derived multipotent Stromal cells have a higher immunomodulatory capacity than their bone marrow-derived counterparts. *Stem Cells Transl Med*2(6):455–463, 2013.
59. **Haddad R, Saldanha-Araujo F:** Mechanisms of T-cell immunosuppression by mesenchymal stromal cells: what do we know so far? *Biomed Res Int*2014: 216806, 2014.
60. **Qiming Z, Jiayi D, Xuesi Z, Xiaoning H, Dongdong F, Yan J, Bei L, Fang J:** Mesenchymal Stem Cells Enhance Therapeutic Effect and Prevent Adverse Gastrointestinal Reaction of Methotrexate Treatment in Collagen-Induced Arthritis. *Hindawi Stem Cells International* 8850820, 12, 2021.
61. **Gad AM, Hassan WA, Fikry EM.** Significant curative functions of the mesenchymal stem cells on methotrexate-induced kidney and liver injuries in rats. *J. Biochem. Mol. Toxicol* 31: e21919, 2017.
62. **Rahnavard M, Hassanpour M, Ahmadi M, Heidarzadeh M, Amini H, Javanmard MZ, Nouri M, Rahbarghazi R, Safaie N.** Curcumin ameliorated myocardial infarction by inhibition of cardiotoxicity in the rat model. *J. Cell. Biochem* 120:11965–11972, 2019.