

**RESEARCH ARTICLE****Effect of Choline and Vitamin E Co-Treatment on Hedgehog Pathway and Histopathological Changes in Heart and Kidney Associated with Obese Rats with Non-Alcoholic Fatty Liver Disease**

Omnia M. Abdelrahman\*, Medhat Fawzy, Mohamed F. Mansour

Department of Biochemistry and molecular biology, Faculty of Veterinary Medicine, Zagazig University, Zagazig 44511, Egypt.

\*Corresponding author Email: Omniamostafa6694@gmail.com

**Abstract**

An increase in the prevalence of non-alcoholic fatty liver disease (NAFLD) is related to an elevation in obesity worldwide. NAFLD is a prevalent liver disorder characterized by excessive lipid accumulation in hepatocytes, primarily induced by a high-fat diet (HFD). NAFLD not only affects the liver but also has significant implications for other organs, including the kidney and heart. The Hedgehog pathway, a critical signaling cascade involved in cellular processes and development, has emerged as a potential player in the pathogenesis of NAFLD and its extrahepatic effects. The purpose of the present study was to study impacts of choline and vitamin E co-treatment on the molecular and histopathological changes in heart and kidney in an obese rat model with NAFLD induced by a high-fat diet. Fifty albino rats were grouped into five equal groups randomly. The first one was kept as a control group the remaining four groups were treated as follows; G2: NAFLD, G3: NAFLD and received low dose of choline (25 mg/kg BW orally) and vitamin E (50 mg/kg BW orally), G4: NAFLD and received medium dose of choline (50 mg/kg BW orally) and vitamin E (100 mg/kg BW orally) and G5: NAFLD and received high dose of choline (100 mg/kg BW orally) and vitamin E (200 mg/kg BW orally). The results revealed that treating rats with varying dosages of choline and vitamin E significantly reduced Hhip, Ptch1, Smo and Gli1 hepatic mRNA expression in choline and vitamin E co-treated groups in comparison to NAFLD group and histologically displayed ameliorative consequences on kidney and heart tissues. In conclusion, choline and vitamin E co-treatment relieves the molecular and histological consequences of NAFLD in rats, with dose dependent manner.

**Keywords:** NAFLD, Hedgehog pathway, Choline, Vitamin E.**Introduction**

Obesity and non-alcoholic fatty liver disease (NAFLD) are closely associated conditions. Obesity is defined as an excess body fat accumulation usually resulting from an imbalance between calorie intake and metabolic rate, characterized by a body mass index (BMI)  $\geq 30$  kg/m<sup>2</sup> and up to 80% of NAFLD patients are obese [1, 2]. Obesity causes stress on several metabolic organs including the liver, heart, and kidney. In obesity, adipose tissue becomes hypertrophic and dysfunctional leading to an increase in the release of free fatty acids into the bloodstream which taken up

by the liver, promoting macrophage infiltration and production of adipokines such as tumor necrosis factor alpha (TNF $\alpha$ ), interleukin-6 (IL-6), all of which encourage the development of NAFLD [3].

NAFLD has become a global health concern due to its rising prevalence and association with obesity, insulin resistance, and metabolic syndrome. NAFLD encompasses a spectrum of liver conditions, ranging from simple steatosis to non-alcoholic steatohepatitis (NASH), fibrosis, cirrhosis, and hepatocellular carcinoma [4]. However, NAFLD is not limited to liver pathology, as it exerts

systemic effects on extrahepatic tissues, including the kidney and heart [5].

The Hedgehog (Hh) pathway consists of essential components including Hedgehog ligands; Sonic Hedgehog, Indian Hedgehog, and Desert Hedgehog, transmembrane receptors; Patched and Smoothed, and downstream transcription factors; Gli proteins [6]. Normally, Hh signaling is inactive in the healthy adult liver. However, in NAFLD, the expression and activation of Hh genes are upregulated NAFLD [7]. In the absence of Hh signaling, Patched acts as a receptor for Hh ligands and inhibits the activity of Smoothed. This inhibition prevents the activation of downstream transcription factors, particularly Gli proteins, which function as suppressors of target gene expression. However, when Hedgehog ligands bind to Patched, it relieves the inhibitory effect on Smoothed. This activation of Smoothed sets off a series of intracellular signaling events, ultimately leading to the liberation of Gli proteins from their repressive state. Consequently, Gli proteins enter the nucleus where they influence the expression of target genes [8-10].

The Hh pathway plays a crucial role in embryonic development, tissue homeostasis, and regeneration. Down-regulation of the Hh pathway has been implicated in various diseases, including cancers and developmental disorders [10, 11]. Activation of the Hh pathway in hepatocytes has been associated with aberrant lipid metabolism and inflammation [10]. The activation of hepatic stellate cells and immune cells within the liver and differentiation into pro-inflammatory and pro-fibrotic phenotypes leads to the release of inflammatory cytokines, such as TNF- $\alpha$  and transforming growth factor-beta (TGF- $\beta$ ), and the production of extracellular matrix proteins, contributing to liver inflammation and fibrosis [12-14].

Choline, an essential nutrient, acts as lipotropic factor and plays a vital role in lipid metabolism, liver function, and cell membrane integrity [15, 16]. Choline deficiency has been implicated in the progression of NAFLD. Supplementation with choline or its derivatives has shown promise in ameliorating liver steatosis, inflammation, and fibrosis in experimental models and clinical studies [15, 17]. In addition, vitamin E, a fat-soluble antioxidant, it has antioxidant and anti-inflammatory properties [18]. It has been investigated as a therapeutic agent for NAFLD due to its ability to counteract oxidative stress and inflammation [19]. Vitamin E supplementation has shown beneficial effects in improving liver histology and biochemical markers in NAFLD [20]. In this experiment, we investigated the molecular and histopathological impacts of choline and vitamin E co-treatment (Chol. and Vit. E co-treat) in a rat model of NAFLD induced by a high-fat diet (HFD). We postulated that Chol. and Vit. E co-treat will synergistically ameliorate the expression of hepatic hedgehog pathway genes and have a positive histological effect on kidney and heart tissues in rats with HFD-induced NAFLD.

## Material and Method

### *Ethical approval*

All instructions and requirements have been followed in this study for handling and rearing the animals for the purpose of experimental design and research. The Animal Care and Use Committee (IACUC), Faculty of Veterinary Medicine, Zagazig University, Egypt, accepted this under approval number: ZU\_IACUC/2/F/54/2022.

### *Experimental animals*

Male albino rats (n=50), their weight ranged from 100 to 120 gm (Laboratory Animal Farm for scientific purpose, Faculty of veterinary Medicine, Zagazig University, Egypt). The animal

acclimatization endured a period of two weeks prior to the start of the experiment. In stainless steel cages with a twelve-hour light-dark cycle, sustained at suitable temperature and humidity, all experimental rats were kept along the experimentation.

### Chemicals

The Choline chloride 70% Liquid and Vitamin E (DL- $\alpha$ -Tocopherol) of 94% purity were delivered from Phytex Pharma Co., 6th October, Giza, Egypt.

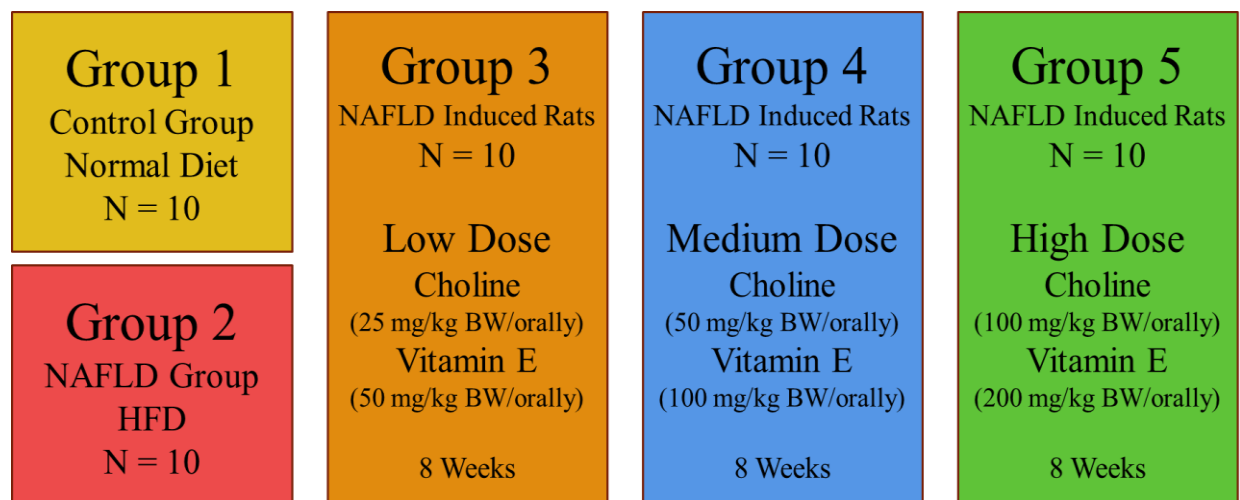
### Induction of obesity with NAFLD

Induction of obesity with NAFLD continues for 14 weeks, forty rats fed a

high fat diet (HFD), which consists of 20% fat, 20% protein, 48% carbohydrates, and 4% fiber [21].

### Experimental design

Fifty albino rats were grouped into 5 groups, each one 10 rats. The control group (G1) (10 rats) received a standard diet. Forty rats in other groups (G2, G3, G4, G5) induced NAFLD by HFD for 14 weeks then G3, G4 and G5 were received the treatment (Figure 1). The different doses of treatment were administered orally daily for a period of 8 weeks.



**Figure 1:** Experimental design of Choline and Vitamin E co-treatment of non-alcoholic fatty liver disease.

### Sampling

At the end of the experiment, which lasted for 24 weeks, animals were humanly euthanized. Kidney and heart tissues were fixed in neutral buffered formalin 10% for histopathological investigation, and liver tissues were kept in 1 ml Trizol and preserved at  $-80^{\circ}\text{C}$  until used for gene expression.

### Gene expression

The gene expression levels of the target genes were normalized to the

mRNA expression of the housekeeping gene GAPDH. Total RNA extraction from collected tissues and cDNA synthesis were carried out according to the manufacturer's instructions. Also, the RNA quality was assessed at A260/A280 ratio using NanoDrop Spectrophotometer following the manufacturer's guidelines. Then Real-time RT-PCR using SYBR Green with low ROX was implemented [22, 23] under optimized conditions (

*Table 1).*

**Table 1 :The applied real time Rt-PCR cycling conditions for Gene expression.**

s	Step	Temperature	Time
1	Initial denaturation	95°C	12 minutes
2	Denaturation (40 cycles)	95°C	20 seconds
3	Annealing	60°C	30 seconds
4	extension for 30 seconds	72°C	30 seconds

Oligonucleotide specific primers Hhip, Ptch-1, Smo, Gli-1 and Gapdh genes were created by Sangon Biotech; Beijing, China (Error! Reference source not found.). A melting curve analysis was performed post-PCR amplification and findings were presented as fold-changes equated to the control group using the  $2^{-\Delta\Delta CT}$  method [24].

**Table 2 : Oligonucleotide primer sequences for real-time PCR.**

Gene	Forward primer (5' → 3')	Reverse primer (5' → 3')	Product size/bp	GenBank accession number
Hhip	GCTCTTTGGTCCTGATGGCT	GCTGGTTGGTGCTGTTGAAG	191	NM_001191817.1
Ptch-1	TCCCCTCCTCCTCCTCTTTC	CTTGTTCTCCTCACCGACCC	192	NM_053566.3
Smo	TTCCTCATCCGAGGGGTCAT	ATTGATCTTGCTGGCTGCCT	87	NM_012807.1
Gli-1	CCTCCACCCAGTATCTCCA	ACAATTCCTGCTGCGACTGA	163	NM_001191910.1
Gapdh	GCATCTTCTTGTCAGTGCC	TACGGCCAAATCCGTTTACA	74	NM_017008.4

Hhip: hedgehog-interacting protein

Ptch-1: protein patched homolog 1

Smo: smoothened

Gli-1: glioma-associated oncogene homolog 1

Gapdh: glyceraldehyde-3-phosphate dehydrogenase

### **Histopathological technique**

Kidney and heart specimens were immersed in a 10% buffered neutral formalin solution and fixed for 48 hours. Afterward, they were dehydrated using increasing concentrations of ethyl alcohol, followed by clearing in xylene. Subsequently, the specimens were immersed in paraffin. Paraffin sections with a thickness of 5 microns were obtained using a microtome (Leica RM 2155, London, UK). To assess histopathological characteristics, the

sections were stained with hematoxylin and eosin (H&E) using standard protocols [25]. The lesions were evaluated using a semiquantitative manner and scored as follows: 0 (no observable histopathological alterations), 1 (rarely minor or localized alterations), 2 (multifocal alterations), and 3 (patchy or diffuse alterations) [26].

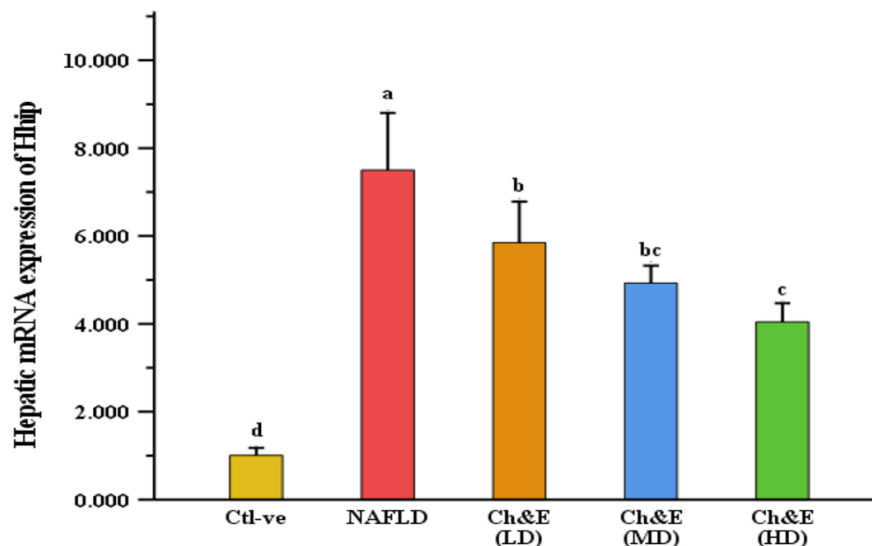
### **Statistical analysis**

The results were expressed as mean  $\pm$  SEM. To compare the different

parameters between groups, a one-way ANOVA was performed. If the ANOVA showed significant results, Duncan's multiple range test was conducted as a post hoc analysis to identify group differences. Statistical analysis was carried out using SPSS version 28, and a significant level of  $P \leq 0.01$  was considered statistically significant.

## Results

### *The influence of Chol. & Vit. E co-treat on the hepatic mRNA expression of Hhip in obese rats with NAFLD*



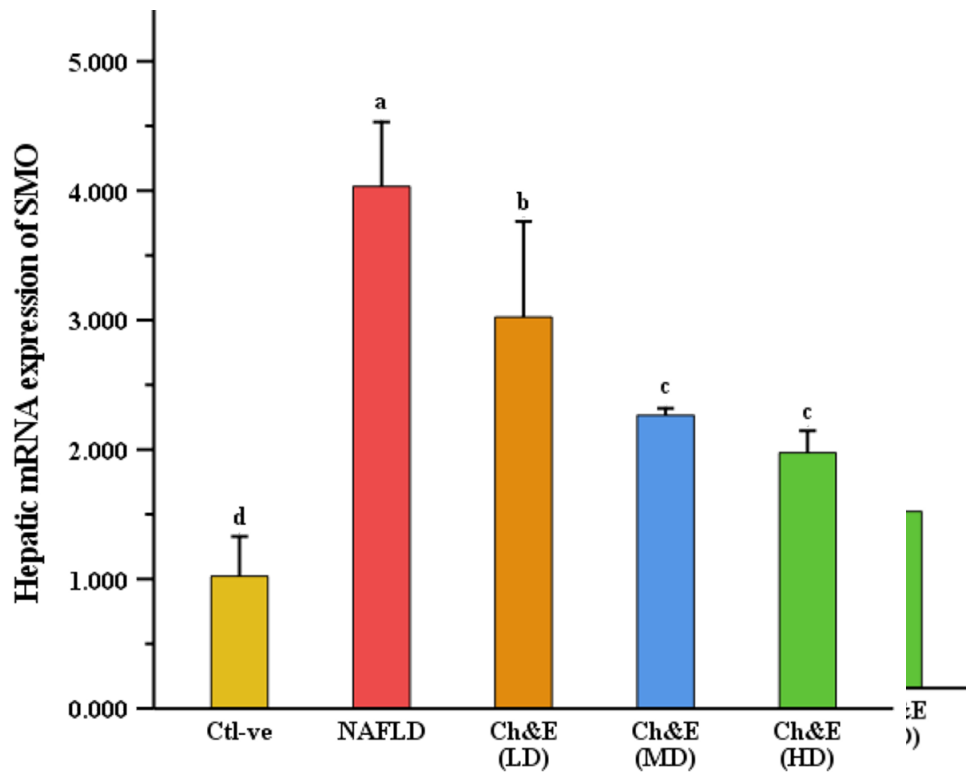
Error! Reference source not found.: The impact of Chol. & Vit. E co-treat on the hepatic mRNA expression of Hhip was assessed in obese rats with NAFLD induced by HFD. The values are presented as mean  $\pm$  SEM, with a sample size of 10 rats per group. Significant differences between means were denoted by different superscripts, indicating statistical significance at  $P \leq 0.01$ .

### *Effect of Chol. & Vit. E co-treat on the hepatic mRNA expression of Ptch1 in obese rats with NAFLD*

Hepatic mRNA expression of Ptch1 significantly ( $P \leq 0.01$ ) increased NAFLD group compared to control group. Furthermore, hepatic mRNA expression of Ptch1 significant ( $P \leq 0.01$ ) decreased

Significant ( $P \leq 0.01$ ) upregulation of Hhip was found in NAFLD group in comparison to control group. However, hepatic mRNA expression of Hhip exhibited significant ( $P \leq 0.01$ ) downregulation in Chol. & Vit. E co-treat groups in comparison to NAFLD group (**Error! Reference source not found.**).

in Chol. & Vit. E co-treat groups in comparison to NAFLD group (**Error! Reference source not found.**).

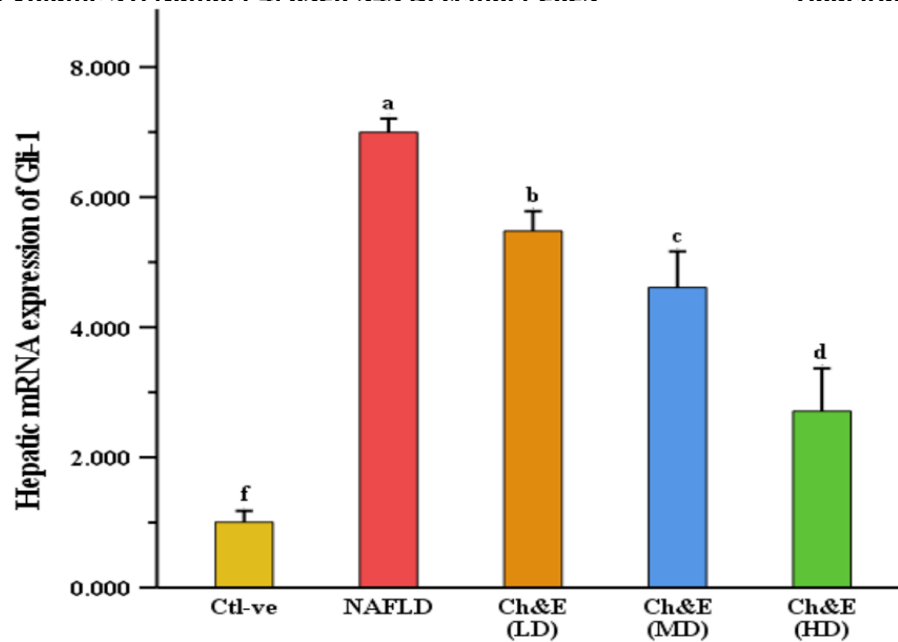


Error! Reference source not found.: The impact of Chol. and Vit. E co-treat on the hepatic mRNA expression of Ptch1 was assessed in obese rats with NAFLD induced by HFD. The values are presented as mean  $\pm$  SEM, with a sample size of 10 rats per group. Significant differences between means were denoted by different superscripts, indicating statistical significance at  $P \leq 0.01$ .

***Effect of Chol. & Vit. E co-treat on the hepatic mRNA expression of Smo in obese rats with NAFLD***

Hepatic mRNA expression Smo was significant ( $P \leq 0.01$ ) higher in the NAFLD group compared to the control

group. Furthermore, hepatic mRNA expression of Smo was significant ( $P \leq 0.01$ ) lower in the Chol. & Vit. E co-treat groups than in the NAFLD group (**Error! Reference source not found.**).

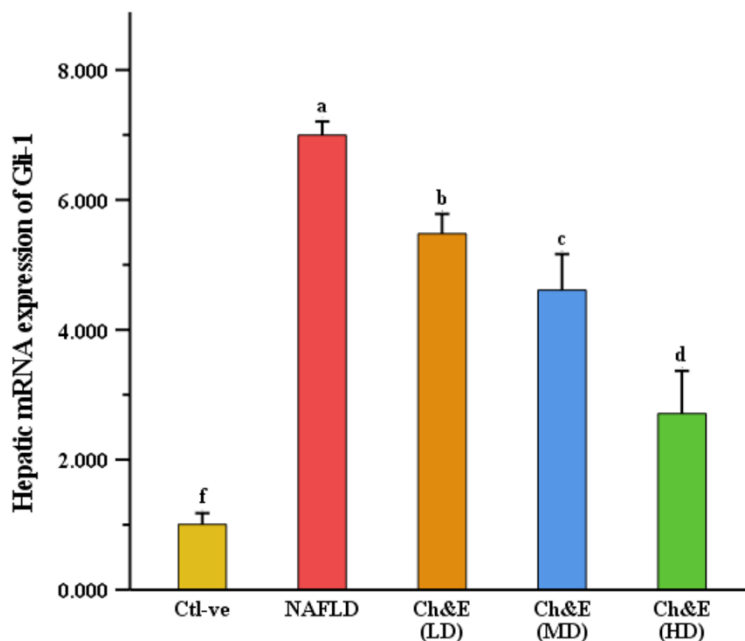


Error! Reference source not found.: The impact of Chol. & Vit. E co-treat on the hepatic mRNA expression of SMO was assessed in obese rats with NAFLD induced by HFD. The values are presented as mean  $\pm$  SEM, with a sample size of 10 rats per group. Significant differences between means were denoted by different superscripts, indicating statistical significance at  $P \leq 0.01$ .

***The influence of Chol. & Vit. E co-treat on the hepatic mRNA expression of Gli1 in obese rats with NAFLD***

Gli1 hepatic mRNA expression was significant ( $P \leq 0.01$ ) greater in the

NAFLD group than in the control group. Moreover, hepatic mRNA expression of Gli1 was significant ( $P \leq 0.01$ ) lower in the Chol. & Vit. E co-treat groups than in the NAFLD group (**Error! Reference source not found.**).



Error! Reference source not found.: The impact of Chol. & Vit. E co-treat on the hepatic mRNA expression of Gli-1 was assessed in obese rats with NAFLD induced by HFD. The values are presented as mean  $\pm$  SEM, with a sample size of 10 rats per group. Significant differences between means were denoted by different superscripts, indicating statistical significance at  $P \leq 0.01$ .

### *Histopathological findings*

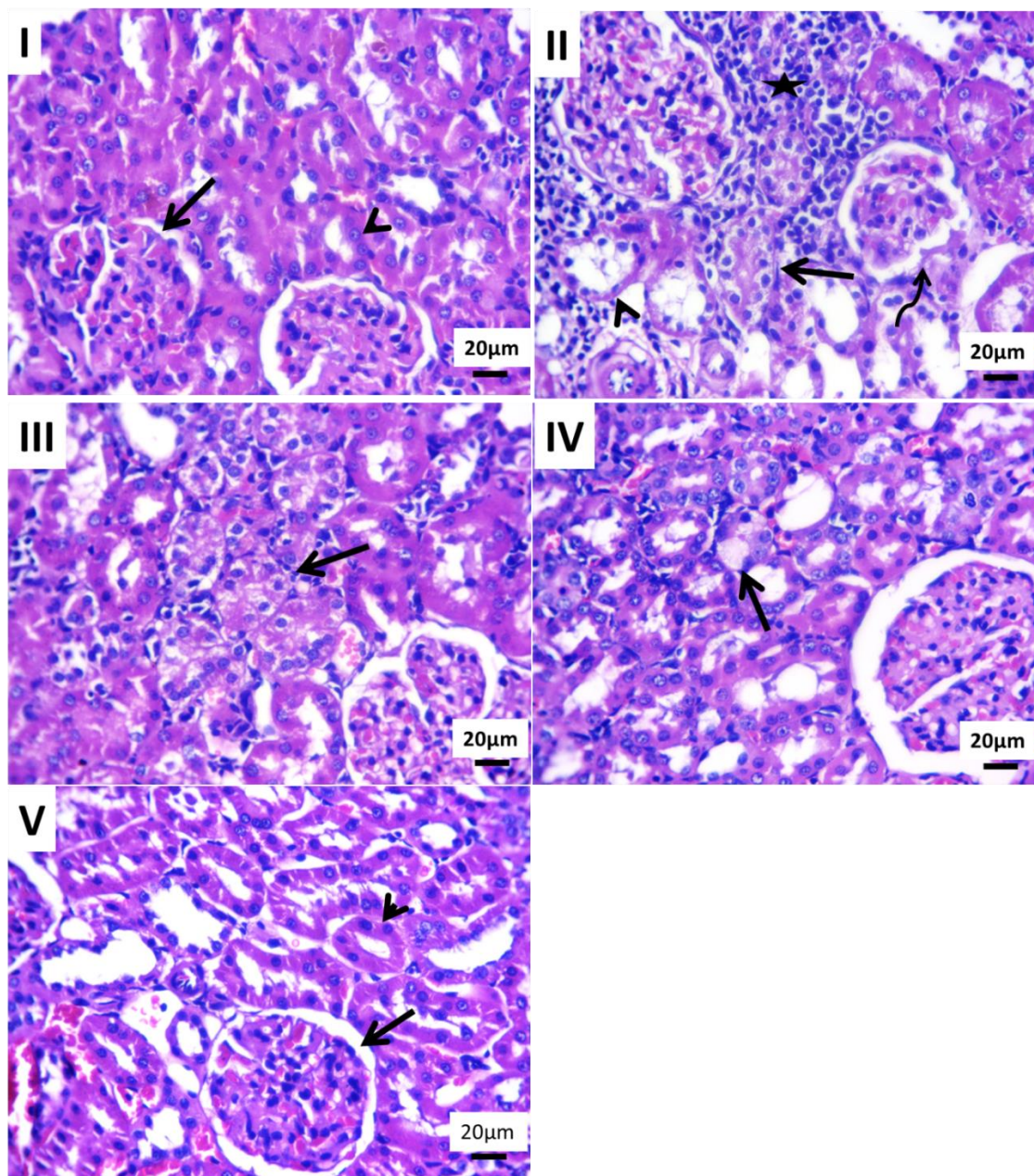
Regular histology of glomeruli and renal tubules was observed in kidney of group 1 and group 5 (Error! Reference source not found. I and V). While interstitial round cells infiltrations between degenerated and necrotic moderate number of renal tubular epithelium.as well, dilated some tubular lumina and shrinking in some glomerular tufts with periglomerular edema were commonly seen alterations in group 2 (Error! Reference source not found. II). Group 3 showed hydropic degenerated renal epithelium in a moderate number of renal tubules. In addition to, lobulated some glomeruli was seen. (Error! Reference source not found. III). While unicellular large vacuolated renal epithelium was demonstrated in group 4

(Error! Reference source not found. IV).

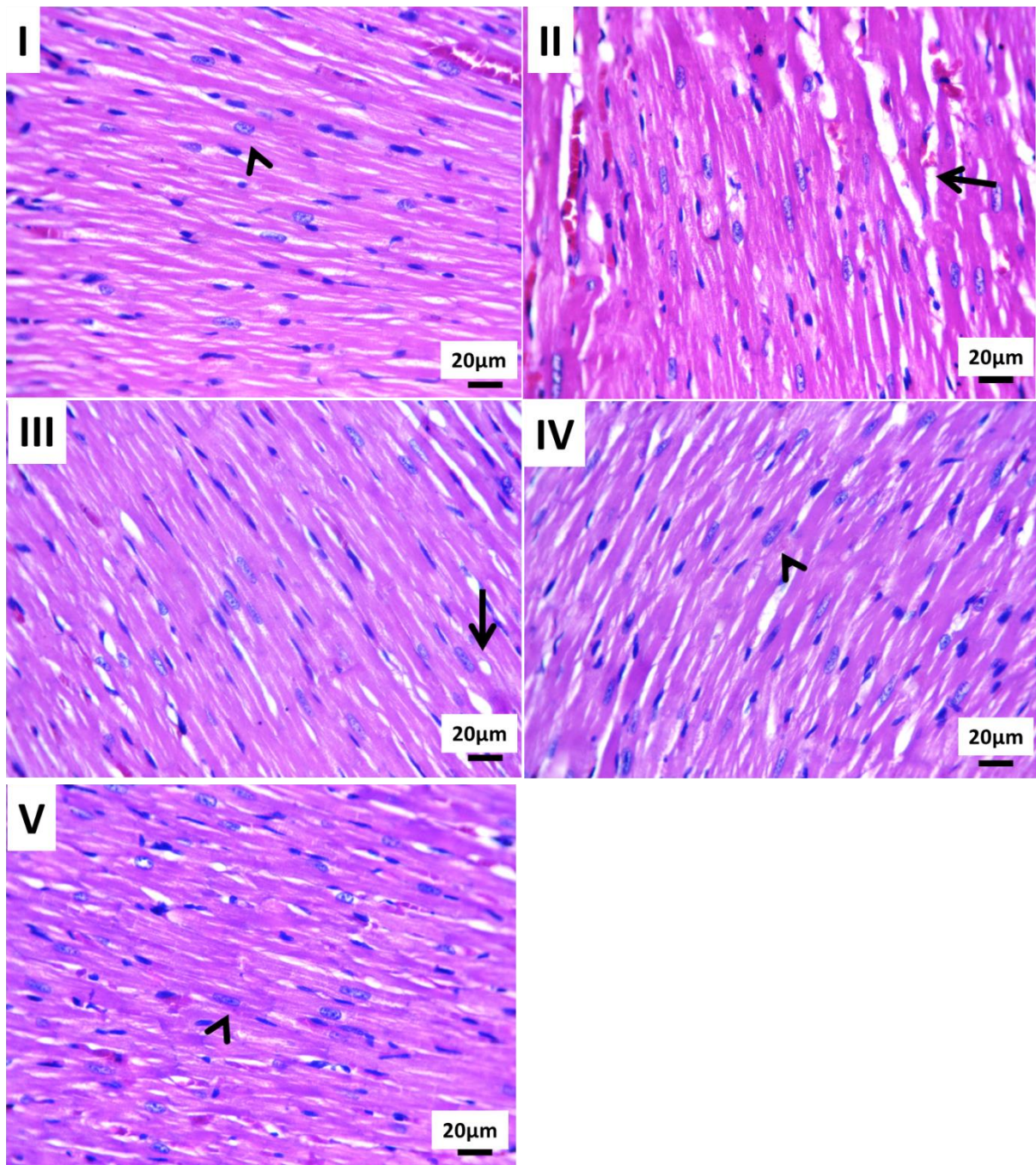
Heart showed normal histology of cardiac muscles in group 1 and group 5 (Error! Reference source not found. I and V). On the other hand, randomly distributed hyaline degenerated cardiomyocytes and dilated interstitial blood vessels were seen in group 2 (Error! Reference source not found. II). In group 3 revealed few numbers of small univacuolated muscle fibers (Error! Reference source not found. III). While group 4 showed maintain structures of branched striated cardiac muscle fibers with centrally located oval nuclei (Error! Reference source not found. IV). The lesions were graded using the following semiquantitative method: 0 indicates no discernible histopathological abnormalities, 1 indicates limited or



localized changes that were uncommon, 2 indicates patchy or widespread changes indicates multifocal changes, and 3 (Error! Reference source not found.).



Error! Reference source not found.: The impact of Chol. & Vit. E co-treated histological level of kidney in obese rats with NAFLD induced by HFD. Photomicrograph of H&E-stained sections from kidney showing: (I) Control group and (V) High dose of Chol. & Vit. E co-treat group: Both groups showed normal histology of glomeruli (arrow) and renal tubules (arrowhead). (II) Interstitial round cells infiltrations (star) between degenerated (arrow) and necrotic renal tubules (arrowhead) beside periglomerular edema (curved arrow) in NAFLD group. (III) Hydropic degenerated renal epithelium (arrow) in low dose of Chol. & Vit. E co-treat group. (IV) Uniccullular large vacuolated renal epithelium (arrow) in moderate dose of Chol. & Vit. E co-treat group. Scale bar 20µm.



Error! Reference source not found.: The impact of Chol. & Vit. E co-treated histological level of heart in obese rats with NAFLD induced by HFD. Photomicrograph of H&E-stained sections from heart showing: (I) Control group and (V) High dose of Chol. & Vit. E co-treat group: Both groups showed normal histology of cardiac muscles (arrowheads). (II) hyaline degenerated cardiomyocytes (arrow) and dilated interstitial blood vessels in NAFLD group. (III) small univacuolated muscle fibers (arrow) in low dose of Chol. & Vit. E co-treat group. (IV) maintain structures of branched striated cardiac muscle fibers with centrally located oval nuclei (arrowheads) in both moderate dose of Chol. & Vit. E co-treat group. Scale bar 20µm

**Table 3: Lesions grade of the severity extent in the renal and cardiac tissues Choline and Vitamin E co-treatment for NAFLD**

Organ	Lesions	Group				
		G1	G2	G3	G4	G5
kidney	Hydropic degenerative changes	0	3	1	1	0
	Necrotic tubules	0	2	0	0	0
	Lymphocytic infiltrates	0	2	1	0	0
	Dilated tubular lumina	0	1	0	0	0
	Shrinkage glomeruli	0	1	1	0	0
Heart	Hyaline degenerative changes	0	2	1	0	0

G1: control group

G2: NAFLD group

G3: low dose of choline and vitamin E co-treatment group

G4: medium dose of choline and vitamin E co-treatment group

G5: high dose of choline and vitamin E co-treatment group

## Discussion

In our previous investigation [27], we examined the potential benefits of combining choline and vitamin E in the treatment of NAFLD in rats and showed the synergistic effects of these two substances on various aspects of NAFLD, including liver function enzymes, lipid profile, antioxidant status, inflammatory cytokines, hepatic lipid metabolism-related genes and histopathological on liver tissue. Currently, the hepatic Hedgehog pathway was investigated as well as histopathological changes in kidney and heart for more understanding and comprehensive clarification of the ameliorative impact of choline and vitamin E on NAFLD.

Choline is a lipotropic factor, meaning it helps in the metabolism of fats in the liver, while vitamin E is an antioxidant that protects against oxidative stress [20, 28]. This study aimed to investigate whether combining these two substances could have a synergistic ameliorative effect on hedgehog pathway genes and positive effect histologically on kidney and heart tissues in rats induced by NAFLD.

The Hedgehog pathway comprises four key components: the ligand (hedgehog), the receptor (Patched), the signal transducer (Smoothed), and the effector transcription factor (Gli). During embryonic development, hedgehog signaling is important for cell differentiation. Disruption of hedgehog signaling has been implicated in the development of various cancers, including liver cancer [29, 30]. Hedgehog ligands are released from producing cells through three mechanisms: facilitated by the protein Dispatched, assembly in VLDL, or via exosomes [31]. Hedgehog signaling remains inactive in healthy adult liver. However, hedgehog signaling is activated in both human and mouse models of NAFLD [7, 32, 33].

Our study revealed significant upregulation of hedgehog pathway genes (Hhip, Ptch1, Smo, and Gli1) in the NAFLD group compared to the control group. Furthermore, in the groups treated with a combination of choline and vitamin E, there was a significant downregulation of Hhip, Ptch1, Smo, and Gli1 hepatic mRNA expression compared to the NAFLD group. The results suggest that this combination therapy has the potential to be an effective approach for the

treatment of NAFLD, particularly at higher doses. High fat diet induced NAFLD leads to increased expression of Hh pathway target genes, including Ptch1, Gli1, and Smo [34]. Sonic hedgehog (Shh) binds to Ptch1, relieving the inhibitory effect of Smo on hedgehog signaling and resulting in the activation of the Hh pathway and Gli transcription factor. In NAFLD, Shh derived from ballooned hepatocytes stimulates Hh signaling in hepatocytes, leading to the production of osteopontin, a protein involved in inflammation and fibrosis, which in turn promotes the accumulation of liver macrophages and the development of NAFLD [35]. Hh signaling is also activated in hepatic stellate cells, macrophages, and adipose tissues, contributing to the progression of NAFLD and insulin resistance [35, 36]. Activated Hh signaling in hepatic cells, including HSCs and immune cells, can induce an inflammatory response. It leads to the production of pro-inflammatory cytokines, such as TNF- $\alpha$  and IL-6, and chemokines that attract immune cells to the liver [37]. Whereas choline deficiency has been associated with the development and progression of NAFLD, characterized by the accumulation of fat in the liver, induced liver damage, inflammation, and altered lipid metabolism [15, 28] all of which could potentially affect the expression or activity of hedgehog pathway components, leading to alterations in hedgehog gene expression. Some studies have shown that choline deficiency can induce NAFLD and upregulate hedgehog signaling in certain tissues [38, 39]. Therefore, it is possible that choline supplementation may help normalize Hh signaling levels in the liver. Furthermore, vitamin E supplementation has shown some benefits in reducing liver inflammation, and oxidative stress NAFLD patients [19]. Vitamin E treatment decreased accumulation of Shh-

producing hepatocytes as well as Hh-regulated sequelae [40].

In our results, HFD caused changes in histological sections of kidney and heart in obese rats with NAFLD. In kidney, NAFLD group showed various alterations including interstitial round cell infiltrations, degenerated and necrotic renal tubular epithelium, dilated tubular lumina, and shrunken glomerular tufts with periglomerular edema. The different doses of Chol. & Vit. E co-treat groups showed improvement in kidney tissue especially the high dose of Chol. & Vit. E co-treat that exhibited normal kidney histology. In addition, in the heart histological sections, the NAFLD group exhibited randomly distributed hyaline degenerated cardiomyocytes and dilated interstitial blood vessels. The different doses of Chol. & Vit. E co-treat groups showed improvement in kidney tissue especially high-dose Chol. and Vit. E co-treat that showed normal cardiac muscle histology. HFD and obesity contribute to the development of NAFLD, renal dysfunction and cardiovascular diseases (CVD) through interconnected mechanisms. These mechanisms include lipid accumulation, hyperglycemia, inflammation, oxidative stress, dyslipidemia, and dysregulated adipokines. These factors increased prevalence and progression of NAFLD, CVD and impaired renal and liver function [5, 41-44]. Several studies have reported a connection between NAFLD, renal diseases, and CVD. NAFLD is an independent risk factor for CVD and impairs renal function via lipoprotein dysmetabolism, increases oxidative stress and decreases antioxidant enzymes, elevates inflammatory cells infiltration [5, 45, 46]

Besides a vital role in cell membrane integrity, acting as a methyl donor and lipotropic action of choline, it has antioxidant properties. choline supplementation and betaine, a derivative

of choline, reduced oxidative stress and the inflammatory response in mice [47-49] indicating that a high intake of choline protective against inflammation and related diseases such as NAFLD, CVD and improved renal function [50]. This demonstrates that choline plays a significant role in maintaining the proper histological integrity and functioning of renal and cardiac tissues. In addition, Vitamin E has been lowering the risk CVD and protect against cardiovascular complications in obesity patients [51]. Moreover, vitamin E plays a role in preventing and ameliorating kidney damage [52, 53]. In addition, vitamin E supplementation has shown beneficial effects in improving kidney and heart histology and biochemical markers such as decreased LDL, MDA levels and increased catalase, SOD activities [20].

### Conclusion

NAFLD is the most common chronic liver disease worldwide. Chol. & Vit. E co-treat alleviates hedgehog pathway genes (Hhip, Ptch1, Smo and Gli1) and histopathological effects in HFD-induced NAFLD in rats with a potential impact to the maximum dose of this combination. As a result, the synergistic combination of choline's lipotropic effects and antioxidant activities of vitamin E might be one prospective treatment strategy for NAFLD.

### Funding

The authors received no financial support for this research.

### References:

- [1] Li, C.; Zhang, H. and Li, X. (2020): The Mechanism of Traditional Chinese Medicine for the Treatment of Obesity. *Diabetes Metab Syndr Obes*, 13: 3371-3381.
- [2] Fan, J.G.; Kim, S.U. and Wong, V.W. (2017): New trends on obesity and NAFLD in Asia. *J Hepatol*, 67(4): 862-873.
- [3] Silva Figueiredo, P.; Carla Inada, A.; Marcelino, G.; Maiara Lopes Cardozo, C.; de Cassia Freitas, K.; de Cassia Avellaneda Guimaraes, R.; Pereira de Castro, A.; Aragao do Nascimento, V. and Aiko Hiane, P. (2017): Fatty Acids Consumption: The Role Metabolic Aspects Involved in Obesity and Its Associated Disorders. *Nutrients*, 9(10):1158.
- [4] Rojas, Y.A.O.; Cuellar, C.L.V.; Barron, K.M.A.; Arab, J.P. and Miranda, A.L. (2022): Non-alcoholic fatty liver disease prevalence in Latin America: A systematic review and meta-analysis. *Ann Hepatol*, 27(6): 100706.
- [5] Byrne, C.D. and Targher, G. (2015): NAFLD: a multisystem disease. *J Hepatol*, 62(1 Suppl): S47-64.
- [6] Yao, Q.; Liu, J.; Xiao, L. and Wang, N. (2019): Sonic hedgehog signaling instigates high-fat diet-induced insulin resistance by targeting PPARgamma stability. *J Biol Chem*, 294(9): 3284-3293.
- [7] Guy, C.D.; Suzuki, A.; Zdanowicz, M.; Abdelmalek, M.F.; Burchette, J.; Unalp, A.; Diehl, A.M. and Nash, C.R.N. (2012): Hedgehog pathway activation parallels histologic severity of injury and fibrosis in human nonalcoholic fatty liver disease. *Hepatology*, 55(6): 1711-1721.
- [8] Varjosalo, M. and Taipale, J. (2008): Hedgehog: functions and mechanisms. *Genes Dev*, 22(18): 2454-2472.
- [9] Kong, J.H.; Siebold, C. and Rohatgi, R. (2019): Biochemical mechanisms of vertebrate hedgehog signaling. *Development*, 146(10): dev166892.
- [10] Garg, C.; Khan, H.; Kaur, A.; Singh, T.G.; Sharma, V.K. and Singh, S.K. (2022): Therapeutic implications of sonic hedgehog pathway in metabolic

- disorders: Novel target for effective treatment. *Pharmacol Res*, 179: 106194.
- [11] Carballo, G.B.; Honorato, J.R.; de Lopes, G.P.F. and Spohr, T. (2018): A highlight on Sonic hedgehog pathway. *Cell Commun Signal*, 16(1): 1-15.
- [12] Chung, S.I.; Moon, H.; Ju, H.L.; Cho, K.J.; Kim, D.Y.; Han, K.H.; Eun, J.W.; Nam, S.W.; Ribback, S.; Dombrowski, F.; Calvisi, D.F. and Ro, S.W. (2016): Hepatic expression of Sonic Hedgehog induces liver fibrosis and promotes hepatocarcinogenesis in a transgenic mouse model. *J Hepatol*, 64(3): 618-27.
- [13] Omenetti, A.; Choi, S.; Michelotti, G. and Diehl, A.M. (2011): Hedgehog signaling in the liver. *J Hepatol*, 54(2): 366-373.
- [14] Wiering, L.; Subramanian, P. and Hammerich, L. (2023): Hepatic Stellate Cells: Dictating Outcome in Nonalcoholic Fatty Liver Disease. *Cell Mol Gastroenterol Hepatol*, 15(6): 1277-1292.
- [15] Brown, A.L.; Conrad, K.; Allende, D.S.; Gromovsky, A.D.; Zhang, R.; Neumann, C.K.; Owens, A.P.; Tranter, M. and Helsley, R.N. (2020): Dietary Choline Supplementation Attenuates High-Fat-Diet-Induced Hepatocellular Carcinoma in Mice. *J Nutr*, 150(4): 775-783.
- [16] Li, Z. and Vance, D.E. (2008): Phosphatidylcholine and choline homeostasis. *J Lipid Res*, 49(6): 1187-1194.
- [17] Bakir, M.B.; Salama, M.A.; Refaat, R.; Ali, M.A.; Khalifa, E.A. and Kamel, M.A. (2019): Evaluating the therapeutic potential of one-carbon donors in nonalcoholic fatty liver disease. *Eur J Pharmacol*, 847: 72-82.
- [18] Debbabi, M.; Nury, T.; Zarrouk, A.; Mekahli, N.; Bezine, M.; Sghaier, R.; Grégoire, S.; Martine, L.; Durand, P. and Camus, E.J.I.j.o.m.s. (2016): Protective effects of  $\alpha$ -tocopherol,  $\gamma$ -tocopherol and oleic acid, three compounds of olive oils, and no effect of trolox, on 7-ketocholesterol-induced mitochondrial and peroxisomal dysfunction in microglial BV-2 cells. *Int. J Mol Sci*.17(12): 1973.
- [19] Podszun, M.C. and Frank, J. (2021): Impact of vitamin E on redox biomarkers in non-alcoholic fatty liver disease. *Redox Biol*, 42: 101937.
- [20] El Hadi, H.; Vettor, R. and Rossato, M. (2018): Vitamin E as a Treatment for Nonalcoholic Fatty Liver Disease: Reality or Myth? *Antioxidants (Basel)*, 7(1):12.
- [21] Sene-Fiorese, M.; Duarte, F.O.; Scarmagnani, F.R.; Cheik, N.C.; Manzoni, M.S.; Nonaka, K.O.; Rossi, E.A.; de Oliveira Duarte, A.C. and Damaso, A.R. (2008): Efficiency of intermittent exercise on adiposity and fatty liver in rats fed with high-fat diet. *Obesity (Silver Spring)*, 16(10): 2217-2222.
- [22] Khamis, T.; Abdelalim, A.F.; Abdallah, S.H.; Saeed, A.A.; Edress, N.M. and Arisha, A.H. (2020): Early intervention with breast milk mesenchymal stem cells attenuates the development of diabetic-induced testicular dysfunction via hypothalamic Kisspeptin/Kiss1r-GnRH/GnIH system in male rats. *Biochim Biophys Acta Mol Basis Dis*, 1866(1): 165577.
- [23] Khamis, T.; Abdelalim, A.F.; Saeed, A.A.; Edress, N.M.; Nafea, A.; Ebian, H.F.; Algendy, R.; Hendawy, D.M.; Arisha, A.H. and Abdallah, S.H. (2021): Breast milk MSCs upregulated beta-cells PDX1, Ngn3, and PCNA expression via remodeling ER stress /inflammatory /apoptotic signaling pathways in type 1 diabetic rats. *Eur J Pharmacol*, 905: 174188.
- [24] Livak, K.J. and Schmittgen, T.D.J.m. (2001): Analysis of relative gene expression data using real-time quantitative PCR and the 2- $\Delta\Delta$ CT method. *Methods* 25(4): 402-408.
- [25] Suvarna, K.S.; Layton, C. and Bancroft, J.D. *Bancroft's theory and practice of histological techniques E-Book: Elsevier health sciences*; 2018.

- [26] Gibson-Corley, K.N.; Olivier, A.K. and Meyerholz, D.K.J.V.p. (2013): Principles for valid histopathologic scoring in research. *Vet Pathol.* 50(6): 1007-15.
- [27] Abdelrahman, O.M.; Fawzy, M. and Mansour, M.F. (2023): Choline and Vitamin E Combination Alleviates Biochemical, Molecular and Histopathological Effects of Non-alcoholic Fatty Liver Disease in Rats. *J Adv Vet Res.* 13(7): 1263-1273.
- [28] Zhu, J.; Wu, Y.; Tang, Q.; Leng, Y. and Cai, W. (2014): The effects of choline on hepatic lipid metabolism, mitochondrial function and antioxidative status in human hepatic C3A cells exposed to excessive energy substrates. *Nutrients,* 6(7): 2552-2571.
- [29] Beckers, L.; Heeneman, S.; Wang, L.; Burkly, L.C.; Rousch, M.M.; Davidson, N.O.; Gijbels, M.J.; de Winther, M.P.; Daemen, M.J. and Lutgens, E. (2007): Disruption of hedgehog signalling in ApoE -/- mice reduces plasma lipid levels, but increases atherosclerosis due to enhanced lipid uptake by macrophages. *J Pathol,* 212(4): 420-428.
- [30] Machado, M.V. and Diehl, A.M. (2018): Hedgehog signalling in liver pathophysiology. *J Hepatol,* 68(3): 550-562.
- [31] Farzan, S.F.; Singh, S.; Schilling, N.S. and Robbins, D.J. (2008): The adventures of sonic hedgehog in development and repair. III. Hedgehog processing and biological activity. *Am J Physiol Gastrointest Liver Physiol,* 294(4): G844-9.
- [32] Swiderska-Syn, M.; Suzuki, A.; Guy, C.D.; Schwimmer, J.B.; Abdelmalek, M.F.; Lavine, J.E. and Diehl, A.M. (2013): Hedgehog pathway and pediatric nonalcoholic fatty liver disease. *Hepatology,* 57(5): 1814-1825.
- [33] Rangwala, F.; Guy, C.D.; Lu, J.; Suzuki, A.; Burchette, J.L.; Abdelmalek, M.F.; Chen, W. and Diehl, A.M. (2011): Increased production of sonic hedgehog by ballooned hepatocytes. *J Pathol,* 224(3): 401-410.
- [34] Kwon, H.; Song, K.; Han, C.; Chen, W.; Wang, Y.; Dash, S.; Lim, K. and Wu, T. (2016): Inhibition of hedgehog signaling ameliorates hepatic inflammation in mice with nonalcoholic fatty liver disease. *Hepatology,* 63(4): 1155-1569.
- [35] Nagoshi, S. (2014): Osteopontin: Versatile modulator of liver diseases. *Hepatol Res,* 44(1): 22-30.
- [36] Seki, E. (2016): HEDGEHOG Signal in hepatocytes mediates macrophage recruitment: A new mechanism and potential therapeutic target for fatty liver disease. *Hepatology,* 63(4): 1071-1073.
- [37] Verdelho Machado, M. and Diehl, A.M. (2016): Role of Hedgehog Signaling Pathway in NASH. *Int J Mol Sci,* 17(6):857.
- [38] Syn, W.K.; Oo, Y.H.; Pereira, T.A.; Karaca, G.F.; Jung, Y.; Omenetti, A.; Witek, R.P.; Choi, S.S.; Guy, C.D.; Fearing, C.M.; Teaberry, V.; Pereira, F.E.; Adams, D.H. and Diehl, A.M. (2010): Accumulation of natural killer T cells in progressive nonalcoholic fatty liver disease. *Hepatology,* 51(6): 1998-2007.
- [39] Lee, C.; Kim, J.; Wang, S.; Sung, S.; Kim, N.; Lee, H.H.; Seo, Y.S. and Jung, Y. (2019): Hepatoprotective Effect of Kombucha Tea in Rodent Model of Nonalcoholic Fatty Liver Disease/Nonalcoholic Steatohepatitis. *Int J Mol Sci,* 20(9): 2369.
- [40] Guy, C.D.; Suzuki, A.; Abdelmalek, M.F.; Burchette, J.L.; Diehl, A.M. and Nash, C.R.N. (2015): Treatment response in the PIVENS trial is associated with decreased Hedgehog pathway activity. *Hepatology,* 61(1): 98-107.
- [41] Yasmin, T.; Rahman, M.M.; Khan, F.; Kabir, F.; Nahar, K.; Lasker, S.; Islam, M.D.; Hossain, M.M.; Hasan, R.; Rana, S. and Alam, M.A. (2021): Metformin treatment reverses high fat diet- induced non-alcoholic fatty liver diseases and

- dyslipidemia by stimulating multiple antioxidant and anti-inflammatory pathways. *Biochem Biophys Rep*, 28: 101168.
- [42] Truong, E. and Noureddin, M. (2022): The Interplay Between Nonalcoholic Fatty Liver Disease and Kidney Disease. *Clin Liver Dis*, 26(2): 213-227.
- [43] Patial, V.; Katoch, S.; Chhimwal, J.; Dadhich, G.; Sharma, V.; Rana, A.; Joshi, R. and Padwad, Y. (2023): Catechins prevent obesity-induced kidney damage by modulating PPARgamma/CD36 pathway and gut-kidney axis in rats. *Life Sci*, 316: 121437.
- [44] de Alwis, N.; Binder, N.K.; Mangwiro, Y.T.M.; Pritchard, N.; Beard, S.; Kaitu'u-Lino, T.J.; Brownfoot, F. and Hannan, N.J. (2022): The effect of metformin on cardiovascular markers in female mice consuming a high fat diet. *Obes Res Clin Pract*, 16(6): 524-32.
- [45] Musso, G.; Cassader, M.; Cohnen, S.; Pinach, S.; Saba, F. and Gambino, R. (2015): Emerging Liver-Kidney Interactions in Nonalcoholic Fatty Liver Disease. *Trends Mol Med*, 21(10): 645-662.
- [46] Thomas, D.M.; Pal, R.; Moopan, N.; Shanid, A. and Devadas, K. (2022): Comparison of Cardio-metabolic Profile in NAFLD Patients with and Without Advanced Fibrosis. *Journal of Clinical and Experimental Hepatology*, 12: S35-S6.
- [47] Mehta, A.K.; Arora, N.; Gaur, S.N. and Singh, B.P. (2009): Choline supplementation reduces oxidative stress in mouse model of allergic airway disease. *Eur J Clin Invest*, 39(10): 934-941.
- [48] Detopoulou, P.; Panagiotakos, D.B.; Antonopoulou, S.; Pitsavos, C. and Stefanadis, C. (2008): Dietary choline and betaine intakes in relation to concentrations of inflammatory markers in healthy adults: the ATTICA study. *Am J Clin Nutr*, 87(2): 424-430.
- [49] Klatt, K.C. Choline and phosphatidylcholine. In: Caballero B, editor. *Encyclopedia of Human Nutrition (Fourth Edition)*. Oxford: Academic Press; 2023. p. 162-74.
- [50] Diez-Ricote, L.; San-Cristobal, R.; Concejo, M.J.; Martinez-Gonzalez, M.A.; Corella, D.; Salas-Salvado, J.; Goday, A.; Martinez, J.A.; Alonso-Gomez, A.M.; Warnberg, J.; Vioque, J.; Romaguera, D.; Lopez-Miranda, J.; Estruch, R.; Tinahones, F.J.; Lapetra, J.; Serra-Majem, L.; Bueno-Cavanillas, A.; Tur, J.A.; Martin Sanchez, V.; Pinto, X.; Gaforio, J.J.; Matia-Martin, P.; Vidal, J.; Mas Fontao, S.; Ros, E.; Vazquez-Ruiz, Z.; Ortega-Azorin, C.; Garcia-Gavilan, J.F.; Malcampo, M.; Martinez-Urbistondo, D.; Tojal-Sierra, L.; Garcia Rodriguez, A.; Gomez-Bellvert, N.; Chaplin, A.; Garcia-Rios, A.; Bernal-Lopez, R.M.; Santos-Lozano, J.M.; Basterra-Gortari, J.; Sorli, J.V.; Murphy, M.; Gasulla, G.; Mico, V.; Salaverria-Lete, I.; Goni Ochandorena, E.; Babio, N.; Herraiz, X.; Ordovas, J.M. and Daimiel, L. (2022): One-year longitudinal association between changes in dietary choline or betaine intake and cardiometabolic variables in the PREvencion con DIeta MEDiterranea-Plus (PREDIMED-Plus) trial. *Am J Clin Nutr*, 116(6): 1565-1579.
- [51] Rychter, A.M.; Hryhorowicz, S.; Slomski, R.; Dobrowolska, A. and Krela-Kazmierczak, I. (2022): Antioxidant effects of vitamin E and risk of cardiovascular disease in women with obesity - A narrative review. *Clin Nutr*, 41(7): 1557-1565.
- [52] Galli, F.; Bonomini, M.; Bartolini, D.; Zatini, L.; Reboldi, G.; Marcantonini, G.; Gentile, G.; Sirolli, V. and Di Pietro, N. (2022): Vitamin E (Alpha-Tocopherol) Metabolism and Nutrition in Chronic Kidney Disease. *Antioxidants (Basel)*, 11(5):989.



- [53] Baltusnikiene, A.; Staneviciene, I. and Jansen, E. (2023): Beneficial and adverse effects of vitamin E on the kidney. *Front Physiol*, 14: 1145216.

### الملخص العربي

## تأثير المعاملة المشتركة بالكولين وفيتامين E على مسار القنفذ والتغيرات النسيجية المرضية في القلب والكلية المصاحبة للجرذان السمينية المصابة بمرض الكبد الدهني غير الكحولي

أمينة مصطفى عبد الرحمن\*، مدحت فوزي، محمد فؤاد منصور

قسم الكيمياء الحيوية والبيولوجيا الجزيئية، كلية الطب البيطري، جامعة الزقازيق، الزقازيق 44519، مصر

مرض الكبد الدهني غير الكحولي (NAFLD) هو مرض الكبد المزمن الأكثر شيوعاً في جميع أنحاء العالم. ترتبط الزيادة في انتشار NAFLD بارتفاع معدلات السمنة في جميع أنحاء العالم. NAFLD هو اضطراب الكبد السائد الذي يتميز بتراكم الدهون المفرط في خلايا الكبد، الناجم في المقام الأول عن اتباع نظام غذائي عالي الدهون (HFD). لا يؤثر NAFLD على الكبد فحسب، بل له أيضاً آثار كبيرة على الأعضاء الأخرى، بما في ذلك الكلى والقلب. يبرز مسار القنفذ، وهو عبارة عن سلسلة إشارات مهمة تشارك في العمليات الخلوية والتطوير، كلاعب محتمل في التسبب في NAFLD وتأثيراته خارج الكبد. كان الغرض من هذه الدراسة هو دراسة تأثيرات العلاج المشترك بالكولين وفيتامين هـ على التغيرات الجزيئية والنسيجية المرضية في القلب والكلية في نموذج فأر يعاني من السمنة المفرطة مع NAFLD الناجم عن اتباع نظام غذائي عالي الدهون. تم تجميع خمسين فأراً ألبينو في خمس مجموعات متساوية عشوائياً. تم الاحتفاظ بالأولى كمجموعة ضابطة وتم التعامل مع المجموعات الأربع المتبقية على النحو التالي؛ المجموعة الثانية فئران تعاني من السمنة المفرطة مع NAFLD، المجموعة الثالثة فئران تعاني من السمنة المفرطة مع NAFLD وتلقى جرعة منخفضة من الكولين وفيتامين هـ، المجموعة الرابعة فئران تعاني من السمنة المفرطة مع NAFLD وتلقى جرعة متوسطة من الكولين وفيتامين هـ والمجموعة الخامسة فئران تعاني من السمنة المفرطة مع NAFLD وتلقى جرعة عالية من الكولين وفيتامين هـ.

كشفت النتائج أن علاج الفئران بجرعات مختلفة من الكولين وفيتامين هـ قلل بشكل كبير من تعبير الحمض النووي الريبوزي المرسل الكبدي (Hhip و Ptch1 و Smo و Gli1) في المجموعات التي تمت معالجتها بشكل مشترك بالكولين وفيتامين هـ مقارنةً بمجموعة الفئران التي تعاني من السمنة المفرطة مع NAFLD وأظهر تشريحاً آثاراً تحسينية على أنسجة الكلى والقلب. في الختام، يعمل العلاج المشترك بالكولين وفيتامين هـ على تخفيف جينات مسار القنفذ (Hhip و Ptch1 و Smo و Gli1) والتأثيرات التشريحية المرضية في NAFLD الناجم عن HFD في الفئران مع تأثير محتمل على الجرعة القصوى من هذا المزيج. ونتيجة لذلك، فإن المزيج التآزري بين تأثيرات الكولين المؤثرة على الدهون وأنشطة فيتامين هـ المضادة للاكسدة قد يكون إحدى استراتيجيات العلاج المرتقبة لـ NAFLD.