

SHORT COMMUNICATION

Co-Infection of Fowl Adenoviruses and Newcastle Disease Virus in Broiler Chicken Farms in Sharkia Province

Alaa Abdallah^{1,2}, Mohamed A. Lebdah², Reham M. ElBakrey^{2*}

¹Veterinarian, Abu Hammad, Sharkia, 44661, Zagazig, Egypt

²Department of Avian and Rabbit Medicine, Faculty of Veterinary Medicine, Zagazig University, 44511 Zagazig, Egypt

*Corresponding author: E-mail address: rehamemara3@gmail.com

Abstract

Fowl adenovirus (FAdVs) infections have an important economic impact, especially in the production of broilers. It is considered the main cause of three syndromes: inclusion body hepatitis, hepatitis-hydropericardium syndrome, and gizzard erosions and ulcerations. This study was conducted on three broiler farms with total bird numbers ranging from 16,500 to 25,000 and ages 26-32 days in Sharkia province, Egypt. Chickens were vaccinated with commercially available Newcastle disease virus (NDV), infectious bronchitis virus (IBV), avian influenza virus (AIV), and infectious bursal disease virus (IBDV) vaccines. The birds showed clinical signs mainly depression, greenish diarrhea, and respiratory signs with mortalities. The pathological lesions were commonly hemorrhages on livers, papillae of proventriculus, and cecal tonsils, hydropericardium, gizzard erosion, and atrophied bursa of fabricius. Based on the molecular diagnosis using real-time machine and primers specific to FAdVs (conserved to all species A-E), and virulent NDV (vNDV), the three broiler flocks were positive for both viruses. The results of the examination and diagnosis of three broiler farms indicated the presence of FAdV infection, accompanying the infection with the most prevalent and circulating viral agent, NDV.

Keywords: NDV, Fowl Adenoviruses, Broilers, Inclusion body hepatitis, Hydropericardium syndrome

Introduction

One of the challenges in the poultry industry is Newcastle Disease (ND), a highly contagious viral disease that infects several species of domestic, exotic, and wild birds [1]. ND has a significant global economic impact on poultry production due to the high cost of handling, which includes not only losses during an outbreak such as growth disorders, decreased productivity, and mortalities, but also expensive control measures like costly repeated testing and vaccination [2]. The virus that causes ND is an important pathogen known as Newcastle Disease Virus (NDV), avian

paramyxovirus-1 (APMV-1) or avian orthoavulavirus-1 (AOaV-1), belongs to the *Paramyxoviridae* family [3]. Lately, NDV sub-genotype VII belonging to class II is thought to be accountable for the concurrent outbreaks among chicken flocks in Egypt, despite using strict preventive immunization [4-7].

In addition to the outbreak of Newcastle disease in poultry farms in Egypt, another prominent viral disease affecting the poultry industry is the fowl adenovirus.

Fowl adenoviruses (FAdVs) belong to the family *Adenoviridae* and many diseases are associated with its infection

[8]. The most prevalent diseases produced by FAdVs infection are inclusion body hepatitis (IBH), hydropericardium syndrome (HPS), and gizzard erosions [9]. IBH is a severe disease that primarily affects young broilers from the ages of less than 2 weeks [10] which is caused by multiple serotypes of FAdV species D and E [11].

Hepatitis/hydropericardium syndrome (HHS) is a more recent significant pathological condition linked to FAdVs that has a significant economic impact on intensive chicken production [12]. In Egypt, Species D and E have mainly been isolated from the outbreaks of FAdVs [10,13-16].

Under field conditions, there is conflicting evidence about the role of FAdVs as the primary etiology. Certain publications indicate the FAdVs role as the primary agent [17]. On the other hand, other researchers consider FAdVs as a secondary pathogen, with disease emerging from co-infection with immunosuppressive agents, such as mycotoxins [18], chicken anemia virus [19], avian reovirus [20], and infectious

bursa disease virus [21]. FAdVs may potentially have immunosuppressive effects due to reducing humoral and cell-mediated immunity, making affected birds more vulnerable to other infections [22, 23].

The present study investigated three broiler farms in Sharkia governorate, Egypt suspected to be co-infected with the Fowl adenoviruses and Newcastle disease virus, the clinical examination was carried out with the detection of the suspected viruses using real-time polymerase chain reaction.

Materials and Methods

Broiler Farms

Three farms of broiler chickens located in Sharkia Province, Egypt, were investigated after complaints from farm owners about the presence of mortalities among birds, which reached up to 320 birds per day with variable clinical signs. And they confirmed the absence of mycotoxins in the ration after laboratory examination. The descriptive data for three farms with the vaccination programs was illustrated in Table 1.

Table 1. Descriptive data of the investigated broiler farms in Sharkia, Egypt during 2023

No of farm	Total No. of birds	Age/ day	Vaccine program	Mortality rate*
Farm 1	16,500	26	0d: Vaxxitek ND 4d: IB (primer, 4/91)- Clone 30- inactivated vaccine (H9+ND) 12d: Gumboro D78 17d: Avinew (ND)	100-280/day (750/ 4 days)
Farm 2	20,000	32	0d: Vaxxitek IBD 4d: IB (Ma5, 4/91)- Clone 30- inactivated vaccine (H9+ND) 8d: inactivated vaccine (H9) 12d: Gumboro D78 17d: Avinew (ND)	40-65/day (152/ 3 days)
Farm 3	25,000	30	0d: Vectormune (ND), Transmune (IBD) 4d: IB (H120, 4/91)- Vitapest- inactivated vaccine (H9) 8d: Bivalent inactivated vaccine (H5+ND) 10d: live attenuated IBD vaccine 20d: Avinew (ND)	150-320/day (920/ 4 days)

* Number of dead birds was calculated since start of clinical disease until the investigation date

Examined Birds and tissue collection

Thirty broiler chickens were selected from the three farms (10 birds per farm) and submitted for clinical and postmortem examination. The tissues from organs such as the heart, liver, lung, and intestine were collected separately as pool samples for each organ for laboratory diagnosis using real-time Reverse transcription and polymerase chain reaction. In which the tissue collection was carried out according to the ethics of the Animal Care and Use Committee (IACUC), Faculty of Veterinary Medicine, Zagazig University, Egypt, under approval number: ZU-IACUC/2/F/283/2022.

Real-time Reverse transcription polymerase chain reaction (rRT-PCR) for detection NDV

The RNA was extracted from the collected tissues (lung and intestine) using QIAamp MinElute Virus Spin kit (Qiagen GmbH, Hilden, Germany) in accordance with the manufacturer's instructions. The rRT-PCR targeting of the fusion (F) gene of virulent NDV was performed using the WizPure™ qPCR Master (PROBE) kit (Wizbiosolutions Inc., Korea). The specific primers (F4839: 5-TCCGGAGGATACAAGGGTCT-3, and F4939: 5-AGCTGTTGCAACCCCAAG-3) and probe (F4894 (VFP-1): 5-[FAM]AAGCGTTTCTGTCTCCTTCCCTCCA[TAMRA]-3) were used for the detection of virulent strains of NDV (vNDV) as previously reported by Wise *et al.* [24], as well as cycling conditions used in this reaction were previously described by Abd Elfatah *et al.* [25].

Real-time polymerase chain reaction (PCR) for detection fowl adenoviruses

The DNA was extracted from the collected tissues (heart and liver) using Promega Wizard® Genomic DNA Purification Kit (Promega Corporation, USA) according to the manufacturer's instructions. The real-time PCR was performed using the GoTaq® 1-Step RT-qPCR kit (Promega Corporation, USA). The specific primers targeting the conserved nucleotide sequences within the 52K gene (52K-F: TGT ACG AYT TCG TSC ARA C, and 52K-R: TAR ATG GCG CCY TGC TC) for detection all fowl adenovirus (FAdV) species (A-E), as well as the cycling conditions used in this reaction were previously described by Günes *et al.* [26].

Results

Clinical signs and pathology

All the investigated broiler farms were exhibited from depression, anorexia, reluctance to move, greenish diarrhea with respiratory signs. The necropsy of examined birds revealed hemorrhages on the tips of proventriculus and rectum, inflamed and hemorrhagic cecal tonsils, elliptical ulcers on Peyer's patches of the intestine. Hydropericardium, enlarged liver with hemorrhagic spots, gizzard erosion, and hemorrhagic spots on duodenum were seen. As well as congested trachea, spleen, and kidneys with inflamed and atrophied bursa of Fabricius were also observed. The pathological lesions of the examined birds from the three broiler flocks are shown in Figure 1 and Table 2.

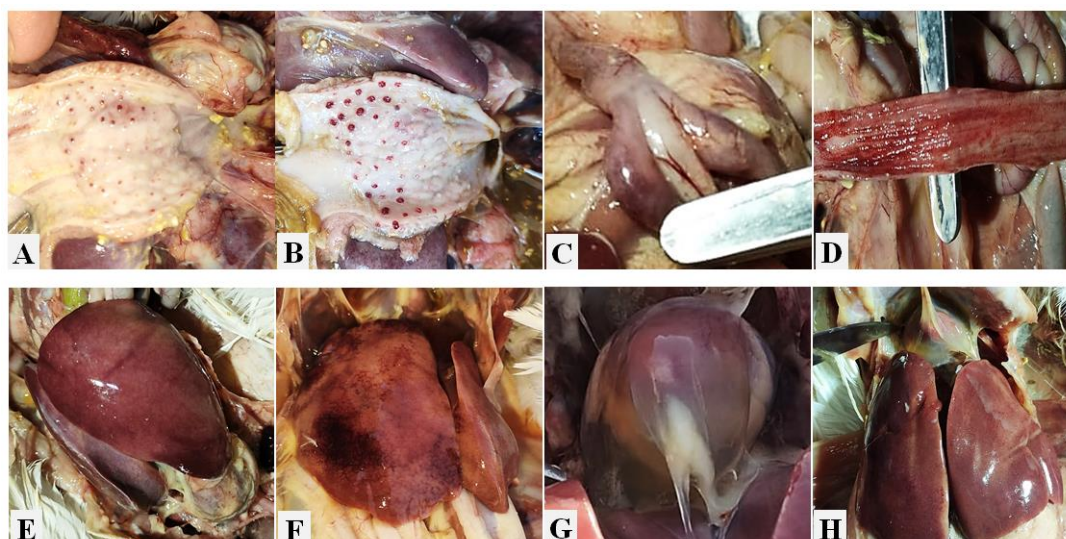


Figure 1. Pathological pictures of the three examined broiler flocks. A) and B) Hemorrhagic spots on papillae tips of proventriculus. C) Enlarged and hemorrhagic cecal tonsils. D) Hemorrhages on mucosa of rectum. E) and F) enlarged livers with hemorrhagic spots on the surfaces. G) Hydropericardium. H) Hydropericardium and enlarged liver with hemorrhagic spots.

Viruses Detection

Among the tested tissue samples that were collected from the birds of three broiler farms and submitted for detection of the NDV and FAdVs using real-time

PCR/RT-PCR with specific primers. The results revealed that the three investigated farms were positive for virulent NDV and FAdVs (Table 2).

Table 2. Postmortem lesions and virus detection in the three investigated broiler farms

No of farms	Haemorrhages									Detection of viruses using real-time machine	
	Papillae of proventriculus	Duodenum	Cecal tonsils	Rectum	Liver with enlarged	Elliptical ulcers on intestine	Gizzard erosion	hydropericardium	Atrophied and inflamed bursa	vNDV	FAdV species (A-E)
	Farm 1	+	+	+	-	+	+	+	+	+	+
Farm 2	+	-	+	+	+	-	-	+	+	+	+
Farm 3	-	-	+	+	+	-	+	+	+	+	+

Discussion

According to the World Organization of Animal Health, diseases caused by Fowl adenoviruses (FAdVs) are globally reported and considered of most apprehension, because of their economic and negative effects on commercial meat bird production and its trade [27]. FAdVs

have recently drawn more interest from the worldwide poultry industry, with limited studies conducted in Egypt [10]. Currently, co-infection of FAdVs and other pathogens is very common, and pathological changes become typical in form. In this study, we investigated three broiler farms in Sharkia province, Egypt after farm owners complained of variable

mortalities and clinical signs among the birds. After visiting these farms, we recorded the visible clinical signs which included depression, anorexia, recumbence, and greenish diarrhea with respiratory signs. After a necropsy examination, we noticed more noticeable pathological lesions concerning the lesions of NDV as hemorrhages on the tips of the proventriculus, inflamed and hemorrhagic cecal tonsils, and elliptical ulcers on Peyer's patches of the intestine as previously mentioned by Ewies *et al.* [5]. Furthermore, the lesions of the enlarged liver with hemorrhagic spots, hydropericardium, and gizzard erosion are commonly notifiable in case of infection with FAdV [9, 28].

The molecular diagnosis confirmed the identification and detection of the velogenic strain of NDV and FAdV in the investigated broiler farms, although these farms were vaccinated against NDV. Maletić *et al.* [29] confirmed that the FAdV has an immunosuppressive effect, consequently reducing the protective efficacy of some vaccines whereas Newcastle's vaccines come primarily. FAdVs not only affect humoral immunity but also cell-mediated immunity [30], this leads to the emergence of a more pathogenic virus increasing mortality and causing severe clinical findings [30, 31]. In which the atrophied bursa of Fabricius was reported in this investigation.

A wide range of ages can be infected with different FAdV serotypes, from less than two weeks old [10] to 20 weeks [11]. The early-age infections may be attributed to the vertical transmission of the virus from the parent flock [32]. Also, horizontal transmission is occurring for broilers. The virus infection and transmission are commonly combined with a failed biosecurity management system and environmental contamination. Where, FAdV unveils high resistance to most disinfectants and detergents, allowing the virus to persist in the poultry

house for long periods, easily transmitting [33].

Finally, the result revealed that FAdVs were detected among poultry populations, especially broilers in Egypt, with NDV co-infection despite the application of the NDV vaccination programs. This requires more attention to increase the awareness of veterinarians and farmers about this infection with FAdV because the virus can be the primary pathogen in broilers which increases the possibility of outbreaks of diseases associated with other pathogens and leads to large economic losses. So the interest in breeder health standards and serotype-specific immunity, the adoption of biosecurity for the broiler flocks, as well as providing a scientific basis for comprehensive prevention and control of FAdV infection may result in reduced transmission. Consequently, the poultry flocks can be protected from the FAdV effect, reducing the possibility of co-infection and maintaining the protective efficiency of vaccines.

Conflict of Interest

No potential conflict of interest was reported by the author(s).

References

- [1] Alexander, D.J.; Senne, D.A. (2008): Newcastle disease. In Saif, Y.M.; Barnes, H.J.; Glisson, J.R.; Fadly, A.M.; McDougald, L.R. and Swayne, D.E. editors. *Diseases of Poultry*, 12th ed. Blackwell Publishing: Ames, IA, USA. 75–100.
- [2] Amoia, C.F.A.N.G.; Nnadi, P.A.; Ezema, C. and Couacy-Hymann, E. (2021). Epidemiology of Newcastle disease in Africa with emphasis on Côte d'Ivoire: A review. *Vet World*, 14(7): 1727.
- [3] Dimitrov, K.M.; Abolnik, C.; Afonso, C.L.; Albina, E.; Bahl, J.; Berg, M.; Briand, F.X.; Brown, I.H.; Choi, K.S.; Chvala, I.; Diel, D.G.; Durr, P.A.; Ferreira, H.L.; Fusaro, A.; Gil, P.; Goujgoulova, G.V.; Grund,

- C.; Hicks, J.T.; Joannis T.M.; Torchetti, M.K. and Wong, F.Y.K. (2019): Updated unified phylogenetic classification system and revised nomenclature for Newcastle disease virus. *Infect Genet Evol*, 74: 103917.
- [4] Radwan, M.M.; Darwish, S.F.; El-Sabagh, I.M.; El-Sanousi, A.A. and Shalaby, M.A. (2013): Isolation and molecular characterization of Newcastle disease virus genotypes II and VIId in Egypt between 2011 and 2012. *Virus Genes*, 47: 311–316.
- [5] Ewies, S.S.; Ali, A.; Tamam, S.M. and Madbouly, H.M. (2017): Molecular characterization of Newcastle disease virus (genotype VII) from broiler chickens in Egypt. *Beni-Suef Univ J Basic Appl Sci*, 6: 232–237.
- [6] Amer, S.A.M.; Ali, M.A.; Kandeil, A.M. and Kutkat, M.A. (2019): Advancement in vaccination of broiler chickens with genotype-matched vaccines to currently epidemic Newcastle disease virus genotype VII in Egypt. *J World's Poult Res*, 9(3): 117-123.
- [7] Eid, A.A.M.; Hussein, A.; Hassanin, O.; Elbakrey, R.M.; Daines, R.; Sadeyen, J.; Abdien, H.M.F.; Chrzastek, K. and Iqbal, M. (2022): Newcastle Disease Genotype VII Prevalence in Poultry and Wild Birds in Egypt. *Viruses*, 14: 2244.
- [8] Harrach, B.; Tarjan, Z.L. and Benko, M. (2019): Adenoviruses across the animal kingdom: a walk in the zoo. *FEBS Lett*, 593(24): 3660–3673.
- [9] Hess, M. (2000): Detection and differentiation of avian adenoviruses: a review. *Avian Pathol*, 29(3): 195–206.
- [10] Adel, A.; Mohamed, A.A.E.; Samir, M.; Hagag, N.M.; Erfan, A.; Said, M.; Arafa, A.; Hassan, W.M.M.; El Zowalaty, M.E. and Shahien, M.A. (2021): Epidemiological and molecular analysis of circulating fowl adenoviruses and emerging of serotypes 1, 3, and 8b in Egypt. *Heliyon*, 7(12).
- [11] Sahindokuyucu, I.; Çoven, F.; Kılıç, H.; Yılmaz, O.; Kars, M.; Yazıcıoğlu, O. Ertunç, E.; and Yazıcı, Z (2020): First report of fowl aviadenovirus serotypes FAdV-8b and FAdV-11 associated with inclusion body hepatitis in commercial broiler and broiler-breeder flocks in Turkey. *Arch Virol*, 165: 43–51.
- [12] Pereira, C.G.; Marin, S.Y.; Santos, B.M.; Resende, J.S.; Resende, M.; Gomes, A.M. and Martins, N.R.S. (2014): Occurrence of Aviadenovirus in chickens from the poultry industry of Minas Gerais. *Arquivo Brasileiro de Medicina Veterinária e Zootecnia*, 66: 801-808.
- [13] Mohamed, M.H.A.; El-Sabagh, I.M.; Abdelaziz, A.M.; Ali, A.M.; Alramadan, M.; Lebdah, M.A.; Ibrahim, A.M. and Al-Ankari, A.S. (2018): Molecular characterization of fowl aviadenoviruses species D and E associated with inclusion body hepatitis in chickens and falcons indicates possible cross-species transmission. *Avian Pathol*, 47(4):384–390
- [14] Radwan, M.M.; El-Deeb, A.H.; Mousa, M.R.; El-Sanousi, A.A. and Shalaby, M.A. (2019): First report of fowl adenovirus 8a from commercial broiler chickens in Egypt: molecular characterization and pathogenicity. *Poult Sci*, 98(1): 97-104.
- [15] Elbestawy, A.R.; Ibrahim, M.; Hammam, H.; Noreldin, A.E.; Bahrawy, A. and Ellakany, H.F. (2020): Molecular characterization of fowl adenovirus D species in broiler chickens with inclusion body hepatitis in Egypt. *Alexandria J Vet Sci*, 64 (1): 110–117.
- [16] Hussein, E.; Anwar, N.F.; Elsebaey, H.S.; Abdelmagid, M.A.; Elkhair, M.A. and Mahana, O. (2023): Isolation and Characterization of Fowl Adenoviruses Associated with Hydro-pericardium Syndrome from Broiler Chickens in Egypt. *J World's Poult Res*, 13(1): 149-160.
- [17] Gomis, S.; Goodhope, R.; Ojkic, D. and Willson, P. (2006): Inclusion body hepatitis as a primary disease in broilers in Saskatchewan, Canada. *Avian Dis*, 50(4): 550-555.

- [18] Singh, A.; Oberoi, M.S.; Jand, S.K. and Singh, B. (1996): Epidemiology of inclusion body hepatitis in poultry in northern India from 1990 to 1994. *Rev. sci. tech. - Off. int. épizoot.*, 15: 1053-1060.
- [19] Toro, H.; Gonzalez, C.; Cerda, L.; Hess, M.; Reyes, E. and Geisse, C. (2000): Chicken anemia virus and fowl adenoviruses: association to induce the inclusion body hepatitis/hydropericardium syndrome. *Avian Dis*, 51-58.
- [20] Rios, R.L.; Marín, S.Y.; Gomes, A.M. Resende, F.M.S.; Horta, R.S.; Resende, M. and Martins, N.R.S. (2012): The occurrence of Orthoreovirus, Rotavirus and chicken anemia virus in chickens of the poultry industry in Minas Gerais, Brazil *Arq Bras Med Vet Zootec*, 64: 1613-1620.
- [21] Gomes, A.D.; Abreu, J.T.; Redondo, R.A.F.; Martins, N. R S.; Resende, J.S. and Resende, M. (2005): Genotyping of infectious bursal disease virus strains by restriction fragment length polymorphism analysis of the VP1, VP2, and VP3 genes. *Avian Dis*, 49(4): 500-506.
- [22] Schonewille, E.; Singh, A.; Göbel, T.W.; Gerner, W.; Saalmüller, A. and Hess, M. (2008): Fowl adenovirus (FAdV) serotype 4 causes depletion of B and T cells in lymphoid organs in specific pathogen-free chickens following experimental infection. *Vet Immunol Immunopathol*, 121(1-2): 130-139.
- [23] Singh, A.; Grewal, G.S.; Maiti, N.K. and Oberoi, M.S. (2006): Effect of fowl adenovirus-1 (IBH isolate) on humoral and cellular immune competency of broiler chicks. *Comp immunol microbiol infect Dis*, 29(5-6): 315-321.
- [24] Wise, M.G.; Suarez, D.L.; Seal, B.S.; Pedersen, J.C.; Senne, D.A.; King, D.J.; Kapczynski, D.R. and Spackman, E. (2004): Development of a real-time reverse-transcription PCR for detection of Newcastle disease virus RNA in clinical samples. *J Clin Microbiol*, 42(1): 329-338.
- [25] Abd Elfatah, K.S.; Elabasy, M.A.; El-Khyate, F.; Elmahallawy, E.K.; Mosad, S.M.; El-Gohary, F.A.; Abdo, W.; Al-Brakati, A.; Seadawy, M.G.; Tahoon, A. and El-Gohary, A.E. (2021): Molecular characterization of velogenic Newcastle disease virus (sub-genotype VII. 1.1) from wild birds, with assessment of its pathogenicity in susceptible chickens. *Animals*, 11(2): 505.
- [26] Günes, A.; Marek, A.; Grafl, B.; Berger, E. and Hess, M. (2012): Real-time PCR assay for universal detection and quantitation of all five species of fowl adenoviruses (FAdV-A to FAdV-E). *J Virol methods*, 183(2): 147-153.
- [27] McFerran, J.B. and Smyth, J.A. (2000): Avian adenoviruses. *Revue scientifique et technique (International Office of Epizootics)*, 19(2): 589-601.
- [28] Sultan, H.; Arafa, A.E.S.; Adel, A.; Selim, K.; El-Hoseni, M. and Talaat, S. (2021): Genetic characterization of Novel fowl aviadenovirus-4 (FADV-4) from the outbreak of hepatitis-hydropericardium syndrome in commercial broiler chickens in Egypt. *Avian Dis*, 65(3): 385-390.
- [29] Maletić, J.; Spalević, L.; Kureljušić, B.; Veljović, L.; Maksimović-Zorić, J.; Maletić, M. and Milićević, V. (2023): Fowl Adenovirus Infection–Potential Cause of a Suppressed Humoral Immune Response of Broilers to Newcastle Disease Vaccination. *Acta Vet*, 73(1): 133-142.
- [30] Song, H.; Bae, Y.; Park, S.; Kwon, H.; Lee, H. and Joh, S. (2018): Loop-mediated isothermal amplification assay for detection of four immunosuppressive viruses in chicken. *J Virol Methods*, 256: 6-11.
- [31] Yu, G.; Lin, Y.; Dou, Y.; Tang, Y. and Diao, Y. (2019): Prevalence of fowl adenovirus serotype 4 and co-infection by immunosuppressive viruses in fowl with hydropericardium hepatitis

- syndrome in Shandong province, China. *Viruses*, 11(6): 517.
- [32] Schachner, A.; Matos, M.; Grafl, B. and Hess, M. (2018): Fowl adenovirus-induced diseases and strategies for their control—a review on the current global situation. *Avian Pathol*, 47(2): 111-126.
- [33] Adair, B.M. and Fitzgerald, S.D. (2008): Adenovirus infections. In Saif, Y.M.; Barnes, H.J.; Glisson, J.R.; Fadly, A.M.; McDougald, L.R. and Swayne, D.E. editors. *Diseases of Poultry*, 12th ed. Blackwell Publishing: Ames, IA, USA. 251-296.

الملخص العربي

العدوى المشتركة بالفيروسات الغذائية للدواجن ومرض النيوكاسل في مزارع لدجاج التسمين بمحافظة الشرقية

علاء عبدالله¹، محمد لبيده²، رهام البكري²
 1 طبيب بيطري، أبوحماد، الشرقية، 44661، مصر
 2 قسم طب الطيور والارانب، كلية الطب البيطري، جامعة الزقازيق، 44511، الزقازيق، مصر

إن عدوى الفيروس الغدي لدى الطيور (FAdVs) لها تأثير اقتصادي مهم، خاصة في إنتاج دجاج التسمين. ويعتبر السبب الرئيسي لثلاث متلازمات: التهاب الكبد الجسمي المتضمن، ومتلازمة التهاب الكبد و القلب، وتآكل وتقرحات القانصة. أجريت هذه الدراسة على 3 مزارع دجاج التسمين بأعداد تتراوح بين 16,500 إلى 25,000 وأعمار 26-32 يوماً في محافظة الشرقية، مصر. تم تطعيم الدجاج بلقاحات فيروس مرض نيوكاسل (NDV) وفيروس التهاب الشعب الهوائية المعدي (IBV) وفيروس أنفلونزا الطيور (AIV) المتوفر تجارياً. ظهرت على الطيور علامات سريرية أبرزها الهزال والإسهال الأخضر وعلامات تنفسية مع نفوق. كانت الأوقات المرضية عادة عبارة عن نزيف في الكبد، و حليمة العضلة المعوية، واللوزتين الأوريتين، واستسقاء القلب، وتآكل القانصة، وضمور جراب فابريسيوس. استناداً إلى التشخيص الجزيئي باستخدام آلة real-time وبادئات خاصة بـ FAdVs المحفوظة لجميع الأنواع (A-E)، و NDV عالي الضراوة (vNDV)، كانت قطعان دجاج التسمين الثلاثة إيجابية لكلا الفيروسين. أشارت نتائج فحص وتشخيص ثلاث مزارع لدجاج التسمين إلى وجود عدوى فيروس FAdV المصاحبة للإصابة بالمرض الفيروسي الأكثر انتشاراً وهو مرض ND.