

## Assessment of Double Chin with Exercises and Mesotherapy

Shymaa F.Salem, Gamal A.Hammad, Refaat M.El-Tananwy, Amal M.Fathy, Eman A.Baraka  
Rheumatology, Rehabilitation and Physical Medicine Dept., Faculty of Medicine, Benha University  
E-mail: dr.fekry.46@gmail.com

### Abstract

**Background:** Double chin treatment options often encompass a blend of exercises and mesotherapy. This study aimed to assess treatment of double chin with exercises and mesotherapy. **Methods:** Thirty female patients, aged 22 to 55 years (mean age: 44.5 years  $\pm$  5.6 SD), were treated with a cocktail comprising Phosphatidyle choline, 20% Caffeine, and 0.5% organic Silicium. The treatment protocol involved up to six sessions spaced a week apart, injecting 0.3 ml of the cocktail per site using a point-by-point technique. Post-injection, patients received instructions for home care and were prescribed daily double chin reduction exercises. The evaluation encompassed physician assessments through blinded photograph evaluation, patient self-assessment questionnaires, and monitoring of adverse effects. **Results:** Among 30 female participants (mean age 44.5  $\pm$  5.6 years) with moderate to significant sub-mental fat deposits, 90% reported improvement post-treatment. Specifically, 16.7% experienced moderate improvement, while 26.7% reported significant and very significant improvements each. Rater agreement in assessing patient improvement was substantial ( $k=0.84$ ). Adverse events included edema (23.3%), pain (23.3%), erythema (16.7%) resolving within two weeks, and subcutaneous nodules in 2 patients. **Conclusions:** The combination therapy demonstrated a high rate of patient-perceived improvement in double chin reduction. Clinician assessments aligned with patient-reported outcomes, affirming the treatment's efficacy. Adverse events, while present, were mostly transient and manageable.

**Keywords:** Double chin; Mesotherapy; Phosphatidyle choline; Caffeine; Silicium; Patient assessment; Adverse effects.

### 1. Introduction

Double chin deformity is an annoying cosmetic problem that results from localized fat deposits beneath the jaw. Excess skin and fatty tissues in this area leads patients, especially women, to undergo surgical procedures such as liposuction and dermolipectomy to improve the cosmetic effect. Neck liposuction produces excellent results and a high degree of patient satisfaction with minimal morbidity [1].

Fearful of extensive surgery and its complications, patients and physicians seek less invasive methods that may offer some results. Non-surgical approaches have become the new paradigm for cosmetic fat reduction. Recent advances in laser and high-frequency focused ultrasound for fat reduction are promising. However, ultrasound cannot be applied over bony prominences including submental area [2].

Mesotherapy has been recently used in treatment of many conditions including hair growth, skin rejuvenation, cellulite and lipolysis and it can be done either by syringe or specialized engineered delivery gun. Although mesotherapy has infrequent local complications, the long term local or systemic effects are still unknown [3].

Injection lipolysis is subcutaneous injections in a depth of 6-13 mm of pharmacologically active detergents to chemically ablate adipose tissue. The most popular formulations used consist of varied concentrations of phosphatidylcholine (PPC), a soy derived

phospholipid, and its solvent, the bile salt sodium deoxycholate (DC). Recently published studies recommended PPC injection for treatment of double chin and they showed impressive results with minimal side effects [4].

The use of mesotherapy for submental fat reduction is safe, efficacious, cost-effective, and can be used as an alternative to invasive surgical procedures but the patients should anticipate localized reactions and not expect liposuction like results. The volumes of fat that can potentially be treated with injection lipolysis are significantly less than the fat volume reduced after liposuction [5].

Double chin exercises can help to tone the muscles of the face and jaw, firm skin along the jaw line and get rid of excess fat to diminish the submental fat. Whatever the cause of double chin, these exercises can help reduce its size and improve its appearance. The exercises include chin lift, neck roll, jaw release and Platysma exercise that stretch and tones the muscles of the jaw, neck and throat[6].

This study aimed to assess treatment of double chin with exercises and mesotherapy.

### 2. Methods

#### Patients:

This study included 30 patients with moderate to significant sub mental fat deposits selected from the department of the Rheumatology,

Rehabilitation & Physical medicine, Benha University Hospitals.

The study received approval from the Research Ethical Committee of Benha Faculty of Medicine and adhered to the principles outlined in the Helsinki Declaration guidelines. Informed consent was obtained from each participant. Confidentiality and personal privacy were strictly maintained at all stages of the study, and patients had the freedom to withdraw from the study at any time without facing any consequences. The collected data were exclusively used for this study's purposes.

**Inclusion criteria:** Careful patient selection was done to assure that the deformity is due to local fat deposition and not resulting from loose skin or muscle tissue and not due to individual anatomy such as a small/short mandible, low hyoid bone, and/or an anteriorly positioned thyroid cartilage. Careful palpation showed the absence of subcutaneous fat in these patients. Also, patients who already had skin laxity, striae, platysmal banding, or pendulous skin were advised that surgery may be much more beneficial.

**Exclusion criteria:** current serious disease or active infection, insulin dependent diabetes mellitus, history of strokes, cancer or thromboembolism, patients on anticoagulant medications (aspirin, warfarin and heparin), history of psoriasis or lichen planus for fear of Koebnerization, pregnancy, breast feeding, known allergy to soy products.

#### **Methodology:**

All the studied participants were subjected to injection lipolysis using a cocktail formed from combination of Phosphatidyle choline (PPC), 20% Caffeine and 0.5% organic silicon in a 1:11\2 ratio (Marketed as "Cosmo Medica" Integrated Cosmotic solution, premium Spanish product).

#### **Treatment protocol:**

The treatment protocol involves injecting 0.3 ml of a cocktail per site using a point-by-point technique with 30-gauge needles, spaced 1cm apart and reaching a depth of 1cm to 1.3cm. Sessions, spaced a week apart and limited to 6, utilized up to 4 mL per session depending on the patient's sub-mental fat [7]. Pre-injection steps included consultation, informed consent, and photographing patients before and after each session. The injection technique employed clean, mapped squares on the treatment area, with no topical anesthetics used. The Pinch and Pull technique was utilized for injection, followed by massage and application of fusidinic acid cream. Subsequent sessions were contingent on the absence of residual oedema or erythema from the prior treatment.

**Post- injection:** After the injection, patients received detailed instructions, including applying fusidinic acid cream every 6 hours, avoiding tight compressive garments, and handling the treated area with clean hands. Patients were informed about potential swelling lasting up to a week and advised to monitor symptoms at home, reporting any concerns. Additionally, a set of daily double chin reduction exercises were prescribed to aid in reducing sub-mental fat, involving movements such as opening the mouth wide with the tongue extended, chin lifts, head hanging, neck rolls, platysma exercises against resistance, and using a tennis ball against the throat to perform chin presses.

#### **Evaluation of Therapy:**

The evaluation of therapy encompassed various assessments. Physician assessment involved blinded clinicians evaluating pairs of photographs, unaware of the sequence (before or after treatment). A scoring system was employed: score 0 denoted incorrect sequence judgment, while score 1 signified correct judgment. Statistical analysis gauged the agreement between raters for sequence identification. Additionally, clinicians used a 4-point scale to rate patient improvement based on paired photographs, ranging from no improvement to dramatic improvement. This multi-pronged physician assessment aimed to comprehensively measure the treatment's impact and effectiveness [8].

Patient assessment relied on self-reporting through a questionnaire administered post-treatment. Patients rated satisfaction and therapy efficacy based on perceived fat loss, skin tightening, chin profile enhancement, and overall improvement. The questionnaire employed a 5-point scale, with ratings ranging from no improvement to very significant improvement. This patient-centric approach provided subjective insights into treatment outcomes, reflecting individual experiences and perceptions [8].

Adverse effects assessment encompassed both physician and patient observations. Any adverse effects like oedema, erythema, subcutaneous nodules, or pain were meticulously recorded and evaluated. This comprehensive examination aimed to gauge the treatment's safety and identify potential side effects experienced by patients, ensuring a thorough understanding of both positive outcomes and potential risks [8].

#### **Statistical analysis:**

In this study the categorical data are presented as numbers and percentage and the continuous data as mean  $\pm$  SD. Statistical analysis was performed by SPSS 25 for Windows. The level

of agreement between the multiple raters for correctly identifying the sequence was evaluated using the generalized kappa statistics. A P-value  $\leq 0.05$  was considered statistically significant.

**3. Results**

This study included 30 patients with moderate to significant sub mental fat deposits selected from Rheumatology, Rehabilitation & Physical Medicine Department, Benha University Hospitals. All patients were females and their ages ranged from 22 to 55 years with mean 44.5 years  $\pm$  5.6 SD. **Table 1**

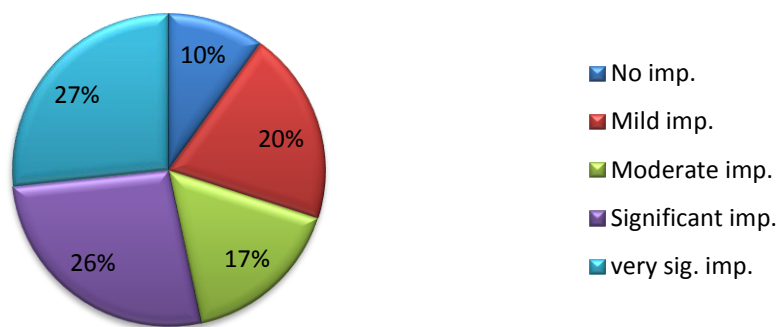
**Table (1)** Demographic data among studied participants

	<b>Patients (n=30)</b>
<b>Age</b>	
Mean $\pm$ SD	44.5 $\pm$ 5.6
(range)	(22 – 55)
Median <45 years	16 (53.3%)
Median $\geq$ 45 years	14 (46.7%)
<b>Sex (N. %)</b>	
Female	30 (100%)
Male	0 (0%)

On assessment of efficacy of therapy by patients using self-assessment questionnaire, 3 patients (10%) reported no improvement while 27 patients (90%) reported improvement, (16.7%) had moderate improvement and (26.7%) had significant and very significant improvement each. **Table 2** and **Fig. 1**

**Table (2)** Evaluation of therapy by patients among studied participants

	<b>Patients(n=30) (N. %)</b>
<b>No improvement</b>	3 (10%)
<b>Improvement</b>	27 (90%)
– <b>Mild improvement</b>	6 (20%)
– <b>Moderate improvement</b>	5 (16.7%)
– <b>Significant improvement</b>	8 (26.7%)
– <b>Very significant improvement</b>	8 (26.7%)



**Fig. (1)** Patients’ assessment of efficacy of therapy

The most patients were improved with significant perfect agreements between rater (k=0.84). **Table 3**

**Table (3)** Evaluation of therapy by physicians among studied participants

	<b>1<sup>st</sup> Rater (N. %)</b>	<b>2<sup>nd</sup> Rater (N. %)</b>	<b>3<sup>rd</sup> Rater (N. %)</b>	<b>Kappa</b>	<b>P</b>
<b>Physician assessment:</b>					
No improvement	3 (10%)	6 (20%)	3 (10%)	0.84	<b>&lt;0.001</b>
Improvement					
Mild	6 (20%)	4 (10%)	6 (20%)		
Significant	10 (33.3%)	10 (20%)	11 (36.7%)		

Dramatic	11 (36.7%)	10 (40%)	10 (33.3%)
----------	------------	----------	------------

Fleiss' Kappa for multiple Raters

The most common adverse events among studied patients were edema (23.3%) and pain (23.3%), followed by erythema (16.7%) that faded gradually over 2 weeks, while only 2 patients had subcutaneous nodules. **Table 4**

**Table(4)** Adverse events among studied participants

	Patients(n=30) (N. %)
Edema	7 (23.3%)
Erythema	5 (16.7%)
Subcutaneous nodules	2 (6.7%)
Pain	7 (23.3%)

#### 4. Discussion

Facial aesthetics are vital in how we're perceived and interact with others, influencing attractiveness judgments and social dynamics. Universally, there's substantial consensus on facial attractiveness across cultures and ages, indicating a shared mechanism for processing facial cues. Perceived attractive individuals often receive preferential treatment in various settings, linking attractiveness to success and societal advantages [9]. Conversely, a double chin, caused by fat accumulation regardless of body type, impacts facial contours, potentially contributing to the perception of aging or obesity. Beyond aesthetics, a double chin might lead to health issues like snoring and sleep apnea, impacting oxygen supply during sleep and potentially causing heart problems [10].

While exercise can strengthen muscles around the neck and jaw, it doesn't specifically target fat in these areas. Understanding the unique nature of subcutaneous fat distribution in the neck and chin underscores the challenges in spot reduction. Today's demand for minimally invasive aesthetic treatments, including injectable therapies, reflects the growing interest in enhancing facial appearance beyond exercise, showcasing a broader array of options for those seeking aesthetic improvements [11, 12].

The aim of this study was to assess treatment of double chin with exercises and mesotherapy.

In the current study we found that all patients were females and their ages ranged from 22 to 55 years with mean 44.5 years.

Unlikely, MD et al. (2019) performed a study on the use of deoxycholic acid for the clinical reduction of excess submental fat, reported that there were 26 males and 24 females. Mean patient age was 35.4 years. The age range was 20-63 years. Mean body mass index (BMI) was 31.1 (4.4; 17.3, 44.8) kg/m<sup>2</sup> [13].

Tsaban et al. (2021) conducted a study on the effect of weight-loss interventions on cervical

and chin subcutaneous fat depots, stating that the mean age was 47.8 ± 9.3 years, the mean BMI was 30.9 ± 3.7 kg/m<sup>2</sup>, and the mean WC was 106.7 ± 9.4 cm. Most of the participants (89.7%) were men [14].

In the present study we found that on assessment of efficacy of therapy by patients using self-assessment questionnaire, 3 patients (10%) reported no improvement while 27 patients (90%) reported improvement, (16.7%) had moderate improvement and (26.7%) had significant and very significant improvement each.

These results were compatible with MD et al. (2019) who reported that patient Reported SMF Rating Scale (PR-SMFRS); Improvement by 1 point from baseline in 47 (94%) patients. Of these, 2 (4%), 13 (26%), 30 (60%), and 2 (4%) patients had 1, 2, 3, and 4 treatment sessions, respectively. Improvement by 2 points from baseline in 3 (6%) patients. Of these, 1(2%) and 2 (4%) patients had 3 and 4 treatment sessions, respectively [13].

This was in accordance with Scarano et al. (2023) who conducted a study on reduction of double chin without surgery using ascorbic acid and ascorbyl-palmitate solution, stated that improvement in submental appearance was achieved by 90% (9/10) of the patients. One patient did not see good improvement in submental appearance after two session treatments and abandoned the treatment [15].

Kwon et al. (2021) illustrated that the objective evaluation based on the 5-point Clinician-Reported Submental Fat Rating Scale (CR-SMFRS) and patients' satisfaction based on the 7-point Subject Self-Rating Scale (SSRS) were determined 8 weeks after treatment. At the follow-up visit, the proportion of treatment responders defined as subjects with ≥1-point improvement in CR-SMFRS was 62.5%, and the proportion of patients satisfied with appearance of their face and chin (score ≥4 on the SSRS) was 67.5% of the total patients [16]. This finding is consistent with results obtained by Grow et al. (2019) who showed that patient

satisfaction scores through FACE-Q had a statistically significant improvement when comparing the pretreatment and final post-treatment assessments for the aesthetics of both the area under the chin as well as the jawline. Furthermore, 12 of 13 patients reported that either family members, friends, or coworkers noted an appreciable difference in the appearance of their double chin following completion of the treatment series. No outcome differences were found based on gender [12].

Our current findings clearly revealed that evaluation of therapy by physicians showed that most patients were improved with significant perfect agreements between rater ( $k=0.84$ ).

This was in accordance with MD et al. (2019) who reported that clinician Reported SMF Rating Scale (CR-SMFRS); Improvement by 1 point from baseline was seen in 44 (88%) patients. Of these, 2 (4%), 11(22%), 29 (58%), and 2 (4%) patients had 1, 2, 3, and 4 treatment sessions, respectively. Improvement by 2 points from baseline was seen in 6 (12%) patients. Of these, 1(2%), 3 (6%), and 2 (4%) patients had 2, 3 and 4 treatment sessions, respectively [13].

Scarano et al. (2023) stated that all patients treated showed good results and were well satisfied with reductions in the submental area which were clinically documented. Before treatment, the letter D was  $10.83\pm 2.66$  mm and after treatment D was  $18.8\pm 1.61$  mm. A statistically significant reduction of the submental area was detected comparing before and after the treatment measurements [15].

Tsaban et al. (2021) examined in this 18-month trial the effect of lifestyle interventions on changes of cervical and chin subcutaneous adipose tissues (SAT) using whole-body MRI. During the intervention, cervical-SAT dynamics paralleled weight changes but were not differentially altered by the intervention groups. Chin-SAT reduced after the 6-month rapid weight loss phase but was regained in parallel to the weight regain phase. While chin-SAT reduction was associated with improved glycemic biomarkers beyond weight changes, the associations of cervical-SAT reduction with cardiometabolic biomarkers were mediated by weight loss. Although located superficially, both cervical and chin SATs were closely related to abdominal visceral fat loss and reduction of ectopic fat in several storage pools. These findings offer insight into potential metabolic roles of specific SAT accumulation and the significance of cervical and chin SATs as surface markers for

metabolic changes during weight loss intervention [14].

The current study found that the most common adverse events among studied patients were edema (23.3%) and pain (23.3%), followed by erythema (16.7%) that faded gradually over 2 weeks, while only 2 patients had subcutaneous nodules.

MD et al. (2019) illustrated that local swelling, lumpiness, and tenderness over the injection sites were reported for a mean 20.7, 23.4, and 11.4 days, respectively. Eighty percent of patients had mild to moderate tenderness post injections. Ten percent of patients witnessed severe pain post injections. None of the patients had complications like marginal mandibular nerve paresis. Lumpiness was defined as a feeling of nodules between thumb and forefingers [13].

Scarano et al. (2023) demonstrated that in one patient prominent submandibular glands and post-platysmal fat with little digastric muscle hypertrophy were observed; at the same time, both can also contribute to submental fullness and would not be improved with SAP treatment. In one patient dermal blebbing was observed during administration because the injections were too superficial, and the needle was gently pushed deeper into the underlying fat. Localized swellings were reported in the submental region, but no patient reported severe erythema following the injections [15]. Grow et al. (2019) showed that there were no significant adverse events in the treatment group, which were defined as marginal mandibular nerve paralysis, dysphagia, dysphonia, or open wounds. Additionally, neither of the 2 males in the study had observed hair loss in the injection area. Numbness in the treatment area occurred in all study participants with complete resolution noted at follow-up 3 months post-treatment [12].

In a study done by Hexsel et al. (2003), 205 patients with localized fat deposits on different body sites were submitted to one to five treatment sessions with an average interval of 15 days between each session. The medication administered was phosphatidylcholine injected in the subcutaneous tissue; 0.2 mL was applied at each point with the total volume varying according to the quantity of localized fat deposits; but in all cases, no more than 10 mL was given. They concluded that the use of phosphatidylcholine in the treatment of localized fat was effective and safe with few side effects, although the exact mechanism of action of phosphatidylcholine injections in the subcutaneous tissue have not yet been explained. They supposed that the medication

penetrates the adipocyte through the double lipid layer, acting as an emulsifying/ten's active agent. The physical-chemical characteristics of the stored lipids would therefore be altered, making them water soluble. This would permit their elimination due to their non-compatibility with the material stored in the adipocyte, which is liposoluble [2].

Heinrich et al. (2005), on his study – “Efficacy of injections of phosphatidylcholine into fat deposits – non-surgical alternative to liposuction in body contouring” – included 86 patients with localized fat deposits on different body areas. He subjected them to one to three treatment sessions using phosphatidylcholine injections. The amount of phosphatidylcholine injected ranged from 5 to 30 mL, depending on individual needs. Results showed significant reductions of the treated fat deposits, and no serious side effects or complications were noted [5].

Another study conducted by Rittes et al. (2001) on the use of phosphatidylcholine for correction of lower lid bulging due to prominent fat pads showed satisfactory results, providing a nonsurgical alternative for treatment of prominent infraorbital fat pads. In this study, 30 patients with prominent lower eyelid fat pads, with no coexisting ocular pathology, and with informed consent were included. Injections of 0.4 mL of phosphatidylcholine into the infraorbital fat pad were given at 15-day intervals for a total of one to four treatment sessions [17].

Kim et al. (2022) performed a study on efficacy and safety of the micro-insulated needle radiofrequency device for reduction of submental fat, 24 adults with excess submental fat were treated once using a micro-insulated needle RF device. The patients' Physician-Assisted Submental Fat Rating Scale score significantly decreased after 1 month and further decreased after 2 months. The average volume of submental fat significantly decreased after 2 months ( $20.44 \pm 5.53$  cc to  $16.41 \pm 4.58$  cc). Patient satisfaction was high. Transient and mild local skin reactions without long-term sequelae were observed in 4 patients [18].

## 5. Conclusion

This study demonstrates the efficacy of exercises and mesotherapy for the reduction of supra platysmal adiposity in the submental region to improve the aesthetics of the neck. Objective volume changes did correlate with subjective improvements in patient satisfaction scores before and after treatment, with a majority of improvement observed after 6

sessions. Insights into the expected course of recovery and side effects were also described, which may aid in prospective patient education and management.

## References

- [1] A.C. Co, M.F. Abad-Casintahan, A. Espinoza-Thaebtharm. Submental fat reduction by mesotherapy using phosphatidylcholine alone vs. phosphatidylcholine and organic silicium: a pilot study. *J Cosmet Dermatol*;6:250-7. 2007
- [2] D. Hexsel, M. Serra, R. Mazzuco, T. Dal'Forno, D. Zechmeister. Phosphatidylcholine in the treatment of localized fat. *J Drugs Dermatol*;2:511-8. 2003
- [3] P.T. Rose, M. Morgan. Histological changes associated with mesotherapy for fat dissolution. *J Cosmet Laser Ther*;7:17-9. 2005
- [4] F. Hasenschwandtner. Phosphatidylcholine treatment to induce lipolysis. *J Cosmet Dermatol*;4:308-13. 2005
- [5] K.G. Heinrich. Efficacy of injections of phosphatidylcholine into fat deposits-A non-surgical alternative to liposuction in body-contouring. *Indian Journal of Plastic Surgery*;38:119-22. 2005
- [6] Jennifer Smith. Exercises to tighten your body after weight loss, *ObesMetabDisordRelat*, 2015.
- [7] R. Kandhari, I. Kaur, D. Sharma. Mesococktails and mesoproducts in aesthetic dermatology. *Dermatol Ther*;33:e14218. 2020
- [8] A.M. Rotunda. Injectable treatments for adipose tissue: terminology, mechanism, and tissue interaction. *Lasers Surg Med*;41:714-20. 2009
- [9] H. Khan, N. Ul Ain, D.S. Bhatti, J. Khan. An Assessment of the Reduction of Submental Fullness With ATX-101 (Deoxycholic Acid Injection) in the Expanded Safe Zone. *Cureus*;15:e35286. 2023
- [10] B. Salsi, I. Fusco. Non-invasive system delivering microwaves energy for unwanted fat reduction and submental skin tightening: Clinical evidence. *J Cosmet Dermatol*;21:5657-64. 2022
- [11] L. Faetani, D. Ghizzoni, A. Ammendolia, C. Costantino. Safety and efficacy of mesotherapy in musculoskeletal disorders: A systematic review of randomized controlled trials with meta-analysis. *J Rehabil Med*;53:jrm00182. 2021
- [12] J.N. Grow, J. Holding, R. Korentager. Assessing the Efficacy of Deoxycholic Acid for the Treatment of Submental Fat:

- A Three-Dimensional Study. *Aesthet Surg J*;39:1400-11. 2019
- [13] D.S. MD, M.S. Khare. The Use of Deoxycholic Acid for the Clinical Reduction of Excess Submental Fat in Indian Patients. *Journal of Drugs in Dermatology*;18:217-25. 2019
- [14] G. Tsaban, A. Bilitzky-Kopit, A. Yaskolka Meir, H. Zelicha, Y. Gepner, I. Shelef, et al. The Effect of Weight-Loss Interventions on Cervical and Chin Subcutaneous Fat Depots; the CENTRAL Randomized Controlled Trial. *Nutrients*;13. 2021
- [15] A. Scarano, R. Amore, A. Greco Lucchina, E. Qorri, M. Marchetti, M. Di Carmine, et al. Reduction of double chin without surgery using ascorbic acid and ascorbyl-palmitate solution: a clinical study. *Eur Rev Med Pharmacol Sci*;27:109-13. 2023
- [16] H.H. Kwon, S.H. Yang, M. Choi, J.Y. Jung, G.H. Park. Tightening and Reduction of Unwanted Submental Fat Using Triple-Layer High-Intensity Focused Ultrasound: Clinical and 3-Dimensional Imaging Analysis. *Dermatol Surg*;47:1595-600. 2021
- [17] P.G. Rittes. The use of phosphatidylcholine for correction of lower lid bulging due to prominent fat pads. *Dermatol Surg*;27:391-2. 2001
- [18] J.Y. Kim, J. Cho, W. Lee. Submental Contouring Using Elastic Threads. *Minimally Invasive Aesthetic Surgery Techniques: Botulinum Toxin, Filler, and Thread Lifting*: Springer; 2022. p. 187-96.