

ORIGINAL RESEARCH

Open Access

# Simplify long-term venous access via external jugular vein in children



Mustafa Akman

## Abstract

**Background:** Bone marrow transfer has begun to be widely used in complicated conditions, such as chemotherapy or hemodialysis, following the description of indwelling central venous catheters and demonstrating their suitability in pediatric patients. The widespread use of it has increased the incidence of complications as well. The use of external jugular vein catheterization, which is a safer route compared to the blind route of administration, has topographical difficulties. The findings obtained in this study showed that these difficulties could be overcome. Our study revealed that the catheterization was possible and described a facilitating technique. Of the pediatric patients involved in the bone marrow transfer programs, patients who were deemed eligible candidates for the use of external jugular vein, based on the preoperative assessment, were included in the present study.

**Results:** No early complication was observed in this study. The central catheter was placed on all patients in the same session. Catheters were inserted using the external jugular vein in 98 patients and percutaneous internal jugular vein in 2 patients. A central catheter was inserted through 105 interventions and 103 incisions in 100 patients. External jugular vein use, which was planned before the procedure, was achieved in 98 patients. The internal jugular vein was selected as the second option in 2 patients. The success rate of external jugular vein use was 95.1%.

**Conclusions:** The findings obtained in this study suggest that placement of a central catheter using an external jugular vein is an appropriate option. Application difficulties can be overcome. Mechanical and early complications are negligible compared to percutaneous blind techniques. The use of the external jugular vein route is easy, requires less equipment, has few complications, and the success of the procedure is a preoperatively predictable technique. External jugular vein catheterization is a better alternative compared to the Seldinger technique, in the absence of ultrasonography, which enhances the success of the percutaneous technique, and in cases where blind techniques, such as bleeding diathesis, may be unfavorable.

**Keywords:** External jugular vein, Central venous access, Children

## Highlights

- Bone marrow transfer has begun to be widely used in complicated conditions.
- The widespread use of bone marrow transfer has increased the incidence of complications as well.
- The use of external jugular vein catheterization, which is a safer route compared to the blind route of administration.

## Background

A central catheter should be inserted in patients who must use high-volume, long-term, intense drugs, which have adverse effects on the vascular wall, and patients whose systemic fluids and pressures are required to be followed up. Indwelling catheters are increasingly

Correspondence: [drmustafaakman@yahoo.co.uk](mailto:drmustafaakman@yahoo.co.uk)  
Department of Pediatric Surgery, Faculty of Medicine, Nisa Hospital, Medipol University, Fatih Caddesi, Yenibosna, 34197 İstanbul, Turkey



© The Author(s). 2021 **Open Access** This article is licensed under a Creative Commons Attribution 4.0 International License, which permits use, sharing, adaptation, distribution and reproduction in any medium or format, as long as you give appropriate credit to the original author(s) and the source, provide a link to the Creative Commons licence, and indicate if changes were made. The images or other third party material in this article are included in the article's Creative Commons licence, unless indicated otherwise in a credit line to the material. If material is not included in the article's Creative Commons licence and your intended use is not permitted by statutory regulation or exceeds the permitted use, you will need to obtain permission directly from the copyright holder. To view a copy of this licence, visit <http://creativecommons.org/licenses/by/4.0/>.

placed in children due to total parenteral nutrition, aggressive chemotherapy, and bone marrow transfer programs. The central catheter not only strengthened the physician's hand but also affected the patient's comfort positively [1].

As with all procedures, the success of the central venous catheterization (CVC) procedure is highly dependent on the experience of the practitioner and the anatomical and topographic structure of the patient [2]. Although facilitative ultrasonography (USG) has become routine, the most widely used percutaneous Blind Seldinger technique remains to bother with severe complications and stands before us as a problem to be solved [3–5].

It is strongly recommended in the Department of Health and Human Services Centers for Disease Control and Prevention guidelines to prefer the subclavian vein, but the Seldinger technique and internal jugular vein (IJV) are predominantly preferred across the world. Complications should be considered primarily in the CVC insertion procedure [6–8]. Thirty-five serious pathologies were described when these complications were detailed [9]. Of these, early complications are mechanical, preventable, and may occur during or shortly after catheter insertion. Prevention of late complications with the changes in mechanical techniques is controversial [10].

In the absence of USG, the option of an external jugular vein (EJV) with fewer complications seems a viable alternative, particularly for practitioners who have not mastered the Seldinger technique. The EJV topography that may lead to failure of the blinded technique warrants additional methods to improve success during planning [11]. Although it has a cosmetic disadvantage, EJV use can be recommended as the safest way in accurately selected patients. It has been demonstrated in our study that the EJV route can be used safely, and drawbacks of the procedure can be eliminated [12].

## Methods

This is a prospective, observational trial that included 100 of 281 patients who were included in the bone marrow transfer program and referred for CVC between 2011 and 2013 and were considered eligible for IJV catheterization at the first examination. This study complied with the document of "World Medical Association Declaration of Helsinki: ethical principles for medical research involving human subjects." All patients were informed verbally and in writing before the procedure, and informed consent was obtained from them.

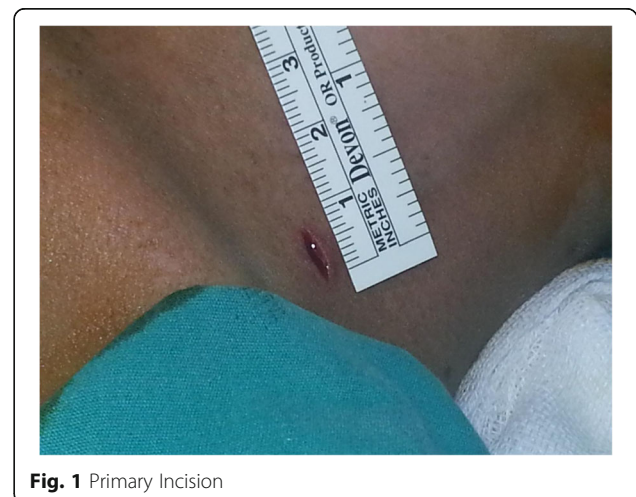EJV traces of the patients were assessed in the Trendelenburg position or by Valsalva maneuver and then marked. Patients whose EJV could not be easily palpated were excluded from the study. The side of the intervention was chosen by the appearance of the vein. The

bleeding-coagulation assessment of the patients was strictly followed. Antibiotic prophylaxis was not administered. A Hickman® (Bard Access Systems, USA) double-lumen catheter was inserted in all patients. A guidewire was not used. Patient demographics, catheter size, inserted vessel, the duration of the procedure, early complications, and all processes of the procedure were recorded. Late complications were excluded from the study.

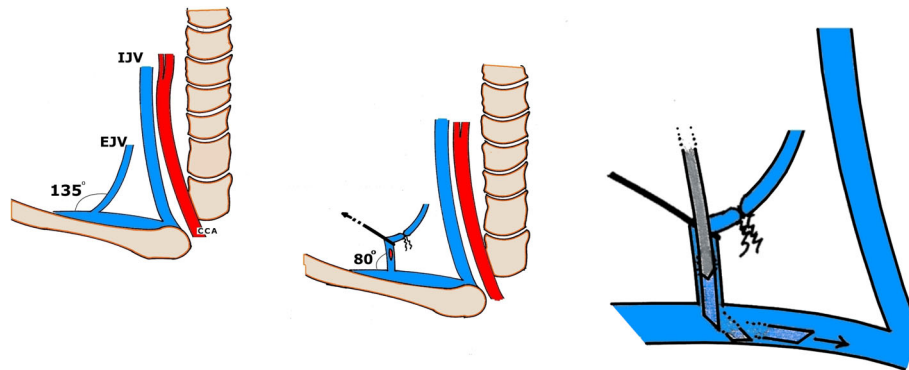
It was the first-time central vascular access for all patients. Vascular preference and implementation were performed by a single surgeon. The procedure was performed under general anesthesia and with fluoroscopic control.

The head in the hyperextension position was turned in the opposite direction and started in a position that was placed in a gentle Trendelenburg. A 5–7 mm transverse skin incision was made on the EJV trace, 2 cm proximal to the clavicle (Fig. 1). The EJV was exposed via blunt dissections from this incision and slung. The size of the catheter to be used was decided at this stage (Fig. 1). A tunnel was generated under the skin by making the incisions at the locations ipsilateral to EJV, the anterior axillary line projection, and lateral to the musculus pectoralis major, suitable to the diameter of the tunneller. The line was measured with the tip of the catheter in the right atrium and the cuff 2 cm close to the distal incision, and the excess was cut at an angle of 45°. The catheter was pushed through the second incision into the supraclavicular incision using tunneller, and its tip was withdrawn from the skin.

The proximal part of the EJV was ligated, and venotomy was performed. The suspended EJV was pulled toward the subclavian vein, changing the subclavian-EJV obtuse angle to an acute angle [Figs. 2, 3]. The catheter was pushed under fluoroscopic control to ensure that its tip was in the right atrium (Fig. 4). During the passage



**Fig. 1** Primary Incision



**Fig. 2** How to correct angle

of the catheter to the subclavian vein or its return to the atrium, it was observed that the rotation movement made by the catheter was facilitating. It was sutured once over the EJV using a 3/0 monofilament suture. The skin openings were closed, and the catheter was heparinized.

#### Exclusion criteria

Patients whose direct EJV appearance was incompatible with catheter size and who could not be palpated at the first examination were excluded from the study.

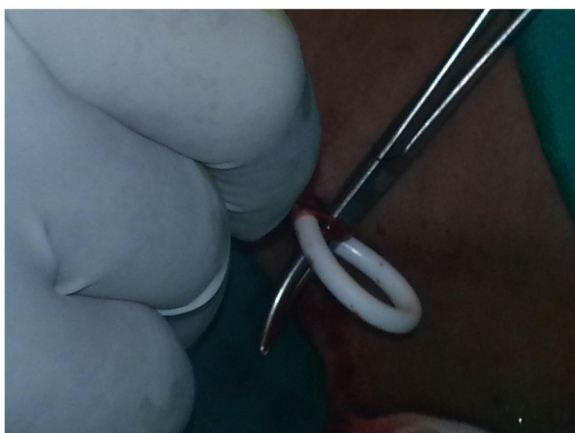
#### Results

An indwelling central catheter was placed in 100 patients, all of whom had been involved in the bone marrow transfer program. Sixty-one percent of the patients were females, and 39% were males, while their mean age was 8, and the median age was 9, with their ages ranging between 6 months and 15 years. While 8f (80%) double-lumen catheters were placed in 80 patients, 6F (15%) double-lumen catheters were placed in 15 patients, and 12f (5%) double-lumen catheters were

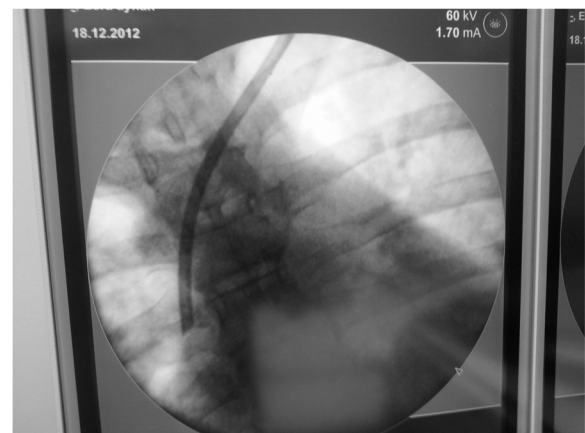used in 5 patients. Right EJV was preferred in 80 patients and left EJV in 20 patients as the first intervention side. EJV traction was performed in all patients. The success rate of inserting a catheter into the preferred vein before skin incision was 95% (Table 1: Details). A catheter was placed in the contralateral EJV in 3 of the 5 patients in whom another vein was used, and in IJV with venotomy through the extended incision in 2 patients (Table 2).

The mean duration of anesthesia was 35 min (25 to 45) in patients who underwent single vessel intervention. In the cases where the first attempt was unsuccessful, it took 45, 50, and 55 min, respectively, in those using EJV, while it took 45 and 50 min in 2 cases where IJV was used.

Of the 5 patients in whom the intervention attempt failed, 2 patients in whom IJV was preferred had vascular smallness, while patients in whom the contralateral EJV was preferred had positional advancement problems of the catheter. Vascular continuity was achieved by repairing the venotomy of 2 patients who underwent the procedure through IJV. Both of these two patients had no



**Fig. 3** The Insertion



**Fig. 4** Final Location of the Catheter

**Table 1** Details

		<b>Total</b>
Characteristics, age, sex	Number of the patients	100
	Number of the attempts	103
	Number of the used devices	103
	Age (av, med, range)	8, 9, 6 m-15
	Sex M/F (n)	39/61
Diagnosis (n)	Thalassemia	71
	Hemoglobinopathy	15
	Severe aplastic anemia	7
	Sickle cell anemia	5
	Severe immunodeficiency syndromes	2
Device type (n)	Hickman/Broviac	103
Tube size (French) (n)	6	15 (+3*)
	8	80
	12	5
Venous access attempt (n)	Right external jugular vein	83
	Left external jugular vein	20
	Internal jugular vein	2
	Subclavian vein	0
Successful venous access (n)	External jugular vein	98
	Internal jugular vein	2
First attempt's laterality (n)	Right side	80
	Left side	20
Failed laterality of EJV (n)	Right side	1
	Left side	4
Successful laterality of EJV (n)	Right side	82
	Left side	16
IJV sides (n)	Right side (failure of right side EJV)	1
	Left side (failure of left side EJV)	1
Duration anesthesia average (min-max) min	Right side's EJV with 1st attempt (n=80)	35 (25-45)
	Left side's EJV with 1st attempt (n=20)	35 (25-45)
	2nd attempt to right side (n=3)	50 (45-55)
	2nd attempt to left side (n=0)	NA
	Right IJV (secondary to failed EJV) (n=1)	45
	Left IJV (secondary to failed EJV) (n=1)	50

NA not applicable

\*Second attempt, smaller device

**Table 2** Unsuccessful EJV catheter insertions' details, reason, age, and gender

	Reason	Age	Gender	Laterality	
				First attempt	Second attempt
Case 1	Small vein	1	Girl	Right	Ipsilateral IJV
Case 2	Small vein	3	Girl	Left	Ipsilateral IJV
Case 3	Unable to manipulate	9	Boy	Left	Contralateral EJV
Case 4	Unable to manipulate	13	Boy	Left	Contralateral EJV
Case 5	Unable to manipulate	15	Girl	Left	Contralateral EJV

early complications (Fig. 5). None of the patients required 3 interventions. No arterial and nerve damage, pneumothorax and hemothorax, or other mechanical complications occurred. Ninety-eight (95.1%) successful IJV catheterization was performed through 105 interventions and 103 incisions (Fig. 5).

The catheter size was reduced in accordance to vessel diameter in two of five cases in which catheterization failed and a switch to contralateral size was required. In three cases, a new device was used. Of these, the new device was used due to technical issues in one case, while a smaller catheter size compatible with vascularity was selected in two cases. Of left-sided cases with catheterization failure, challenges in manipulation played a role in three, while it failed to reach a stage where manipulation was assessed. The IJV was preferred due to the presence of an unexpectedly small vessel in one of 80 right-sided EJVs cases. As a principle, the contralateral vessel was preferred in cases of manipulation difficulties; however, the small caliber of IJV was considered a sign for the switch to IJV.

In our study, no early catheter-related infection or thrombosis was detected.

## Discussion

The use of a central venous catheter in children, which had been defined by Broviac (1973), was described by Hickman (1979) [13, 14]. Increasing treatment options and providing comfort to the patient has enabled CVC to become widespread rapidly [15]. In many clinics, the success of treatment is increased in complicated cases, such as the treatment of large-surface burns, chemotherapy, hemodialysis, or plasmapheresis by placing a central catheter immediately after the patient's admission [1]. Regarding the frequency of use, the most used veins are subclavian and internal jugular veins, or femoral and

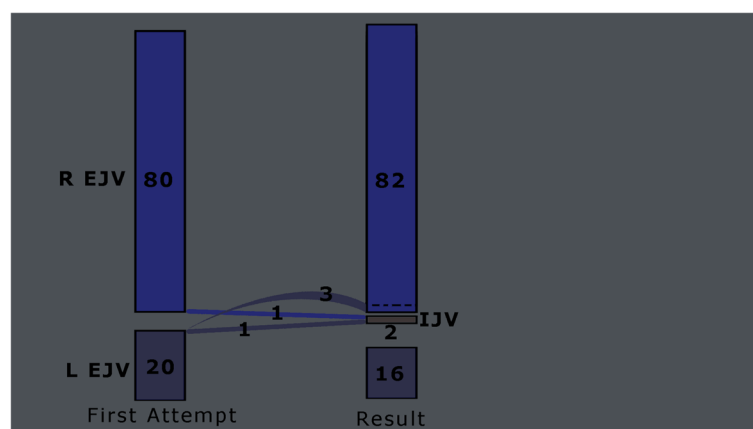
external jugular veins, respectively. Besides, the most common method is the Seldinger technique [16].

The widespread use of CVC has increased the incidence of catheter-related complications. Of these complications, early complications include air embolism, arrhythmia, hematoma, hemo/pneumothorax, hydro/chylothorax, cardiac perforation, cardiac tamponade, vascular, and nerve injuries. Rare but fatal complications, such as the intrusion of the guidewire into the vein, vena cava superior or aortic injury, catheter fractures are also considered in the early complications group. These are all mechanical incidents that may occur during catheter insertion and can be prevented as well [6–8, 10, 17].

Late complications, such as thrombosis, vena cava superior syndrome, arteriovenous fistula, arterial and venous aneurysm, venous thrombosis and various infections, endocarditis, sepsis, and secondary complications are not related to catheter insertion mechanics. Although early complications can be prevented by changing and developing the technique, it is controversial for late complications. The situation is not different for children [10].

Despite the corrective and facilitating effects of USG, the complications of the Seldinger technique remain to bother. The longer learning curve, the proximity of the used vein to the major structures, and the blindness of the procedure are the main factors. Blind mechanical arterial injuries are more fatal in children [17].

It has been demonstrated in many studies that the complication rate, which reaches 12% in the Seldinger technique, is lower in the cutdown technique. Complications, such as pneumothorax, hemothorax, vascular or brachial plexus injuries, catheter pinch-off, and catheter migration, which are common in the percutaneous technique, do not occur in the cutdown technique [12]. Opting for the EJV cutdown technique means avoiding these complications.



**Fig. 5** Second attempts to



The EJV, which is also termed the vena cutanea colli posterior, arises near the parotid gland and runs through the superficial and deep fascia toward the supraclavicular fossa [17, 18]. Two types of EJV were found in Shima et al.'s study, and 83% of them had single EJVs, whereas 17% had double EJVs [19]. Their findings revealed that there might be 3 EJVs on the same side. The EJV can advance in any deeper plane or behind the sternocleidomastoid muscle. These variations indicate the crucially detailed assessment before the procedure. The advancement of the vein under the skin both provides direct visualization and facilitates its dissection and manipulation.

It is considered that it is a suitable alternative for practitioners who have not mastered the Seldinger technique to prefer the EJV in case they need vascular access in the absence of USG. It is put forward in our study that the EJV could be used effectively by demonstrating a maneuver that facilitates safe CVC insertion through the EJV. We suggest that the insertion angle of the subclavian vein, which is one of the CVC placement obstacles through EJV, can be overcome with the maneuver we have described. Instead of facing the fatal complications of the Seldinger technique, it may be realistic for appropriate patients to use this safe and less complicated technique.

The anatomical structure of pediatric patients, the required catheter diameter, and the existing vessel diameter incompatibilities raise the significance of technical details [11, 18, 20, 21]. Thanks to the use of EJV, which is located just under the skin and can be decided without cutting the catheter to be inserted, percutaneous procedure, which is highly dependent on the experience of the practitioner and technical possibilities, such as USG, can be avoided [3–5, 22]. There are few series revealing the use of EJV, particularly in children. The reason for this can be the presence of factors that may reduce the success, such as thin vascular structure and not being suitable for percutaneous technique.

There are inconsistencies among studies on the anatomy of cervical vascularity. Among individual variations described by Pikkieff et al., as similar to duplications that reduce vessel diameter, jugular vein trace that makes it challenging to access vessel is not infrequent. The vein may have different courses from its origin, the junction of the posterior division of the retromandibular vein and the posterior auricular, ipsilateral subclavian vein. It has been shown that there are variations in the EJV termination angle. This topographic state that may result in manipulation difficulties despite eligible EJV diameter is the base of our study.

This is a topographic obstacle that constrains the use of the EJV regarding the placement of a central catheter

[18]. As seen in the studies conducted by Dalip et al. and Alshafei et al., the angle at which EJV enters the subclavian vein is almost always an obtuse angle [11]. This angle is corrected by suspending and pulling the EJV in procedures, which is performed close to the clavicle and becomes an acute angle; hence, the topographic drawback that prevents the passage of the catheter is eliminated (yirmiüç [23]). Thus, it is not surprising that the success of percutaneous EJV catheterization in the study of Romao et al. was lower [16].

EJV CVC, which can be obtained with high success from the first application on accurately selected cases, also gains value by being a sacrificial vein (yirmidört [24]). EJV attachment or loss, selected as the primary procedure, and the trauma caused by the surgical procedure to be performed do not affect the patient.

Complications of the cutdown technique have been revealed to be between 0 and 10% in clinical studies. No early complications were encountered in our study, and the success of EJV catheterization was 98% [4, 6–9, 17, 22]. Although Freeman et al. reported that infection rates are lower in the percutaneous technique, catheter infections typically occur in the late period and due to use. Avoiding the use of EJV due to the potentiality of infections cannot be considered a correct argument [25].

Qureshi, Kumar et al. suggested that complication rates were higher despite using sonography by emphasizing vascular access, which continues to be relevant. Hoeatam et al. reported that the reason for preferring jugular access under fluoroscopy guidance was the shorter duration of the procedure without the need for sonography. Meliota et al. indicated the significance of vascular diversity by demonstrating axillary artery use [26–28].

Naik et al. showed that vascular access was challenging in pediatric patients faced due to complex surgeries, chronic diseases, multiple hospitalizations and prolonged treatment, emphasizing the need for imaging techniques and fluid therapy via non-vascular routes [29].

Balsorano suggested that catheter-related problems were more commonly encountered in the real-world. In the review by Fulvio Pinelli et al., it was reported that interventions, such as peripherally inserted central catheters (PICCs), are commonly used and that EJV has become critical as it seems to be an expandable vessel when compared to subclavian vein and IJV [30, 31].

In the study conducted by Johansen et al., burn, cutaneous infections, vascular anomalies, thrombosis, and complications, such as pneumothorax, were emphasized in the selection of catheterization sites. In addition, the authors suggested that large-diameter devices should be considered in disorders requiring higher flows, such as dialysis, and that duration of catheter use should be considered [32].

## Conclusion

EJV cutdown is a simple technique, safe, has a short learning curve and is fast, effective in the treatment and can easily overcome application challenges, and has fewer complications. The number of medical devices and tools that are required is few. Despite the anatomical difficulties, its success among children is not low. The use of internal jugular and subclavian veins should be avoided as much as possible due to the high complication rates and as the vein that is used is not a sacrificial vein, and the femoral vein should remain the last option due to the difficulty of use and hygienic problems.

Although it has been revealed that high CVC success rates can be achieved by surgical EJV, it is not widely used yet. The reasons may be the ignoring of complications, the ability to successfully tackle complications, the ability of non-surgeons to use the Seldinger technique, the need for an operating room, and the lack of fluoroscopy during the procedure. The use of the EJV route as a routine and the first option needs to be assessed with case series. We aimed in our study to tackle early mechanical complications and insertion failures by describing a technique that facilitates the insertion of an indwelling catheter via EJV, which can be performed in pediatric patients easily. We hope that our research will encourage further studies.

## Importance of the study

The contribution of this study to the literature is that this study emphasizes the effectiveness of EJV, which is not used routinely yet is a practical central catheterization technique. It has been shown in the study that the procedure can be performed successfully even in the absence of sophisticated medical devices, such as USG.

## Further studies

Practical guidelines and protocols should be established, and the use of EJV should be encouraged in further studies, which are more comprehensive and include larger populations. Topographical difficulties should be investigated and detailed.

## Limitations

This study has some limitations. The primary limitation of the study is that the study population is inadequate to demonstrate the potential complications of the procedure. In addition, the technique itself has some limitations as well, such as the size of the vein and topographic variations. These limitations of the technique might affect the findings obtained in the present study.

## Abbreviations

EJV: External jugular vein; IJV: Internal jugular vein; USG: Ultrasonography; CVC: Central venous catheterization

## Acknowledgements

The author would like to express our gratitude to Mr. Mehmet Akif Yeşilipek and Mrs. Gülsün Karasu, Professor of Bone Marrow—Stem Cell Transplantation Center for their kind efforts to support this project.

## Author's contributions

Mustafa Akman, single surgeon and author contribution. The author(s) read and approved the final manuscript.

## Funding

The author has declared that no financial support was received from any organization for the submitted work.

## Availability of data and materials

Data was collected from each patient and reported.

## Declarations

### Ethics approval and consent to participate

All requirements of "World Medical Association Declaration of Helsinki: ethical principles for medical research involving human subjects" were obeyed, and standard techniques, principles and medications were used according to the literature and textbooks, and new medications and techniques were not used. In this study, all requirements of applications and medications were strictly obeyed according to National Ethics rules.

### Consent for publication

The participant has consented to the submission of the article to the journal. The importance of the study was explained verbally to the participants and written informed consent was obtained from all individual participants included in the study.

### Competing interests

The authors declare that they have no conflict of interest.

Received: 11 December 2020 Accepted: 23 February 2021

Published online: 17 May 2021

## References

- Kolaček S, Puntis JWL, Hojsak I, Braegger C, Bronsky J, et al. ESPGHAN/ESPEN/ESPR/CSPEN guidelines on pediatric parenteral nutrition: venous access. *Clin Nutrition*. 2018;37(6):2379–91. <https://doi.org/10.1016/j.clnu.2018.06.952>.
- Eisen LA, Narasimhan M, Berger JS, Mayo PH, Rosen MJ, et al. Mechanical complications of central venous catheters. *J Intensive Care Med*. 2006;21(1):40–6. <https://doi.org/10.1177/0885066605280884>.
- He C, Vieira R, Marin JR. Utility of ultrasound guidance for central venous access in children. *Pediatr Emerg Care*. 2017;33(5):359–62. <https://doi.org/10.1097/PEC.0000000000001124>.
- Pietroboni PF, Carvajal CM, Zuleta YI, Ortiz PL, Lucero YC, et al. Landmark versus ultrasound-guided insertion of femoral venous catheters in the pediatric intensive care unit: an efficacy and safety comparison study. *Med Intensiva*. 2020;44(2):96–100. <https://doi.org/10.1016/j.medin.2019.07.014>.
- Arul GS, Lewis N, Bromley P, Bennett J, et al. Ultrasound-guided percutaneous insertion of Hickman lines in children. Prospective study of 500 consecutive procedures. *J Pediatr Surg*. 2009;44(7):1371–6. <https://doi.org/10.1016/j.jpedsurg.2008.12.004>.
- McGee DC, Gould MK. Preventing complications of central venous catheterization. *N Engl J Med*. 2003;348:1123–33. <https://doi.org/10.1056/NEJMra011883>.
- Bagwell CE, Salzberg AM, Sonnino RE, Haynes JH, et al. Potentially lethal complications of central venous catheter placement. *J Pediatr Surg*. 2000;35(5):709–13. <https://doi.org/10.1053/jpsu.2000.6029>.
- Abdelmoneim HM, Ibrahim HM, Ahmed AR, Mohammed KA. Mechanical complications of central venous catheters in pediatric intensive care unit (PICU). *Egypt J Hospital Med*. 2020;78(1):142–8. <https://doi.org/10.12816/EJHM.2020.68484>.

9. Silberzweig JE, Sacks D, Khorsandi AS, Bakal CW. Reporting standards for central venous access. *J Vasc Interv* 2003 (14)9, 443-452. doi: <https://doi.org/10.1097/01.nvi.0000094617.61428.bc>.
10. Nixon SJ. Death after inserting Hickman line was probably avoidable. *BMJ*. 2002;324(7339):739. <https://doi.org/10.1136/bmj.324.7339.739/b>.
11. Dalip D, Iwanaga J, Loukas M, Rod J, Oskouian RJ, Tubbs RS. Review of the variations of the superficial veins of the neck. *Cureus*. 2018;10(6):e2826. <https://doi.org/10.7759/cureus.2826>.
12. Newman BM, Jewett TC Jr, Karp MP, Cooney DR. Percutaneous central venous catheterization in children: first line choice for venous access. *J Pediatr Surg*. 1986;21(8):685–8. [https://doi.org/10.1016/s0022-3468\(86\)80387-6](https://doi.org/10.1016/s0022-3468(86)80387-6).
13. Broviac JW, Cole JJ, Scribner BH. A silicone rubber atrial catheter for prolonged parenteral alimentation. *Surg Gynecol Obstet*. 1973;136:602–6.
14. Hickman RO, Buckner CD, Clift RA, Sanders JE, Steward P, et al. A modified right atrial catheter for access to the venous system in marrow transplant recipients. *Surg Gynecol Obstet*. 1979;148(6):871–5.
15. Alshafei A, Tareen F, Maphango N, White D, O'Connor B, et al. Open tunneled central line insertion in children — external or internal jugular vein? *Journal of Pediatric Surgery*. 2018;53:2318–21. <https://doi.org/10.1016/j.jpedsurg.2018.07.004>.
16. Romao RLP, Valinetti E, Tannuri ACA, Tannuri U. Percutaneous central venous catheterization through the external jugular vein in children: improved success rate with body maneuvers and fluoroscopy assistance. *J Pediatr Surg*. 2008;43(7):1280–3. <https://doi.org/10.1016/j.jpedsurg.2007.08.052>.
17. Goutail-Flaud MF, Sfez M, Berg A, Laguenie G, Couturier C, et al. Central venous catheter-related complications in newborns and infants: a 587-case survey. *J Pediatr Surg*. 1991;26(6):645–50. [https://doi.org/10.1016/0022-3468\(91\)90001-a](https://doi.org/10.1016/0022-3468(91)90001-a).
18. Pikkieff E. Subcutaneous veins of the neck. *J Anatomy*. 1937;72:120–7.
19. Shima H, von Luedinghausen M, Ohno K, Michi K. Anatomy of microvascular anastomosis in the neck. *Plast Reconstr Surg*. 1998;101(1):33–41. <https://doi.org/10.1097/00006534-199801000-00007>.
20. Comert E, Comert A. External jugular vein duplication. *J Craniofac Surg* 2009;20: 2173Y2174. doi: <https://doi.org/10.1097/SCS.0b013e3181bf0248>.
21. Deslaugiers B, Vaysse P, Combes JM, Guitard J, Moscovici J, et al. Contribution to the study of the tributaries and the termination of the external jugular vein. *Surg Radiol Anat*. 1994;16(2):173–7. <https://doi.org/10.1007/BF01627591>.
22. Omid M, Rafiei MH, Hosseinpour M, Memarzade M, Riahinejad M. Ultrasound-guided percutaneous central venous catheterization in infants: learning curve and related complications. *Adv Biomed Res*. 2015;4:199. <https://doi.org/10.4103/2277-9175.166135>.
23. Kopuz C, Akan H. The importance of the angulation and termination of external jugular vein in central venous catheterization in newborn. *Okajimas Folia Anat Jpn*. 1996;73(2–3):155–9. [https://doi.org/10.2535/ofaj1936.73.2-3\\_155](https://doi.org/10.2535/ofaj1936.73.2-3_155).
24. Chakravarthy M, Krishnamoorthy J, Nallam S, Kolar N, Faris A, et al. External jugular venous route for central venous access: our experience in 563 surgical patients. *J Anesth Clin Res*. 2011;2:6. <https://doi.org/10.4172/2155-6148.1000144>.
25. Freeman JJ, Gadepalli SK, Siddiqui SM, Hirschl RB. Improving central line infection rates in the neonatal intensive care unit: effect of hospital location, site of insertion, and implementation of catheter associated bloodstream infection protocols. *J Pediatr Surg*. 2015;50(5):860–3. <https://doi.org/10.1016/j.jpedsurg.2015.02.001>.
26. Polat TB. Use of percutaneous carotid artery access for performing pediatric cardiac interventions: single-center study. *Ann Pediatric Cardiol*. 2019;13: 16–24.
27. Hoetama E, Prakoso R, Roebiono PS, Sakidjan II, Kurniawati Y, et al. Balloon pulmonary valvuloplasty in neonates with critical pulmonary stenosis: jugular or femoral. *Ann Pediatr Cardiol*. 2019;13:11–5. [https://doi.org/10.4103/apc.APC\\_14\\_19](https://doi.org/10.4103/apc.APC_14_19).
28. Meliota G, Lombardi M, Zaza P, Tagliente MR, Vairo U. Balloon angioplasty of aortic coarctation in critically ill newborns, using axillary artery access. *Ann Pediatr Cardiol*. 2019;13:67–71. [https://doi.org/10.4103/apc.APC\\_2\\_19](https://doi.org/10.4103/apc.APC_2_19).
29. Naik VM, Mantha SS, Rayani BK. Vascular access in children. *Indian J Anaesth*. 2019;63:737–45. *J Vasc Access*. 2020;1129729820904885. [https://doi.org/10.4103/ija.IJA\\_489\\_19](https://doi.org/10.4103/ija.IJA_489_19).
30. Balsorano P, Virgili G, Villa G, Pittiruti M, Romagnoli S, et al. Peripherally inserted central catheter-related thrombosis rate in modern vascular access era—when insertion technique matters: a systematic review and meta-analysis. *J Vasc Access*. 2020;21(1):45–54. <https://doi.org/10.1177/1129729819852203>.
31. Pinelli F, Cecero E, Degl'Innocenti D, Selmi V, Giua R, et al. Infection of totally implantable venous access devices: a review of the literature. *J Vasc Access* 2018 19 (3) 230-242. doi: <https://doi.org/10.1177/1129729818758999>.
32. Johansen M, Classen V, Muchantef K. Long-term IV access in paediatrics - why, what, where, who and how. *Acta Anaesthesiol Scand*. 2020;00:1–10. <https://doi.org/10.1111/aas.13729>.

## Publisher's Note

Springer Nature remains neutral with regard to jurisdictional claims in published maps and institutional affiliations.

**Submit your manuscript to a SpringerOpen<sup>®</sup> journal and benefit from:**

- Convenient online submission
- Rigorous peer review
- Open access: articles freely available online
- High visibility within the field
- Retaining the copyright to your article

---

Submit your next manuscript at ► [springeropen.com](https://www.springeropen.com)