


ORIGINAL RESEARCH

Open Access



Single port laparoscopic-assisted ovarian cystectomy using optical forceps in neonates: a brief technical report

Hanan Said^{1*} , Yasmine Shafik¹, Mohammed Faiz¹, Osama Bawazir², Obada Alhallaq¹, Asmaa Abdulmoez³ and Yasser Al Dahshan⁴

Abstract

Background: The management of neonatal ovarian cysts is often demanding. However, offering surgery as a definitive treatment for patients who lack easy access to healthcare for follow-up is reasonable. Minimally invasive, ovary-sparing surgery provides benefits, including shorter operative times, hospital stay, and superior cosmesis. The novel modification described here renders added value because it utilizes readily available and reusable instruments, averts the need for multiple ports and large incisions, and is essentially time-saving.

So, the aim of the study is to evaluate the safety and feasibility and describe the use of optical forceps during single-port laparoscopic-assisted (SPLA) ovarian cystectomy in a specific cohort of neonates with simple/complicated ovarian cysts.

Results: Neonates who required ovarian cystectomy/salpingo-oophorectomy, admitted from January 2015 to December 2019 and fulfilled the inclusion criteria, were treated with optical forceps during SPLA. After the surgery, we put in place a follow-up protocol to monitor complications and recurrences.

Twenty-one neonates were included. The average gestational age was 37.2 ± 1.6 weeks, operative time was 43.2 ± 2.4 min, and length of hospital stay was 2.4 ± 0.5 days. In our experiment, there was no encounter with complications, recurrences, or ones that required conversion to laparotomy, nor did we require the use of extra ports.

Conclusion: SPLA procedures using optical forceps for managing neonatal cysts requiring surgery appear to be a safe and achievable option by allowing complete visualization of the cyst/lesion. It also has an excellent cosmetic result with a near-normal umbilicus scar. Further research is required to compare this method to open and laparoscopic standards.

Keywords: Optical forceps, Neonates, Ovarian cysts, Laparoscopy

Background

With the increasing utilization of routine prenatal ultrasound, the detection of ovarian cysts has risen dramatically [1]. Currently, they are the most frequently encountered abdominal tumors in female fetuses and

newborns. Clinically, significant ovarian cysts in live births are estimated to be one in 2500 [2, 3].

Ovarian cysts would be classified either as simple or complex based on ultra-sonographic appearance. Simple cysts are anechoic, have smooth and thin walls, demonstrate posterior acoustic enhancement, and lack solid components, septations, or internal flow [4]. Observation is the management of choice for all asymptomatic neonatal cysts and obviates the need for an invasive

*Correspondence: hananmasaid@gmail.com

¹ Department of Pediatric Surgery, International Medical Center, Jeddah, Saudi Arabia

Full list of author information is available at the end of the article

intervention in approximately half of all neonates with complex cysts [1].

Doing the procedure through laparoscopy is favored over its counterpart, laparotomy, for multiple reasons: faster recovery, improved cosmesis, and shorter hospital stay [2, 3, 5]. Several laparoscopic techniques have been described in the literature for the management of simple ovarian cysts or those that have become torsed. However, all of these methods either required the use of multiple ports or enlarging the entrance incision to facilitate specimen retrieval [5–10]. To maneuver, a way around those mentioned above and still perform a quick and safe surgery under-maintained direct vision. This study aims to detail the steps of single-port laparoscopic-assisted (SPLA) ovarian cystectomy/salpingo-oophorectomy using optical forceps and demonstrate its safety through reporting outcomes in 21 cases. In the English-language literature, this is the first report utilizing this particular method for our population.

Methods

This study is a prospective analysis of 21 consecutive neonates who were selected to undergo SPLA ovarian cystectomy/salpingo-oophorectomy from January 2015 to December 2019. Procedures were carried out by two senior pediatric surgery consultants operating at two separate tertiary care centers in Jeddah, Saudi Arabia. The study was approved by the institutional ethical committee, and informed consent was obtained from the caregivers of all neonates. The nature of the procedure was explained clearly, along with its indications, expected complications, and available alternatives. All procedures performed were in line with ethical standards, the Helsinki Declaration and its later amendments. To standardize the process at both institutes, the surgeons agreed on the steps of the procedure along with inclusion and exclusion criteria as described below and ensured the availability of all equipment before the beginning of the study.

Inclusion and exclusion criteria

In this study, we included medically cleared neonates diagnosed with simple ovarian or hemorrhagic cysts greater than or equal to 5cm at birth. The diagnosis was a two-step procedure: at first, they were diagnosed before birth and confirmed after. Lastly, they must live in rural areas without easy access to healthcare.

Our study excluded asymptomatic neonatal cysts regardless of size whose parents agree to comply with observation and follow-up and abdominal cysts of non-ovarian origin.

At our centers, the benefits and risks of surgery and conservative management are discussed as a treatment

option when neonates have cysts larger than 5cm and families live far away from centers that can offer care.

Preoperative workup

Diagnosis of a cystic abdominal lesion was often easily detected by ultrasonography. All neonates had routine preoperative lab work and markers CA 19-9 and CA-125 withdrawn.

Operative procedure

Under general anesthesia, neonates were placed in the supine position, then prepped and draped. We created a 5-mm longitudinal trans-umbilical incision, and we gained access into the peritoneum via the open Hasson technique. We ligated the umbilical vein and arteries to prevent the occurrence of air embolism [11, 12]. Afterwards, we introduced a 5-mm port, and we increased the pressure to 8mmHg and a flow rate of 2L/min to achieve pneumoperitoneum. The entire abdominal cavity was then explored, and the presence of a simple/hemorrhagic ovarian cyst or torsion was noted using a 5-mm 30° laparoscope. In the case of a simple/hemorrhagic ovarian cyst, a transabdominal needle with a syringe was used to aspirate cyst contents under vision, and the aspirate was sent for cytology (Fig. 1). We then removed the laparoscope. We then introduced a 0° 29-mm optical non-crushing forceps (Karl Storz, Germany) via the 5-mm port to grasp and exteriorize the cyst/adnexa under vision (Fig. 2). This instrument is generally used for the retrieval of foreign bodies during bronchoscopy.

Depending on the presence or not of torsion, we performed a cystectomy with complete preservation of the ovarian tissue \pm repair of the ovary or performed a salpingo-oophorectomy. All excised specimens were sent for histopathology. Finally, the abdominal closed in

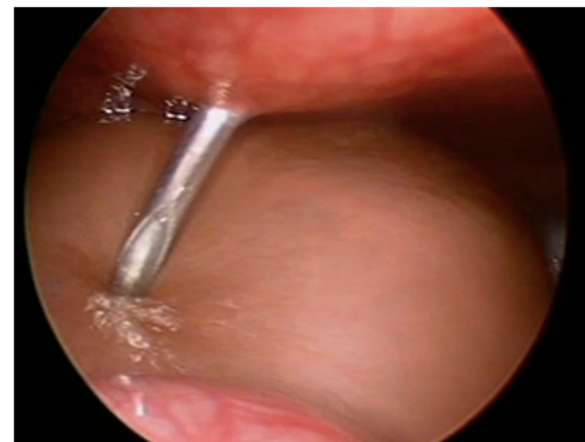

Fig. 1 Needle aspiration of the ovarian cyst

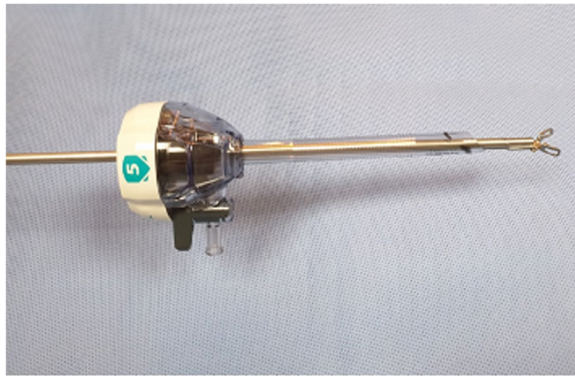


Fig. 2 Bronchoscopy optical forceps in a 5-mm port

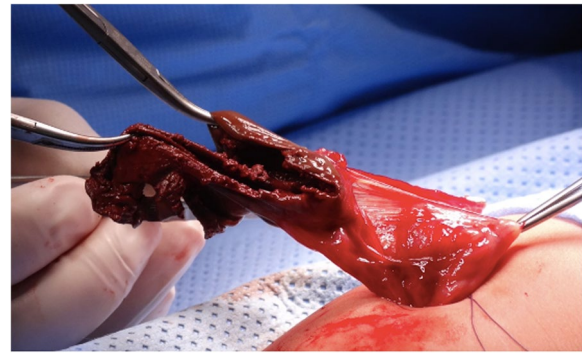


Fig. 3 Gross appearance of the necrotic tissue attached to the colon that was excised

anatomical layers by 4/0 Vicryl and skin sealed by 6/0 monocryl.

Postoperative protocol

Antibiotics (Cefuroxime & Gentamicin) were given for the first 24 h post-procedure. Progress to full feeds was achieved during the first postoperative day and discharged on the 2nd or 3rd postoperative day. Follow-up entailed a clinical assessment at 2 weeks, and ultrasound assessments at 2, 6, 12, 24, and 36 months after discharge.

Statistical analysis

The statistical analysis was carried out using SPSS Version 27.0. The analyzed data included gestational age, age at presentation, cyst size, and operative time as mean and standard deviation.

Results

A total of 23 neonates presented to our centers; 2 were excluded because they were discovered to have mesenteric cysts intraoperatively. Of the remaining enrolled 21 patients, 12 had right ovarian cysts, 6 had left-sided cysts, and 3 had bilateral cysts. Our patients were 37.2 ± 1.6 weeks old on average. The mean age on the day of surgery was 5.4 ± 4.2 days. Fifteen were diagnosed antenatally and 6 postnatally. Preoperative CA 19-9 and CA-125 levels were within normal for all patients. The mean cyst size operated upon was 6.8 ± 0.9 cm (calculated using the largest diameter). Eleven cysts were simple while the remaining ten were hemorrhagic, 4 of which were torsed. No cysts turned out malignant, and a small amount of remnant ovarian tissue was found on histopathological examination of one specimen (Fig. 3). Mean operative time (measured from the time of skin opening to skin closure) was 43.2 ± 2.4 min. Conversion to laparotomy or multiple port laparoscopy was not needed for any of the cases. The average length of hospital

stay was 2.4 ± 0.5 days, and all reached full feed by the end of the 1st 24 h postoperative. No complications or recurrence in our series. The umbilical scar was almost invisible at the 6-month-follow-up mark. Table 1 details findings from our 21 patient cohorts.

Discussion

It is hypothesized that reducing the number of trocar incisions would lead to multiple benefits. Initially, we would see a lower risk of vascular or visceral injury from trocar placement, followed by lower rates of trocar site hernias and wound infections. Lastly, the reduced number of incisions would lead to improved cosmetics for the patient [13]. SILS for standard pediatric procedures is also more cost-effective when compared to traditional laparoscopy [14] and is deemed safe and feasible for the management of ovarian pathology in children [15].

However, the use of SILS multi-channel ports necessitates the creation of large fascial and skin incisions. Also, crowding, limited maneuverability, and little instrument triangulation, which is more pronounced in newborns, make traditional SILS technically challenging. Hence, the use of optical forceps introduced through a single 5-mm port described here resolves restrictions present with conventional SILS and makes the most of its benefits. In addition, the extracorporeal excision of adnexal disease allows for quick and easy tactile control.

Before 2015, attempt for conservative management with frequent follow-up as recommended internationally. Using this management style, we lost two of the three ovaries due to torsion.

Up to our knowledge and in support of our technique, the use of optical forceps to facilitate laparoscopic procedures in the pediatric population has been reported in three other papers with good results. Yilmaz et al. used optical forceps to describe novel

Table 1 Patient demographics, findings, and follow-up

Case No.	Antenatal Diagnosis	Postnatal age at diagnosis (days)	Gestational Age At Birth (weeks)	Cyst size (cm)	US +/- CT Features	Side	Procedure	OR Time (min.)	Age at OR (postnatal days)	L.O.H Stay	Cyst Histology	Torsion	Follow Up
1	Yes	N/A	39	5.4x6.1x4.0	Simple	Rt.	SPLA Cystectomy	43	2	3	Follicular	No	Till 5 years old, no recurrence
2	No	2	37	4.9x6.8x4.3	Simple	Rt.	SPLA Cystectomy	44	3	3	Follicular	No	Till 5 years, no recurrence
3	Yes	N/A	35	5.9x6.8x5.1	Complicated	Lt.	SPLA Cystectomy	43	2	3	Hemorrhagic	No	Till 4 years, no recurrence
4	Yes	N/A	38	5.1x6.3x5.9	Complicated	Rt.	SPLA Cystectomy	44	2	3	Hemorrhagic	No	Till 6 years, no recurrence
5	Yes	N/A	38	Rt. 6.1x7.1x4.7 Lt. 2.0x3.0x1.5	Rt. Complicated Lt. simple	Bilateral	SPLA Cystectomy for Rt. Side	44	2	3	Hemorrhagic	No	At the age of 1 year, the left sided cyst decreased in size and disappeared at 2 years. No recurrence on the right side at 2 years.
6	No	3	36	7.2x5.8x5.2	Simple	Rt.	SPLA Cystectomy	44	5	3	Follicular	No	Till 1 year, no recurrence. Small cyst appeared at 2 years which then disappeared at the 3 years US follow up.
7	Yes	N/A	34	5.2x6.1x3.8	Complicated	Rt.	SPLA Salpingo-oophorectomy	47	7	3	Hemorrhagic	Yes	Till 5 years. No complications.
8	Yes	N/A	36	6.2x7.5x3.9	Complicated	Rt.	SPLA Salpingo-oophorectomy	48	2	3	Necrotic tissue with small remnant ovarian tissue	Yes	Till 5 years, no Complications.
9	No	9	38	7.3x6.2x4.7	Simple	Rt.	SPLA Cystectomy	43	11	3	Follicular	No	Till 4 years, no recurrence
10	Yes	N/A	38	7.0x6.3x5.3	Complicated	Lt.	SPLA Cystectomy	40	2	2	Hemorrhagic	No	Till 3 years, no recurrence
11	No	3	38	6.3x5.8x5.0	Complicated	Lt.	SPLA Cystectomy	41	5	2	Hemorrhagic	No	Till 4 years, no recurrence
12	No	12	37	7.8x6.4x4.9	Complicated	Lt.	SPLA Detorsion and Partial Cystectomy to Save the Ovary	47	12	2	Hemorrhagic	Yes	At 2 months US, bulky left ovary, no cyst. At 6 month US, within normal left ovary.
13	Yes	N/A	36	Rt. 7.1X5.3x5.1 Lt. 1.8X2.1x1.7	Simple Bilateral	Bilateral	SPLA Cystectomy on Rt. Side. Lt. Side Observed	40	3	2	Follicular	No	6 month US, marked decrease in the size of the Lt. cyst. It disappeared at the 1 year US F/U. No recurrence on the rt. side.
14	Yes	N/A	38	Rt. 1.0x0.8x1.0 Lt. 5.8x6.3x4.1	Simple Bilateral	Bilateral	SPLA Cystectomy in Lt. Side. Rt. Side Observed	41	2	2	Follicular	No	Rt. Cyst disappeared at US 6 months. Lt. at 6 months, cystic changes in the ovary. Both normal at 1 year. F/U at 3 years was NAD.
15	Yes	N/A	34	6.5x7.1x4.2	Simple	Rt.	SPLA Cystectomy	42	2	2	Follicular	No	US normal at 6 months. 2 year follow up NAD.
16	Yes	N/A	39	5.2x6.9x5.1	Complicated	Lt.	SPLA Cystectomy	43	3	2	Hemorrhagic	No	Normal US at the 2 year US. Did not F/U during the first year of life.
17	Yes	N/A	37	7.2X5.8x4.1	Simple	Rt.	SPLA Cystectomy	44	3	2	Theca lutein	No	US normal at the 1 year F/U. She missed US 6 months.
18	No	14	40	13.0X10.0x10.0	Complicated	Rt.	SPLA Salpingo-oophorectomy	47	14	2	Hemorrhagic	Yes	Till 6 months, no recurrence, then lost to follow up.
19	Yes	N/A	37	6.7X5.2x4.3	Simple	Lt.	SPLA Cystectomy	41	10	2	Follicular	No	Normal US at 6 months then lost to follow up.
20	Yes	N/A	38	5.4X5.5x4.2	Simple	Rt.	SPLA Cystectomy	40	12	2	Follicular	No	Normal US at 1 year F/U then lost to follow up.
21	Yes	N/A	39	6.4X5.3x4.5	Simple	Rt.	SPLA Cystectomy	42	11	2	Follicular	No	Normal US at 6 months, then lost to follow up.

techniques for the repair of inguinal and Morgagni hernias in children [16, 17]. In another paper, optical forceps were used to enable the SPLA creation of a gastrostomy for a baby who was not a good candidate for the percutaneous endoscopic route [18]. We believe that adding bronchoscopic optical graspers to the pediatric surgeon’s armamentarium of laparoscopic instruments adds clear value and gives a new dimension to minimally invasive surgery.

The mean operative time for our technique is shorter than that of most SILS procedures performed for pediatric adnexal pathology in the literature. We believe that this is partly due to the ease of our procedure performed on a specific cohort of cases. Alternatively, this could be explained by differences in defining operative time between studies and the complexity of patients included in the other reports. The mean length of hospital stay was comparable to that of medical literature. Towards the beginning of our study, neonates remained for 3 days in the NICU till discharged home. As intensivists became more familiar with the procedure, they were more comfortable discharging patients home

earlier on the second postoperative day. Through our study, we did not face any immediate or delayed complications nor recurrences. The low complication rate confirms the overall low risk of complications documented in similar literature [5, 19–23].

Limitations of our study include small sample size and the lack of an objective assessment for scar appearance. However, both surgeons and caregivers have expressed their satisfaction with near-normal or normal umbilicus at the 6-month-follow-up period.

Conclusion

We can conclude that using optical forceps for adnexal disease via SPLA procedure in newborns who are not candidates for observation is safe and feasible. These procedures also yield reduced operating time for the surgeon and excellent cosmetic results for the patient.

To summarize, the optical forceps should be added as a helpful tool in the surgeon arsenal. It has shown its capacity to expedite many pediatric laparoscopic procedures. Such procedures could include duplication and mesenteric cyst resections, appendectomy, and Meckel’s diverticulectomy, among others.

Abbreviations

SPLA: Single-port laparoscopic-assisted; CT: Computerized tomography; CA19-9: Cancer antigen 19-9; CA-125: Cancer antigen-125; SPSS: Statistical Package for the Social Sciences; SILS: Single-incision laparoscopic surgery; NICU: Neonatal intensive care unit.

Acknowledgements

Not applicable.

Authors' contributions

H.S. is the chief surgeon in the first center and contributed to the study design, review, and approval of the final version of the manuscript. O.B. is the chief surgeon in the second center. Y.S. and O.A. participated in surgery and follow-up of the patients and collected the patients' data. M.F. who proposed the idea of the unique procedure. A.A. and Y.A. analyzed the data, wrote the initial draft, and approved the final version of the manuscript. The authors read and approved the final version of the manuscript.

Funding

This research did not receive any specific grant from funding agencies in the public, commercial, or not-for-profit sectors.

Availability of data and materials

The related data and material of the current study are available from the corresponding author on a reasonable request.

Declarations

Ethics approval and consent to participate

The study was approved by the research ethics committee at the Faculty of Medicine, Umm Al-Qura University, Makkah, Saudi Arabia (The first center, International Medical Center, Jeddah, Saudi Arabia is an affiliate to the Faculty of Medicine, Umm Al-Qura University) in March 2014, # 109/3/2014. A written informed consent for participation, images, and clinical data of participants that compromise anonymity at this study was obtained from parents/guardians.

Consent for publication

Not applicable.

Competing interests

Not applicable.

Author details

¹Department of Pediatric Surgery, International Medical Center, Jeddah, Saudi Arabia. ²Department of Surgery, Faculty of Medicine, Umm Al-Qura University, Makkah, Saudi Arabia. ³Neonatal Unit, International Medical Center, Jeddah, Saudi Arabia. ⁴Department of Anesthesiology, International Medical Center, Jeddah, Saudi Arabia.

Received: 13 March 2021 Accepted: 18 March 2022

Published online: 05 July 2022

References

- Nussbaum AR, Sanders RC, Hartman DS, Dudgeon DL, Parmley TH. Neonatal ovarian cysts: sonographic-pathologic correlation. *Radiology*. 1988;168(3):817–21. <https://doi.org/10.1148/radiology.168.3.3043551>.
- Trinh TW, Kennedy AM. Fetal ovarian cysts: review of imaging spectrum, differential diagnosis, management, and outcome. *Radiographics*. 2015;35(2):621–35. <https://doi.org/10.1148/rg.352140073>.
- Qazi SH, Jeelani SM, Dogar SA, Das JK, Saxena AK. Approaches to the management of pediatric ovarian masses in the 21st century: systematic review and meta-analysis. *J Pediatr Surg*. 2020;55(3):357–68. <https://doi.org/10.1016/j.jpedsurg.2019.09.003>.
- Schenkman L, Weiner TM, Phillips JD. Evolution of the surgical management of neonatal ovarian cysts: laparoscopic-assisted transumbilical extracorporeal ovarian cystectomy (LATEC). *J Laparoendosc Adv Surg Tech A*. 2008;18(4):635–40. <https://doi.org/10.1089/lap.2007.0193>.
- Papic JC, Billmire DF, Rescorla FJ, et al. Management of neonatal ovarian cysts and its effect on ovarian preservation. *J Pediatr Surg*. 2014;49:990–4. <https://doi.org/10.1016/j.jpedsurg.2014.01.040>.
- Van der Zee DC, van Seumeren IG, Bax KM, Rövekamp MH, ter Gunne AJ. Laparoscopic approach to surgical management of ovarian cysts in the newborn. *J Pediatr Surg*. 1995;30(1):42–3. [https://doi.org/10.1016/0022-3468\(95\)90606-1](https://doi.org/10.1016/0022-3468(95)90606-1).
- Bailez M, Martinez FM. Endosurgical postnatal approach to fetal ovarian cysts. *Pediatr Endocrinol Innovat Tech*. 1997;1:111–6. <https://doi.org/10.1089/pei.1997.1.111>.
- Decker PA, Chammas J, Sato TT. Laparoscopic diagnosis and management of ovarian torsion in the newborn. *JLS*. 1999;3(2):141–3.
- Tseng D, Curran TJ, Silen ML. Minimally invasive management of the prenatally torsed ovarian cyst. *J Pediatr Surg*. 2002;37(10):1467–9. <https://doi.org/10.1053/jpsu.2002.35415>.
- Prasad S, Chui CH. Laparoscopic-assisted transumbilical ovarian cystectomy in a neonate. *JLS*. 2007;11(1):138–41.
- DiChiacchio L, Cappiello CD, Greenspon J. Extracorporeal cardiopulmonary resuscitation in a neonate after air embolism during insufflation for laparoscopic peritoneal dialysis catheter placement. *J Surg Case Rep*. 2018;2018(6):rjy1119. Published 2018 Jun 13. <https://doi.org/10.1093/jscr/rjy119>.
- Olsen M, Avery N, Khurana S, Laing R. Pneumoperitoneum for neonatal laparoscopy: how safe is it? *Paediatr Anaesth*. 2013;23(5):457–9. <https://doi.org/10.1111/pan.12146>.
- Landman MP, Billmire D. Umbilical access in laparoscopic surgery in infants less than 3 months of age: a survey of the American Pediatric Surgical Association. *J Pediatr Surg*. 2020;55(10):2094–8.
- Fader AN, Escobar PF. Laparoendoscopic single-site surgery (LESS) in gynecologic oncology: technique and initial report. *Gynecol Oncol*. 2009;114(2):157–61. <https://doi.org/10.1016/j.ygyno.2009.05.020>.
- Islam S, Adams SD, Mahomed AA. SILS: Is it cost- and time-effective compared to standard pediatric laparoscopic surgery? *Minim Invasive Surg*. 2012;2012:807609. <https://doi.org/10.1155/2012/807609>.
- Lacher M, Kuebler JF, Yannam GR, et al. Single-incision pediatric endosurgery for ovarian pathology. *J Laparoendosc Adv Surg Tech A*. 2013;23(3):291–6. <https://doi.org/10.1089/lap.2012.0380>.
- Yilmaz E, Afsarlar CE, Erdogan D, Ozguner IF. Outpatient single-port laparoscopic percutaneous Morgagni hernia repair assisted by an optical forceps. *Minim Invasive Ther Allied Technol*. 2017;26(3):182–7. <https://doi.org/10.1080/13645706.2016.263213>.
- Yilmaz E, Afsarlar CE, Senel E, et al. A novel technique for laparoscopic inguinal hernia repair in children: single-port laparoscopic percutaneous extraperitoneal closure assisted by an optical forceps. *Pediatr Surg Int*. 2015;31(7):639–46. <https://doi.org/10.1007/s00383-015-3722-z>.
- Patel H, Feins NR. Single-site laparoscopic gastrostomy with a 4-mm bronchoscopic optical grasper. *J Pediatr Surg*. 2008;43(9):1765. <https://doi.org/10.1016/j.jpedsurg.2008.07.017>.
- Takeda A, Imoto S, Nakamura H. Management of pediatric and adolescent adnexal masses by gasless laparoendoscopic single-site surgery. *Eur J Obstet Gynecol Reprod Biol*. 2014;181:66–71. <https://doi.org/10.1016/j.ejogrb.2014.07.021>.
- Pontarelli EM, Emami C, Nguyen NX, Torres M, Anselmo DM. Single-incision laparoscopic resection of ovarian masses in children: a preliminary report. *Pediatr Surg Int*. 2013;29(7):715–8. <https://doi.org/10.1007/s00383-013-3325-5>.
- Litz C, Danielson PD, Chandler NM. Single incision laparoscopic surgery for pediatric adnexal pathology. *J Pediatr Surg*. 2014;49(7):1156–8. <https://doi.org/10.1016/j.jpedsurg.2013.10.017>.
- Akkoyun I, Gülen S. Laparoscopic cystectomy for the treatment of benign ovarian cysts in children: an analysis of 21 cases. *J Pediatr Adolesc Gynecol*. 2012;25(6):364–6. <https://doi.org/10.1016/j.jpjag.2012.06.007>.

Publisher's Note

Springer Nature remains neutral with regard to jurisdictional claims in published maps and institutional affiliations.