

CASE REPORTS

Open Access



# A Sri Lankan child with hypersplenism secondary to pre-hepatic portal hypertension, successfully managed with partial splenic artery embolization: a case report and review of the literature

Visvalingam Arunath\* , Manoj Sanjeeva Liyanarachchi, Sundarraajah Gajealan and Kumudu Weerasekara

## Abstract

**Background:** Hypersplenism, one of the major complications of portal hypertension, is traditionally treated by splenectomy. However, partial splenic artery embolization is an evolving minimally invasive intervention to treat these patients effectively.

**Case presentation:** A 13-year-old girl was referred for further evaluation of isolated splenomegaly with pancytopenia. She did not have bleeding manifestations or features of anemia. She never had hematemesis or melena. On examination, she was pale. Abdominal examination revealed massive splenomegaly of 10 cm below the costal margin without hepatomegaly. Rest of the examination was unremarkable. Her investigations revealed a white cell count of  $1700/\text{mm}^3$  (neutrophils 9.8% and lymphocytes 88.7%), hemoglobin 9.5 g/dL and platelet count  $42,000/\text{mm}^3$ . Blood picture showed pancytopenia without abnormal cells. Her reticulocyte count was 1.9%. Complete liver profile was normal. Abdominal ultrasonography revealed massive splenomegaly with the oblique length of 17 cm and normal echogenic liver with normal size. Cavernous transformation of portal vein with portal hypertension was evident. Mesenteric angiogram showed portal vein thrombosis and markedly tortuous splenic artery. Anti-nuclear antibodies and double-stranded DNA were negative. Ham test and urine for hemosiderin were negative. Clauss fibrinogen assay was normal. Hemoglobin high performance liquid chromatography for hemoglobin subtypes was normal. Anti-phospholipid antibodies were negative. JAK2 V617F mutation was not identified. Diagnosis of pre hepatic portal hypertension was made. Her upper gastrointestinal endoscopy was normal. Partial splenic artery coil embolization was done by interventional radiology team. Vaccines against capsulated organisms were given. Post-procedure contrast abdominal computed tomography revealed infarction of approximately 70% of the spleen and blood counts were improved. Index case is in the follow up for 3 years. She is on penicillin prophylaxis with regular blood count and annual upper gastrointestinal endoscopy monitoring.

**Conclusions:** Minimally invasive interventions such as partial splenic artery embolization should be considered in managing the patients with hypersplenism secondary to portal hypertension.

**Keywords:** Pre-hepatic portal hypertension, Hypersplenism, Partial splenic artery embolization, Portal vein thrombosis

\*Correspondence: arunkarthi91@gmail.com  
Lady Ridgeway Hospital, Colombo 08, Sri Lanka

## Background

Hypersplenism (HS) is defined as increased activity of the spleen leading to pancytopenia which is one of the major complications of portal hypertension (PH) irrespective of the etiology. Traditional treatment option for HS is splenectomy. However, partial splenic artery embolization (PSE) is an evolving minimally invasive intervention to treat these patients effectively [1]. We report a Sri Lankan child with HS secondary to pre-hepatic portal hypertension who had been successfully treated by PSE.

## Case presentation

A 13-year-old Sri Lankan girl was referred from local hospital for further evaluation of isolated splenomegaly with pancytopenia which was incidentally found while managing for an uncomplicated bronchopneumonia. This girl, second child of non-consanguineous parents had uneventful past medical history. She did not have bleeding manifestations and features of anemia. She never had hematemesis or melena in the past and did not have features of hematological malignancies or chronic liver parenchymal disease. In her family, none of them were affected by thrombophilia or thrombotic diseases.

On examination, this averagely built child was pale. Abdominal examination revealed splenomegaly which was 10 cm below the costal margin and firm in consistency with palpable splenic notch. Her liver span was 5 cm which was normal for her age and there was no hepatomegaly. Examination of other systems was unremarkable.

Her complete blood count revealed; white cell count  $1700/\text{mm}^3$  (neutrophils 9.8% and lymphocytes 88.7%), hemoglobin 9.5 g/dL, and platelet  $42,000/\text{mm}^3$ . Blood picture showed pancytopenia without abnormal cells. Her reticulocyte count was 1.9% and erythrocyte sedimentation rate was 6 mm/1st hour. Complete liver profile including synthetic function and coagulation profile were normal.

Abdominal ultrasonography revealed massive splenomegaly with the oblique length of 17 cm and normal echogenic liver with normal size. Carvenous transformation of portal vein with portal hypertension was evident and patent umbilical vein through ligamentum venosus was seen. Computed tomography (CT) of abdomen with mesenteric angiogram showed portal vein thrombosis with extensive portosystemic collateral pathway formation and markedly tortuous splenic artery from its origin to splenic hilum without focal changes (Fig. 1).

Anti-nuclear antibody was negative and anti-double standard DNA was 27.1 IU/mL (normal < 39.2). Ham test and urine for hemosiderin were negative. Plasma fibrinogen antigen was 1.8 g/L (normal 1.49–3.53) and Clauss fibrinogen assay was 185 mg/dl (normal 150–400). Her sickling test was negative and hemoglobin high performance liquid chromatography for hemoglobin subtypes

was normal. Dilute Russel's viper venom test and kaolin clotting time negative for lupus coagulants. Anti-cardiolipin IgG antibody and anti- $\beta_2$  glycoprotein antibodies were negative. JAK2 V617F mutation was not identified.

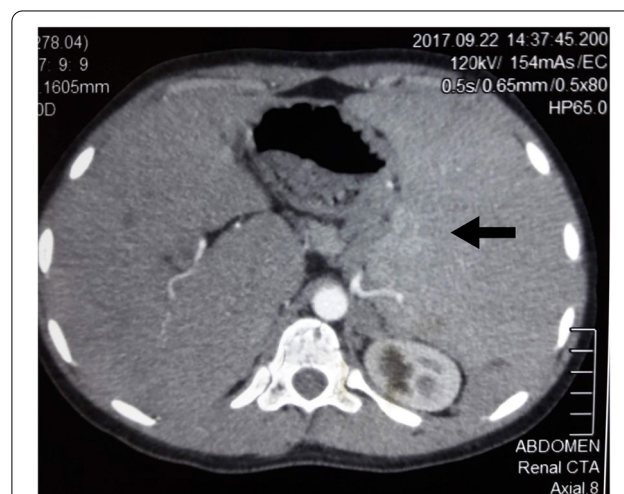
Diagnosis of pre-hepatic portal hypertension was made. Her upper gastrointestinal (GI) endoscopy was normal. As the child had significant hypersplenism, partial splenic artery coil embolization was done through right-sided femoral puncture under local anesthesia by interventional radiology team. Vaccines against capsulated organisms were given before the procedure.

Contrast abdominal CT after the procedure revealed grossly enlarged spleen with non-enhancing, hypo attenuating region suggesting infarction of approximately 70% of the spleen (Fig. 2). Following the intervention, blood cell lines were started to rise and developed thrombocytosis which needed a short course of anti-platelet therapy (Table 1).

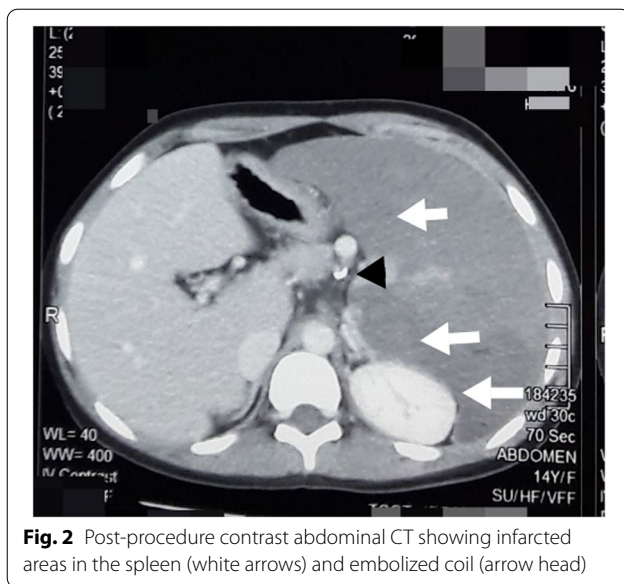
Index case is in the follow-up for 3 years. She is on penicillin prophylaxis with blood count and annual upper GI endoscopy monitoring. Her blood counts and complete liver profile were normal so far. Latest ultrasonography of the abdomen showed portal vein thrombosis without hepatosplenomegaly. Spleen was normal in morphology and oblique length was 6 cm. Her latest endoscopy studies revealed small fundal varices and she was started on carvedilol subsequently. Follow-up CT scan was not done.

## Discussion

Portal vein thrombosis (PVT) is the most prevalent cause of PH in children, whereas etiology remains obscure in majority of the cases [2]. Gastrointestinal bleeding, most common presentation of PH is a life-threatening complication and is encountered in more



**Fig. 1** Pre-procedure CT mesenteric angiogram of abdomen showing massive splenomegaly of  $15 \times 16$  cm (black arrow) and markedly tortuous splenic artery



**Fig. 2** Post-procedure contrast abdominal CT showing infarcted areas in the spleen (white arrows) and embolized coil (arrow head)

**Table 1** Hemogram before and after partial splenic artery embolization

	Before PSE	After PSE			
		Day 3	Day 15	Day 30	Day 60
Hemoglobin (g/dL)	7.9	9.2	9.6	10.9	10.7
White cell count (/mm <sup>3</sup> )	1680	16,580	17,800	16,600	6600
Neutrophil count (/mm <sup>3</sup> )	370	1425	7599	13,000	4460
Lymphocyte count (/mm <sup>3</sup> )	1280	13,264	8188	2154	2046
Platelet count ( $\times 10^3$ /mm <sup>3</sup> )	26	317	1127	880	387

than 70% of children with PH [3]. Splenomegaly, with or without HS is the second major clinical manifestation and may be discovered first on routine physical examination because more than half of patients in many series with portal vein obstruction do not experience bleeding until after age 6 years [2, 3].

The therapy of PH mainly focuses the management of the complications. It must be emphasize that the use of many therapies is based on experience in adults with PH due to lack of pediatric data [2]. Various surgical procedures have been devised to divert portal blood flow and to decrease portal pressure. However, these shunt procedures are technically challenging in children and causes increased risk for encephalopathy as well as significant risk of failure secondary to shunt thrombosis [2].

HS is a dangerous complication and may lead to serious bleeding tendency and recurrent infections. This pancytopenia can be diminished by reducing the volume

of the functional splenic parenchyma. Splenectomy, the traditional definitive treatment even with good preoperative preparation and careful surgery may be prudent in patients as it carries high mortality rate and risk of major complications [4, 5]. An alternative to this surgery is embolization of the splenic artery noninvasively [6].

From the last two decades, PSE has been used to treat patients with HS due to PHT, regardless of the cause. Platelet and leukocytic counts markedly improves and persists in normal range following the intervention [6, 7].

Several studies have shown the technical feasibility and favorable results of PSE and pointed out in particular its less onerous postoperative course than that for surgery [7]. However, PSE is often associated with considerable high risk of complications such as subcapsular collections, ascites, pleural effusion, splenic abscess, post-embolization syndrome, and total splenic necrosis which may lead to procedure-related deaths [5–12]. Fortunately, our patient did not develop major complications following the procedure.

Hematologic response and the severity of complications correlates with the amount of the infarcted splenic mass and the complication rate increases clearly with the size of the infarction [8]. General recommendation is achieving infarction between 50% and 70% of the splenic mass to get good therapeutic hematologic response and alleviate HS with less procedure related complications [9]. PSE can be done in more than one sessions with an adequate interval depends on the previous response to PSE [13]. One of the great technical difficulties in this procedure involves the quantification of the volume infarcted during the procedure with conventional angiographic series; the production of splenic images by the most recent angiography systems may be extremely helpful in this regard [6]. However, we could not assess the infarcted splenic volume objectively in our patient due to the limited sources.

PSE, like splenectomy, can theoretically increase the risk of infection by encapsulated organisms. Consideration should be given to vaccines against these organisms and it should be given before PSE. All patients should be given proper information to reduce infectious complications as well [13].

In previously reported pediatric studies, both prehepatic and hepatic cases of portal hypertension were successfully managed with splenic embolization and there were only few cases with post-operative complications. During the first 5 years of follow-up after the procedure, majority of the patients were well and PSE slowed the sequel of portal hypertension and the complications associated with it [5, 14–22]. Other conditions which had been successfully managed with PSE in children included blunt splenic injuries,

splenic neoplasms, and secondary hypersplenism in various disorders such as thalassemia major, hereditary spherocytosis, and Gaucher disease [23–25]. As splenic regeneration following PSE may occur more frequently in children than in adults, partial splenic embolization may be a favorable alternative to splenectomy in pediatric patients.

## Conclusions

PSE is a really effective non-surgical minimally invasive procedure while achieving remarkable hematologic response on controlling hypersplenism irrespective of the etiology.

## Abbreviations

HS: Hypersplenism; CT: Computed tomography; PH: Portal hypertension; PSE: Partial splenic artery embolization.

## Acknowledgements

We would like to express our sincere gratitude to the patient for giving the consent to present this case in this paper. We would like to appreciate the Department of Radiology, Lady Ridgeway Hospital and Department of Interventional Radiology, National Hospital of Sri Lanka for helping us in the management of this child.

## Authors' contributions

VA, MSL, SG, and KPW were responsible for delivering the patient care. VA wrote the case and the manuscript. Editing and supervision were done by MSL, SG, and KPW. All authors revised, read, and approved the final manuscript.

## Funding

No funding or grant support was available for this case report.

## Availability of data and materials

Relevant data and materials are available for review if needed.

## Declarations

### Ethics approval and consent to participate

Not applicable.

### Consent for publication

Written informed consent was obtained from a parent of the patient for publication of this case report and accompanying images. A copy of the consent form is available for review.

### Competing interests

The authors declare that they have no competing interests.

Received: 16 March 2021 Accepted: 18 March 2022

Published online: 05 July 2022

## References

- Shneider B, Bosch J, de Franchis R, Emre S, Groszmann R, Ling S, et al. Portal hypertension in children: expert pediatric opinion on the report of the Baveno V consensus workshop on methodology of diagnosis and therapy in portal hypertension. *Pediatr Transplant*. 2012;16(5):426–37.
- Giouleme O, Theocharidou E. Management of portal hypertension in children with portal vein thrombosis. *J Pediatr Gastroenterol Nutr*. 2013;57(4):419–25.
- Alvarez F, Bernard O, Brunelle F, et al. Portal obstruction in children. I. Clinical investigation and hemorrhage risk. *J Pediatr*. 1983;103:696–702.
- Alwmark A, Bengmark S, Gullstrand P, Joelsson B, Lunderquist A, Owman T. Evaluation of splenic embolization in patients with portal hypertension and hypersplenism. *Ann Surg*. 1982;196(5):518–24.
- Vittorio J, Orellana K, Martinez M, Ovchinsky N, Schlossberg P, Griesemer A, et al. Partial splenic embolization is a safe and effective alternative in the management of portal hypertension in children. *J Pediatr Gastroenterol Nutr*. 2019;68(6):793–8.
- Lee CM, Leung TK, Wang HJ, Lee WH, Shen LK, Liu JD, et al. Evaluation of the effect of partial splenic embolization on platelet values for liver cirrhosis patients with thrombocytopenia. *World J Gastroenterol*. 2007;13(4):619–22.
- Koconis K, Singh H, Soares G. Partial splenic embolization in the treatment of patients with portal hypertension: a review of the english language literature. *J Vasc Interv Radiol*. 2007;18:463–81.
- N'Kontchou G, Seror O, Bourcier V, et al. Partial splenic embolization in patients with cirrhosis: efficacy, tolerance and long-term outcome in 32 patients. *Eur J Gastroenterol Hepatol*. 2005;17:179–84.
- Zhu K, Meng X, Qian J, Huang M, Li Z, Guan S, et al. Partial splenic embolization for hypersplenism in cirrhosis\* a long-term outcome in 62 patients. *Dig Liv Dis*. 2009;41(6):411–6.
- Abdella HM, Abd-El-Moez AT, Abu El-Maaty ME, Helmy AZ. Role of partial splenic embolization for hypersplenism in patients with liver cirrhosis and thrombocytopenia. *Indian J Gastroenterol Mar*. 2010;29(2):59–61.
- Madoff DC, Denys A, Wallace MJ, et al. Splenic arterial interventions: anatomy, indications, technical considerations, and potential complications. *Radiographics*. 2005;25(Suppl):S191–211.
- Amin MA, El-Gendy MM, Dawoud IE, Shoma A, Negm AM, Amer TA. Partial splenic embolization versus splenectomy for the management of hypersplenism in cirrhotic patients. *World J Surg*. 2009;33(8):1702–10.
- Nassef A, Zakaria A, Abd EBM. Partial splenic artery embolization in portal hypertension patients with hypersplenism: Two interval-spaced sessions' technique. *Egypt J Radiol Nucl Med*. 2013;44(3):531–7.
- Kumpe D, Rumack C, Pretorius D, Stoecker T, Stellin G. Partial splenic embolization in children with hypersplenism. *Radiology*. 1985;155(2):357–62.
- Brandt C, Rothbarth L, Kumpe D, Karrer F, Lilly J. Splenic embolization in children: Long-term efficacy. *J Pediatr Surg*. 1989;24(7):642–5.
- Israel D, Hassall E, Culham J, Phillips R. Partial splenic embolization in children with hypersplenism. *J Pediatr*. 1994;124(1):95–100.
- Watanabe Y, Todani T, Noda T. Changes in splenic volume after partial splenic embolization in children. *J Pediatr Surg*. 1996;31(2):241–4.
- Harned R, Thompson H, Kumpe D, Narkewicz M, Sokol R. Partial splenic embolization in five children with hypersplenism: effects of reduced-volume embolization on efficacy and morbidity. *Radiol*. 1998;209(3):803–6.
- Petersons A, Volrats O, Bernsteins A. The first experience with non-operative treatment of hypersplenism in children with portal hypertension. *Eur J Pediatr Surg*. 2002;12(5):299–303.
- Cwikiel W, Keussen I, Larsson L, Solvig J, Kullendorff C. Interventional treatment of children with portal hypertension secondary to portal vein occlusion. *Eur J Pediatr Surg*. 2003;13(5):312–8.
- Nio M, Hayashi Y, Sano N, Ishii T, Sasaki H, Ohi R. Long-term efficacy of partial splenic embolization in children. *J Pediatr Surg*. 2003;38(12):1760–2.
- Meisheri I, Kothari P, Kumar A, Deshmukh A. Splenic artery embolisation for portal hypertension in children. *Afr J Paediatr Surg*. 2010;7(2):86.
- Thanopoulos B, Frimas C. Partial splenic embolization in the management of hypersplenism secondary to Gaucher disease. *J Pediatr*. 1982;101(5):740–3.
- Pratl B, Benesch M, Lackner H, Portugaller H, Pusswald B, Sovinz P, et al. Partial splenic embolization in children with hereditary spherocytosis. *Eur J Haematol*. 2008;80(1):76–80.
- Gross J, Woll N, Hanson C, Pohl K, Scorpio R, Kennedy A, et al. Embolization for pediatric blunt splenic injury is an alternative to splenectomy when observation fails. *J Trauma Acute Care Surg*. 2013;75(3):421–5.

## Publisher's Note

Springer Nature remains neutral with regard to jurisdictional claims in published maps and institutional affiliations.