


CASE REPORTS

Open Access



Coexistence of pulmonary hydatid cyst and tuberculosis in a child: a case report

Assia Haif^{1,2*} , Djelloul Achouri^{1,2}, Halima Bougharnout¹, Asma Chahmana¹, Fahima Bouchareb³, Boubakeur Bendecheche³ and Zineddine Soualili^{1,2}

Abstract

Background: The echinococcosis and tuberculosis of the lungs are both endemic in Algeria.

The coexistence of echinococcosis and tuberculosis in the same lobe of the lung is exceptional.

Case presentation: A 10-year-old girl was admitted with a history of productive cough, fever, and chest pain.

Chest examination revealed decreased air entry at left lower lobe. Chest X-ray demonstrated a round left lower lobe with an air fluid interface. Chest CT scan with intravenous contrast showed a lingual hydroaeric formation measuring 5×6 cm with a detached membrane image.

A diagnosis of a complicated hydatid disease of the lung was made and the patient was subsequently started on oral albendazole before undergoing exploratory thoracotomy where partial cystectomy and the obliteration of the pericyst cavity. Histopathology was notable for echinococcosis membrane characteristics.

After 2 months, the patient re-presented with complaints of cough, hemoptysis, and dyspnea.

Radiographic images favored repermeabilization of bronchopleural fistulas.

The management was the closing of the bronchial openings.

Histological findings include image characteristic of the echinococcosis and tuberculosis.

The patient continued on albendazole and an anti-tuberculosis regimen, with concurrent functional physiotherapy sessions.

During the following 3-year follow-up, drastic clinical, radiographic, and functional improvement was noted.

Conclusion: Concurrent tuberculosis and echinococcosis infection should be taken into consideration when patients present with persistent bronchopleural fistula in endemic areas.

A multidisciplinary approach of different medical teams facilitates diagnosis and rapid treatment.

Keywords: Echinococcosis, Tuberculosis, Lung, Co-existence, Children

Background

Echinococcosis and tuberculosis of the lungs are endemic in the Mediterranean area, with a high burden of disease in Algeria [1]. Echinococcosis may develop in any organ,

but the lung is primarily affected in children [2]. Most cysts are acquired in childhood, remain asymptomatic for a long period of time, and are incidentally found on chest radiography later in life [3]. While rare, adult case reports of co-infection of tuberculosis and echinococcosis have been published, but the literature is relatively sparse concerning childhood disease burden [4, 5].

*Correspondence: a.haif@univ-setif.dz

² Laboratory of applied pediatric surgery, Ferhat Abbas Setif University 1, Setif, Algeria

Full list of author information is available at the end of the article

Case presentation

A 10-year-old girl was admitted with a history of productive cough, fever, and chest pain. There were no antecedents, with vaccinations up-to-date. There was no reported history of exposure, including intimate contact with contagious dogs. Review of systems was notable for weight loss. On examination, the general condition of the patient was preserved. Chest examination revealed decreased air entry at the left lower lobe, but systemic examination was unremarkable, other than a BCG mark in the upper extremity. Laboratory studies revealed leucocytosis, with serologic *Echinococcus* IgG positive.

Chest X-ray demonstrated a round left lower lobe with an air-fluid interface, an acute angle of connection, and free costodiaphragmatic recess of the pleural cavity (Fig. 1). Chest computed tomography with intravenous contrast showed a lingual hydroaeric formation measuring 5×6 cm with a detached membrane image associated with peri-cystic parenchymal condensation (Fig. 2). Chest spirometry showed decreased respiratory exhalation, 83.1% of predicted.

A diagnosis of complicated hydatid disease of the lung was made, and the patient was subsequently started on oral albendazole, before undergoing exploratory thoracotomy where partial cystectomy and the obliteration of the pericyst cavity occurred. Histopathology was notable for echinococcosis membrane characteristics.

After 2 months, the patient re-presented with complaints of cough, hemoptysis, and dyspnea. Physical exam was notable for decreased breath sounds and enlargement of the left sided chest wall. Casoni skin test and

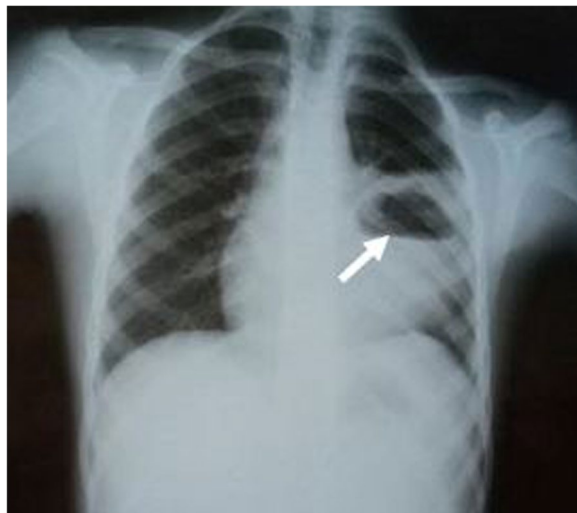

Fig. 1 Chest X-ray: a round left lower lobe with an air fluid interface (white arrow), an acute angle of connection, and free costodiaphragmatic recess of pleural cavity

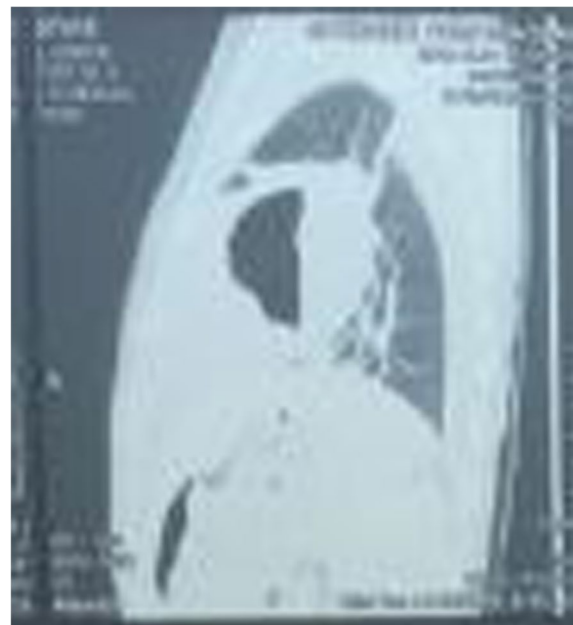

Fig. 2 Chest CT scan with injection contrast: A lingual hydroaeric formation measuring 5×6 cm with a detached membrane

sputum cultures were negative. Radiographic images favored repermeabilization of bronchopleural fistulas and the patient underwent surgical closure of the bronchial openings, pleural lung biopsy, and placement of a thoracic drain. Histology was notable for characteristic laminated and cuticle appearance of the echinococcosis (Fig. 3a); caseating epithelioid cell granulomas with giant cells are features of tuberculosis (Fig. 3b). Ziehl Neelsen staining was strongly positive (Fig. 4).

The patient continued on albendazole for 2 months and an anti-tuberculosis regimen for 6 months, with concurrent functional physiotherapy sessions. During the following 3-year follow-up, drastic clinical, radiographic, and functional improvement was noted (Fig. 5).

Discussion

Human echinococcosis is a zoonic disease attributable to larval forms (metacestodes) of *Echinococcus* (*E.*) tapeworms found in the small intestine of carnivores [6]. Tuberculosis is one of the most common infections worldwide, with high prevalence in developing countries, Algeria among them. Echinococcosis is endemic in Algeria and poses a significant public health concern.

The most common location for echinococcosis in children is the lung. The high elasticity and compressible tissue found in children's lungs is thought to be the underlying cause of expedited growth of echinococcosis in children [7, 8]. Distinguishing echinococcosis and tuberculosis from each other is often easy with

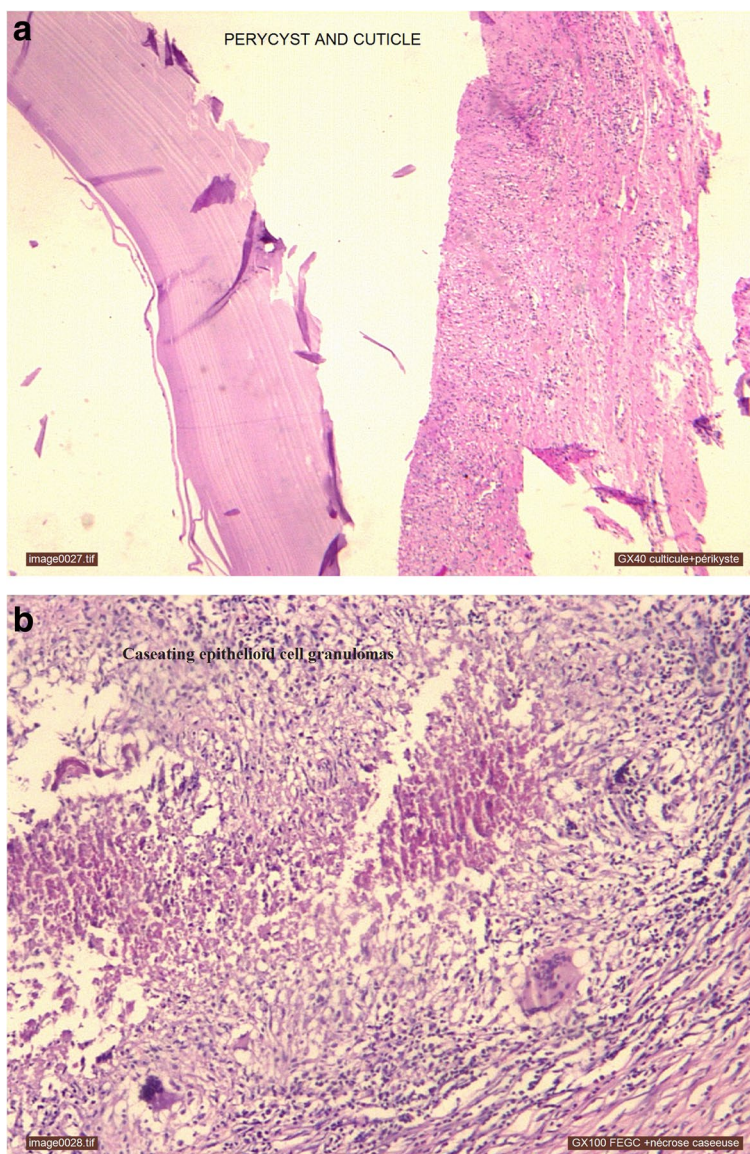


Fig. 3 Biopsy of the lung specimen: section of the cyst wall. **a** Pericyst and cuticle layer. **b** Caseating epithelioid cell granulomas with giant cells

laboratory and radiological investigations. However, distinguishing complicated echinococcosis from atypical tuberculosis is not easy and is further complicated should these two pathogens exist in the same location [9].

Similarities in the symptoms of tuberculosis and echinococcosis, as well as immune progression of both diseases, make definitive diagnosis difficult. Tuberculosis infection can often mask the symptoms of early-stage echinococcosis, particularly pulmonary echinococcosis. Tuberculosis-mediated immune system suppression can spur the progression of early echinococcosis to advance or late state echinococcosis [10].

Surgical treatment of lung echinococcosis aims to avoid lung parenchyma resection, with the ultimate goal to be as conservative as possible. Surgical goals include removal of the cyst membrane (cystectomy), closure of bronchial fistulas, and obliteration of the residual cavity (the capitonnage) with sutures. Some surgeons advocate that obligatory closure of the capitonnage is not necessary, as adequate results can also be obtained when the residual cavity spontaneously obliterates [11]. However, some reports indicate that capitonnage shortens post-operative chest tube drainage time, reduces morbidity, prevents pneumothorax and emphysema formation, and, ultimately, minimizes hospital course [12, 13]. Medical

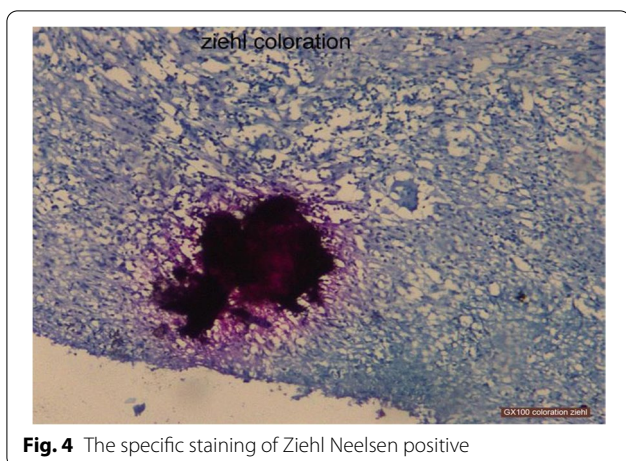


Fig. 4 The specific staining of Ziehl Neelsen positive

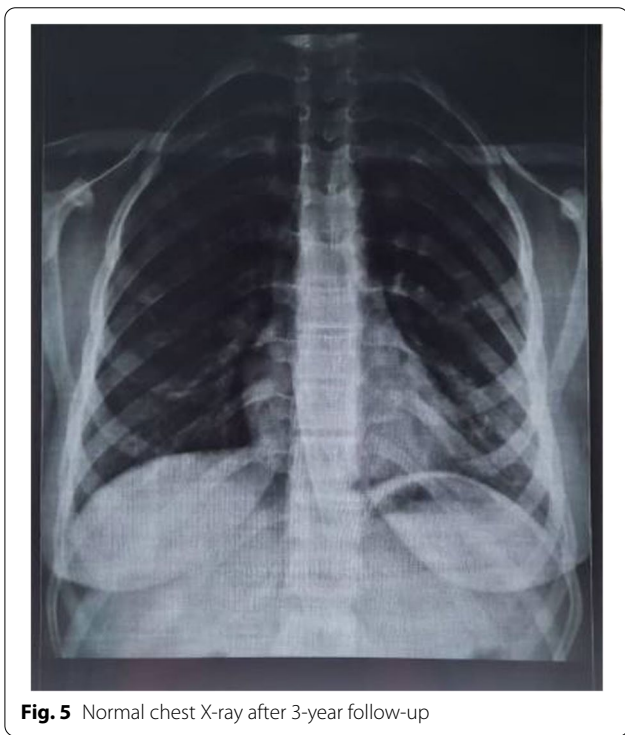


Fig. 5 Normal chest X-ray after 3-year follow-up

treatment with benzimidazole drugs can also lead to a successful outcome. Mebendazole and albendazole are the only anthelmintic agents effective against cystic echinococcosis [4].

While the treatment of echinococcosis of the lung is primarily surgical, tuberculosis seldom requires surgical intervention. Hemoptysis, bronchopleural fistula, or persistent cavities are the rare cases where surgical intervention is required.

Both echinococcosis and tuberculosis are still prevalent in children in Algeria [14, 15]. Co-existence of both

diseases in the same patient is rare, especially in children. As in the case described above, distinguishing a complicated echinococcosis infection from tuberculosis is a diagnostic challenge given the similarities in clinical presentation. In this case, Ziehl Neelsen staining illuminated the concurrent pulmonary tuberculosis infection [4, 5].

Conclusion

Concurrent tuberculosis and echinococcosis infection should be taken into consideration when patients present with persistent bronchopleural fistula or pulmonary cavitary lesions in endemic areas. While this association is rare, its high morbidity and mortality highlight the need for rapid diagnosis. A multidisciplinary approach between pediatrics, pediatric surgery, and pathology facilitates diagnosis and rapid treatment.

Acknowledgements

Not applicable.

Authors' contributions

All authors read and approved the final manuscript.

Funding

Not applicable.

Availability of data and materials

All data generated or analyzed during this study are included in this published article

Declarations

Ethics approval and consent to participate

Not applicable

Consent for publication

Informed written consent was obtained from the parents of the patient for publication of this report and the accompanying images.

Competing interests

The authors declare that they have no competing interests.

Author details

¹Department of Pediatric Surgery, University Hospital Center of Setif, Setif, Algeria. ²Laboratory of applied pediatric surgery, Ferhat Abbas Setif University 1, Setif, Algeria. ³Department of anesthesiology, University Hospital Center of Setif, Setif, Algeria.

Received: 9 November 2021 Accepted: 30 June 2022

Published online: 09 August 2022

References

1. Assia H. Laparoscopic management of anaphylactic shock following abdominal trauma revealing intravascular rupture of cystic echinococcosis (a case report and brief literature review). *Issues Dev Med Med Res.* 2022;5:29–34.
2. Hafsa C, et al. Imagerie du kyste hydatidique du poumon chez l'enfant. *J Radiol.* 2005;86(4):405–10.
3. Kern P, et al. The echinococcoses: diagnosis, clinical management and burden of disease. In: *Advances in parasitology*; Elsevier; 2017. p. 259–369.

4. Begum T, et al. Pulmonary hydatid cysts and tuberculosis in a child a case report. *J Bangladesh College Phys Surg.* 2011;29(2):102–5.
5. Karande S, et al. Coexistent hydatid disease and pulmonary tuberculosis in a five year old girl. *J Assoc Phys India.* 1991;39(4):353–4.
6. Brunetti E, Kern P, Vuitton DA. Expert consensus for the diagnosis and treatment of cystic and alveolar echinococcosis in humans. *Acta tropica.* 2010;114(1):1–16.
7. Mamishi S, Sagheb S, Pourakbari B. Hydatid disease in Iranian children. *J Microbiol Immunol Infect.* 2007;40(5):428.
8. Aslanabadi S, et al. Hydatid cyst in children: a 10-year experience from Iran. *Afr J Paediatr Surg.* 2013;10(2):140.
9. Al-Shaikh MH, Bashaab MO. Unpredictable pulmonary tuberculosis with Hydatid cyst in adult male. *Egypt J Chest Dis Tubercul.* 2017;66(2):317–9.
10. Yang YR, et al. Human cases of simultaneous echinococcosis and tuberculosis-significance and extent in China. *Parasites Vectors.* 2009;2(1):1–5.
11. Turna A, et al. *Surgical treatment of pulmonary hydatid cysts: is capitonnage necessary?* *Ann Thorac Surg.* 2002;74(1):191–5.
12. Kosar A, et al. Effect of capitonnage and cystotomy on outcome of childhood pulmonary hydatid cysts. *J Thorac Cardiovasc Surg.* 2006;132(3):560–4.
13. Ksia A, et al. Capitonnage seems better in childhood pulmonary hydatid cyst surgery. *J Pediatr Surg.* 2020;55(4):752–5.
14. Zait H, et al. Epidemiological profile of 290 cases of human cystic echinococcosis diagnosed in the Mustapha University Hospital (Algiers) from 2006 to 2011. *Pathol Biol.* 2013;61(5):193.
15. Selmane S, L'Hadj M. Epidemiology and clinical characteristics of tuberculosis in leon bernard tuberculosis unit in algeria. *Int J Mycobacteriol.* 2020;9(3):254.

Publisher's Note

Springer Nature remains neutral with regard to jurisdictional claims in published maps and institutional affiliations.

Submit your manuscript to a SpringerOpen[®] journal and benefit from:

- Convenient online submission
- Rigorous peer review
- Open access: articles freely available online
- High visibility within the field
- Retaining the copyright to your article

Submit your next manuscript at ► [springeropen.com](https://www.springeropen.com)
