

# Isolated Penile or Scrotal Post-Fournier's Gangrene Sequelae, the Role of Electro-Photo-Biomodulation in Conservative Treatment

NADER G. ELMELEGY, M.D.; TAREK G. SHOUKR, M.D. and SAMEH ELGHAMRY, M.D.

The Department of Plastic and Reconstructive Surgery, Faculty of Medicine, Tanta University

## Abstract

*Introduction:* Jean Alfred Fournier first described Fournier's gangrene in 1883 as a quickly progressing and possibly fatal necrotizing fasciitis of the skin and soft tissue of the scrotum, perineal region, along with the abdominal wall. The best method of reconstruction is still debatable now.

*Objective:* To evaluate the effect of E-light in management of post-fournier's gangrene sequelae.

*Patients and Method:* Sixteen male patients with isolated penile or scrotal post-Fournier's gangrene raw area participated in this study to be treated by E-light sessions.

*Results:* Twelve patients (75%) had an excellent satisfaction rate, and four (25%) rated it as good. No fair or poor results were documented.

*Conclusion:* We recommend the utilization of E-light in the management of post-Fournier's gangrene isolated raw areas of the scrotum and penis as it is an efficient, simple, and cheap treatment with satisfactory results and no complications.

**Key Words:** Fournier's gangrene – E-light – IPL (Intense Pulsed Light) – RF (Radiofrequency).

*Ethical Commitments:* All the procedures performed in this research work that involved human participants, as well as the design of this study, were approved by the Ethical Research Regulations Committee of our University, which follows the National Research Ethics Committee of the National Supreme Council of Universities. The National Research Ethics Committee regulations are compliant with the 1964 Helsinki Declaration and its later amendments on ethical standards. The legal guardians of all the participants in this study signed informed consent, which included the use of their medical data and clinical photography in scientific publications.

*Competing Interests:* The authors have no relevant financial or non-financial interests to disclose.

---

**Correspondence to:** Dr. Tarek Shoukr  
E-Mail: tarekshoukr@yahoo.com

## Introduction

Jean Alfred Fournier first described Fournier's gangrene in 1883 as a quickly progressing and possibly fatal necrotizing fasciitis of the skin and soft tissue of the scrotum, perineal region, along with the abdominal wall [1]. This type of gangrene is characterized by the absence of a specific etiologic agent, sudden onset, and rapid progression [2]. Diabetes mellitus stands as the most common predisposing factor even though 25% of instances are still idiopathic [3]. There are multiple sources of infection although urogenital and colorectal sources are the commonest.

Mostly this type of gangrene affects men, but some authors have also reported female involvement [4]. Reconstruction that was succeeded by antibiotics with broad spectrum, hemodynamic support, and aggressive surgical debridement is the cornerstone to achieve a stable and aesthetic cover. Several reconstructing procedures were described as secondary intention wound healing, tension sutures, skin grafts, and local, distant, or free skin flaps [5]. The best method of reconstruction is still debatable till now [6]. Used separately or combined, intense pulsed light (IPL) radiofrequency (RF) is a well-known treatment for scars, skin rejuvenation, rosacea, and hair removal. A sequence of dynamic alterations, which begin with the increase of collagenase and metalloproteinase activity, is implicated in the way that radiofrequency therapy affects the molecular processes that follow post-ablative resurfacing. These enzymes start the process of dermal remodeling, enabling the buildup of new dermal tissues [7]. IPL can induce thermal injury, trigger a subclinical wound-healing process, and stimulate fibroblasts, causing them to produce novel collagen and remodel the dermis [8,9]. Additionally, data suggested that mast cell-derived chymase played a significant part in the production of extracellular matrix induced by IPL [10].

Bipolar RF current flows to areas with the least resistance. When it is combined with IPL, the preheating effect of the tissues directs the RF field specifically to that area. This requires that the pulse duration of IPL must be longer than that of the RF to preheat the target tissue and thus increase the selectivity of RF preserving the surrounding tissues from damage and decreasing the needed amount of energy [11-16]. The term "E-light" was used by the authors to describe a combined treatment of RF, IPL, and cooling. To our knowledge, the published research didn't document the utilization of "E-light" in the therapy for post-Fournier's gangrene raw areas. Due to patients' weakness and vulnerability this simple and non-invasive method of treatment could be a favorable one.

**Material and Methods**

*Patients:*

Sixteen male patients with isolated penile or scrotal post-Fournier's gangrene raw area participated in this study from September 2020 until August 2022. Cooperative, compliant patients free from skin diseases, immunity disorders, or photosensitivity were included in the study. Exclusion criteria were patients that received any other treatment like skin flaps or grafts for their raw areas before the start of our treatment except surgical debridement. Once the raw area was clean, E-light treatment sessions were started. Three plastic surgeons assessed the raw area before and one month after the end of treatment. Patient-reported clinical outcome measures were obtained in the form of a questionnaire (a modification of the Odom's criteria) [40]. Table (1).

A result of an overall score of 1 to 4 was used to evaluate patients' satisfaction. Results were considered excellent when the score was 4, good when the score was 3, fair when the score was 2 and poor when it was 1.

*Technique:*

Manufacture of Beijing Oriental Wison Mechanical & Electronic Co. Ltd., a two-handle beauty machine® was used in this study (Fig. 1). All participants got sessions at intervals of two weeks. Treatment ended when there was complete healing of the raw area. For each patient, the number of sessions was recorded. IPL fluence varied between 20-24 J. Pulse delays were between 15 and 30 milliseconds, and pulse durations varied from 2 to 7 milliseconds. The fluencies of the RF element of E-light ranged between 5 and 7 J. The diameter of the spot was 8-32mm. Photography and assessment was done one month after the complete healing of the raw area. A monthly follow-up with a minimum of one year after complete healing was done. The follow-up period was a minimum of one year after their last treatment session.




Fig. (1): (A) The 2 Handles Beauty Machine®, the machine used in this study. (B) The machine handpiece: (1) IPL part (2) IPL filter (3) RF part.

Table (1): Modified Odom's criteria.

Grade	Definition
Excellent	- All symptoms relieved, patient is able to perform daily occupations and activities without impairment.
Good	- Minimal persistence of symptoms, patient is able to perform daily occupations and activities without significant interference.
Fair	- Relief of some symptoms, but daily occupations and activities remain significantly limited.
Poor	- Symptoms and signs unchanged or worse.

**Results**

In this study, 16 male patients were involved with an age ranging from 40-61 years with a mean of 47.5. Five patients (31.3%) had isolated penile raw areas, while 11 patients (68.8%) had isolated scrotal raw areas. The raw area was less than 50% in 2 cases (40%) and more than 50% in 3 cases (60%) in penile patients, while it was less than 50% in 5 cases (45.5%) and more than 50% in 6 cases (54.5%) in scrotal patients. The period between the beginning of E-light treatment and the occurrence of Fournier's gangrene ranged from 7 to 11 weeks during which patients received medical treatment and surgical debridement by another surgical team.

Treatment sessions varied between five and seven according to raw area size and the patient's response. When the raw areas showed complete healing, the treatment stopped. Twelve patients (75%) had an excellent satisfaction rate, and four (25%) rated it as good. No fair or poor results were documented.

Results were documented in Tables (2-5). The minimum follow-up period was 1 year. There was no complication during the study or the follow-up period. Examples of results were demonstrated in Figs. (2-4).

Table (2): Demographic data of the patients.

Age		Site	
Mean	Range	Penile	Scrotal
47.5	40-61	5 (31.3%)	11 (68.8%)

Table (3): Percentage of the raw area before the start of treatment.

	Penile		Scrotal	
	<50%	>50%	<50%	>50%
Number	2	3	3	6
Percent	40	60	45.5	54.5

Table (4): Statistical analysis of the treatment data of the patients.

Variable	Number	Percentage	Range
The time gap in weeks	Non applicable	Non applicable	2
<i>Number of treatment sessions:</i>			
5	11	68.8	5-7
6	2	12.5	
7	3	18.8	

Table (5): Patients' satisfaction.

Result	Points	Number of patients	Percent
Excellent	4	12	75
Good	3	4	25
Fair	2	0	0
Poor	1	0	0

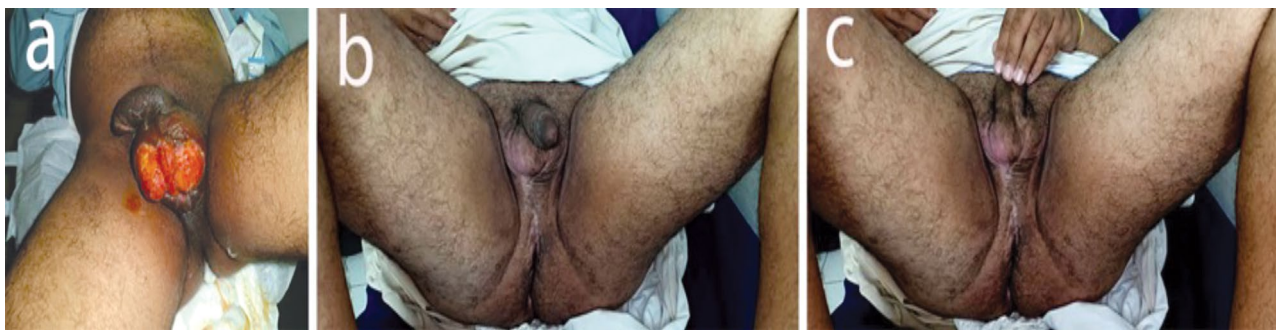

Fig. (2): Post Fernier gangrene isolated scrotal raw area. (A) Before treatment and (B, C) Six months after treatment completion.

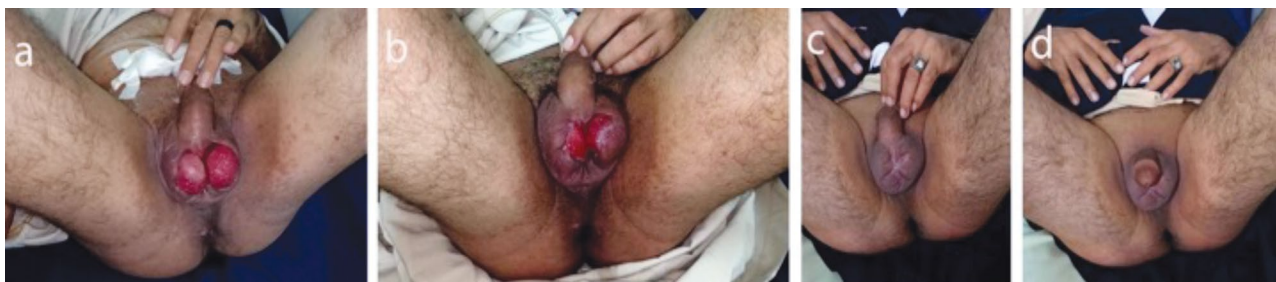

Fig. (3): Post Fernier gangrene isolated scrotal raw area. (A) Before treatment, (B) During treatment and (C, D) After treatment completion.

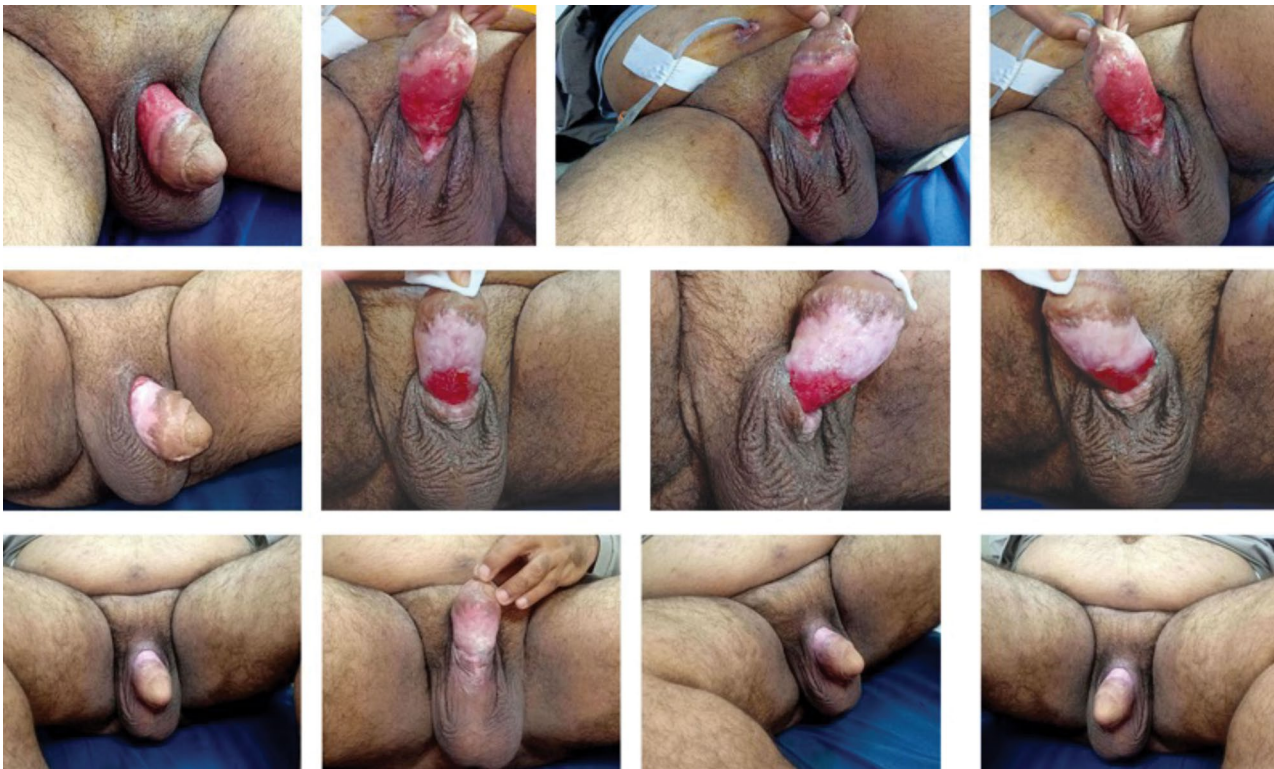

Fig. (4): Post Fournier gangrene isolated penile raw area before treatment, during treatment and after treatment completion.

### Discussion

Tissue similarity is a prominent issue for functionality and aesthetic reasons making reconstruction of penile and scrotal raw areas after Fournier gangrene challengeable due to their unique color, texture, and contour. Patients usually with medical comorbidities such as diabetes are more susceptible to surgical interventions thus requiring a simple one-stage reconstruction with low cost. Primary suture without tension that can be used for small scrotal defects, gives the best results. Healing by secondary intention is another simple treatment but again needs a small defect [17-20]. Many of our cases have near total loss of all scrotal skin which cannot heal by secondary intention in this short time with no contracture, no hypertrophic or keloid formation. So this type of healing differs completely from well-known healing by secondary intention as in secondary intention the time will be longer and there will be more contraction and more scars that not seen in our cases.

If we can decrease the time of treatment, increase the area to be treated and improve the shape of the resultant scar it may be the recommended treatment technique. In our study, 68.8% of cases showed complete healing after five sessions with a maximum period of ten weeks of therapy. There were 75% of patients with excellent results and 25% with good results, while there were no patients

with fair or poor results. In our study, the percentage of raw areas before the start of treatment was more than 50% in 60% of cases of penile patients and 54.5% of cases of scrotal patients. Testicular implantation in subcutaneous pockets of the thigh is simple but cosmetically and functionally unaccepted [21-24].

Local advancement flaps that may or may not incorporate the dartos muscle, for defects below 50% although they are simple but still carry donor-site morbidity and complications [17,25-27]. For defects larger than 50% split-thickness skin grafting or flap reconstruction can be adopted. Skin grafting was thought to be a simple and easy single-stage procedure that can hide major defects and still produce adequate practical and aesthetic outcomes [17,23,28].

Other authors have described skin grafting complications such as contracture and graft loss from hemorrhage, infection, or shearing. Additionally, some writers believed that the thin grafted skin was more prone to injury and might fail to provide the necessary level of protection [21]. They documented that Insufficient movement between the grafted skin alongside the testes may cause discomfort or pain [28,29]. In some authors' opinion, If the testes are stripped away from the tunica vaginalis they cannot be grafted [23].

Some authors claimed that durable testicular protection with immediate coverage can be done by flap reconstruction with a lower incidence of contracture. Some studies documented that the aesthetic results are suboptimal because of flap thickness, [22] while others supported acceptable cosmetic results [17,21,22,25,26,30-35].

Flap reconstruction is a longer and more complex procedure that may be linked to higher morbidity at donor and receiver sites. Possible flap consequences include wound dehiscence, fibrosis at the donor site, hematoma, and seroma. After flap repair, exposure to greater temperatures may impair the function of the testicles. Hantash et al. found that RF therapy resulted in a significant in vivo wound repair response as well as a steadily rising level of inflammatory cell invasion from day 2 within 10 weeks. They stated that the first proof of ne elastogenesis and increase of procollagen production in the context of RF therapy was given by their PCR and immunohistochemical investigations [36].

In a study delivered by John et al., they concluded that Radiofrequency might promote substantial and frequently synchronous, mRNA over expression for numerous wound healing variables and suggested that radiofrequency has immense potential as a treatment option for wounds [37]. Seng-Feng et al. noticed a marked increased expression level of collagen compared to that in the untreated rodents in IPL-pretreated ones, indicating the stimulation of angiogenesis by IPL. They concluded that IPL exerts a beneficial effect on wound healing, by accelerating the closure rate of the wound, collagen production, and angiogenesis [38]. Trinh et al., suggested the use of IPL with low energy as an adjunct treatment to enhance human wound healing [39].

We evaluate the results clinically only without skin biopsy. We will do another research and will add skin biopsy in the evaluation methods.

In conclusion, we recommend the utilization of E-light in the management of post-Fournier's gangrene isolated raw areas of the scrotum and penis as it is an efficient, simple, and cheap treatment with satisfactory results and no complications.

## References

- Eke N.: Fournier's gangrene: A review of 1726 cases. *Br. J. Surg.*, 87 (6): 718-28. Kılıç A., Aksoy Y., Kulik A. Fournier's gangrene: Etiology, treatment, and complications. *Ann. Plast. Surg.*, 47 (5): 523-7, 2001.
- Kılıç A., Aksoy Y. and Kılıç A.: Fournier's gangrene: Etiology, treatment, and complications. *Ann. Plast. Surg.*, 47 (5): 523-7, 2001.
- Chen S.Y., Fu J.P., Chen T.M. and Chen S.G.: Reconstruction of scrotal and perineal defects in Fournier's gangrene. *J. Plast. Rec. Aest. Surg.*, 64 (4): 528-34, 2011.
- Hasdemir A.O., Büyükaşık O. and Cöl C.: The clinical characteristics of female patients with Fournier's gangrene. *Int. Urogynecol J. Pelvic Floor Dysfunct.*, 20 (12): 1439-43, 2009.
- Karian L.S., Chung S.Y. and Lee E.S.: Reconstruction of Defects after Fournier Gangrene: A Systematic Review. *Eplasty*, 15: e18, 2015.
- Abid S., Mir M., Haroon R., et al.: Reconstruction of soft tissue defects in Fournier's gangrene at a tertiary care center. *Int. J. Res. Med. Sci.*, 4 (10): 4341-4318, 2016.
- Orringer J.S., Kang S., Johnson T.M., Karimipour D.J., Hamilton T., Hammerberg C., Voorhees J.J. and Fisher G.J.: Connective tissue remodeling induced by carbon dioxide laser resurfacing of photodamaged human skin. *Arch. Dermatol.*, 140: 1326-1332, 2004.
- Negishi K., Wakamatsu S., Kushikata N., Tezuka Y., Kotani Y. and Shiba K.: Full-face photorejuvenation of photodamaged skin by intense pulsed light with integrated contact cooling: Initial experiences in Asian patients. *Lasers Surg. Med.*, 30 (4): 298-305, 2002.
- Prieto V.G., Diwan A.H., Shea C.R., Zhang P. and Sadick N.S.: Effects of intense pulsed light and the 1,064 nm Nd:YAG laser on sun-damaged human skin: Histologic and immunohistochemical analysis. *Dermatol. Surg.*, 31 (5): 522-525, 2005.
- Amano N., Takai S., Jin D., Ueda K. and Miyazaki M.: Possible roles of mast cell-derived chymase for skin rejuvenation. *Lasers Med. Sci.*, 24 (2): 223-229, 2009.
- Yaghmai D., Garden J.M., Bakus A.D., Spenceri E.A., et al.: Hair removal using a combination of the radiofrequency and intense pulsed light source. *J. Cosmet Laser Ther.*, 6 (4): 201-207, 2009.
- Elmelegy N. and El Sakka D.M.: Intensive pulsed light, radiofrequency, and cooling in the aesthetic treatment of unpleasant facial scars. *J. Clin. Exp. Dermatol. Res.*, 6 (4). DOI:10.4172/2155-9554.10000296.2015.
- Gold M.H., Biron J.A. and Sensing W.: Facial skin rejuvenation by combination treatment of IPL followed by continuous and fractional radiofrequency. *J. Cosmet. Laser Ther.*, 18 (1): 2-6, 2016.
- Garden J.M., Zelickson B., Gold M.H., Friedman D., et al.: Home hair removal in all skin types with a combined radiofrequency and optical energy source device. *Dermatol. Surg.*, 40 (2): 142-151, 2014.
- Elmelegy N. and EL Sakka D.M.: Electrophoto-biomodulation in the aesthetic treatment of postburn hypopigmentation clinical response in relation to histopathological changes. *Ann. Plast. Surg.*, 79 (3): 264-269, 2017.
- Taub A.F. and Devita E.C.: Successful treatment of erythematotelangiectatic with rosacea with pulsed light and radiofrequency. *J. Clin. Aesthet. Dermatol.*, 1 (1): 37-40, 2008.

- 17- Carvalho J.P., Hazan A., Cavalcanti A.G. and Favorito L.A.: Relation between the area affected by Fournier's gangrene and the type of reconstructive surgery used. A study with 80 patients. *Int. Braz. J. Urol.*, 33: 510-4, 2007.
- 18- Akilov O., Pompeo A., Sehr D., Bowlin P., Molina W.R. and Kim F.J.: Early scrotal approximation after hemiscrotoectomy in patients with Fournier's gangrene prevents scrotal reconstruction with a skin graft. *Can Urol. Assoc. J.*, 7: E481-5, 2013.
- 19- Okeke L.I.: Fournier's gangrene in Ibadan. *Afr. J. Med. Sci.*, 29: 323-4.
- 20- Campbell R.M. (1957): Dermatome grafting of the totally denuded testes. *Plast. Reconstr. Surg.*, 19: 509-13, 2000.
- 21- Bhatnagar A.M., Mohite P.N. and Suthar M.: Fournier's gangrene: A review of 110 cases for etiology, predisposing conditions, microorganisms, and modalities for coverage of necrosed scrotum with bare testes. *N. Z. Med. J.*, 121: 46-56, 2008.
- 22- Tan B.K., Rasheed M.Z. and Wu W.T.: Scrotal reconstruction by testicular apposition and wrap-around skin grafting. *J. Plast. Reconstr. Aesthet. Surg.*, 64: 944-8, 2011.
- 23- Tiwari I.N., Seth H.P. and Mehdiratta K.S.: Reconstruction of the scrotum by thigh flaps. *Plast. Reconstr. Surg.*, 66: 605-7, 1980.
- 24- Yu P., Sanger J.R., Matloub H.S., Gosain A. and Larson D.: Anterolateral thigh fasciocutaneous island flaps in perineoscrotal reconstruction. *Plast. Reconstr. Surg.*, 109: 610-6, discussion 617-8, 2002.
- 25- Chen S.Y., Fu J.P., Chen T.M. and Chen S.G.: Reconstruction of scrotal and perineal defects in Fournier's gangrene. *J. Plast. Reconstr. Aesthet. Surg.*, 64: 528-34, 2011.
- 26- Ferreira P.C., Reis J.C., Amarante J.M., et al.: Fournier's gangrene: A review of 43 reconstructive cases. *Plast. Reconstr. Surg.*, 119: 175-84, 2007.
- 27- Parkash S. and Gajendran V.: Surgical reconstruction of the sequelae of penile and scrotal gangrene: A plea for simplicity. *Br. J. Plast. Surg.*, 37: 354-7, 1984.
- 28- Por Y.C., Tan B.K., Hong S.W., et al.: Use of the scrotal remnant as a tissue-expanding musculocutaneous flap for scrotal reconstruction in Paget's disease. *Ann. Plast. Surg.*, 51: 155-60, 2003.
- 29- Boukind H., Ezzoubi M., Chafiki N., et al.: Scrotal reconstruction after necrotizing cellulitis of the perineum and external genital organs. Apropos of 21 cases. *Ann. Urol. (Paris)*, 29: 308-12, 1995.
- 30- El-Khatib H.A.: V-Y fasciocutaneous pudendal thigh flap for repair of the perineum and genital region after necrotizing fasciitis: Modification and new indication. *Ann. Plast. Surg.*, 48: 370-5, 2002.
- 31- Coskunfirat O.K., Uslu A., Cinpolat A. and Bektas G.: Superiority of medial circumflex femoral artery perforator flap in scrotal reconstruction. *Ann. Plast. Surg.*, 67: 526-30, 2011.
- 32- Karac, al N., Livaoglu M., Kutlu N. and Arvas L.: Scrotum reconstruction with neurovascular pedicled pudendal thigh flaps. *Urology*, 70: 170-2, 2007.
- 33- Hsu H., Lin C.M., Sun T.B., Cheng L.F. and Chien S.H.: Unilateral gracilis myofasciocutaneous advancement flap for single-stage reconstruction of scrotal and perineal defects. *J. Plast. Reconstr. Aesthet. Surg.*, 60: 1055-9, 2007.
- 34- Lee S.H., Rah D.K. and Lee W.J.: Penoscrotal reconstruction with gracilis muscle flap and internal pudendal artery perforator flap transposition. *Urology*, 79: 1390-4, 2012.
- 35- Spyropoulou G.A., Jeng S.F., Demiri E., Dionyssopoulos A. and Feng K.M.: Reconstruction of perineoscrotal and vaginal defects with pedicled anterolateral thigh flap. *Urology*, 82: 461-5, 2013.
- 36- Basil M. Hantash, Anan Abu Ubeid, Hong Chang, Reza Kafi and Bradley Renton: Bipolar Fractional Radiofrequency Treatment Induces Neoenlastogenesis and Neocollagenesis Lasers in Surgery and Medicine, 41: 1-9, 2009.
- 37- John Moffett, Nicole J. Kubat, Nicole E. Griffin, Mary C. Ritz, Frank R. George: Pulsed radio frequency energy field treatment of cells in culture: Increased expression of genes involved in angiogenesis and tissue remodeling during wound healing. *The Journal of Diabetic Foot Complications*, 3 (2): 30-39, 2011.
- 38- Seng-Feng Jeng, Jian-A Chen, Li-Ren Chang, Chien-Chung Chen, Hsiang-Shun Shih, Ting-Mao Chou, Hsing-Fu Chen, Guan-Ming Feng, and Chih-Hui Yang: Beneficial Effect of Intense Pulsed Light on the Wound Healing in Diabetic Rats. *Lasers Surg. Med.*, 52 (6): 530-536, 2020.
- 39- Trinh Cao Minh, Do Xuan Hai and Pham Thi Ngoc: Effects of Intense Pulsed Light on Tissue Vascularity and Wound Healing: A Study with Mouse Island Skin Flap Model. *Plast. Surg. Int.*, 2015: 429367, 2015.
- 40- Odom G.L., Finney W. and Woodhall B.: Cervical disk lesions. *J. Am. Med. Assoc.*, 166: 23-28. 1958.