

# Electrophotobiomodulation: A New Step in the Reconstructive Ladder of Post-Traumatic Defects

NADER ELMELEGY, M.D.; YASER EL HAWARY, M.D. and MOHAMED SAAD SADAKA, M.D.

*The Department of Plastic & Reconstructive Surgery, Faculty of Medicine, Tanta University*

## Abstract

**Background:** Researchers have tried to improve their “reconstructive ladders” by adding more steps for a larger applicability that fits most of the situations, as more methods and technology, such as free tissue transfer, robotic surgery and vascularized composite allotransplant, have become accessible. Electrophotobiomodulation was reported as a successful tool in wound management with very narrow spectrum of complications.

**Objective:** To evaluate the safety and efficacy of Electrophotobiomodulation in reconstruction of post-traumatic defects and its place in the reconstructive ladder.

**Patients and Methods:** Between May 2017 and January 2023, 38 patients underwent treatment with Electrophotobiomodulation, including 17 on the face, 7 on the upper limb, 3 on the upper back, and 11 on the lower limb. Both throughout sessions and at least six months after the patient’s final session, photographs of the patient and a post-treatment wound assessment were evaluated and also patient satisfaction with the result was assessed.

**Results:** Regarding post-treatment clinical evaluation of our patients, it was excellent to good in the majority of cases (87%). Patient satisfaction rate was also excellent to good in the majority of patients (84%). Minor issues were experienced by small percent of patients (8%) including hyperpigmentation, hypopigmentation, and hypertrophic scarring.

**Conclusions:** Electrophotobiomodulation is a safe effective technique that can induce very good wound healing without the need for any type of flap or skin graft, preserving other tissues from mutilation and hence it deserves its place in the reconstructive ladder.

**Key Words:** Photobiomodulation, Reconstruction – Ladder – Traumatic – Defects.

**Disclosure:** The authors state that they have no financial relation to the study’s subject matter, and they have no conflicts of interest.

---

**Correspondence to:** Dr. Mohamed Saad Sadaka,  
E-Mail: mohammed.sadaka@med.tanta.edu.eg

**Ethical Considerations:** The Helsinki Declaration’s tenets were followed while conducting this study. The Tanta University Faculty of Medicine’s Ethical Committee gave its approval for this work. All patients provided written agreement after receiving full information about the surgery and the publication of their images.

## Introduction

All plastic surgeons are familiar with the reconstructive ladder. The basic concept of sorting the methods of reconstruction by their complexity is still valid and is evolving and undergoing continuous modification. The main frame of this sorting starts with secondary intention healing followed by primary closure and then local and remote flaps [1].

The strict application of the reconstructive ladder has several limitations. Even while there is a merit in using the simplest method of reconstruction for a given defect, certain situations necessitate more complex methods of reconstruction to achieve certain goals that will not be achieved by the simpler method even if it can close the wound. Several changes to the reconstructive ladder have been suggested to address these issues. Researchers have tried to improve their “reconstructive ladders” by adding more steps for a larger applicability that fits most of the situations, as more methods and technology have become accessible, such as free tissue transfer, robotic surgery and vascularized composite allotransplant [2].

Electrophotobiomodulation (EPBM) is the combination of radiofrequency (RF) energy with intense pulsed light (IPL) and it was reported by the senior author of this article as a safe and successful tool in many applications including wound management with very narrow spectrum of complications [3-6]. In this article we present Electrophotobiomodulation as a new step in the reconstructive ladder.

## Patients and Methods

This is a prospective clinical study that has been conducted on 38 patients who were presented to the Department of Plastic and Reconstructive surgery in Tanta University or in the author's private clinic with posttraumatic defects during the period between May 2017 and January 2023. All patients underwent the EPBM treatment, including 17 patients on the face, seven patients on the upper limb, three patients on the upper back, and 11 on the lower limb.

Approval was obtained before commencing this study from the Ethical Committee in our University. All patients signed informed consent regarding the procedure to be done. It was made clear in this work that neither general anesthesia nor surgery would be used.

### Exclusion criteria:

Patients with conditions that affect wound healing, such as photosensitivity, steroid use, and collagen vascular abnormalities were excluded from the study.

### The Electrophotobiomodulation procedure is:

With two hands, an e-light cosmetic tool was used for this task. Its production is being handled by Beijing Oriental Wison Engineering & Technology Co. When we first encountered the patient at an outpatient clinic, we began using Electrophotobiomodulation for the patients with raw areas that were not found to have excessive exposure to vital structures. The treating physician and patient both used specialized eye protection equipment. Eutectic mixture of local anesthetic (EMLA) 5% cream was applied over the treatment area half an hour before the commencement of the treatment session.

We used the stimulatory mode, promoting tissue repair. We used a combination of IPL and RF to stimulate macrophages, keratinocytes, and angiogenesis based on the findings of the preceding investigations. Each patient receives twice weekly sessions; however, the frequency of sessions could be modified according to the patient's response and the treating physician's evaluation. This twice weekly regimen is defined by the senior author of this work based on his experience in this modality of treatment [3-6]. 24-82 pulses per session were provided during a single treatment. Three to seven minutes per session were spent on each therapy, depending on the condition being treated. Each patient's required number of sessions was recorded. Between sessions, wounds were managed by daily saline-soaked dressing.

The IPL component was employed with various screens to prevent skin problems (530nm, 580nm, 640nm, and 755nm, depending on the skin color).

We stopped the treatment once the lesion has fully healed. Both throughout sessions and at least six months after the patient's final session, photographs of the patient and a post-treatment wound assessment were done and also patient satisfaction with the result was assessed.

## Results

The most common age group in our patients was 10-20 years followed by the age group 20-30 years. We had more male than female patients. The most common site of defects in our study was the lower limb followed by upper limb and nose (Table 1).

Regarding the post-treatment clinical evaluation of our patients, it was excellent to good in the majority of cases (87%). Patient satisfaction rate was also excellent to good in the majority of patients (84%). Minor issues were experienced by a small percent of patients (8%) including hyperpigmentation, hypopigmentation and hypertrophic scarring (Table 2).

Table (1): Presented Age, gender, Fitzpatrick skin type, and filtration type in our study.

The Parameter	Patient count (Total 38)	Percent
<i>Patient's age at first visit:</i>		
10-20Y	15	39.5
20-30Y	8	21.1
30-40Y	2	5.2
40-50Y	4	10.5
>50Y	9	23.7
<i>Gender:</i>		
Boys	23	60.5
Girls	15	39.5
<i>Areas involved:</i>		
Nose	7	18.4
Cheek	4	10.5
Neck	6	15.9
Back	3	7.9
Upper limb	7	18.4
Lower limb	11	28.9
<i>Fitzpatrick skin type:</i>		
Type 3	12	31.6
Type 4	21	55.2
Type 5	5	13.2
<i>Filter type:</i>		
530 nm	11	28.9
580 nm	13	34.2
640 nm	9	23.7
755 nm	5	13.2

Table (2): Descriptive analytical information on clinical evaluation result, patient satisfaction, and problems encountered.

Variable	Total Number of patients (38)	Percentage
<i>Clinical satisfaction:</i>		
Excellent	12	31.6
Good	21	55.2
Fair	5	13.2
<i>Patient satisfaction:</i>		
Excellent	7	18.4
Good	25	65.7
Fair	6	15.9
<i>Problems encountered:</i>		
Hyperpigmentation	2	5.3
Hypopigmentation.	3	7.9
Hypertrophic scar	3	7.9
Keloid	0	0

All cases were presented to us within the first week of injury and they did not undergo any other treatment modality before presenting to us except patients shown in Figs. (3,4) who were presented two months after injury, and they have failed

negative pressure wound therapy. The wounds are presented in the photos at the time they were first presented to us. The time to healing in our patients was in a range of one to three weeks.

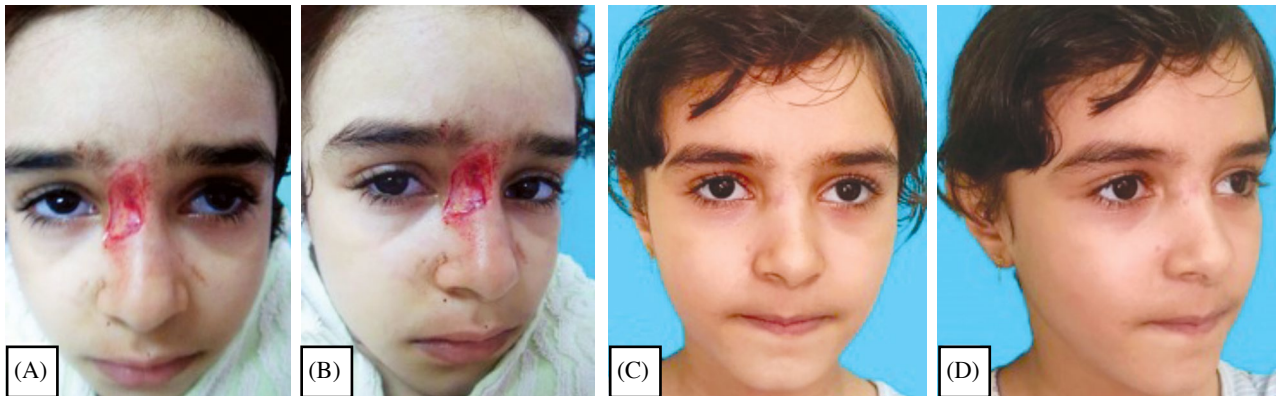

Fig. (1): Nine years old girl with posttraumatic defect of nose. (A) Frontal view before application of EPBM. (B) Oblique view before application of EPBM. (C) Frontal view after application of EPBM. (D) Oblique view after application of EPBM.

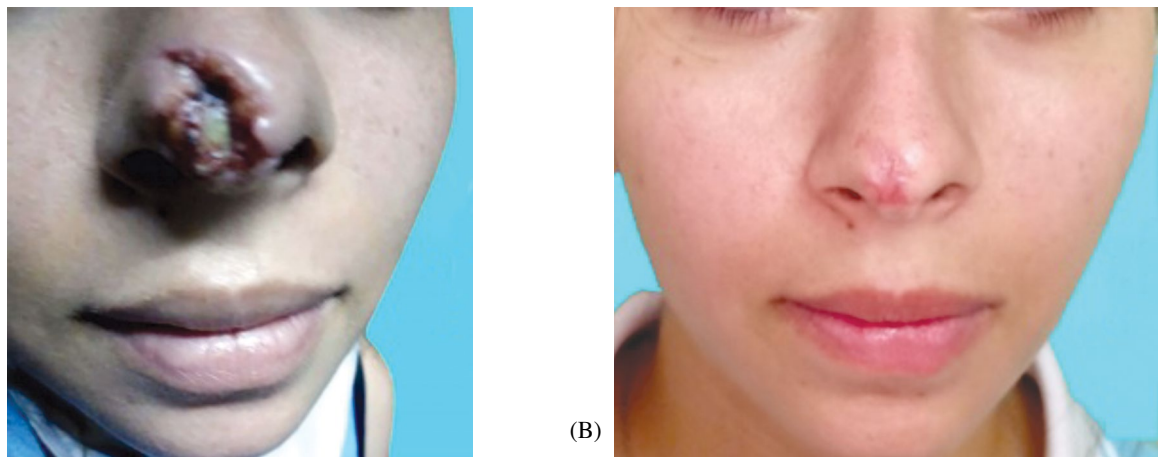


Fig. (2): Twenty-one years old lady with Untreated post-traumatic nasal skin and subcutaneous tissue loss with exposure of the lower lateral cartilage of the lower third of the nose. (A) Frontal view before application of EPBM. (B) Frontal view after application of EPBM.

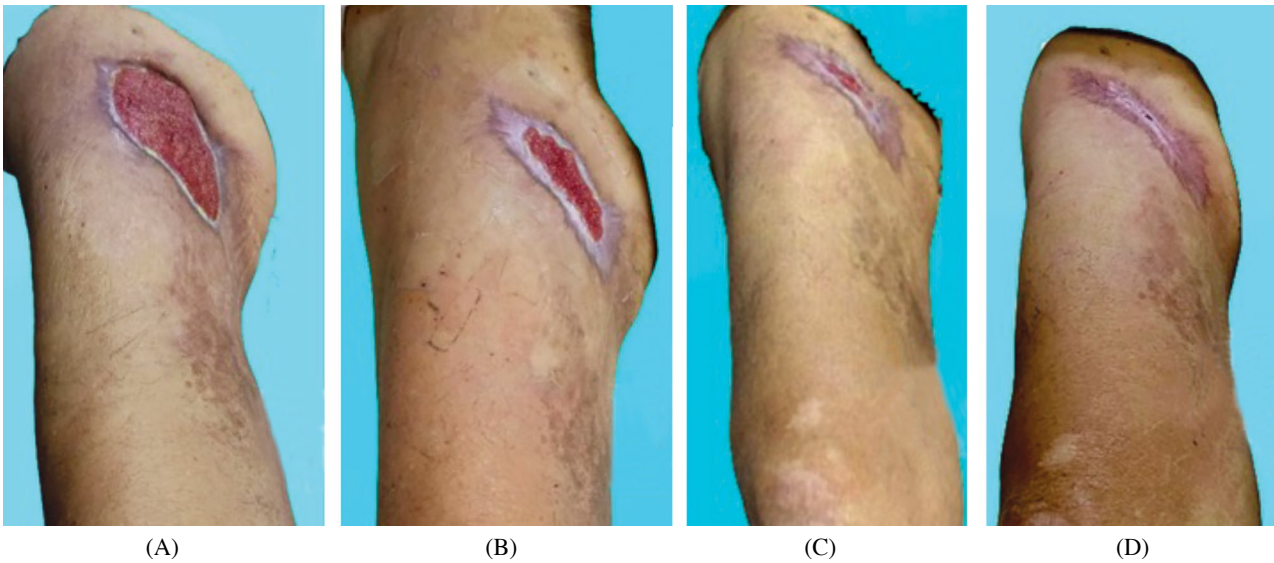

Fig. (3): Diabetic 76-year-old man with raw area in the groin region. (A) Before application of EPBM. (B,C,D) The progress of defect throughout the period of EPBM therapy.

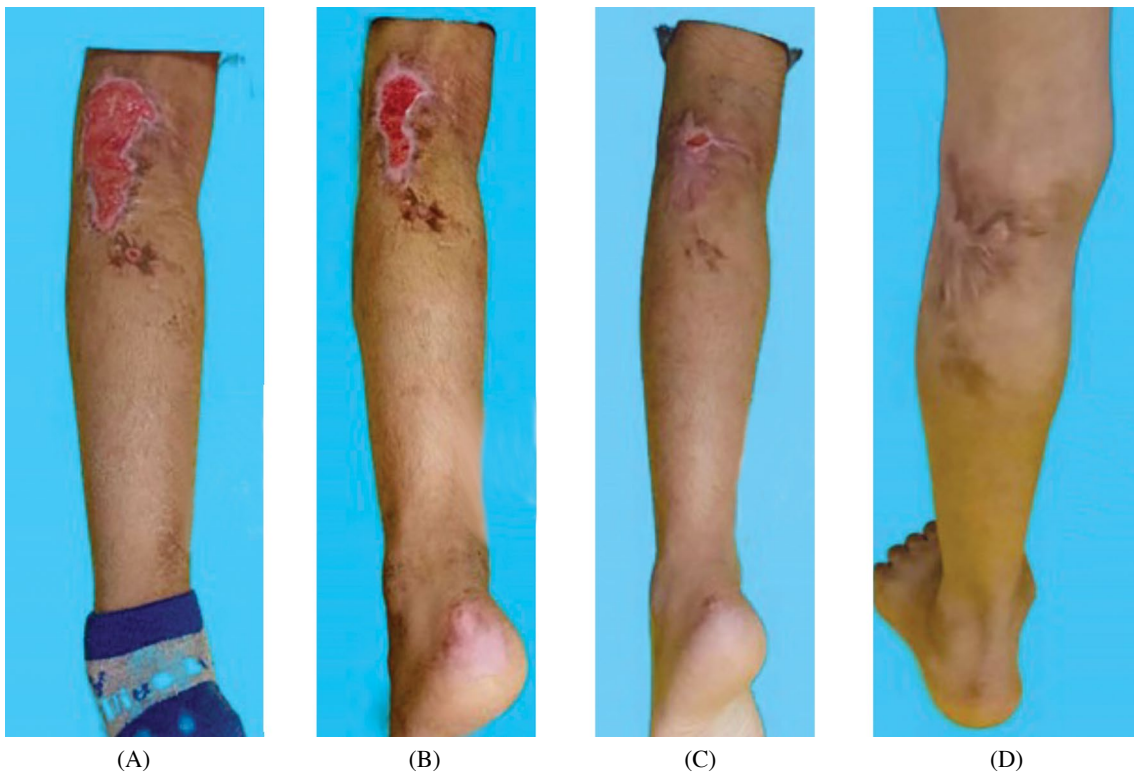


Fig. (4): 13-year-old male child with post-traumatic raw area at the back of the knee. (A) Before application of EPBM. (B,C,D) The progress of the wound throughout the period of application of EPBM until complete healing.

**Discussion**

The reconstructive ladder is a construct that welcomes upgrading, which is the primary reason for its stability throughout the ages. The balance between preserving the donor site and repairing defects is indicated by the term “reconstructive balance,” which emphasizes its significance [7]. Other ideas like a reconstructive lift, and reconstructive

matrix, in the authors’ opinion, act as tools that aid the surgeon in selecting one of the rungs of the reconstructive ladder. In this article, we evaluated EPBM as a new step in the reconstructive ladder.

Laser is the use of coherent monochromatic light to generate heat-induced injury of the skin. The type of laser wavelength selected is based on depth and target chromophore properties. IPL ther-

apy uses a flash lamp light source that emits non-coherent light with wavelengths between 515nm and 1200nm. Filter sets allow for the targeting of selective chromophores (melanin versus hemoglobin) [8]. The advances in RF energy significantly improved the application of light-based devices because RF delivers pure heat effect that differs according to electrical characters of each tissue [9]. Electrophotobiomodulation is the use of a combination of IPL and RF to modulate tissues to repair itself, to reduce inflammation, and to assist in wound healing [4].

In our case series, and as shown in case examples presented in this article, the tissue defects presented could be reconstructed by skin graft as the first step in the conventional reconstructive ladder. However, skin graft frequently contracts and will lead to significant color and texture mismatches at the recipient site especially if the graft was used to reconstruct any area of the face like the nose. Also, skin grafts do not provide the same pliability and glide that is required in the skin of certain areas like the nose and they can be significantly morbid at the donor area.

The second step in the standard reconstructive ladder would be the use of local flaps from neighboring tissues. However, this will be at the expense of additional scarring which is undesirable especially in the face. Additionally, local flaps have the risk of failure which will cost the patient another reconstructive procedure in addition to the original donor site morbidity and the prolonged period of hospitalization and wound care. Another option might be distant and free flaps, but these are unfavorable choices because of the poor color and texture match, significant donor site morbidity, and the high likelihood of failure.

In these instances, we used EPBM, which combines RF with IPL. The Electrophotobiomodulation mode of action relies on the stimulatory actions of IPL and RF which stimulates macrophages to aid in the quick debridement of necrotic tissue. It also involved stimulating fibrocytes to lay down collagen, keratinocytes to induce rapid proliferation and angiogenesis. The outcomes were quite pleasing with very hardly perceptible scars, no requirement for a donor site with all its potential difficulties, well-matched tissues in terms of color and texture, and the avoidance of scar contracture with preservation of normal function. Previous authors have described the application of Photobiomodulation in wound management with successful results [10,11].

Negative pressure wound therapy (NPWT) is a noninvasive method that can achieve healing in some complex wounds without donor site morbidity. However, when compared to EPBM, we find that NPWT has higher cost, requires continuous expert care, may require hospitalization and is difficult to apply in many areas, such as the face for

example. Also, NPWT has many complications such as infection, bleeding, mechanical failure and retained sponge [12,13].

In contrast to conventional methods, EPBM stimulation was employed in our research to enhance the physiological characteristics of numerous cell types, including macrophages, fibrocytes, and keratinocytes. This had a very beneficial outcome because it allowed for the removal of the dead tissue without bleeding while also accelerating the healing process [3]. A study by Mosca, et al. [14] evaluated the effectiveness of Photobiomodulation treatment in the healing of burn wounds by observing collagen deposition, fibroblast proliferation, angiogenesis, and wound contraction. They discovered that photo biomodulation increased collagen deposition, revascularization, and tissue repair in second-degree and third-degree burn lesions. Limited light-emitting diode (LED) therapy (658nm), in burn patients, was studied by Whelan, et al. They concluded that LED therapy accelerates healing with higher epithelialization, greater collagen production, increased keratinocyte and fibroblast proliferation, and a reduction in pain and pruritus [15]. This is also what we observed in our patients.

The main limitation of our study is that there is no control group in which no intervention to be done except saline soaked dressing. This will help to statistically quantify the effect of EPBM on wound healing and warrants further study. However, many studies in the literature reported the results of conventional dressing in soft tissue defects [16-25]. In a study of 393 patients who underwent only conventional dressing as a treatment to their wounds, healing was achieved in 81.4% of patients with median time to healing of 86 days. The mean surface area of wounds was 32 cm<sup>2</sup> and the commonest locations were the abdomen (34%) followed by the lower extremities (30%). They concluded prolonged healing times and common adverse events worsening the health-related quality of life [19]. Many other studies reported the time of wound healing using conventional dressing to be 30-69.5 days [24], 65 days with hydrocolloid dressing (range 40-137 days) and 68 days with moist gauze dressing (range 33-168 days) [25]. Other workers reported the percentage of their cases that achieved wound healing using conventional dressing to be 83% [23], 40% after 12 weeks and 60% after 24 weeks [22], or arrest of healing in all cases (defects of 6.5 to 12.5cm in length) [21].

The reliance on conventional dressing for wound healing has many drawbacks. It needs frequent change, less cost effective, bacterial protection is lost if outer surface soaked, painful removal, and can allow evaporation and wound dehydration [18]. Also, it has many complications as exuberant granulation tissue, contractures, hypertrophic scars,



keloids, and infections [17,20]. Arnaud evaluated scar thickness after wounds healed by conventional dressing on a scale from 1 to 10 and they found it at a mean of 6.5. They also found the average healing period 57 days (in the head) or 127 days (in lower extremity) [16].

Compared to all above mentioned studies on conventional dressing, we find our technique effective in wound management whether regarding the short healing period (1-3 weeks) or the excellent scar quality and avoidance of contractures. The authors believe that EPBM would become a memorable reconstructive alternative with substantial benefits once an independent rung is added to the reconstructive ladder for it (Table 3).

Table (3): The reconstructive ladder proposed by the authors after adding the EPBM.

Primary closure
Adjunctive wound therapy like Electrophotobiomodulation and negative Pressure Wound Therapy
Closure by Secondary Intention
Skin Graft(s)
Local Flap(s)
Pedicled Freestyle Perforator Flap(s)
Tissue Expansion
Free Tissue transfer

### Conclusions:

Electrophotobiomodulation is a safe effective technique that can induce very good wound healing without the need for any type of flap or skin graft, preserving other tissues from mutilation and hence it deserves its place in the reconstructive ladder.

### References

- 1- Janis J.: The New Reconstructive Ladder: Modifications to the Traditional Model, 124: 469-70, 2009.
- 2- Al Deek N.F. and Wei F.C.: It is the time to say good bye to the reconstructive ladder/lift and its variants. Journal of plastic, reconstructive & aesthetic surgery: JPRAS, 70 (4): 539-40, 2017.
- 3- Elmelegy N.G.: Aesthetic Treatment of Acute Burns of the Face Using Electro-Photobiomodulation. Journal of Burn Care & Research, 2023.
- 4- Elmelegy N.G.: Hypertrophic Scars of the Hand: The Role of Electrophotobiomodulation Theory as a Recent Line of Treatment. Plastic and Reconstructive Surgery, 151 (2): 375-83, 2023.
- 5- Elmelegy N.: Epiderm-Abrasion-Assisted Intensive Pulsed Light and Radiofrequency in Aesthetic Treatment Extensive Facial Freckles. Aesthetic Plastic Surgery, 44 (6): 2259-67, 2020.
- 6- Elmelegy N.G., Hegazy A.M., Sadaka M.S. and Abdeldaim D.E.: Electrophotobiomodulation in the treatment of facial post-burn hypertrophic scars in pediatric patients. Annals of burns and fire disasters, 31 (2): 127-32, 2018.
- 7- Turner A.J. and Parkhouse N.: Revisiting the reconstructive ladder. Plastic and Reconstructive Surgery, 118 (1): 267-8, 2006.
- 8- Trivedi M.K., Yang F.C. and Cho B.K.: A review of laser and light therapy in melasma. International journal of women's dermatology, 3 (1): 11-20, 2017.
- 9- Sadick N. and Rothaus K.O.: Aesthetic Applications of Radiofrequency Devices. Clinics in Plastic Surgery, 43 (3): 557-65, 2016.
- 10- Nair H.K.R., Chong S.S.Y. and Selvaraj D.D.J.: Photobiomodulation as an Adjunct Therapy in Wound Healing. The international journal of lower extremity wounds, 22 (2): 278-82, 2023.
- 11- Solmaz H., Ulgen Y. and Gulsoy M.: Photobiomodulation of wound healing via visible and infrared laser irradiation. Lasers in Medical Science, 32 (4): 903-10, 2017.
- 12- Novelli G., Daleffe F., Birra G., et al.: Negative pressure wound therapy in complex cranio-maxillofacial and cervical wounds. International wound journal, 15 (1): 16-23, 2018.
- 13- Enescu D.M., Stoicescu S., Tomiță M., Nacea I., Ioniță D. and Tatar R.: Management of lower extremity traumatic injuries with negative pressure wound therapy: Experience of a pediatric plastic surgery department. Injury, 51 (Suppl. 4): S9-s15, 2020.
- 14- Mosca R.C., Ong A.A., Albasha O., Bass K. and Arany P.: Photobiomodulation Therapy for Wound Care: A Potent, Noninvasive, Photoceutical Approach. Advances in skin & wound care, 32 (4): 157-67, 2019.
- 15- Whelan H.T., Smits R.L., Jr., Buchman E.V., et al.: Effect of NASA light-emitting diode irradiation on wound healing. Journal of Clinical Laser Medicine & Surgery, 19 (6): 305-14, 2001.
- 16- Karen Arnaud: Enhanced Secondary Intention Healing vs. Standard Secondary Intention Healing in Mohs Surgical Defects on the Head and Distal Lower Extremities. ClinicalTrials.gov. May-2023.
- 17- Bertone A.L.: Second-intention healing. The Veterinary clinics of North America Equine Practice, 5 (3): 539-50, 1989.
- 18- Boateng J.S., Matthews K.H., Stevens H.N. and Eccleston G.M.: Wound healing dressings and drug delivery systems: A review. Journal of Pharmaceutical Sciences, 97 (8): 2892-923, 2008.
- 19- Chetter I.C., Oswald A.V., McGinnis E., et al.: Patients with surgical wounds healing by secondary intention: A prospective, cohort study. International Journal of Nursing Studies, 89: 62-71, 2019.
- 20- Donaldson M.R. and Coldiron B.M.: Scars after second intention healing. Facial plastic surgery: FPS, 28 (5): 497-503, 2012.

- 21- Jaffe A.T., Heymann W.R. and Lawrence N.: Epidermal maturation arrest. *Dermatologic surgery: Official publication for American Society for Dermatologic Surgery* [et al], 25 (11): 900-3, 1999.
- 22- Jull A.B., Cullum N., Dumville J.C., Westby M.J., Deshpande S. and Walker N.: Honey as a topical treatment for wounds. *The Cochrane database of systematic reviews*, 2015 (3): Cd005083, 2015.
- 23- Jurczak F., Dugré T., Johnstone A., Offori T., Vujovic Z. and Hollander D.: Randomised clinical trial of Hydrofiber dressing with silver versus povidone-iodine gauze in the management of open surgical and traumatic wounds. *International Wound Journal*, 4 (1): 66-76, 2007.
- 24- Vermeulen H., Ubbink D., Goossens A., de Vos R. and Legemate D.: Dressings and topical agents for surgical wounds healing by secondary intention. *The Cochrane database of systematic reviews*, 2004 (2): Cd003554, 2004.
- 25- Viciano V., Castera J.E., Medrano J., et al.: Effect of hydrocolloid dressings on healing by second intention after excision of pilonidal sinus. *The European Journal of Surgery Acta Chirurgica*, 166 (3): 229-32, 2000.