

Comparative Study between Fat Injection and Platelet Rich Plasma in Post Burn Facial Scar: Clinical and Histological Assessment

WAGDI M. ALI, M.D.*; ABDELRAHMAN M. SHEHATA, M.Sc.*; TAREK RAIEF, M.D.*;
MOHAMED ELYOUNSI, M.D.*; DALIA M. BADAR, M.D.** and YOUSSEF HASSAN, M.D.*

The Departments of Plastic Surgery* and Pathology**, Faculty of Medicine, Assiut University

Abstract

Background & Aim: There is no widely approved treatment procedure for post-burn scars, even though many therapy approaches have been promoted. Many previous studies separately evaluated fat injection and platelet rich plasma in treatment of post-burn scar. This study aimed to compare efficacy of both fat injection and platelet rich plasma in improving outcome of post burn facial scar.

Patients and Methods: In the current study a total of 60 patients with post-burn facial scar were enrolled. Those patients were randomly subdivided into either fat injection group (n=30) or platelet rich plasma group (PRP) (n=30). Baseline characteristics were recorded in addition to Vancouver score (VS) used to assess the scar and histological evaluation.

Results: Most patients were female with no significant differences among both groups regarding different baseline data and scar characteristics. There were no significant differences among the groups regarding baseline Vancouver score (VS) and epidermal thickness, but the fat injection group had significantly lower VS (3.67 ± 1.83 vs 3.87 ± 1.33 ; $p < 0.001$) and higher epidermal thickness (362.20 ± 92.73 vs. 255.40 ± 90.00 (um); $p < 0.001$) during follow-up. There were only two (6.7 percent) cases in the PRP group & four (13.3%) cases in the fat injection group developed conservatively relieved edema.

Conclusion: The autologous fat injection was effective and safe technique in improving the outcome of post-burn facial scar as evaluated by Vancouver score and epidermal thickness. It's recommended to perform such study on large number of patients in multiple centers with longer duration of follow-up to confirm such findings.

Key Words: Post-burn scar – Vancouver score – Platelets rich plasma – Fat injection.

Ethical Consideration: The study was approved by the Medical Faculty's Institutional Review Board (IRB). The current study was carried out in accordance with the Declaration

Correspondence to: Dr. Abdelrahman M. Shehata,
E-Mail: abdelrahmanshehata084@gmail.com

of Helsinki. All the patients gave their written consent. ClinicalTrials.gov has a record of the current study with identifier NCT04557514.

Disclosure: The authors declared no conflict of interest.

Introduction

Autologous platelet-rich plasma (PRP) has attracted a lot of interest recently in several medical specialties, including but not limited to dermatology, plastic surgery, oro-maxillofacial surgery, and orthopedics. Based on the idea that PRP, among other claimed favorable benefits, stimulates tissue regeneration since it contains cytokines and growth factors, it has been used in a variety of clinical contexts [1].

PRP is being further investigated for application in the treatment of chronic wounds, scars, and burns because of the predicted impact on tissue repair, forming a promising complementary strategy in reconstructive plastic surgery. Despite expanding clinical acceptance, there is still debate over PRP's efficacy since there is a dearth of reliable data and disagreement among academics over how to categorize PRP [2].

Fat grafting has been shown to improve the appearance of scars and fibrotic tissue on all areas of the face, including the skin's texture, color, volume, smoothness, and quality. The multipotent mesenchymal stem cells responsible for remodeling via grafting and differentiation are responsible for the autologous adipose graft's biological effects [3]. This study compared the effectiveness of platelet-rich plasma and fat injection in treating facial scars following burns excluding burn scar at area other than the face, post-burn scar with duration less than 1 year, patients with different comorbidities (diabetes mellitus, hypertension, thromboembolic diseases), immunocompromised patients and patient's refusal.

Patients and Methods

Study design and setting:

The Assiut University Hospitals' Plastic and Reconstructive Surgery Department completed a randomized controlled study. The work was completed in the years 2020-2022.

Selection criteria:

Any patient with postburn facial scar (atrophic scar) more than 1 year with age between 15 and 60 years was enrolled in the study. Atrophic scars of any size, shape and quality involved in the study.

Exclusion criteria:

- Extreme age (>60 or <15 years old).
- Patients with postburn scar at area other than the face.
- Post-burn scar with duration less than 1 year.
- Patients with different comorbidities (diabetes mellitus, hypertension, thromboembolic disease).
- Immunocompromised patients.
- Patient's refusal.

Sample size calculation:

To detect an effect clinically and histopathologically with $p > 0.05$ and 80% power, confidence level 0.95, we needed a sample size of 30 cases in each group. G power 3.1.3 was used to calculate the estimated size of the sample.

Participants and randomization:

Each case was randomly assigned to one of two groups: Either the PRP group (n=30) or the fat injection group (n=30) using the fast Calcs method for randomization (<https://www.graphpad.com/quickcalcs/randomize1/>).

Methodology:

Preoperative assessment:

All patients were undergone through history and careful evaluation of the burn.

Operative techniques:

Group I (PRP group):

All PRP procedures were performed without any kind of sedation. Before a patient goes into surgery, doctors take 15-30 milliliters of blood from a big vein. Each patient's acid citrate dextrose (ACD) anticoagulant was collected in a 6-ml tube.

Preparation:

For platelet separation the samples were centrifuged; with a relative Force of 1500 G, during 10min. The upper layer containing mostly platelets and WBCs, and intermediate thin layer (buffy coat) that is rich in white blood cells (WBCs) taken, then Another-time centrifugation of PRP protocol in empty tubes was selected to aid in formation of soft pellets (erythrocyte-platelet) at the bottom of the

tube by second spin at with force of 3000 G, during 10min in empty sterile tube. The upper portion of volume composed of platelet poor plasma (PPP) is discarded.

Face sterilization with betadine solution:

Injection:

Following processing, the PRP tubes were brought to room temperature before being delivered to the operating room, where they were applied using insulin sterilized syringes under the target scar following subcision. The amount of PRP injected depend on size of scar average 3-5ml. sunscreen used for 10 days. The injection repeated every month for 3 months.

Group II (fat injection):

All Cases of fat injection operated under general anesthesia.

Infiltration:

After 20 minutes of tumescent infiltration (500 ml of ringer lactate solution and adrenaline 1mg/ml) in multidirectional planes, subcutaneous fat began to be expelled in the syringe as the plunger of a 50ml luer-lock syringe was slowly pulled back and forth.

Face sterilization with betadine solution:

To gain access to subcutaneous fat with a 4 mm multiport harvesting cannula, the abdomen or flanks are stapled with knife no. (11). Donor site skin incisions were sutured using vicryl 4/0, and a compressive elastic dressing was used for five days to eliminate the possibility of collection.

Fat injection Superficial sub scar fat injection was done using cannula no (3 G) mounted on a Luer- Lock syringe after subcision, injection done in planes. Massage to the recipient sites done intra-operative and sunscreen described for all cases for 6 weeks as the skin is more susceptible to pigmentation changes. The amount of fat injected depend on size of scar average 10-20ml. Also, the injection repeated every month for 3 months.

Histopathological evaluation:

Skin punch biopsies were taken from the scar before and after one month of the procedures and after 3 months. At room temperature, the samples had been stored for 24 hours with formalin 10%, then embedded in paraffin and sectioned at a thickness of 5µm for standard histological analysis. For the purpose of analyzing the histopathological and histomorphometric alterations, sections were stained with (H&E) and seen under an Olympus microscope.

Histomorphometric evaluations required photographing all groups' specimens under 10x magnification with a camera (ToupCam LCMOS05100K-PA). Each case's epidermal thickness was measured

with the use of the open-source program Image J. (<http://imagej.nih.gov/ij/>).

The epidermal thickness was determined by measuring the vertical distance between the basal ridge and the granulosum interface. The epidermal thickness of a single tissue piece was evaluated in five different spots. Each sample was measured five times, and the average of those readings was used in the statistical analysis. The 10x objective's scale bar was calibrated against a known standard before measurements were taken, as detailed in previous studies [4,5].

Postoperative care:

Both groups received antibiotics for seven days, as well as anti-inflammatories, soothing agent, sun-screen, and analgesics (if required).

Follow-up:

Clinically:

- 1- Two blinded doctors using Vancouver scale (VS).
- 2- Researcher evaluate scar using Vancouver Scale (VS) at the first, second, and third month post-operative.

Histopathologically:

Histopathological evaluation before, after one month of the procedures and after 3 months.

Outcomes:

The major purpose of the study was to use the Vancouver Scar Scale (VS) to assess scar quality at 1, 3, and 6 months after surgery. (Fig. 1) [6]. Secondary outcome was to assess frequency of complications in each group.

Statistical analysis:

Statistical analysis was performed using IBM SPSS Statistics Version 23, 64 bits. Symmetrically distributed parameters were reported as mean and standard deviation. For ordinal categorical data, the median and range were shown in square brackets. Continuous variables were compared using student *t*-tests, while baseline and follow-up Vancouver scores were compared using a paired *t*-test. Categorical data was analyzed using the Chi-square test. Typically, the level of significance was fixed at 0.05.

Results

Baseline data of the studied patients (Table 1):

There were no significant differences among the PRP & fat injection groups' mean ages (29 ± 8.79 vs. 29.03 ± 7.49 (years); $p=0.98$). Patients were mostly female. In the PRP and fat injection groups, 10 (33.3%) and 8 (26.7%) patients, respectively, had a history of prior CO₂ laser therapy.

Characteristics of the scar in the studied groups (Table 2):

The most frequent etiology of burn was flame burn followed by scald burn. Round shaped scar was frequently present in the studied patients. Both groups had insignificant differences as regard scar and scar age.

Table (1): Baseline data of the research patients.

	PRP group (n=30)	Fat injection group (n=30)	<i>p</i> - value
Age (years)	29±8.79	29.03±7.49	0.98
Sex:			
Male	8 (26.7%)	7 (23.3%)	0.50
Female	22 (73.3%)	23 (76.7%)	
Smoking	8 (26.7%)	4 (13.3%)	0.16
Previous therapy	10 (33.3%)	8 (26.7%)	0.13

Data was expressed as frequency (percentage), mean (SD).
p-value was significant if <0.05.
PRP: Platelets rich plasma.

Table (2): Characteristics of the scar in the studied groups.

	PRP group (n=30)	Fat injection group (n=30)	<i>p</i> - value
Etiology:			
Flame burn	20 (66.7%)	17 (56.7%)	0.23
Scald burn	10 (33.3%)	9 (30%)	
Contact burn	0	4 (13.3%)	
Shape of the scar:			
Linear	10 (33.3%)	8 (26.7%)	0.58
Round	12 (40%)	16 (53.3%)	
Whole face	8 (26.7%)	6 (20%)	
Site of the scar:			
Cheek	14 (46.7%)	12 (40%)	0.13
Forehead	4 (13.3%)	10 (33.3%)	
Nose	4 (13.3%)	2 (6.7%)	
Whole face	8 (26.7%)	6 (20%)	
Size of the scar (cm)	10.27±6.7	11.63±6.08	0.93
Duration (months)	10.73±9.72	10.53±9.54	0.41

Data was expressed as frequency (percentage), mean (SD).
p-value was significant if <0.05.
PRP: Platelets rich plasma.

Vancouver score among the studied groups (Table 3, Fig. 2):

Fat injection group had significantly lower (3.67 ± 1.83 vs. 3.87 ± 1.33 ; $p<0.001$) Vancouver score improving vascularity, pigmentation, pliability, and decreasing height. There were insignificant differences among groups regarding baseline (6.80 ± 1.45 vs. 7.03 ± 1.73 ; $p=0.57$).

Histopathological results through the studied groups (Table 4, Fig. 3):

After fat injection and PRP injection, the stratum corneum thinned and the epidermis' thickness grew, and the uneven collagen bands were replaced with ordered, parallel new collagen fibrils, with a variable degree as these changes were more prominent in fat injection (Fig. 3). Fat injection group had significantly higher epidermal thickness during follow-up (362.20 ± 92.73 vs. 255.40 ± 90.00 (μm); $p < 0.001$).

Frequency of complications in the studied groups (Table 5):

Post-injection edema was reported in 2 (6.7%) patients of PRP group and 4 (13.3%) patients of fat injection group. The majority (93.3% vs. 96.7%) of both groups didn't report any complications. Insignificant differences present between both groups as regard frequency of complications ($p = 0.18$).

Table (3): Vancouver score in the studied groups.

	PRP group (n=30)	Fat injection group (n=30)	p_1 - value
<i>Vancouver score:</i>			
Baseline	6.80 ± 1.45	7.03 ± 1.73	0.57
Follow-up	3.67 ± 1.83	3.87 ± 1.33	0.64
p_2 value	<0.001	<0.001	

Data was expressed as mean (SD).

p -value was significant if < 0.05 .

PRP: Platelets rich plasma.

- p_1 value compares between both groups while p_2 value compares between baseline and follow score in each separate group.

Table (4): Epidermal thickness in the studied groups.

	PRP group (n=30)	Fat injection group (n=30)	p_1 - value
<i>Epidermal thickness:</i>			
Baseline	126.60 ± 42.54	127.98 ± 30.98	0.88
Follow-up	255.40 ± 90.00	362.20 ± 92.73	
p_2 value	<0.001	<0.001	<0.001

Data was expressed as mean (SD).

p -value was significant if < 0.05 .

PRP: Platelets rich plasma.

- p_1 value compares between both groups while p_2 value compares between baseline and follow score in each separate group.

Table (5): Frequency of complications in the studied groups.

	PRP group (n=30)	Fat injection group (n=30)	p_1 - value
<i>Complications:</i>			
Edema	2 (6.7%)	4 (13.3%)	0.18
No complications	28 (93.3%)	26 (96.7%)	

Data was expressed as frequency (percentage).

p -value was significant if < 0.05 .

PRP: Platelets rich plasma.

Scar characteristics	Score
<i>Vascularity:</i>	
Normal	0
Pink	1
Red	2
Purple	3
<i>Pigmentation:</i>	
Normal	0
Hypopigmentation	1
Hyperpigmentation	2
<i>Pliability:</i>	
Normal	0
Supple	1
Yielding	2
Firm	3
Ropes	4
Contracture	5
<i>Height (mm):</i>	
Flat	0
<2	1
2-5	2
>5	3
Total score	13

Fig. (1): Vancouver score scale and its parameters (6).

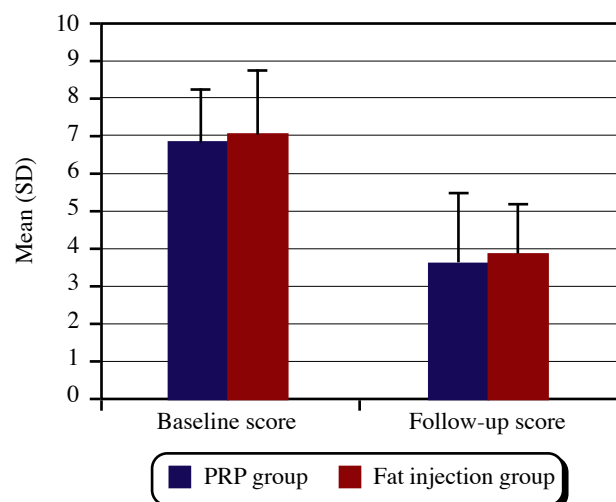


Fig. (2): Baseline and follow-up Vancouver score in the studied groups. PRP: Platelets rich plasma.

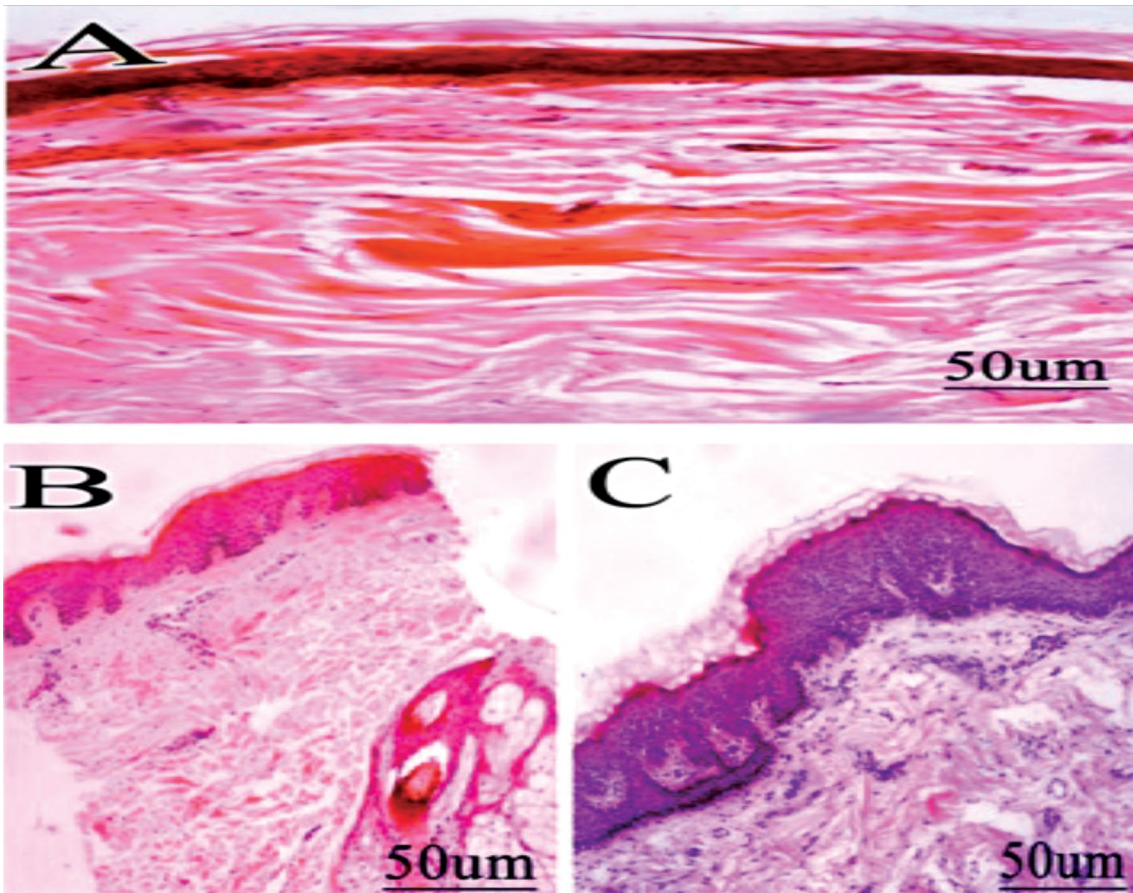


Fig. (3): Histopathology of specimens in the current study. (A) Photomicrograph of a patient's post-burn scar demonstrating hyperkeratosis and flattening of rete ridges in a portion of skin. (B) Picture from section of patient with post burn scar after three sessions of PRP injection exhibiting thinning in the stratum corneum and thickened epidermis. (C) Picture from section of patient with after fat injection demonstrating thinner stratum corneum than in cases with PRP injection and higher epidermal thickness.

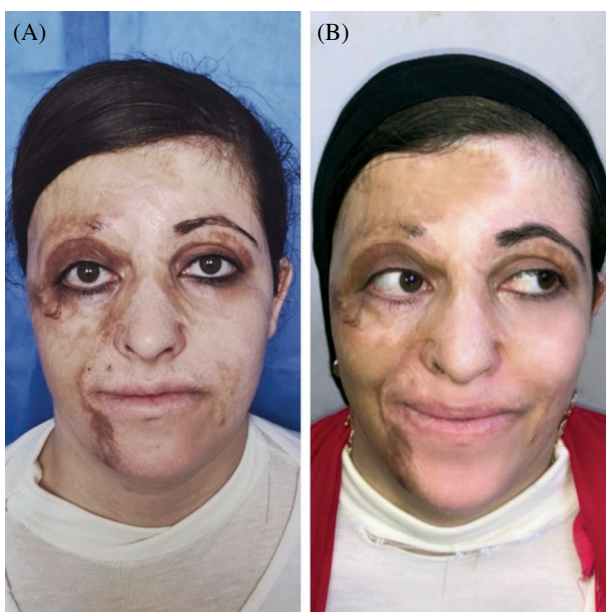

Fig. (4): A case of fat injection: (A): Preoperative and (B) Post-operative 3 months after injection.

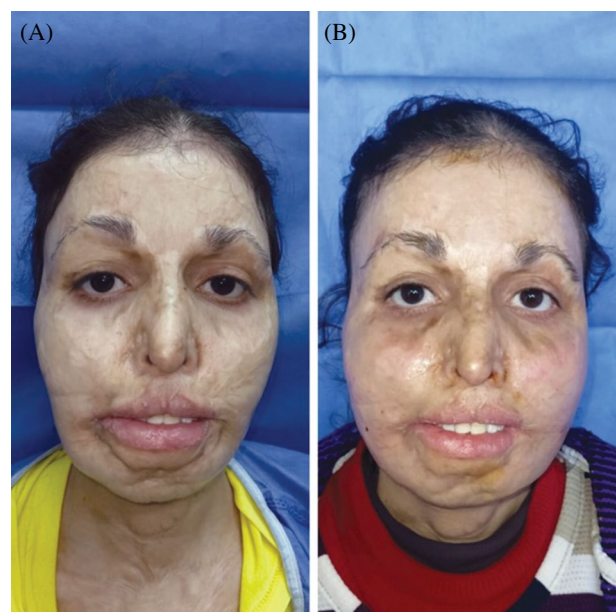


Fig. (5): A case of fat injection: (A): Preoperative and (B): Post-operative 3 months after injection.

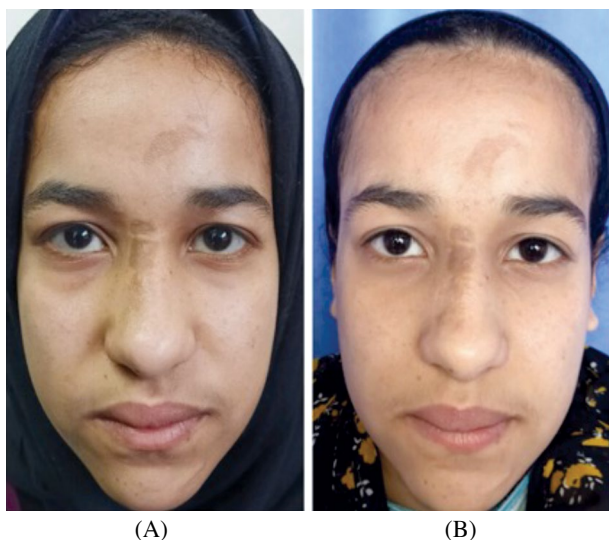


Fig. (6): A case of PRP injection: (A): Preoperative and (B): Postoperative 3 months after injection.

Discussion

Living with scars, particularly on the face, may be even more challenging today. Academics and professionals are concerned about the shifting ideas of what is normal in terms of appearance and the rising standards of beauty. Unsurprisingly, persons with a noticeable difference may find it difficult to live in a society that emphasizes beauty [7].

A total of 60 burn sufferers with post-burn facial scars were included in the current study. These cases were assigned at random into 2 equal groups: the PRP group (n=30) and the fat injection group (n=30). This study compared the effectiveness of platelet-rich plasma & fat injection in treating facial scars following burns. The chief findings in this study were; (1) No significant differences between both groups as regard baseline characteristics, (2) During follow-up, fat injection group had significantly lower (3.67 ± 1.83 vs. 3.87 ± 1.33 ; $p < 0.001$) Vancouver score improving vascularity, pigmentation, pliability, and decreasing height, (3) fat injection group had significantly higher epidermal thickness during follow-up (362.20 ± 92.73 vs. 255.40 ± 90.00 (μm); $p < 0.001$), finally, both techniques were safe and only two (6.7%) cases of the PRP group & four (13.3%) cases of the fat injection group developed conservatively relieved edema. Similar findings were obtained by previous studies [8,9].

Results (itching, pigmentation, and pliability) were also better with PRP in a trial of 38 patients with mature scars after burns who were treated with intralesional PRP injection [10]. However, the results of our study are at odds with those of Ruiz et al., who reported significantly better outcomes in vascularity, pliability, discomfort, color, and irregularity, especially after 180 days of treatment [11].

Higher platelet concentrations are known to be produced by increasing rotational force; however, excessive forces may cause growth factors to be lost in the supernatant plasma due to early platelet activation and tube rupture, which would reduce the therapeutic effectiveness of PRP. Since the platelet concentrations obtained vary greatly between the experiments, the reported unsatisfactory findings may, in general, be attributed to the quality of the material used [12,13].

The fat injection has many advantages and few disadvantages when used to repair face scars. The skin's texture is improved after autologous fat grafting, and it can now be stretched further without tearing. Flexibility is improved, notably in the joints, eyes, nasal valve, and mouth; symmetry is improved, so that the patient may feel some recovery of facial mimicry [14].

One of the main results in the present study was that fat injection group had significantly higher epidermal thickness during follow-up (362.20 ± 92.73 vs. 255.40 ± 90.00 (μm); $p < 0.001$). Regarding potential issues with each approach, problems from fat injection are minimal and infrequent. Infections (cellulitis), protracted swelling, intravascular injections, fat necrosis, ecchymosis, irregular or asymmetries in the contours, and over grafting are the most frequent. The percentages reported in the scientific literature for volume retention following grafting vary greatly. Because to the anticipated resorption rate, a 20% to 30% overcorrection should be advised [3,15].

Hasiba-Pappas et al., stated that PRP has few side effects observed. In our study, PRP develops mild edema spontaneously resolved [16]. Three reported studies noticed isolated hematoma formation [17-19]. Another study found that a case of wrist ganglion in palm resolved spontaneously in one patient [20]. Lightheadedness or mild discomfort during the injection was the most prevalent negative reaction to PRP injections in the face and scalp, however both symptoms went away soon after the operation was through [18,21-23].

The current study acknowledges some limitations included relatively small sample size, being conducted in single center, enrolled only those with post-burn facial scar and lastly no long-term assessment of those patients. Any yet, the main points of strength were nature of study (clinical trial), performing of randomization and considered the first study that discussed such issue.

In conclusion, autologous fat injection was effective and safe technique in improving the outcome of post-burn facial scar as evaluated by Vancouver score and histologically by epidermal thickness. Both techniques have no significant dif-

ference as regard outcome and complications. Also, it's recommended to perform such studies on large number of patients in multiple centers with longer duration of follow-up to confirm such findings.

References

- 1- Chamata E.S., Bartlett E.L., Weir D. and Rohrich R.J.: Platelet-rich plasma: Evolving role in plastic surgery. *Plastic and Reconstructive Surgery*, 147: 219-230, 2021.
- 2- García-Sánchez J.M., Mirabet Lis V., Ruiz-Valls A., Pérez-Plaza A., Sepúlveda Sanchis P. and Pérez-del-Caz M.D.: Platelet rich plasma and plasma rich in growth factors for split-thickness skin graft donor site treatment in the burn patient setting: A randomized clinical trial. *Burns*, 48: 1662-1670, 2022.
- 3- Klinger M., Klinger F., Caviggioli F., Maione L., Catania B., Veronesi A., Giannasi S., et al.: Fat grafting for treatment of facial scars. *Clinics in Plastic Surgery*, 47: 131-138, 2020.
- 4- Egan K.P., Brennan T.A. and Pignolo R.J.: Bone histomorphometry using free and commonly available software. *Histopathology*, 61: 1168-1173, 2012.
- 5- van den Broek L.J., Niessen F.B., Scheper R.J. and Gibbs S.: Development, validation and testing of a human tissue engineered hypertrophic scar model. *ALTEX-Alternatives to animal experimentation*, 29: 389-402, 2012.
- 6- Jain V., Gupta J., Gupta N. and Jain P.: Alteration in gene expression of transforming growth factor- β following treatment of hypertrophic burn scars with three different therapeutic modalities. *International Journal of Medical and Biomedical Studies*, 3, 2019.
- 7- Van Loey N.E.E.: Psychological Impact of Living with Scars Following Burn Injury. In: Téot L., Mustoe T.A., Middelkoop E., Gauglitz G.G., eds. *Textbook on Scar Management: State of the Art Management and Emerging Technologies*. Cham: Springer International Publishing, 429-434, 2020.
- 8- El-Sayed Shalaby M., Mahmoud Attia Ibrahim S. and Nasser Abdulhay Hassanin M.: Nano fat combined with platelet rich plasma injection versus nano fat injection alone in the treatment of atrophic scar. *Al-Azhar Medical Journal*, 49: 611-620, 2020.
- 9- Gentile P., Di Pasquali C., Bocchini I., Floris M., Eleonora T., Fiaschetti V., Floris R., et al.: Breast reconstruction with autologous fat graft mixed with platelet-rich plasma. *Surgical innovation*, 20: 370-376, 2013.
- 10- Elsayed M., Moaty M.A., Moghazy A. and Eldeen O.S.: Evaluation of the effect of platelet-rich plasma on post-burn scars. *OAJ*, 5: 8-9, 2017.
- 11- Ruiz A., Cuestas D., Garcia P., Quintero J., Forero Y., Galvis I. and Velasquez O.: Early intervention in scar management and cutaneous burns with autologous platelet-rich plasma. *Journal of Cosmetic Dermatology*, 17: 1194-1199, 2018.
- 12- Vendramin F., Franco D. and Franco T.: Methods to obtain autologous platelet-rich plasma gel. *Revista Brasileira de Cirurgia Plástica*, 24: 212-218, 2001.
- 13- Pietrzak W.S. and Eppley B.L.: Platelet rich plasma: Biology and new technology. *Journal of Craniofacial Surgery* 2005;16:1043-1054.
- 14- Gheisari M., Ahmadzadeh A., Nobari N., Iranmanesh B. and Mozafari N.: Autologous fat grafting in the treatment of facial scleroderma. *Dermatology Research and Practice*, 2018.
- 15- Caviggioli F., Forcellini D., Vinci V., Cornegliani G., Klinger F. and Klinger M.: Employment of needles: A different technique for fat placement. *Plastic and Reconstructive Surgery*, 130: 373e-374e, 2012.
- 16- Hasiba-Pappas S.K., Tuca A.C., Luze H., Nischwitz S.P., Zrim R., Geißler J.C., Lumenta D.B., et al.: Platelet-rich plasma in plastic surgery: A systematic review. *Transfusion Medicine and Hemotherapy*, 49: 129-142, 2022.
- 17- Harper J.G., Elliott L.F. and Bergey P.: The use of autologous platelet-leukocyte-enriched plasma to minimize drain burden and prevent seroma formation in latissimus dorsi breast reconstruction. *Annals of Plastic Surgery*, 68: 429-431, 2012.
- 18- Davis A. and Augenstein A.: Amniotic allograft implantation for midface aging correction: A retrospective comparative study with platelet-rich plasma. *Aesthetic Plastic Surgery*, 43: 1345-1352, 2019.
- 19- Marck R.E., Gardien K.L., Stekelenburg C.M., Vehmeijer M., Baas D., Tuinebreijer W.E., Breederveld R.S., et al.: The application of platelet-rich plasma in the treatment of deep dermal burns: A randomized, double-blind, intra-patient controlled study. *Wound Repair and Regeneration*, 24: 712-720, 2016.
- 20- Loibl M., Lang S., Dendl L.-M., Nerlich M., Angele P., Gehmert S. and Huber M.: Leukocyte-reduced platelet-rich plasma treatment of basal thumb arthritis: A pilot study. *BioMed Research International*, 2016.
- 21- Kumar V., Sharma N., Mishra B., Upadhyaya D. and Singh A.K.: To study the effect of activated platelet-rich plasma in cases of androgenetic alopecia. *Turkish Journal of Plastic Surgery*, 29: 28, 2021.
- 22- Kapoor R., Shome D., Vadera S. and Ram M.S.: QR 678 & QR678 Neo vs PRP A randomised, comparative, prospective study. *Journal of Cosmetic Dermatology*, 19: 2877-2885, 2020.
- 23- Takikawa M., Nakamura S., Nakamura S., Ishirara M., Kishimoto S., Sasaki K., Yanagibayashi S., et al.: Enhanced effect of platelet-rich plasma containing a new carrier on hair growth. *Dermatologic Surgery*, 37: 1721-1729, 2011.