

## Original Article

# Performance of Universal Adhesives Containing M-TEG-P and 10-MDP Monomers Restoring Non-Carious Cervical Lesions in Geriatric Patients: A One-year Randomized Clinical Trial

Hend Taha Hanafi Mahmoud<sup>1</sup>, Ahmed El-Hoshy<sup>1</sup>, Dina Kamal<sup>1\*</sup>

<sup>1</sup>Conservative Dentistry Department, Faculty of Dentistry, Cairo University, Cairo, Egypt

E-mail: dina.kamal@dentistry.cu.edu.eg

Submitted: 17-11-2023

Accepted: 08-12-2023

## Abstract

**Aim:** The aim of this study was to assess the performance of moisture resistant, M-TEG-P containing universal adhesive (TMR-Aquabond0, YAMAKIN CO., Japan) in comparison to 10-MDP containing universal adhesive (Single Bond Universal Adhesive, 3M ESPE, USA) in geriatric patients with NCCLs. **Materials and methods:** 28 participants were enrolled in this study. NCCLs were restored using nano hybrid universal resin composites preceded with either Aquabond0 or Single bond universal adhesive. Restorations were assessed using the World Dental Federation (FDI) criteria at baseline (1 week), 6 and 12 months, measuring fractures and retention, marginal adaptation, marginal staining, post-operative sensitivity, and secondary caries. Categorical data was described as frequency and percentage, intergroup comparisons between interventions were performed using Chi-Squared test with statistical significance level set at ( $P \leq 0.05$ ), survival rate was analyzed using Kaplan-meier and Log-rank test. **Results:** No statistically significant difference between the two groups was found for all outcomes  $p > 0.05$ . However, a statistically significant difference was found regarding survival analysis ( $p = 0.034$ ) where 10-MDP containing adhesive showed higher survival rate than M-TEG-P phosphate containing universal adhesive. **Conclusion:** Both universal adhesives revealed acceptable performance after 12 months of clinical service in NCCLs in geriatric patients. However, it should be noted that (Single Bond Universal, 3M ESPE, USA) showed a better survival rate.

**Keywords:** M-TEG-P, 10-MDP, Universal adhesives, Adhesive dentistry, Non-carious cervical lesions

## I. INTRODUCTION

Dental adhesives and resin composites are without a doubt the first choice for restoring tooth tissues defects for their excellent esthetic and mechanical properties. Despite the great advances in dental adhesives, the dentin-resin interface is still the weakest zone in a resin composite restoration due several factors as dentin bond degradation,

nano-leakage and gap formation which might result in secondary caries around the tooth-restoration margins. Therefore, improving the bond durability is fundamental for increasing restoration longevity. Therefore, there was an increased demand for simplified adhesive systems with improved bonding performance which led to the development

of universal adhesives *Wawrzynkiewicz et al., (2020)*.

When an adhesive is applied to the treated dentin, it is thought that osmotic pressure causes the interstitial fluid to leak from the dentinal tubule to the interface. It is very difficult to prevent moisture from penetrating into this adhesive, and there are many uncertainties as to how much moisture permeates an area of the cavity and to what extent it becomes a hindrance to adhesion *Sakamoto et al., (2016)*. Also, there are so many factors inherent to dentin, as humidity, caries-affected tissue, and the lack of retention due to extensive tooth loss that might contribute to adhesive-interface degradation. In addition, oral factors as pH fluctuations and thermo-mechanical stresses may reduce restoration longevity *Santis et al., (2017)*.

Tooth wear is a universal physiological phenomenon, with slow irreversible progression. It is usually associated with aging and parafunctional habits. Their prevalence worldwide is 46.7% higher in geriatric patients *Santis et al., (2017)*. Non-carious cervical lesions (NCCLs) are ideal to assess the performance of adhesives. These lesions generally do not provide any macro-retention. Therefore, improper bonding will cause restoration loss. Loss of retention is the key for evaluating the performance of adhesives in NCCLs based clinical trials *Peumans et al., (2020)*.

Geriatrics implies medical support for elder adults, an age group difficult to define accurately. Despite there is no specific age to classify, patients older than 65 years are often described as geriatric patients. Also, from a chronological point of view, medical treatment of the elderly (geriatrics) begins from the age of 65 years old *Stefanacci R.G., (2022)*.

A greater percentage of failures was observed in restorations placed in the cervical region compared to occlusal and anterior restorations, and the longevity of the restorations was unsatisfactory. Factors that lead to unsuccessful non-carious cervical lesion (NCCL) restorations is the differences of the tooth substrate that are being faced, including occluded dentinal tubules constituting the sclerotic formation, the presence of bacteria on the lesion surface and acid-resistant hyper-mineralized layers. All this serves as a barrier to the diffusion of primer and resin

infiltration in a manner similar to the smear layer of intact dentin. As such, there is a need for new techniques and improvements in dental adhesion to prolong the clinical longevity of restored cervical lesions *Akarsu et al., (2020)*. Despite the outstanding clinical performance of many universal adhesives in dentin bonding and restorations durability in NCCLs, "Simplifying the method of adhesion" includes reducing or shortening the steps required for adhesion; for example, the wait time (decalcifying time) until the surface is etched after application of the adhesive to the tooth substance, or shortening the time required for visible light activation (light activation time) in the subsequent curing is highly needed in modern dentistry *Washino et al.,(2016)*. Therefore, to improve bonding to dentin a novel adhesive containing M-TEG-P® phosphate monomer was introduced. This monomer succeeded in developing an adhesive whose components will not exhibit phase separation during the solvent volatilization that occur after application, and whose adhesion will not be susceptible to influence by the amount of moisture mixed into the adhesive layer *Yamakin et al., (2016)*. The M-TEG-P universal adhesive (TMR-Aquabond0, YAMAKIN CO., Japan) has shorter decalcifying time which enables the next step of the process to be performed, solvent removal by air-blow immediately after adhesive application on the tooth surface. It also has shorter light activation time as long as the LED lamp has a light amount of 1000mW/cm<sup>2</sup> or more, AQUA-BOND can be cured and adhere well with good reproducibility with activation of ten seconds or more without any particular additional requirements. Furthermore, in the case of LED lamps with a light amount of 2400mW/cm<sup>2</sup> or more, adhesion by activation for three seconds or longer can be reliably achieved *Washino et al., (2016)*. This recently introduced universal adhesive also exhibits chemical adhesion to dentin, showing hydrolytic bond stability when compared to other functional monomers *Ranjitha et al. (2020)*

Due to the limited available clinical data, this clinical trial was designed to assess the performance of two universal adhesives, 10-MDP-containing universal adhesive (Single Bond Universal, 3M ESPE, USA) and M-TEG-P containing universal adhesive (TMR-Aquabond0, YAMAKIN CO., Japan) placed in NCCLs for

geriatric patients over 12 months. The null hypothesis was that the two adhesives would behave equally in regard to fractures and retention,

marginal adaptation, marginal discoloration, secondary caries and post-operative sensitivity.

## II. MATERIALS AND METHODS

### A. Materials

The materials used are summarized in table (1) with their composition, lot number and manufacturer.

**Table (1): Materials' composition, lot number and manufacturer**

Materials	Composition	Lot Number	Manufacturer
<b>Single Bond Universal Adhesive</b>	MDP Phosphate Monomer, Dimethacrylate resins, HEMA, Vitrebond Copolymer, Filler, ethanol, water, initiators, silane	10420A	3M ESPE, 2510 Conway Avenue St. Paul, MN 55144-1000 USA Phone 1-800-634-2249 <a href="https://www.3M.com/dental">https://www.3M.com/dental</a>
<b>Etch-Rite™</b>	38% Phosphoric acid, Water, Synthetic amorphous silica, Polyethylene glycol	160728	PULPDENT Corporation 80 Oakland Street Watertown, MA 02472 USA <a href="https://www.pulpdent.com">https://www.pulpdent.com</a>
<b>Filtek™ Z250 XT</b>	Fillers: Nanohybrid silica/zirconia (82% by weight) Matrix: BIS-GMA, UDMA, BIS-EMA, PEGDMA and TEGDMA (18% by weight)	NC99452	3M ESPE, 2510 Conway Avenue St. Paul, MN 55144-1000 USA Phone 1-800-634-2249 <a href="https://www.3M.com/dental">https://www.3M.com/dental</a>
<b>TMR-AQUA BOND 0</b>	M-TEG-P phosphate monomer, distilled water, methacrylate monomer, carboxylic monomer, photopolymerization initiator, ethanol, thickener	01062024	YAMAKIN CO., LTD. 1090-3 Otani, Kamibun, Kagamicho, Konan-shi, Kochi, 781-5451 Japan <a href="https://www.yamakin-global.com">https://www.yamakin-global.com</a>
<b>TMR Z FILL 10</b>	methacrylate monomer, inorganic fillers (silica, alumina, and zirconia: average particle diameter < 20µm), pigments, Inorganic filler content rate Approximately 55 vol%	01042126	YAMAKIN CO., LTD. 1090-3 Otani, Kamibun, Kagamicho, Konan-shi, Kochi, 781-5451 Japan <a href="https://www.yamakin-global.com">https://www.yamakin-global.com</a>

HEMA: 2 hydroxyethyl methacrylates, MDP: Methacryloxydecyl dihydrogen phosphate, PENTA: dipentaerythritol pentacrylate phosphate, BIS-GMA: Bisphenol A-glycidyl methacrylate, UDMA: Urethane dimethacrylate, , BIS-EMA: Bisphenol A Ethoxylated Dimethacrylate, PEGDMA: Polyethylene Glycol Dimethacrylate, TEGDMA: Triethylene Glycol Dimethacrylate, M-TEG-P: 10-methacryloyloxy tetraethylene glycol dihydrogenphosphate

### B. Methods

#### • Trial Registration and Ethical Approval

Trial was registered in (clinicaltrials.gov), with registration number: NCT05029479. Prior to the start of the study, approval by the Research Ethics Committee (REC), Faculty of Dentistry, Cairo University was obtained with identification number: 101021

#### • Study Setting and Design

This study took place in clinics of Faculty of Dentistry Cairo University. This is a randomized trial with two parallel arms, 1:1 allocation ratio, trial framework is equivalence frame. Participants were randomly assigned to each group (n= 14). The FDI criteria was adopted to evaluate the tested materials as baseline, 6 months, and 12 months.

#### • Sample Size Calculation

According to *Haak et al., (2019)* in which the probability of score 1 for fracture and retention of restorations performed using light cured universal adhesive was (0.99), probability of score 5 was (0.01) with effect size  $w=0.98$  ( $n=9$ ). If the estimated probability of score 1 for fracture and retention of restorations performed using M-TEG-P phosphate-based universal adhesive was (0.9), probability of score 5 was (0.1) with effect size  $w=0.8$  ( $n=13$ ). With an alpha ( $\alpha$ ) level of 0.05 (5%) and power=80%, the estimated sample size was 22 cases. Sample size was raised by (20%) to compensate for dropouts through follow-ups to a total of (28) cases; (14) per group. Sample size calculation was performed using G\*Power 3.1.9.2 using chi square test.

- **Eligibility Criteria**

**Table (2): Inclusion and exclusion criteria of participants**

Inclusion Criteria	Exclusion Criteria
<ul style="list-style-type: none"> <li>- Geriatric patients of age <math>\geq</math> 65 years</li> <li>- Patients committed to the whole study period</li> <li>- Males and Females</li> <li>- Patients complaining from compromised esthetics or sensitivity</li> </ul>	<ul style="list-style-type: none"> <li>- Patients below 65 years old</li> <li>- History of allergy to any of the materials used</li> <li>- Infectious diseases</li> <li>- Inadequate oral hygiene</li> <li>- Severe Bruxism with more than 50% wear</li> <li>- Severe dysgnathia/traumatic occlusion</li> </ul>

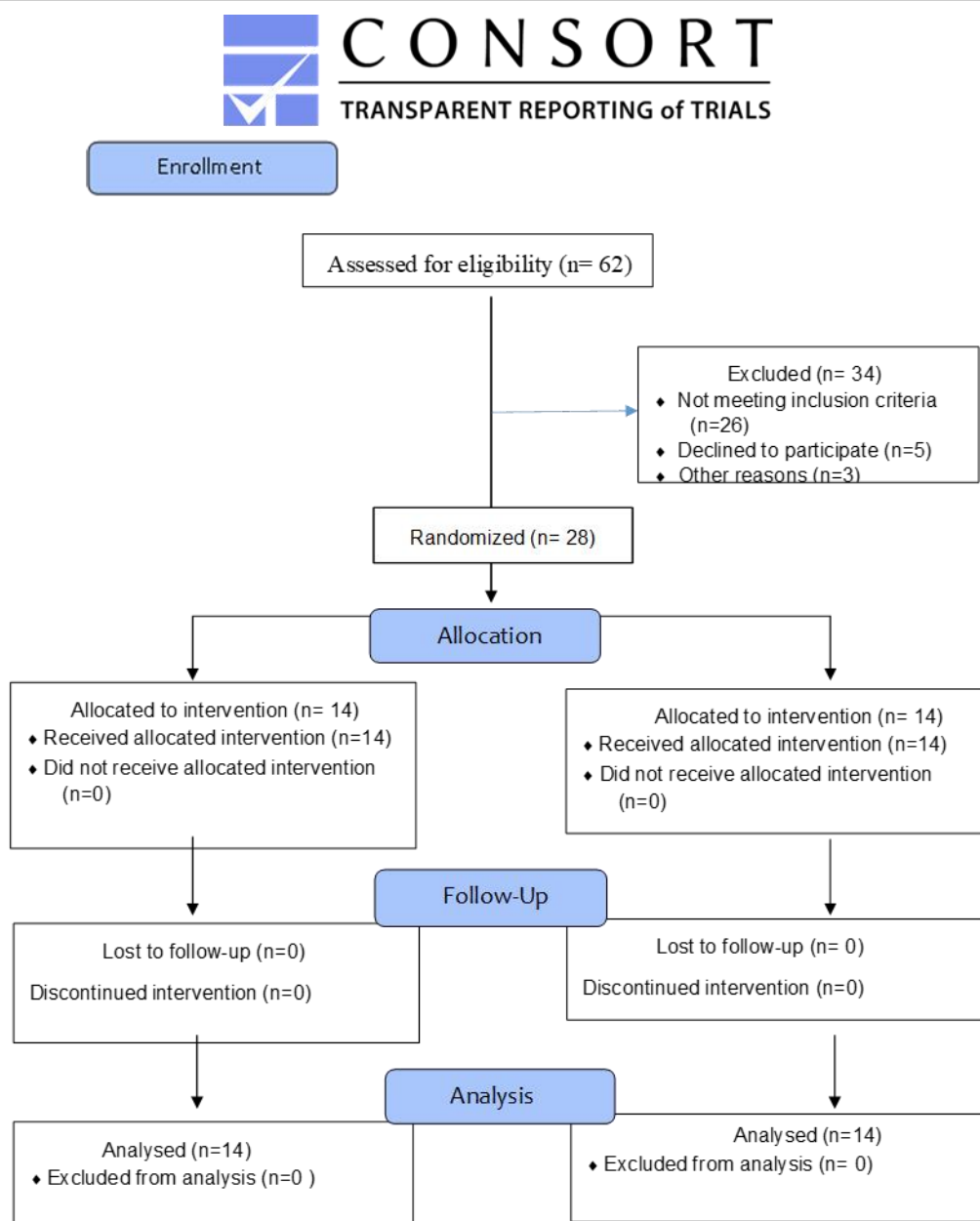
**Table (3): Inclusion and exclusion criteria of teeth**

Inclusion Criteria	Exclusion Criteria
<ul style="list-style-type: none"> <li>- Non-carious cervical lesions score 2 and 3 according to DAW classification for NCCLs (<i>Loomba et al.,2014</i>)</li> <li>- Anterior and posterior teeth</li> <li>- Absence of periapical alterations</li> </ul>	<ul style="list-style-type: none"> <li>- Non-vital teeth or teeth with pulp affection</li> <li>- Severe periodontal diseases</li> <li>- Active caries lesions</li> <li>- Teeth with Grade 3 mobility</li> <li>- Teeth with exposed pulp</li> </ul>

- **Recruitment**

Patients were recruited from the clinic of Conservative Dentistry Department, Faculty of Dentistry Cairo University, where there was a continuous and high patient flow from which

eligible patients could be selected to fulfill the eligibility criteria one month before intervention. Patients were recruited by convenient consecutive sampling until reaching the target sample size. (**Figure 1**)



**Figure (1):** CONSORT flow diagram

- **Sequence Generation and Allocation Concealment**

Simple randomization was performed by generating numbers from 1:28 using Random Sequence Generator and Integrity Services Ltd (<https://www.random.org/>) either intervention or comparator group. Each generated random number from 1-14 represents the intervention and from 15-28 is the comparator. The numbers were secured in sealed and obscured envelopes, organized by a contributor who did not participate in any other clinical trial phase.

- **Masking/blinding**

This is a triple blinded study where the volunteers/patients and the assessors were blinded, as well as the statistician. The operator was not blinded due to different application protocol of the restorative materials.

- **Clinical Procedures**

**Field Preparation**

Local anesthesia was administered to the patients (ARTINIBSA 40 mg/ml + 0,01mg/ml, Inibsa, Spain). Shade selection was done under appropriate conditions. Cavities to be restored were isolated with rubber dam (Nic Tone, Expertech

Solutions, Bucharest, Romania) to ensure moisture control of the operative field and lack of contamination of the cavities. Subgingival clamps were used for stabilization and impervious isolation of the teeth (TOR VM Dental Manufacturing Company, Russia).

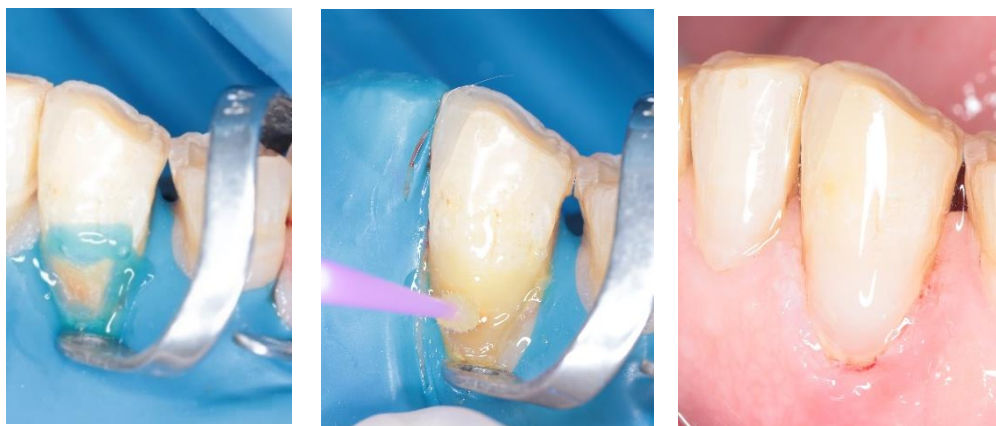### Cavity Preparation Steps

Round bur in a high-speed hand piece (NSK high speed hand-piece Pana Air FX PAF-SU-M4, Japan) with air/water coolant were used to prepare class V cavity preparations (according to lesion depth and width) and a yellow-coded abrasive diamond used to prepare the incisal bevel. Any tooth suffered from pulpal exposure was excluded from the study.

### Intervention group Application “M-TEG-P phosphate monomer based universal adhesive” (TMR-Aquabond0, YAMAKIN CO., Japan):

Materials were placed upon manufacturer instructions as follows: selective enamel etching was performed where 38% phosphoric acid etching

gel (Pulpdent, Etch-Rite, USA) was applied on all enamel margins for 15 seconds. Rinsing followed by gentle air dryness was performed to remove excess moisture without desiccating the dentin. M-TEG-P universal adhesive (TMR-Aquabond0, YAMAKIN CO., Japan) was placed on a dispensing dish and then applied to the cavity surfaces with a brush. Air-blowing was performed to spread the adhesive into a thinner layer. Afterwards, the adhesive was cured with a light curing unit for ten seconds using LED light intensity 1200 mW/cm<sup>2</sup> (Woodpecker i-LED, Woodpecker Co., Ltd, Guilin, Guangxi, China). Universal nanocomposite (TMR-Z Fill 10, YAMAKIN CO., Japan) restorative material was placed into the prepared cavity in 2mm thick increments and light cured for 20 seconds. After light curing, shape correction was done with fine and extra-fine diamond abrasives, followed by sequential discs for further restoration finishing and polishing (**Figure 2**).

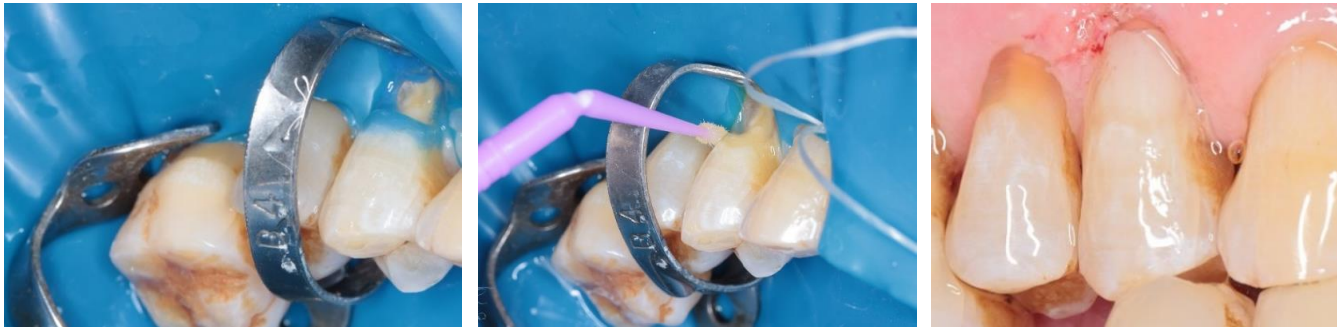

**Figure (2):** Selective enamel etching, adhesive and resin composite application of intervention group

### Comparator group application “10-MDP containing universal adhesive” (Single Bond Universal Adhesive, 3M ESPE, USA):

Materials were placed upon manufacturer instructions as follows: selective enamel etching was performed where 38% phosphoric acid etching gel (Pulpdent, Etch Rite, USA) was applied on all enamel margins for 15 seconds. Rinsing followed by gentle air dryness was performed to remove excess moisture without desiccating the dentin. 10-MDP universal adhesive (Single Bond Universal, 3M ESPE, USA) was placed on a dispensing dish and then applied to the cavity surfaces with a brush

with active rubbing for 20 seconds. The adhesive was gently air dried for five seconds to evaporate the solvent. Afterwards, the adhesive was cured with a light curing unit for ten seconds using LED light intensity 1200 mW/cm<sup>2</sup> (Woodpecker i-LED, Woodpecker Co., Ltd, Guilin, Guangxi, China). Nanohybrid composite (3M™ ESPE™ Filtek™ Z250XT, USA) was placed into the prepared cavity in 2mm thick increments and light cured for 20 seconds. Afterwards, shape correction was done with fine and extra-fine diamond abrasives, followed using sequential discs for further restoration finishing and polishing (**Figure 3**).



**Figure (3):** Selective enamel etching, adhesive and resin composite application of control group

• **Outcomes**

The restorations were assessed using the World Dental Federation (FDI) criteria at baseline

(1 week after placement), 6 and 12 months, measuring fractures and retention, marginal adaptation, marginal staining, post-operative sensitivity and secondary caries (**Figure 4**).

	<u>Esthetic Property</u>	<u>Functional Properties</u>		<u>Biological Properties</u>	
	<b>1. Staining Margin</b>	<b>2. Fractures and Retention</b>	<b>3. Marginal Adaptation</b>	<b>4. Postoperative Sensitivity</b>	<b>5. Secondary Caries</b>
1. Clinically very good	1.1. No marginal staining	2.1. Restoration retained, no fractures/cracks	3.1. Harmonious outline, no gaps, no discoloration	4.1. No hypersensitivity	5.1. No secondary or primary caries
2. Clinically good (after correction very good)	1.2. Minor marginal staining, easily removable by polishing	2.2. Small hairline crack	3.2.1. Marginal gap (50 µm) 3.2.2 Small marginal fracture removable by polishing	4.2. Low hypersensitivity for a limited period of time	5.2. Very small and localized demineralization. No operative treatment required
3. Clinically sufficient/satisfactory (minor shortcomings with no adverse effects but not adjustable without damage to the tooth)	1.3. Moderate marginal staining, not esthetically unacceptable	2.3. Two or more or larger hairline cracks and/or chipping (not affecting the marginal integrity)	3.3.1. Gap <150 µm not removable 3.3.2. Several small enamel or dentin fractures	4.3.1. Premature/ slightly more intense 4.3.2. Delayed/ weak sensitivity; no subjective complaints, no treatment needed..	5.3. Larger areas of demineralization, but only preventive measures necessary (dentine not exposed)
4. Clinically unsatisfactory (repair for prophylactic reasons)	1.4. Pronounced marginal staining; major intervention necessary for improvement	2.4. Chipping fractures that damage marginal quality; bulk fractures with or without partial loss (less than half of the restoration)	3.4.1. Gap >250 µm or dentine/base exposed 3.4.2. Chip fracture damaging margins 3.4.3. Notable enamel or dentine wall fracture	4.4.1. Premature/ very intense 4.4.2. Extremely delayed/weak with subjective complaints 4.4.3. Negative sensitivity; intervention necessary but not replacement	5.4. Caries with cavitation (localized and accessible and can be repaired)
5. Clinically poor (replacement necessary)	1.5. Deep marginal staining not accessible for intervention	2.5. (Partial or complete) loss of restoration	3.5. Filling is loose but <i>in situ</i>	4.5. Very intense, acute pulpitis or nonvital Endodontic treatment is necessary and restoration has to be replaced	5.5. Deep secondary caries or exposed dentine that is not accessible for repair of restoration
Acceptable or not acceptable (n, %, and reasons)	Esthetic criteria	Functional criteria		Biological criteria	

**Figure (4):** FDI criteria for evaluating restorations



### • Statistical Analysis

Data was analyzed using Medcalc software, version 19 for windows (MedCalc Software Ltd, Ostend, Belgium). Categorical data was described as frequency and percentage, intergroup comparisons between interventions was performed using the Chi-Squared test with statistical significance level set at ( $p \leq 0.05$ ), intragroup comparison within each intervention was performed using the Chi-Squared test with statistical significance level set at ( $p \leq 0.016$ ) after Bonferroni correction. Relative risk was used to assess the clinical significance. Survival rate was analyzed using Kaplan-meier and Log-rank test. The confidence limit was set at 95% with 80% power and all tests were two tailed.

## III. RESULTS

### 1. Demographic Data

This study was conducted on 28 participants that were randomly assigned to the two arms ( $n=14$ ). After 12 months, 28 participants completed the follow-up with a 100% retention

rate. Regarding gender, there was 16 males and 12 females in the current study, in the M-TEG-P universal adhesive group there was 4(28.6%) males and 10(71.4%) females, while in the Single bond universal group there were 12(85.7%) males and 2(14.3%) females, there was statistically significant difference between both groups regarding gender ( $P = 0.0027$ ). Mean age of the participants in the current trial was  $65.5 \pm 2$  years; mean age within M-TEG-P universal adhesive group was  $65.7 \pm 1.2$  years, while within the Single bond universal group mean age was  $65.3 \pm 2.7$  years, there was no statistically significant difference between the two groups regarding age ( $P=0.595$ ). According to teeth distribution in the dental arches, there were 7 maxillary incisors, 3 maxillary canines, 4 maxillary premolars, 1 maxillary molar, 3 mandibular incisors, 1 mandibular canine and 9 mandibular premolars in the current study, there was no statistically significant difference between both groups regarding teeth distribution ( $P = 0.0751$ ). Distribution of teeth is shown in Table (4).

**Table (4): Teeth distribution among groups**

Teeth distribution	M-TEG-P Universal Adhesive	10-MDP Universal Adhesive	Total
Maxillary incisors	4(57.1%)	3(42.9%)	7(25%)
Maxillary canines	2(66.7%)	1(33.3%)	3(10.7%)
Maxillary premolars	3(75%)	1(25%)	4(14.3%)
Maxillary molars	1(100%)	0(0%)	1(3.6%)
Mandibular incisors	2(66.7%)	1(33.3%)	3(10.7%)
Mandibular canines	0(0%)	1(100%)	1(3.6%)
Mandibular premolars	2(22.2%)	7(77.8%)	9(32.1%)
Mandibular molars	0(0%)	0(0%)	0(0%)
Total	14 (50 %)	14 (50 %)	28

### 2. Clinical Evaluation

Intergroup comparison between both adhesives revealed no statistically significant difference for all outcomes at all follow-up intervals ( $p > 0.05$ ). Intragroup comparison within M-TEG-P universal adhesive revealed no significant difference between follow-up intervals regarding fracture and retention, postoperative hypersensitivity, secondary caries ( $p > 0.05$ ), while there was statistically significant difference for marginal adaptation and marginal staining ( $p < 0.016$ ). Intragroup comparison within single bond

universal revealed statistically significant difference between follow-up periods for marginal adaptation, postoperative hypersensitivity, and marginal staining ( $p < 0.016$ ), while there was no statistically significant difference for fracture and retention, and secondary caries ( $p > 0.05$ ). Intergroup and Intragroup comparison between the two groups at different time intervals is shown in Table (5).



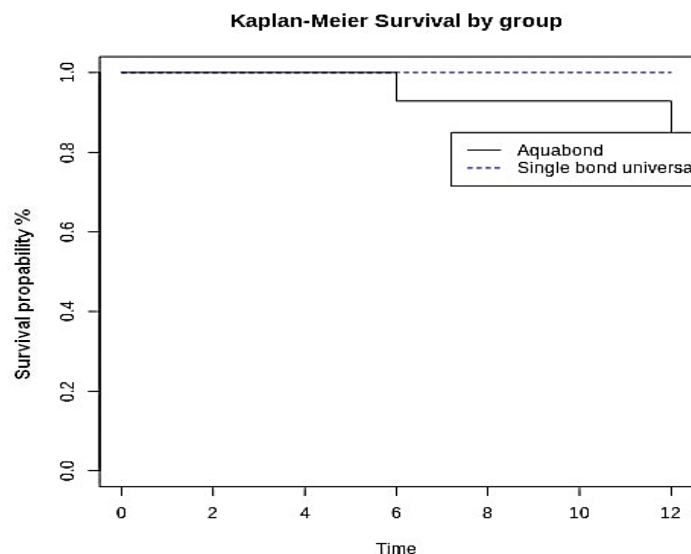
**Table (5):** Intergroup and Intragroup comparison between the two groups at different time intervals

Outcome	Follow up	M-TEG-P Universal Adhesive					10-MDP Universal Adhesive					p-value		
		N	Success		Failure		N	Success		Failure				
			1	2	3	4		5	1	2	3		4	5
Fracture and Retention	Baseline	14	14(100%)	0(0%)	0(0%)	0(0%)	0(0%)	14	14(100%)	0(0%)	0(0%)	0(0%)	0(0%)	1.0000
	6 Months	14	13(92.9%)	0(0%)	0(0%)	0(0%)	1(7.1%)	14	12(85.7%)	2(14.3%)	0(0%)	0(0%)	0(0%)	0.2187
	12 Months	14	13(92.9%)	0(0%)	0(0%)	0(0%)	1(7.1%)	14	12(85.7%)	2(14.3%)	0(0%)	0(0%)	0(0%)	0.2187
	p-value		0.3749					0.1979						
Marginal Adaptation	Baseline	14	14(100%)	0(0%)	0(0%)	0(0%)	0(0%)	14	14(100%)	0(0%)	0(0%)	0(0%)	0(0%)	1.0000
	6 Months	14	12(85.7%)	1(7.1%)	0(0%)	1(7.1%)	0(0%)	14	8(57.1%)	6(42.9%)	0(0%)	0(0%)	0(0%)	0.2921
	12 Months	14	5(35.7%)	4(28.6%)	2(14.3%)	3(21.4%)	0(0%)	14	4(28.6%)	7(50%)	3(21.4%)	0(0%)	0(0%)	0.4315
	p-value		0.0092*					0.0010*						
Postoperative Sensitivity	Baseline	14	11(78.6%)	3(21.4%)	0(0%)	0(0%)	0(0%)	14	14(100%)	0(0%)	0(0%)	0(0%)	0(0%)	0.0719
	6 Months	14	11(78.6%)	3(21.4%)	0(0%)	0(0%)	0(0%)	14	12(85.7%)	2(14.3%)	0(0%)	0(0%)	0(0%)	0.6280
	12 Months	14	8(57.1%)	5(35.7%)	1(7.1%)	0(0%)	0(0%)	14	9(64.3%)	5(35.7%)	0(0%)	0(0%)	0(0%)	0.5016
	p-value		0.5046					0.0112*						
Secondary Caries	Baseline	14	14(100%)	0(0%)	0(0%)	0(0%)	0(0%)	14	14(100%)	0(0%)	0(0%)	0(0%)	0(0%)	1.0000
	6 Months	14	14(100%)	0(0%)	0(0%)	0(0%)	0(0%)	14	14(100%)	0(0%)	0(0%)	0(0%)	0(0%)	1.0000
	12 Months	14	14(100%)	0(0%)	0(0%)	0(0%)	0(0%)	14	14(100%)	0(0%)	0(0%)	0(0%)	0(0%)	1.0000
	p-value		1.0000					1.0000						
Marginal Staining	Baseline	14	14(100%)	0(0%)	0(0%)	0(0%)	0(0%)	14	14(100%)	0(0%)	0(0%)	0(0%)	0(0%)	1.0000
	6 Months	14	8(57.1%)	5(35.7%)	1(7.1%)	0(0%)	0(0%)	14	8(57.1%)	6(42.9%)	0(0%)	0(0%)	0(0%)	0.7384
	12 Months	14	4(28.6%)	3(21.4%)	4(28.6%)	2(14.3%)	1(7.1%)	14	4(28.6%)	7(50%)	3(21.4%)	0(0%)	0(0%)	0.1489
	p-value		0.0053*					0.0010*						

### 3. Survival Analysis

Overall survival of M-TEG-P and 10-MDP universal adhesives in cervical restorations was assessed after 12 months. Four restorations failed after 12 months in M-TEG-P universal adhesive group due to scoring 4 or 5 in marginal staining,

marginal adaptation, and fracture and retention. Kaplan-meier analysis was used to obtain survival curves, comparison of survival curves was performed using Logrank test, there was statistically significant difference between both adhesives (p=0.034123). (Figure 5)



**Figure (5):** Survival analysis of M-TEG-P and 10-MDP universal adhesives after 12 months

#### IV. DISCUSSION

There are a lot of factors inherent to dentin and several external factors that contribute to failure at the interface. Consequently, clinical studies are required to assess the longevity of adhesive restorations exposed to the different oral conditions *Santis et al., (2017)*.

The gained interest in simplified and less technique sensitive adhesion resulted in developing more versatile adhesive systems, termed "universal" or "multi-mode", which are simplified adhesives implemented either in etch-and-rinse mode, self-etch mode or even after selective enamel etching protocol *Zanatta et al., (2019)*.

Enamel and dentin require different adhesive approaches due to different inherent tissue characteristics. Usually, adhesives used in dentin are self-etch due to their less aggressive acid conditioning, reducing collagen collapse liability after air dryness. On the other hand, enamel requires phosphoric acid etching to promote retention. Therefore, selective enamel etching has been implemented to restore cavities involving enamel and dentin *Zanatta et al., (2019)*. After evaluating studies of 1-5 years clinical follow up, selective enamel etching prior to universal adhesives improves the clinical performance of resin composite and reduces restoration loss *Shinohara et al., (2020)*.

The American Dental Association recommends clinical studies on non-carious cervical lesions to evaluate adhesives as they are non-retentive, and retention depends mainly on the

adhesive *Follak et al., (2021)*. NCCLs have special inherent characteristics, such as increased sclerosis, high occlusal forces stressing on the cervical tooth area, limited retentive cavity design, and margins extending to dentin, rendering them ideal to test adhesives *Ruschel et al., (2018)*.

Universal adhesives exhibit functional monomers that improve the bond strength by chemically adhering to the tooth structure. 10-methacryloyloxydecyl dihydrogen phosphate (10-MDP) is now an integral entity in dental adhesives. It has high affinity to the hydroxyapatite calcium, which is improved by the stability and low solubility of the calcium salts formed, rendering it a desired constituent in adhesives *Ruschel et al., (2018)*. The 10-Methacryloyloxydecyl dihydrogen phosphate (MDP), interacts with hydroxyapatite crystals by a dual mechanism: First, stable ionic bonding with calcium forming nano-layered MDP-Ca salts with hydroxyapatite at the interface. This nano-layering greatly improves bond durability. *Perdigão et al., (2019)*.

Hydrolytic degradation of the hybrid layer reduces dentin bond strength with eventually loss of the adhesive joint. For the resin monomer infiltration, water is mandatory to help in the expansion of the dentin collagen scaffold. Yet, excess moisture may cause phase separation among the hydrophobic and the hydrophilic monomers, which may result in improper resin infiltration, voids at the interface and reduced monomer conversion. This will consequently reduce the bond durability, increase the enzymatic degradation of

the exposed collagen, and the hydrolysis of the poorly polymerized adhesive. To overcome these shortcomings newer modifications of the adhesive have been developed. The novel and newly introduced universal adhesive used in this study is claimed to overcome the moisture involved in dental adhesion such as moisture during cavity preparation, tissue fluids that leak out of the dentinal tubules due to capillary action and osmotic pressure on the adhesive interface, gingival fluid seepage and the water that may be introduced when removing the adhesive solvent by air-blowing. In the composition of this adhesive, the added M-TEG-P monomer claimed to have succeeded in developing an adhesive whose components will not exhibit phase separation during solvent volatilization that occurs after application, and whose adhesion will not be susceptible to influence by the amount of moisture mixed into the adhesive layer. M-TEG-P amphiphilic phosphate monomer claimed to be efficient in removing the smear layer on enamel and dentin, or the calcium component as the smear plug, and forms a preferable surface for adhesion. Therefore, this novel adhesive can adhere immediately after application, and the adhesiveness gently increases with time due to controlled demineralization. So, this novel adhesive (Aquabond0, YAMAKIN CO., Japan) doesn't require time for demineralization and can be cured immediately after application *Yamakin et al., (2016)*.

The length of the spacer chain (number of carbons) is claimed to influence the ionic bond greater than its hydrophilicity. It was found that 2-MEP (shorter chain), MTEP, and CAP-P (hydrophilic spacer) resulted in significantly lower formation of monomer-calcium salts and tensile bond strength than 10-MDP and 12-MDDP. But surprisingly, MTEP and CAP-P, which are more hydrophilic monomers and contain ester and ether groups within their spacer chains, both can remain on the dentin surface after rinsing. Remarkably, the more hydrophilic functional monomer (MTEP) formed fewer but more rinse-resistant monomer-Ca salts. MTEP and CAP-P compared to 2-MEP have more stable chemical bonding which is enhanced by their high dentin wettability and due to their fairly long spacer chain, increasing the separation of methacrylate and phosphate functional groups. It is demonstrated that monomers showing weak

hydroxyapatite interaction are less likely to create high initial bond strength and durability, compared to those with superior chemical interaction *Van Landuyt et al., (2008)*. These findings are important in leading future formulations of functional monomers, which should be designed to a long and hydrophobic spacer, to realize stable chemical interaction and higher bond durability *Feitosa et al., (2013)*.

This randomized clinical study evaluated the performance of two different adhesive systems, conducted on 28 participants with non-carious cervical lesions, randomly assigned to each group (n=14). After 12 months, 28 participants fulfilled the follow-up with a 100% retention rate.

Regarding fractures and retention, there was no statistically significant difference between the two adhesives and also intragroup comparison within both groups at follow up; baseline, 6 and 12 months. This was in accordance with *Ruschel et al., (2018)* and *Zanatta et al., (2019)* who attributed that there is no significant difference between resin composite restorations placed using same 10-MDP universal adhesive as our study regarding retention rates after 12 months follow up. *Follak et al., (2021)* showed that 10-MDP universal adhesive has better clinical performance after 6 months follow up regarding retention rates. *Yoshida et al., (2012)* observed significant chemical interaction between the MDP and hydroxyapatite, forming stable nanolayering which explains the high bond stability. Our results were in disagreement with *Gonçalves et al. (2021)* who reported statistically significant difference in 10-MDP containing universal adhesive regarding retention rate after 12 months and up to 3 years follow-up. This may be attributed to applying the universal adhesive without selective enamel etching resulting in higher debonding rates.

Concerning marginal adaptation, no significant difference was found between the two adhesives within different follow up intervals; baseline, 6 and 12 months but there was statistically significant difference between different follow-up periods within M-TEG-P and 10-MDP universal adhesive groups. This is in agreement with *Follak et al., (2021)* who also encountered failure in the restoration bonded by 10-MDP adhesive regarding marginal adaptation (3 restorations) after 6 months. These results were also similar to *Gonçalves et al.*

(2021) who discovered that there was statistically difference within 10-MDP universal adhesive groups when applied with selective enamel etching after 12 months and up to 3 years follow-up period regarding marginal defects and surface texture. But, this was in disagreement with *Zanatta et al., (2019)* who reported acceptable marginal adaptation after 6, 12 and 18 months follow up, this disagreement may be attributed to the different application techniques between the studies as they applied 10-MDP universal adhesive in total-etch mode 30 seconds to enamel and 15 seconds to dentin then removed excess water using absorbent paper, to leave a moist dentin surface while in our study the adhesive was applied in selective enamel etching mode and we used compressed air to remove all excess moisture.

As for postoperative sensitivity, our study showed no statistically significant difference between both groups at follow up intervals; baseline, 6 and 12 months. Intragroup comparison within M-TEG-P universal adhesive have shown no statistically significant difference between different follow-up intervals but there was statistically significant difference within 10-MDP universal adhesive between different follow-up intervals and this may be attributed to the effective adhesion of the novel M-TEG-P universal adhesive to both enamel and dentin even when it was adhered under moist conditions so, it does not require excessive dryness to dentin substrate which may cause postoperative sensitivity. In the contrary to our results *Zanatta et al., (2019)* recorded no or very few cases of post-operative sensitivity and this may be due to different in methodologies as in both studies they applied 10-MDP universal adhesive to moist dentin with only blotting excess water unlike our study where we used compressed air to remove excess moisture and for deeper resin infiltration.

Regarding secondary caries, there was no statistically significant difference between both adhesives for different follow up intervals; baseline, 6 and 12 months. Intragroup comparison within M-TEG-P and 10-MDP universal adhesives have shown no statistically significant difference between different follow-up periods. This was also reported by *Zanatta et al., (2019)*, *Shinohara et al., (2020)*, *Gonçalves et al. (2021)* and *Follak et al., (2021)*.

As for marginal staining, our study showed no statistically significant difference between the two adhesives within different follow up intervals: baseline, 6 and 12 months. Intragroup comparison within M-TEG-P and 10-MDP universal adhesives have shown statistically significant difference between different follow-up periods. There was three times more risk for marginal staining (score 4 and 5) of M-TEG-P universal adhesive when compared to 10-MDP universal adhesive after 12 months. Our results agreed with *Zanatta et al., (2019)* who stated that there was a statistically significant difference regarding marginal staining in 10-MDP adhesive group at 6, 12 and 24 months follow up. Our findings were in disagreement with *Haak et al., (2019)* who discovered no significant increase in marginal staining in 10-MDP adhesive group applied using selective enamel etching technique after 6, 12 and 36 months, this disagreement may be attributed to the different populations included in our current study and their study as they included young age participants whose teeth may have different structure than geriatric patients included in our current study. Also, in disagreement with *Gonçalves et al., (2021)* who verified that there was no statistically significant difference regarding marginal staining in resin composite restorations applied by 10-MDP-based universal adhesive with and without selective enamel etching after 1- and 3-year follow-up. This difference in results may be because they applied a thin protective coating (Finishing Gloss, 3M ESPE St. Paul, USA) onto the restoration surface.

In reference to the survival rate, overall survival of M-TEG-P and 10-MDP universal adhesive-based resin composite restorations assessed after 12 months, 4 restorations failed after 12 months in M-TEG-P universal adhesive group due to scoring 4 or 5 in marginal staining, marginal adaptation and fracture and retention. There was a statistically significant difference between both adhesives regarding survival rate.

At the end of the current study, failure rate for M-TEG-P universal adhesive (TMR-Aquabond0, YAMAKIN CO., Japan) after 12 months clinical service was  $4/14 = 28\%$  (more than 10%) while failure rate for (Single Bond Universal, 3M ESPE, USA) was 0%. Therefore, the null hypothesis was rejected. There was no statistically

significant difference between both adhesives regarding fractures and retention, marginal adaptation, post-operative hypersensitivity, marginal discoloration and secondary caries. However, statistically significant differences were found regarding survival rate. Studies in agreement or disagreement with our results are mainly related to the 10-MDP universal adhesive (Single Bond Universal, 3M ESPE, USA), as there were no available clinical trials on our M-TEG-P monomer containing novel adhesive (TMR-Aquabond0, YAMAKIN CO., Japan) and this gives an indication to the clinical importance of our study. It's recommended that further studies on M-TEG-P monomer containing universal adhesives should be performed on different populations and with different follow up periods.

Limitations of this study that were encountered were mainly the small sample size and short follow up time, so further investigations with larger sample sizes and longer follow up periods are advocated to obtain more reliable results.

## V. CONCLUSION

Under the limitations of this study, it can be concluded that both adhesives, M-TEG-P and 10-MDP containing universal adhesives showed acceptable performance after 12 months of clinical service in non-cariou cervical lesions (NCCLs) in geriatric adults. Both adhesives showed similar results and performed equally in the present study. However, it should be noted that 10-MDP containing universal adhesive showed a higher survival rate.

## VI. RECOMMENDATIONS

1. Due to limited available research, more clinical studies comparing the performance of M-TEG-P containing universal adhesives with other universal adhesives are recommended.
2. Clinical trials assessing the performance of M-TEG-P universal adhesives in different clinical scenarios should be emphasized, using the new material in several clinical situations, different age groups, restoring carious lesions and for different follow up periods.
3. More clinical trials measuring bonding performance of M-TEG-P containing universal adhesives using different measuring tools such as

Scanning Electron Microscopy (SEM) or Quantitative Margin Analysis (QMA).

## Conflict of Interest:

The authors declare no conflict of interest.

## Funding:

This research received no funding grant from any agency in the commercial, not-for-profit or public sectors.

## Ethics:

This study was granted approval by the research ethics committee, faculty of dentistry, Cairo university with approval ID number: 10102

## VII. REFERENCES

- Akarsu S, Karademir S A, Ertas E, Atasoy S., (2020). The effect of diode laser application on restoration of non-cariou cervical lesion: Clinical follow up. *Niger J Clin Pract* 2020;23:165-71
- Feitosa, V. P., Ogliari, F. A., Van Meerbeek, B., Watson, T. F., Yoshihara, K., Ogliari, A. O., Sinhoreti, M. A., Fagundes, T. C., & Sauro, S. (2014). Can the hydrophilicity of functional monomers affect chemical interaction? *Journal of Dental Research*, 93(2), 201–206.
- Follak, A. C., Ilha, B. D., Oling, J., Savian, T., Rocha, R. de O., & Soares, F. Z. M. (2021). Clinical behavior of universal adhesives in non-cariou cervical lesions: A randomized clinical trial: Six-month follow up of two universal adhesives on NCCLs. *Journal of Dentistry*, 113(July), 103747.
- Gonçalves, D. F. M., Shinohara, M. S., Fagundes, T. C., Ramos, F. D. S. e. S., Oliveira, L. D. C., & Omoto, É. M. (2021). Three-year evaluation of different adhesion strategies in non-cariou cervical lesion restorations: A randomized clinical trial\*. *Journal of Applied Oral Science*, 29, 1–10.
- Haak, R., Hähnel, M., Schneider, H., Rosolowski, M., Park, K. J., Ziebolz, D., & Häfer, M. (2019). Clinical and OCT outcomes of a universal adhesive in a randomized clinical trial after 12 months. *Journal of Dentistry*, 90(May), 103200.
- Haak, R., Werner, M. S., Schneider, H., Häfer, M., & Schulz-Kornas, E. (2022). Clinical

- Outcomes and Quantitative Margin Analysis of a Universal Adhesive Using a Randomized Clinical Trial over Three Years. *Journal of Clinical Medicine*, 11(23).
- **Loomba K, Bains R, Bains VK, Loomba A.(2014)** Proposal for clinical classification of multifactorial noncarious cervical lesions. *Gen Dent* , 62(3):39-44. PMID: 24784513.
  - **Perdigão, J., Kose, C., Mena-Serrano, A. P., De Paula, E. A., Tay, L. Y., Reis, A., & Loguercio, A. D. (2014).** A new Universal simplified adhesive: 18-month clinical evaluation. In *Operative Dentistry* (Vol. 39, Issue 2, pp. 113–127).
  - **Ranjitha GR, Vikram R, Meena N, Vijayalakshmi L, Murthy CS., (2020).** Clinical efficacy of universal adhesives for the restoration of noncarious cervical lesions: A randomized clinical trial. *J Conserv Dent*. 2020;23(3):227-232.
  - **Ruschel, V. C., Shibata, S., Stolf, S. C., Chung, Y., Baratieri, L. N., Heymann, H. O., & Walter, R. (2018).** Eighteen-month clinical study of universal adhesives in noncarious cervical lesions. *Operative Dentistry*, 43(3), 241–249.
  - **Sakamoto T, Kimura H, Ohkawauchi K, Mizuta Y, Hayashi M,(2016).** Chemistry of Dental Adhesives. *Journal of the Adhesion Society of Japan*, 52(5): 152-165, 2016.
  - **Santis LR, Silva TM, Haddad BA, Goncalves LL, &Goncalves SE,(2017).** Influence of dentin thickness on intrapulpal temperature under simulated pulpal pressure during Nd:YAG laser irradiation. *Lasers Medical Science* 32(1)161-167
  - **Shinohara, M. S., Carvalho, P. R. M. de, Neves Marcon, L., Gonçalves, D. F. M., Ramos (2020).** Strategies in noncarious cervical lesion restorations: 1-year follow-up. *Quintessence International (Berlin, Germany: 1985)*, 51(5), 352–363.
  - **Stefanacci Richard G. (2022).** Quality of Life in Older People, MSD MANUAL, Thomas Jefferson University, Jefferson College of Population Health, Reviewed/Revised May 2022
  - **Washino T, Fukunishi K, Minami M, Ishida T. (Ed.),(2016).** Secchaku no shikumi to tsukaikonashi (The Mechanism and Handling of Adhesives). *QDT*, 41: 54-63, 2016.6)
  - **Wawrzynkiewicz A, Rozpedek-Kaminska W, Galita G, et al.,(2020).** The Cytotoxicity and Genotoxicity of Three Dental Universal Adhesives-An In Vitro Study. *Int J Mol Sci*. 2020;21(11):3950. Published 2020 May 31. doi:10.3390/ijms21113950
  - **Yamakin Ph.D. Group (Ed.),(2016).** Basic Information and product Report on Dental Bonding Material.YAMAKIN CO., LTD., 2016
  - **Zanatta, R. F., Silva, T. M., Fagundes, T. C., & Gonçalves, S. E. P. (2019).** Bonding performance of simplified adhesive systems in noncarious cervical lesions at 2-year followup: A double-blind randomized clinical trial. *Operative Dentistry*, 44(5), 476–487. <https://doi.org/10.2341/18-049>