

Recurrent Visceral Leishmaniasis in a Young Immunocompetent Patient

Rupak Chatterjee¹, Shatavisa Mukherjee^{2*}, Netai Pramanik¹

¹Department of Tropical Medicine, School of Tropical Medicine, Kolkata, West Bengal, India.

²Department of Clinical & Experimental Pharmacology, School of Tropical Medicine, Kolkata, West Bengal, India

Corresponding Author
Ms Shatavisa
Mukherjee
Department of Clinical
& Experimental
Pharmacology
School of Tropical
Medicine, Kolkata
700073
West Bengal, India
Email:
shatavisa100@gmail.com
ORCID ID: 0000-
0001-9524-1525
© 2024 The author (s).
Published by Zagazig
University. This is an
open access article
under the CC BY 4.0
license
<https://creativecommons.org/licenses/by/4.0/>
Receive
date:12/12/2023

Revise date:13/1/2024

Accept day:18/1/2024

Publish date:24/1/2024

Key words: Visceral
Leishmaniasis,
Relapse,
Immunocompetent

Leishmaniasis is a parasitic disease caused by an intracellular protozoan of genus *Leishmania* and is transmitted by the vector – sandfly. It is an endemic disease in many tropical countries like India. The clinical spectrum of Visceral Leishmaniasis (VL) varies from asymptomatic to severe forms depending on the immune status of the host. When the immune system is suppressed, there are high chances for relapses or reactivation of the disease; which is very rare in immunocompetent hosts. Here, we report a case of second time relapse of VL in a young immunocompetent male with no comorbidities, despite appropriate treatment of VL with liposomal amphotericin B. (L-Amb).

Introduction

Leishmaniasis is a globally widespread parasitic disease caused by different species of the genus *Leishmania*. The disease is transmitted by infected female phlebotomine sandfly bite. From a clinical perspective, leishmaniasis can be classified into three main forms: visceral (also known as Kala-azar), cutaneous, and mucocutaneous leishmaniasis. Visceral Leishmaniasis (VL) represents the most severe manifestation, characterized by a widespread protozoan infection affecting organs of the reticulo-endothelial system, including the liver, spleen, and bone marrow. *Leishmania donovani* is the predominant pathogen causing VL in India [1,2]. The infection is marked by two primary pathogenetic features: the intracellular replication of the

parasite within resident tissue macrophages and the host's immune-inflammatory response, which governs the disease's expression, outcome, and severity. The severity and outcome are influenced by factors such as parasite properties, strain, and various host factors, including the immune status of the host [3].

When the immune system of the body is suppressed in conditions like HIV infection, long term immunosuppressant therapy etc., there are chances for relapses of the disease. Relapse is very rare in otherwise healthy immune-competent patients and if it occurs, is mainly due to drug resistance or sub-optimal treatment [4]. In this case, we report an unusual case of multiple relapses of VL in a young immunocompetent male patient despite appropriate treatment with liposomal amphotericin B (L-Amb) as per National programme guideline.

Case Details

A 24 years old male, resident of rural district (Malda) of eastern India (state of West Bengal), developed intermittent fever – low grade with occasional high spikes with chills and rigor, fatigue, severe nausea, anorexia, abdominal pain and dragging sensation with heaviness of left side of abdomen for about one month. There was no history of headache, chest pain, cough, joint pain, lymphadenopathy, diarrhoea, arthralgia or myalgia. He took some symptomatic treatment initially with antipyretics and analgesics, and later

also received antibiotics on advice from local physician. Short term causes of fever were ruled out from local clinic though his fever did not subside. He then was admitted in the nearest state government district hospital. Here, on clinical examination, he was found to have moderate pallor with huge splenomegaly. No lymphadenopathy was observed. He was investigated and laboratory reports conferred leukopenia (total WBC-3000/mm³), normocytic-normochromic anemia (Hb-7g%), mild thrombocytopenia (platelet count around 90,000/mm³). Both liver and renal function tests were within normal limits, except for altered albumin: globulin ratio. His chest Xray and urine analysis were normal, blood culture revealed no growth. He was clinically suspected as Kala-azar. rk39 test was done, which was found to be positive. Diagnosis of VL was then confirmed by bone marrow aspiration study showing Leishmania Donovan (LD) bodies. He received injection liposomal amphotericin B 10mg/kg single dose. After which, he gradually improved, spleen size reduced, blood counts normalised and was discharged .

About 8 months later, he was admitted in the present facility with complaints of high-grade fever with chills, severe nausea, loss of appetite, weakness, and abdominal pain. Physical examination revealed pallor with mild hepatomegaly and huge splenomegaly with spleen palpable up to about 10cm below left costal margin along splenic axis. Laboratory investigations revealed pancytopenia. Chest X-ray was normal, urine and blood culture also did not confer any growth. HIV, HBsAg and anti-HCV were all found to be non-reactive. Owing to his past history of VL, and the patient presenting with fever, progressive weight loss, hepatosplenomegaly, pancytopenia with hypergammaglobulinemia from an endemic region, he was considered to be a case of relapse VL. Bone marrow aspiration study was done, splenic aspirate avoided due to risk of complications. Bone marrow study showed amastigote form of the parasite. (Figure 1) Diagnosis was confirmed. He was then given L-Amb 15mg/kg dose Intravenous single dose. He also received 2 units PRBC for his anaemia. With therapy, his clinical condition improved and patient was discharged. After 7 months, patient was again readmitted with high grade intermittent fever for two weeks, with abdominal

pain, anorexia and nausea. On examination, he had severe pallor, mild hepatomegaly with hugely enlarged spleen. Complete blood count showed haemoglobin- 3.5g%, Total WBC 1100/mm³, platelet- 60,000/mm³. He was given PRBC transfusion. Liver function test showed total bilirubin-0.7 mg/dl; albumin- 4.5g/dl, globulin – 2g/dl, SGOT-52U/L, SGPT-27U/L, ALP- 126U/L, urea and creatinine were within normal limits. Malaria was ruled out. Scrub IgM was non-reactive. Urine routine and microscopic examination revealed trace albumin, pus cell: 1-2/hpf. Urine and blood culture showed no growth. ICTC and HBsAg and anti-HCV were repeated and were again non-reactive. Whole abdomen ultrasound revealed mild enlarged liver with hugely enlarged spleen-24cm. CD4 count was done and was found to be 195cells/mm³. Bone marrow aspiration study was done, where LD body was found. (Figure 2)

Patient was then given as treatment, 15mg/kg of L-AmB in two divided doses as the body weight of patient was 50kg. On first day, 8 vials (50mg/vial) were given followed by 7 vials on 3rd day. This was followed by 14 days course of tablet Miltefosine 50mg twice daily. With the above therapy regimen, patient improved clinically, appetite was restored, spleen reduced in size. Blood counts post treatment were Hb-9.1g%, Total WBC- 2600/mm³, platelet-1.5lakhs/mm³. Patient was discharged in a hemodynamically stable and afebrile condition.

Discussion :

The prognosis of VL infection differs based on the host's immune status. Adequate treatment typically results in a complete cure, while the disease may prove fatal if left untreated [5]. Liposomal Amphotericin B have improved treatment outcomes because of shorter duration of therapy and lower toxicity compared to conventional amphotericin B [6]. Liposomal Amphotericin B exhibits concentration-dependent efficacy against Leishmania species. Higher doses lead to a more significant reduction in parasite load, and the drug remains present in the liver and spleen for an extended period after the cessation of therapy [7]. Recurrences of the disease is rare in the immunocompetent persons receiving L-AmB as it is highly effective as monotherapy [8].

In the present case, despite being immunocompetent, the patient presented with relapse VL twice. Initially he was treated with L-AmB 10mg/kg IV single dose, then first relapse was treated with 15mg/kg L-AmB. Second relapse being treated with 15mg/kg L-AmB divided in 2 doses followed by 14 days course of tablet miltefosine .

The exact cause of relapse was however unclear. The relapse may have been due to the leishmania strain itself or visceral parasite burden. Moreover, threat of drug resistance also exists which is an issue to be further analysed and needs more research .

Research Highlights

1. Recurrent visceral leishmaniasis is rare in the immunocompetent persons receiving L-AmB as it is highly effective as monotherapy.
2. The exact cause of relapse though unclear, may hint towards leishmania strain itself or visceral parasite burden.

3. Threat of drug resistance also remains as a significant concern.

Declaration of patient consent: All appropriate patient consent forms obtained .

Conflict of Interest: There are no conflicts of interest.

Funding Information: Nil

Authorship Contribution:

RC and SM - Study Conceptualization and Data Acquisition;

RC, SM, NP – Drafting the manuscript and finalization

Acknowledgement: The authors are highly grateful to the faculties of Department of Tropical Medicine, School of Tropical Medicine, Kolkata, namely Dr Kumkum Sarkar, Dr Sekhar Pal and Dr Debananda Gonjhu for their assistance and intellectual support for this case.

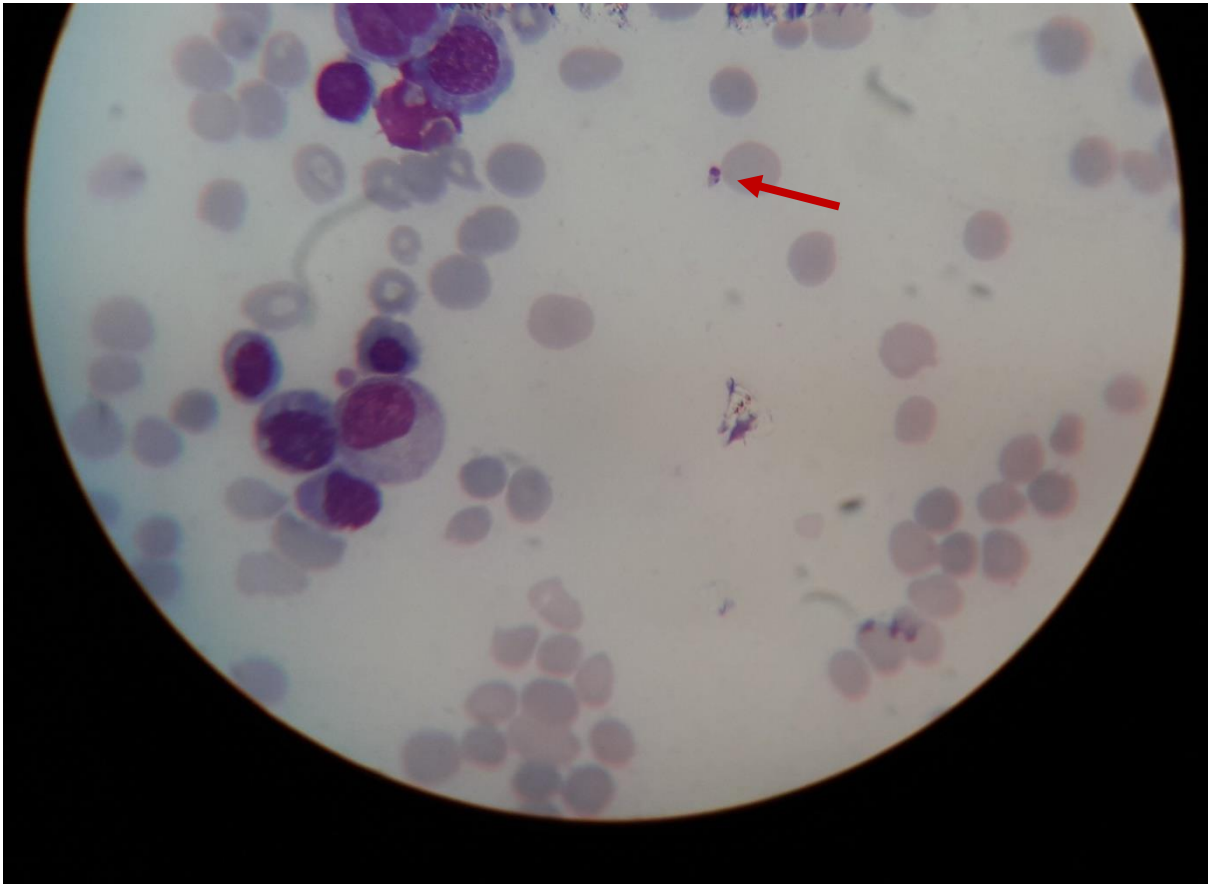


Figure 1 : Bone marrow aspirate showing *Leishmania donovani* body (LD body) shown by red arrow

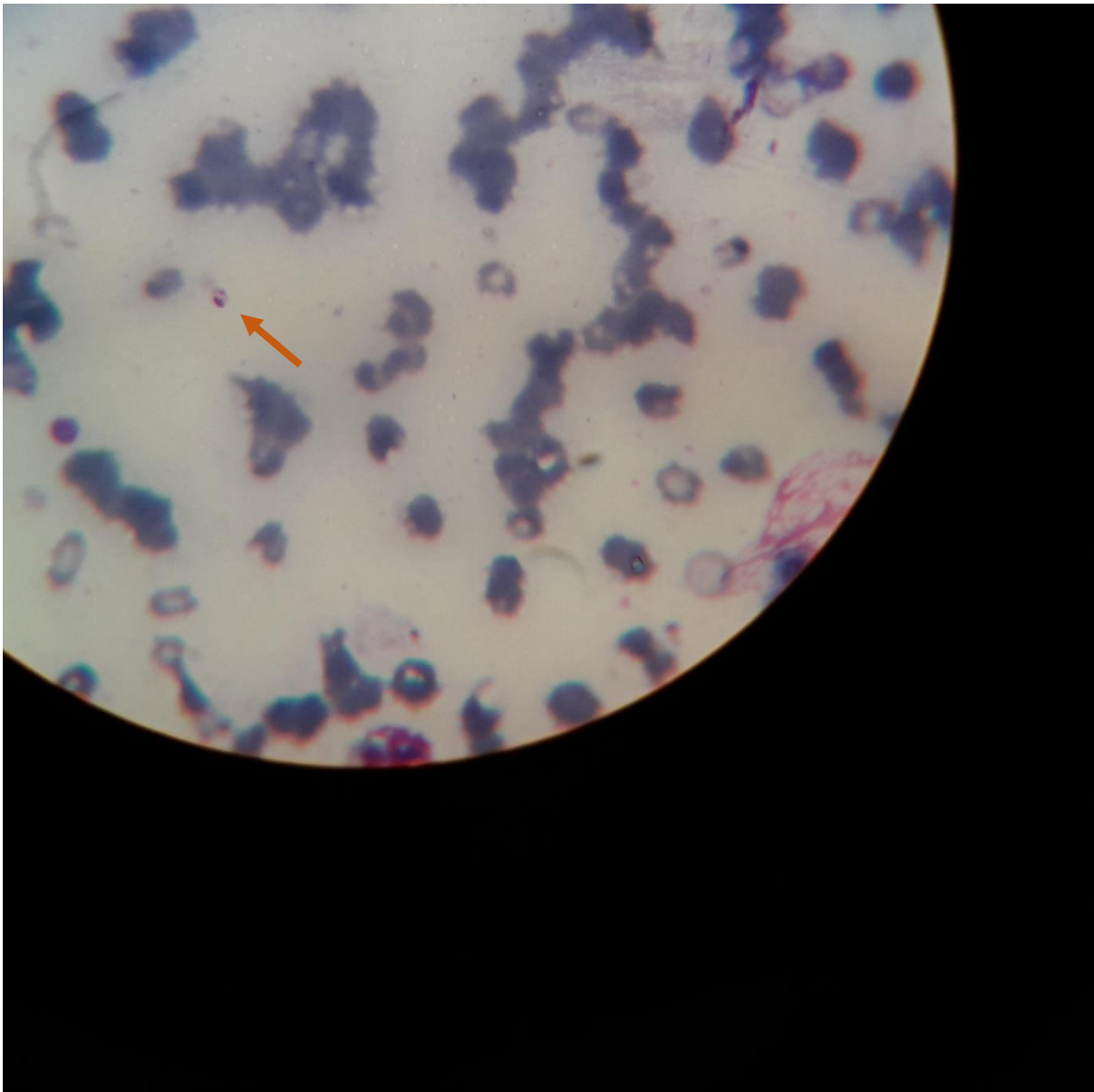

Figure 2: Bone marrow aspirate from same patient showing presence of LD body on relapse episode of fever depicted by red arrow

REFERENCES

- 1- Bañuls AL, Hide M, Prugnolle F. Leishmania and the leishmaniases: a parasite genetic update and advances in taxonomy, epidemiology and pathogenicity in humans. *Adv Parasitol.* 2007;64:1-109.
- 2- Herwaldt BL. Leishmaniasis. *Lancet.* 1999;354(9185):1191-9
- 3- Murray HW, Berman JD, Davies CR, Saravia NG. Advances in leishmaniasis. *Lancet.* 2005;366(9496):1561-77.
- 4- Desjeux P. The increase in risk factors for leishmaniasis worldwide. *Trans R Soc Trop Med Hyg.* 2001;95(3):239-243.
- 5- Prasad P, Sundar S. Multiple relapses of Visceral leishmaniasis after combination therapy in immunocompetent patient: case report. *MOJ Clin Med Case Rep.* 2016;4(3):63-64.
- 6- Goswami RP, Goswami RP, Das S, Satpati A, Rahman M. Short-Course Treatment Regimen of Indian Visceral Leishmaniasis with an Indian Liposomal Amphotericin B Preparation (Fungisome™). *Am J Trop Med Hyg.* 2016;94(1):93-8.

- 7- Bern C, Adler-Moore J, Berenguer J, Boelaert M, den Boer M, Davidson RN, et al. Liposomal amphotericin B for the treatment of visceral leishmaniasis. *Clin Infect Dis.* 2006;43(7):917-24.
- 8- Takele Y, Mulaw T, Adem E, Womersley R, Kaforou M, Franssen SU, Levin M, Taylor GP, Müller I, Cotton JA, Kropf P. Recurrent visceral leishmaniasis relapses in HIV co-infected patients are characterized by less efficient immune responses and higher parasite load. *iScience.* 2022;26(2):105867.

Site as: Chatterjee, R., Mukherjee, S., Pramanik, N. Recurrent Visceral Leishmaniasis in a Young Immunocompetent Patient. *Afro-Egyptian Journal of Infectious and Endemic Diseases*, 2024; 14(1): 121-126. doi: 10.21608/aeji.2024.252778.1340