

(Review)

## **Valsartan ameliorated cognitive decline, oxidative stress and inflammation in AlCl<sub>3</sub>-induced Alzheimer's disease in rats**

Noha M. Saeed<sup>1,\*</sup>, Manar M. Esmail<sup>1</sup>, Hanaa M. Abdelrahman<sup>2</sup> and Ali M. Elgindy<sup>1</sup>

<sup>1</sup>Pharmacology and Toxicology Department, Faculty of Pharmacy, Egyptian Russian University, Badr City, Cairo-Suez Road, 11829, Cairo, Egypt.

<sup>2</sup>Faculty of Pharmacy, Egyptian Russian University, Badr City, Cairo-Suez Road, 11829, Cairo, Egypt.

\*Corresponding author(s): Noha M. Saeed, E-mail: noha\_msaeed@eru.edu.eg,

### **ABSTRACT**

Alzheimer's disease (AD) is a chronic neurodegenerative disease that results in cognitive and memory deficits. The objective of the study was to investigate the potential neuroprotective effects of valsartan against the neurobehavioral and pathological changes that occur in rats with AD induced by aluminum chloride (AlCl<sub>3</sub>). The study involved eighteen male rats, which were divided into three groups: control, AD, and valsartan. The control group was given saline, the AD group was given AlCl<sub>3</sub> (70 mg/kg/day p.o.) for 28 days, and the valsartan group was given valsartan (30 mg/kg/day p.o.) for 28 days, one hour after the injection of AlCl<sub>3</sub>. Behavioral tests, including open field, Morris water maze, and novel object tests were conducted and brain tissues were analyzed for biochemical and histological changes at the end of the experiment. Treatment with valsartan resulted in improvements in behavioral impairments caused by AlCl<sub>3</sub>. Moreover, valsartan attenuated body weight, oxidative stress, and neuroinflammation as well as histopathological alterations induced by AlCl<sub>3</sub>. The study's findings suggest that valsartan may have potential neuroprotective effects against the development of AD induced by aluminum intoxication.

**Keywords:** Alzheimer's disease; valsartan; aluminum chloride; oxidative stress; neuroinflammation.

## 1. Introduction

Alzheimer's disease (AD) is a neurodegenerative condition that is characterized by memory loss and various cognitive impairments. It is currently ranked as the fourth leading cause of death among elderly individuals worldwide (1). According to Alzheimer's Disease International, a global umbrella organization for over 100 Alzheimer's disease organizations, around 60 million people around the world suffer from dementia, and this number is projected to reach 78 million by 2030 (2). Mortality rates from dementia have been rapidly increasing globally since the 1990s, with the death rate rising from 10.49 deaths per 100,000 to 20.98 deaths per 100,000 between 1990 and 2019 (3). AD is characterized by several pathological features, including the extracellular accumulation of aggregated  $\beta$ -amyloid ( $A\beta$ ), and intracellular aggregation of phosphorylated tau (P-tau) in parts of the brain that are important for memory, such as the hippocampus (4). Although the exact cause of the disease is still unknown, factors as, mutations of amyloid precursor protein (APP) occupational exposure to volatile anesthetics, toxic metals like aluminum, industrial chemicals, electromagnetic fields, air pollutants, and pesticides are thought to contribute to the development of AD. Additionally, medical pre-existing conditions such as diabetes, cerebrovascular disease, hypertension, cancer, depression, traumatic brain injury, and dyslipidemia may also contribute to the development of AD (5).

Aluminum chloride ( $AlCl_3$ ) is one of the experimental models used to induce AD. Aluminum is present in various substances that we consume such as food, water, dust, air, beverages, flavored drinks, energy drinks, and medications (6). Aluminum can cross the blood-brain barrier (BBB) and accumulate in the brain. It induces oxidative stress and neuroinflammation that can contribute to the development of AD (7). Aluminum exposure leads to impaired glucose utilization, increased free-radical generation, lipid peroxidation, and changes in phosphoinositide metabolism and protein phosphorylation, all of which contribute to severe neurotoxicity. These changes can also lead to a decrease in reduced glutathione, catalase, glutathione reductase activity, and superoxide dismutase (SOD) within the neurons. Besides, an increase in glutamate level, along with the release of oxidative products such as myeloperoxidase (MPO), malondialdehyde (MDA), carbonyls, and peroxynitrite. Therefore, loss of balance between oxidants and antioxidants leads to oxidative stress and damage. The overproduction of highly reactive radicals and fatigue of the antioxidant system enhances amyloid protein buildup

in the hippocampus, resulting in cognitive impairment (8). Amyloid- $\beta$  deposition may induce the expression of nuclear factor kappa B (NF- $\kappa$ B) and its signaling molecules, potentially contributing to the inflammatory response and neuronal damage seen in AD (9). Moreover, aluminum can significantly increase the activity of acetylcholinesterase (AChE), which leads to a greater breakdown of the acetylcholine (ACh) in the brain and memory loss (10). The brain renin-angiotensin system (RAS) may be involved in the development of Alzheimer's disease. Specifically, angiotensin-II (Ang-II) the main effector of the RAS, which has two receptors in the brain known as angiotensin type-1 (AT1) and angiotensin type-2 (AT2). Recent research suggests that activation of the AT1 receptor can trigger several pathways that contribute to neurodegeneration, including the generation of reactive oxygen species (ROS), inflammatory responses, and apoptosis. These findings suggest that the RAS and its receptors may be potential targets for the development of new treatments for AD (11).

Valsartan is an approved medicine that is a strong, orally active non-peptide tetrazole derivative that specifically inhibits Angiotensin II Receptor type 1, lowering blood pressure, and is used to treat hypertension. It is also available in combination with other antihypertensive medications (12). The aim of the present study was to investigate the potential neuroprotective effects of inhibiting RAS by valsartan on cognitive function and neuronal damage in an experimental model of AD. The study also aimed to assess the possible mechanisms underlying the neuroprotective actions of inhibiting RAS, specifically through the inhibition of ROS overproduction and the enhancement of the brain's antioxidant defense system.

## **2. Materials and methods**

### **2.1. Chemicals**

Valsartan and AlCl<sub>3</sub> were obtained from Sigma-Aldrich, CA, USA (Cat no. SML0142 and 8.01081, respectively).

### **2.2. Experimental animals**

For this study, male Wistar rats weighing 150-170g were sourced from the animal facility of the Faculty of Pharmacy, Egyptian Russian University, Cairo, Egypt. Rats were allowed to adjust to the laboratory conditions for a period of one week before the experiment commenced. During the experiment, rats were housed under controlled environmental conditions, with a constant temperature of  $23 \pm 2^\circ\text{C}$ , humidity of  $60 \pm 10\%$ , and a 12-/12-h light/dark cycle. Rats were given

free access to a standard chow diet. The experimental protocol was conducted in accordance with the international guidelines for the care and use of research animals and was approved by the institutional Ethics Committee of the Faculty of Pharmacy, Egyptian Russian University, Egypt. The approval number for the study was ERU-2021-11-005.

### **2.3. Experimental design**

Eighteen male rats were randomly divided into three groups consisting of 6 rats each. Group I was designated as the control group, where rats were given saline orally, daily for 28 days. Group II was designated as the AD group, where rats were given AlCl<sub>3</sub> (70 mg/kg) orally dissolved in saline daily for 28 days according to a previous study (13). Group III was designated as the valsartan treatment group, where rats were given 30 mg/kg valsartan orally dissolved in saline (11) one hour after the administration of AlCl<sub>3</sub> (70 mg/kg p.o) daily for 28 days.

At the end of the experiment, rats were weighed and anesthetized using phenobarbital before being sacrificed by cervical dislocation followed by decapitation. The whole brain was immediately removed, washed with isotonic saline, and frozen at -80°C until homogenization for measuring the brain tissue content. Additionally, two random rats from each group were selected for histopathological examination of brain tissue.

### **2.4. Behavioral tests**

#### **Open-field test**

The open-field test is commonly used to assess changes in locomotor activity (14). In this study, the test was performed using a square wooden box with dimensions of 80 × 80 × 40 cm. The walls of the box were red, while the floor was black and divided into 16 squares of equal size (4 × 4 cm) by white lines. Each animal was placed individually in the center of the box and monitored for 5 minutes in each trial. The number of squares passed with both feet (ambulation frequency) was used to measure locomotor activity, while vertical activity was measured by counting the number of rearing movements (when the animal stood on its hind legs). The floor of the box was cleaned after each tested animal.

#### **Morris water maze test**

The Morris water maze (MWM) test was used to evaluate the rats' spatial memory and learning (15). For this experiment, a pool of a dark color measuring 180 cm in diameter and 50 cm deep

was employed. It was divided into 4 equally sized quadrants. In addition, a mobile circular platform with a diameter of 9 cm was positioned in the middle of one of the four quadrants (the target quadrants) 1 cm below the water's surface for the training phase. The pool was filled with water up to a depth of 35 cm, and the temperature was maintained at  $25\pm 2$  °C throughout. Rats were trained three days before the test day to swim freely from various starting positions to the platform for 120 seconds. In the test step, the platform was taken from the apparatus, and the water was made opaque by adding a soluble, non-toxic, dark blue dye. The rats were given one minute to swim from the quadrant across from the target quadrant. The time the rats spent in the target quadrant was measured.

### **Novel object test**

The novel object test was used to assess the rats' recognition memory; it is based on the rodents' innate capacity to examine new things over familiar ones (16). The equipment is built of a black open field box measuring 50 cm wide, 80 cm long, and 60 cm high. The test was divided into three phases. During the habituation phase, rats were placed in an empty box for 10 minutes to explore. During Phase Two, rats were placed in the test box with two identical objects placed opposite to each other in two opposing corners, 6cm from the walls. The rats were given 3 minutes to investigate both things. During the testing phase, rats were placed in a box with one of the familiar objects replaced with a novel object that differed in shape, size, and color. The test lasted 3 minutes, and the rats' time spent exploring both objects was recorded using an overhead camera throughout training and testing sessions. The Discrimination Index was calculated by dividing the time spent examining familiar and novel objects by the total time spent exploring both objects. The findings can range from +1 to -1, with a positive value indicating more time spent examining the novel object, a negative value indicating more time spent with the familiar object, and a zero score indicating no preference.

### **2.5. Measurement of acetylcholine esterase activity and glutamate content**

To determine the activity of AChE and the content of glutamate in the brain tissues of both control, AD, and treated animals, commercially available ELISA kits were utilized following the procedures provided by the manufacturer (Cat no. MBS2709297 and MBS756400, respectively).

The kits were obtained from MyBioSource, a company located in San Diego, USA. The results of the AChE activity and glutamate were expressed as ng/mg/protein.

#### **2.6. Detection of oxidative stress and antioxidant markers**

The levels of MPO and SOD in the brain tissues of control, AD, and treated rats were measured using a manufacturer-recommended ELISA assay kit (Cat no. SD 25 21, Biodiagnostic, Giza, Egypt) and enzymatic assay kit (Cat no. E4581, BioVision, Milpitas, CA, USA), respectively. The values were expressed as ng/mg protein and U/mg protein, respectively.

#### **2.7. Quantification of inflammatory markers**

nuclear factor kappa B (NF- $\kappa$ B) levels in the brain tissues of control, AD, and treated rats were measured using a manufacturer-recommended ELISA assay kit (Cat no. SCB824Ra, CLOUD-CLONE CORP. CA, USA). The values were expressed as ng/mg protein.

#### **2.8. Determination of total proteins**

Protein content in all tissue samples was determined colorimetrically according to the Lowery *et al.* (17) method.

#### **2.9. Histopathological study**

To examine the brain tissue in the different animal groups, the brain portions were excised and cut into smaller pieces. The sections were then fixed 10% neutral formalin solution for 72 hours and processed for paraffin embedding. Thin sections of 4-6  $\mu$ m thickness were cut from the embedded tissue and subjected to staining using hematoxylin and eosin. The stained sections were then examined under a light microscope.

#### **2.10. Statistical analysis**

The data for ambulation frequency and rearing frequency were expressed as median and comparisons among the groups were analyzed using Kruskal-Wallis test, followed by Dunn's multiple comparison test. The rest of all data were expressed as mean  $\pm$  S.D and comparisons among the groups were conducted using one-way analysis of variance (ANOVA) followed by Tukey's test. In the study, the level of statistical significance was set at  $P < 0.05$ . All statistical analyses and the creation of graphs were performed using GraphPad Prism version 8.0.2 software.

### 3. Results

#### 3.1. Effect of valsartan on AlCl<sub>3</sub>-induced body weight changes in AD rat model.

The AlCl<sub>3</sub> dramatically altered the weight of the rats. Consequently, the rat's weight in the AlCl<sub>3</sub> group was markedly reduced by 40 % compared with the control group. Oppositely, in the valsartan group, the weight was increased by 1.54-fold in comparison with the AlCl<sub>3</sub> group (Figure 1).

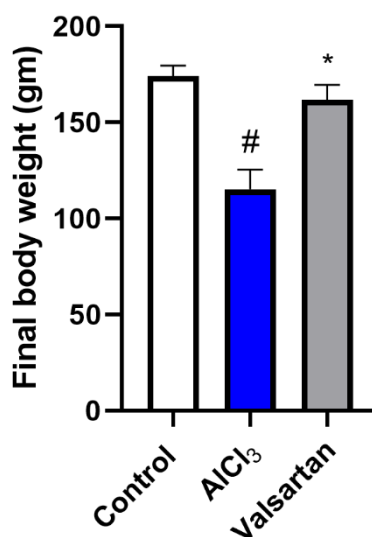
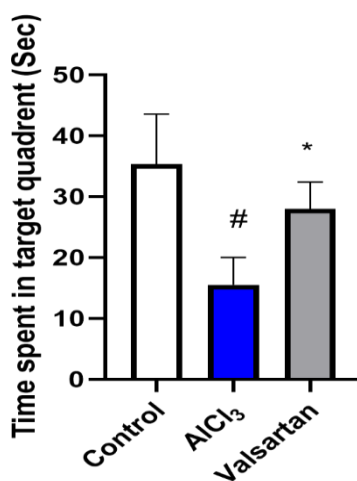


Figure 1: Effect of valsartan on AlCl<sub>3</sub>-induced body weight changes in AD rat model. The data is presented as the mean  $\pm$  SD (n=6). The symbols # or \* indicate that the results were significantly different from the control group or the AlCl<sub>3</sub>-induced Alzheimer's disease group, respectively, at a significance level of  $P < 0.05$ , using one-way analysis of variance (ANOVA) followed by the Tukey-Kramer test as a post-hoc analysis.

#### 3.2. Effect of Valsartan on AlCl<sub>3</sub>-induced behavioral changes in AD rat model

Assessing the various behavioral activities including locomotor activity, learning, recognition, and memory was done using different tests. For instance, the MWM test was used to assess the spatial memory of the animals. The findings showed that the group that received AlCl<sub>3</sub> only spent the least time in the target quadrant. The reduction in the time spent was significant (56.13%) compared to the control group. In comparison to AlCl<sub>3</sub> alone, animals that received both valsartan and AlCl<sub>3</sub> significantly had spent more time in the target quadrant by 1.8 folds (Figure 2). While the cognitive ability was tested using the novel object recognition (Figure 3-

a), the group that received AlCl<sub>3</sub> only showed a dramatic drop in the time exploring the novel object. They spent 43.69% of the total time exploring the novel object while 56.3% on the familiar object. Yet, the animals received normal saline and those injected with both AlCl<sub>3</sub> and valsartan spent 66.47% and 62.42% of the total time investigating the new object than the familiar one, respectively. **Figure 3-b** indicates the discrimination index of different groups, in comparison of the control and AlCl<sub>3</sub> groups, the discrimination index was significantly reduced by 62.56% simultaneously with the total time spent exploring both objects (46.8%). However, treatment with valsartan reversed the effect of AlCl<sub>3</sub>, where the discrimination index in the valsartan group was dramatically higher than that of the AlCl<sub>3</sub> group by 2 folds, also the valsartan group noticeably spent more time exploring both objects (1.3-fold). Lastly, the open field test was used to identify the locomotor activity. The AlCl<sub>3</sub>-only group locomotion was dramatically reduced other than in control and valsartan-treated groups. It was obvious with the significant reduction in the ambulation and rearing frequency by 60.64% and 67.67% respectively compared to the normal group. Nonetheless, treatment using valsartan abolished the negative effect of AlCl<sub>3</sub> on locomotion, where it demonstrated noticeable improvement by 1.94 and 2.29 folds in frequency of ambulation and rearing, respectively (**Figure 4**).



*Figure 2: Effect of valsartan on AlCl<sub>3</sub>-induced changes in time spent in target quadrant in Morris water maze test. The data is presented as the mean  $\pm$  SD (n=6). The symbols # or \* indicate that the results were significantly different from the control group or the AlCl<sub>3</sub>-induced Alzheimer's disease group, respectively, at a significance level of  $P < 0.05$ , using one-way analysis of variance (ANOVA) followed by the Tukey-Kramer test as a post-hoc analysis.*



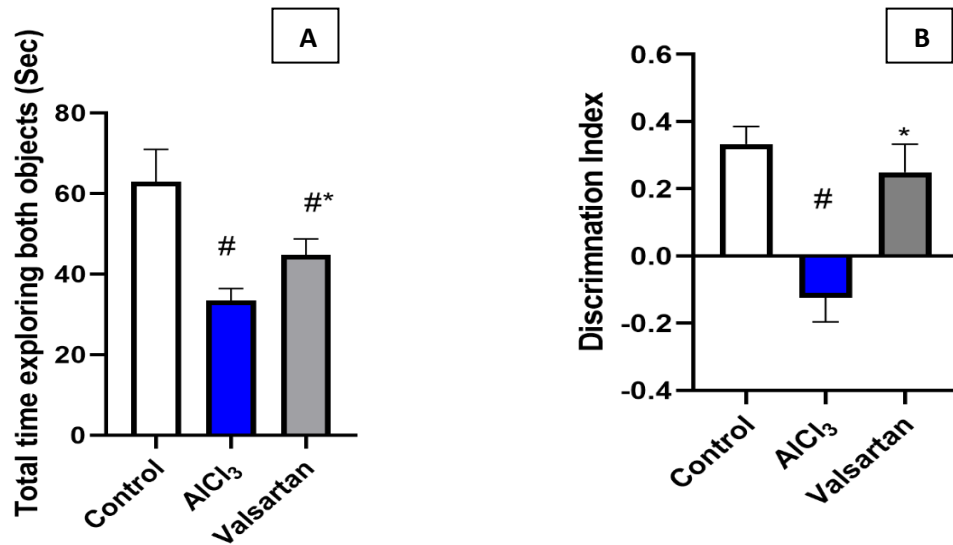


Figure 3: Effect of valsartan on AlCl<sub>3</sub>-induced changes in Total time exploring both objects (A) and discrimination index (B) in novel object recognition test. The data is presented as the mean  $\pm$  SD (n=6). The symbols # or \* indicate that the results were significantly different from the control group or the AlCl<sub>3</sub>-induced Alzheimer's disease group, respectively, at a significance level of  $P < 0.05$ , using one-way analysis of variance (ANOVA) followed by the Tukey-Kramer test as a post-hoc analysis.

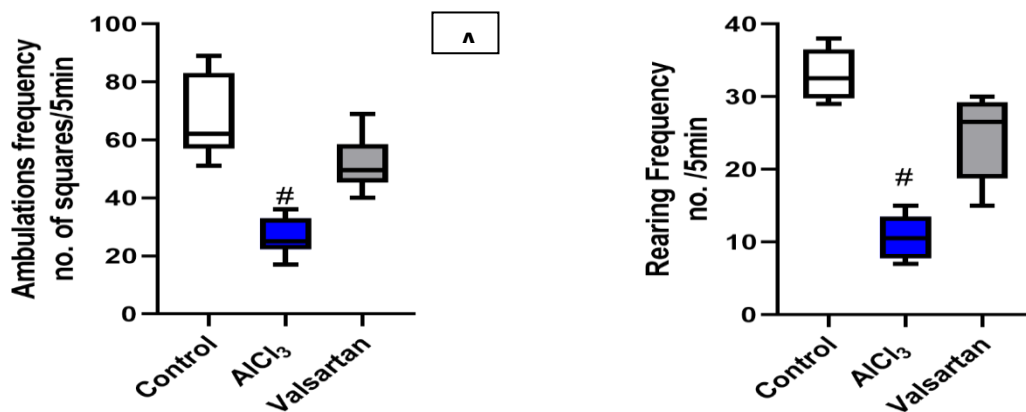
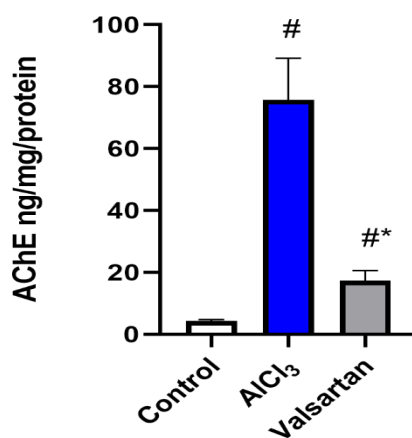


Figure 4: Effect of valsartan on AlCl<sub>3</sub>-induced changes in ambulation (A) and rearing frequency (B) in open field test and. The data is presented as median (n=6). The symbols # or \* indicate that the results were significantly different from the control group or the AlCl<sub>3</sub>-induced Alzheimer's disease group, respectively, at a significance level of  $P < 0.05$ , Kruskal-Wallis test, followed by Dunn's multiple comparison test as a post-hoc analysis.

### 3.3. Effect of Valsartan on AlCl<sub>3</sub>-induced changes in acetylcholine esterase activity in the hippocampus of AD rat model

Regarding AChE levels in the hippocampus, it was enhanced significantly by 17.72 folds in the brain of the AlCl<sub>3</sub> group compared to the control group. It's noteworthy that giving valsartan to rats that had been exposed to AlCl<sub>3</sub> significantly decreased AChE activity by 77.12% when compared to the AlCl<sub>3</sub> group. Moreover, there was a significant difference in the levels of the AChE between the control group and the valsartan group (**Figure 5**).



*Figure 5: Effect of valsartan on AlCl<sub>3</sub>-induced changes in (AChE) activity in the hippocampus of AD rat model. The data is presented as the mean  $\pm$  SD (n=6). The symbols # or \* indicate that the results were significantly different from the control group or the AlCl<sub>3</sub>-induced Alzheimer's disease group, respectively, at a significance level of  $P < 0.05$ , using one-way analysis of variance (ANOVA) followed by the Tukey-Kramer test as a post-hoc analysis.*

### 3.4. Effect of Valsartan on AlCl<sub>3</sub>-induced changes in glutamate levels in the hippocampus of AD rat model

One of the key indicators of AD is the glutamate concentration in the hippocampus. The injection of AlCl<sub>3</sub> for 28 in the AlCl<sub>3</sub> group markedly elevated the glutamate content by 5.54 folds (**Figure 6**). Contrarily, compared to the AlCl<sub>3</sub> group, valsartan therapy significantly decreased the glutamate level in the rat's hippocampus by 13.07%. However, the glutamate content of the control group was considerably lower than the AlCl<sub>3</sub> and valsartan group.

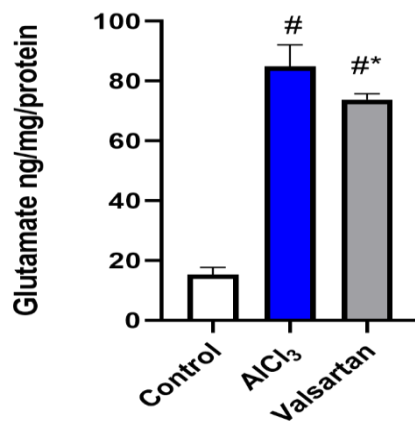


Figure 6: Effect of valsartan on AlCl<sub>3</sub>-induced changes in glutamate levels in the hippocampus of AD rat model. The data is presented as the mean  $\pm$  SD (n=6). The symbols # or \* indicate that the results were significantly different from the control group or the AlCl<sub>3</sub>-induced Alzheimer's disease group, respectively, at a significance level of  $P < 0.05$ , using one-way analysis of variance (ANOVA) followed by the Tukey-Kramer test as a post-hoc analysis.

### 3.5. Effect of Valsartan on AlCl<sub>3</sub>-induced changes in oxidative stress markers in the hippocampus of AD rat model

The rat's hippocampus exhibited a definite change in antioxidant and oxidative stress levels (Figure 7). When compared to the control group, the AlCl<sub>3</sub> group's MPO levels were significantly greater by 5.4 folds while SOD levels were significantly lower by 75.55%. However, compared to the AlCl<sub>3</sub> group, pretreatment with valsartan markedly reduced MPO by 27.9% and raised SOD brain contents by 2.84 folds. Additionally, there was a significant difference in both levels between the control and valsartan groups.

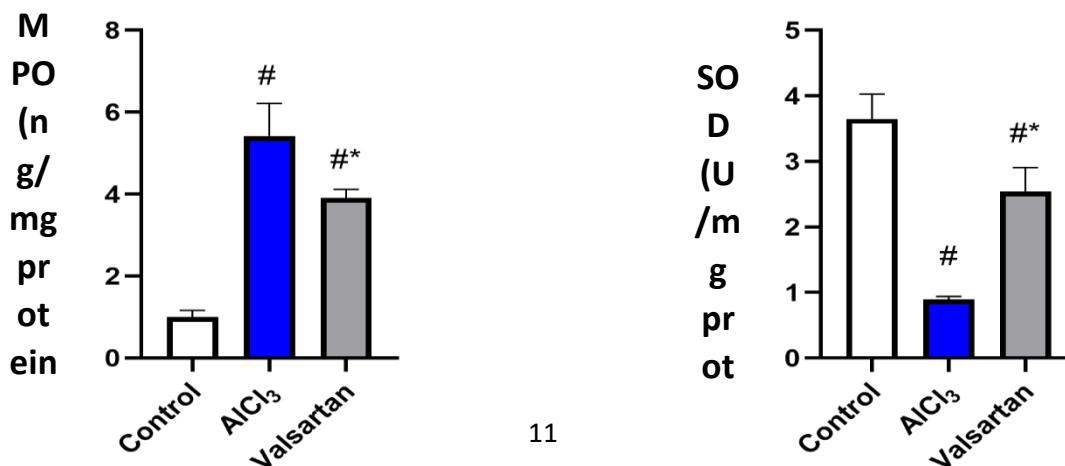


Figure 7: Effect of valsartan on  $AlCl_3$ -induced changes in MPO and SOD contents in the hippocampus of AD rat model. The data is presented as the mean  $\pm$  SD ( $n=6$ ). The symbols # or \* indicate that the results were significantly different from the control group or the  $AlCl_3$ -induced Alzheimer's disease group, respectively, at a significance level of  $P < 0.05$ , using one-way analysis of variance (ANOVA) followed by the Tukey-Kramer test as a post-hoc analysis.

### 3.6. Effect of Valsartan on $AlCl_3$ -induced changes in nuclear factor kappa B levels in the hippocampus of AD rat model

A quantitative measurement was performed to determine how  $AlCl_3$  and valsartan medication altered the levels of the inflammatory mediator NF- $\kappa$ B. The findings demonstrated that the NF- $\kappa$ B levels were noticeably higher (3.39 folds) in the group injected with  $AlCl_3$  only than in the control group. Additionally, the injection of valsartan significantly reduced the level of NF- $\kappa$ B (33.41%) when correlated to the  $AlCl_3$  group. Nevertheless, the difference in the NF- $\kappa$ B levels in both the control and valsartan groups was significant (**Figure 8**).

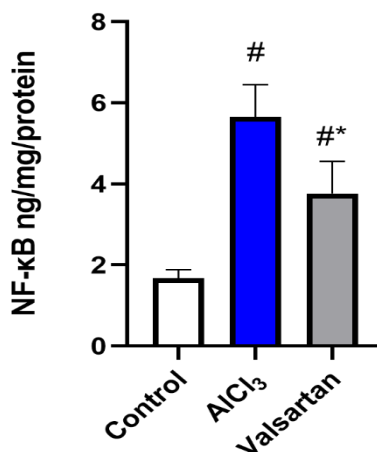


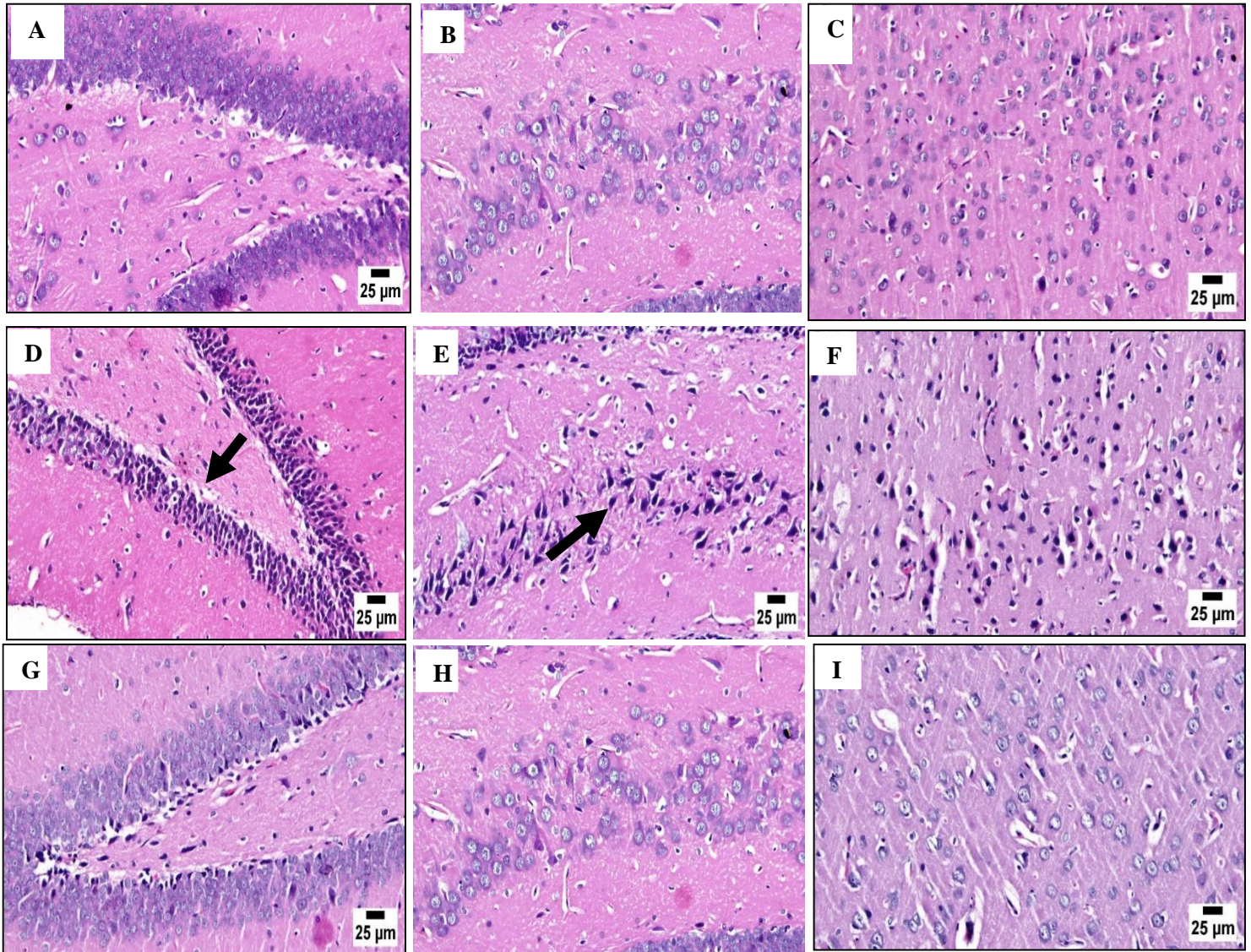
Figure 8: Effect of valsartan on  $AlCl_3$ -induced changes in (NF- $\kappa$ B) levels in the hippocampus of AD rat model. The data is presented as the mean  $\pm$  SD ( $n=6$ ). The symbols # or \* indicate that the results were significantly different from the control group or the  $AlCl_3$ -induced Alzheimer's disease group, respectively, at a significance level of  $P < 0.05$ , using one-way analysis of variance (ANOVA) followed by the Tukey-Kramer test as a post-hoc analysis.

### 3.7. Histopathology

Hippocampus CA4 and DG regions and the cerebral cortex of the control group were found to be normal upon histopathological testing. In contrast, the cerebral cortex and CA4 and DG region of



the hippocampus of the  $AlCl_3$  showed a variety of histological alterations. The hippocampus area showed dark, deteriorating neurons. While the cerebral cortex displayed diffuse gliosis. Valsartan treatment caused marked improvement with some degenerated neurons in DG region of the hippocampus and apparently normal neurons in the cerebral cortex (**Figure 9**).



*Figure 8: Effect of valsartan on CA4 and DG regions of the hippocampus and cerebral cortex histopathology in AD rats. (A, B, C) control group, showing normal CA4 and DG region of hippocampus and normal cerebral cortex, respectively. (C, D, E) which is the  $AlCl_3$  group, displayed numerous dark neurons in CA4 region (arrow) and numerous dark neurons in DG region (arrow) of hippocampus and numerous degenerated neurons in the cerebral cortex, respectively. (G, H, I) which is the valsartan treatment group showed apparently normal CA4 region marked improvement with some degenerated neurons in DG region of hippocampus and apparently normal neurons in the cerebral cortex, respectively.*

#### 4. Discussion

Alzheimer's disease (AD) is an irreversible neurodegenerative disease manifested by loss of spatial memory and impairment of cognitive functions, with highly rising mortality and morbidity rates (18-20). One of the risk factors causing AD is exposure to aluminum which is abundantly present in nature and considered a potent neurotoxin (21). Its capacity to pass the BBB drives the generation of free radicals, which in turn induces brain oxidative stress and neuronal inflammation, both of which result in damage to memory- and learning-related brain regions (22, 23). Nevertheless, the treatment of AD remains one of the most difficult neurological problems because there are no known underlying mechanisms for it. There is mounting evidence that inflammation may play a key role in the onset and progression of AD, where proinflammatory cytokines are overexpressed in the brains of AD patients, causing the buildup of A $\beta$  plaque aggregates and tau hyperphosphorylation, which results in neuronal loss (24, 25). In this study, it was found that treatment using valsartan in an AlCl<sub>3</sub>-induced AD model enhanced their spatial learning behavior and significantly reduced AChE, glutamate activity, hippocampal oxidative stress, and pro-inflammatory cytokine production, indicating that it may be neuroprotective against AlCl<sub>3</sub>-driven AD (26).

In alignment with previous studies, our results showed that rats intoxicated with AlCl<sub>3</sub> affected their behavioral activity, in which they exhibited a weak exploratory preference and locomotor activity and poor spatial memory in MWM, NOR, and open-field tests (27). For instance, MWM in the present study proved that AlCl<sub>3</sub> caused a disturbance in the spatial memory of the animals which was reflected by spending less time in the target quadrant which is in accordance with previous results (28). On the other hand, in NOR and open-field tests, AlCl<sub>3</sub> caused a dramatic reduction in the locomotive activity and recognition behavior. This was observed in NOR by the noticeable decline in the discrimination index and total time spent exploring both objects. In the open-field test, the ambulation and rearing frequency were markedly decreased when compared to the control group. These findings are in conformity with a previously published result (29). Valsartan treatment mitigated AlCl<sub>3</sub>-induced cognitive impairment as demonstrated by considerably spending more time in the target quadrant, a high discrimination index with a longer time exploring the objects, and an increase in ambulation and rearing frequency. These findings are in agreement with a previous study (30). These results suggest the potential protective effects of valsartan against cognitive deficits.

Acetylcholine is one of the brain's main excitatory neurotransmitters, which is strongly correlated with AD. According to earlier research, cholinergic anomalies were seen in the early stages of Alzheimer's disease, but by the late stages, the majority of cholinergic neurons had been lost (31). Previous studies have noted enhanced AChE activity in rats exposed to AlCl<sub>3</sub>, which is consistent with the findings of the present investigation. AlCl<sub>3</sub>'s direct neurotoxic impact, which changes the kinetic characteristics of AChE, may be the cause of the elevated AChE activity. Moreover, Long-term Al exposure results in the overexpression of the APP gene and the subsequent synthesis of A $\beta$  production. A $\beta$  stimulates alpha7-nicotinic acetylcholine receptors, increasing AChE activity (32). Using valsartan as a treatment in our study reversed the effect of AlCl<sub>3</sub> on AChE, where it leads to a decline in the levels of the AChE in the hippocampus in correlation with a previous study (33).

Glutamate is crucial for long-term potentiation, which is regarded to be the primary physiological mechanism underlying learning and memory. Excess glutamate in the brain can cause nerve cells to overexcite. Excessive excitation can cause brain cell damage and death. (34). Our results described that the level of glutamate was elevated in exposure to AlCl<sub>3</sub> in accordance with a recent study (26). A significant improvement in the levels of glutamate and glutamine was observed with Valsartan, indicating a restoration of normal neurotransmission and metabolic processes like those reported in a previous study in which valsartan increased glutamate levels in rat kidneys (35).

Numerous pieces of evidence have linked free radical damage and oxidative stress to AD etiology. Nitration, lipid peroxidation adduction products, and free carbonyls are some of the damages behind AD (36). In this study, antioxidant enzymes were represented as superoxide dismutase (SOD), as well as oxidative products represented as MPO. AlCl<sub>3</sub> caused neuronal oxidative stress in the model group, according to the resultant data, which was supported by increased MPO and a decrease in superoxide dismutase (SOD) activity in accordance with previous research (37). Valsartan caused a significant reduction of MPO and an increment in SOD in alignment with a recent study in which valsartan increased SOD in obstructive pulmonary disease (38) revealing the increase in antioxidant ability induced by valsartan.

One of the most important inflammatory mediators is NF-kB, it controls the expression of many genes involved in inflammation and apoptosis. There has been evidence of NF-kB activity

in the AD brain from numerous research. Active NF- $\kappa$ B is primarily seen in neurons and glial cells in the A $\beta$  plaques of AD patients (39). Memory impairment might be brought on by activated NF- $\kappa$ B, which might be due to enhancing apoptosis and the expression of other inflammatory mediators like tumor necrosis factor-alpha (TNF-a). It's noteworthy that glutamate has also been shown to be a mediator of NF- $\kappa$ B activation (40). Furthermore, as shown in the previous work (41, 42), NF- $\kappa$ B-dependent interleukin (IL-1) overexpression, increases AChE activity and synthesis. In the present study, NF- $\kappa$ B was significantly upregulated in the induction group using AlCl<sub>3</sub>, which was formerly demonstrated before (43). Valsartan had the ability to cause a significant reduction in the NF- $\kappa$ B levels in the present study. This effect was previously reported in a rat model of unilateral ureteral obstruction (44). In the present study, using valsartan also significantly reduced histopathological changes of the cortex and hippocampus of the brain as previously shown in earlier work (11) while concurrently reducing cognitive deficit, oxidative stress, and inflammation.

## 5. Conclusion

Based on the findings, it can be concluded that prolonged accumulation of Al can lead to neurotoxicity by causing the development of neurofibrillary tangles and amyloid aggregates. Aluminum administration also induces oxidative stress, resulting in an elevation of MPO levels and a decrease in antioxidant enzyme levels, such as SOD. Aluminum is also a strong cholinotoxin that leads to alterations in cholinergic transmission, resulting in a significant increase in AChE levels. Additionally, AlCl<sub>3</sub> leads to an elevation in the levels of NF- $\kappa$ B. However, valsartan was found to attenuate the cognitive decline induced by AlCl<sub>3</sub> and act as a neuroprotective agent against neurotoxicity. This is due to its regulation of AChE activity in the brain and elevation of the antioxidant ability by increasing the activities of SOD while reducing the formation of ROS by reducing the level of MPO. Furthermore, valsartan was found to alleviate NF- $\kappa$ B-mediated inflammasome activation. Overall, these findings suggest that valsartan may be a potential therapeutic agent for the treatment of neurodegenerative diseases induced by AlCl<sub>3</sub> toxicity.

## 6. list of abbreviations

Acetylcholinesterase: AchE, aggregated  $\beta$ -amyloid: A $\beta$ , Alzheimer's disease: AD, amyloid precursor protein: APP, Aluminum chloride: AlCl<sub>3</sub>, one-way analysis of variance: ANOVA,



angiotensin-II: Ang-II, angiotensin type-1: AT1, angiotensin type-2: AT2, blood-brain barrier: BBB, malondialdehyde: MDA, Morris water maze: MWM, nuclear factor kappa B: NF-kB, myeloperoxidase: MPO, renin-angiotensin system: RAS, superoxide dismutase: SOD,

### **Acknowledgment**

The authors would like to express our special thanks of gratitude to fifth-year students, 2023 graduates, and faculty of pharmacy, at Egyptian Russian University, for their participation in performing the experimental procedures.

### **Conflict of interest**

No conflict of interest.

### **7. References**

1. Breijyeh Z, Karaman R. Comprehensive Review on Alzheimer's Disease: Causes and Treatment. *Molecules* (Basel, Switzerland). 2020;25(24).
2. Sehar U, Rawat P, Reddy AP, Kopel J, Reddy PH. Amyloid Beta in Aging and Alzheimer's Disease. *International journal of molecular sciences*. 2022;23(21).
3. Javaid SF, Giebel C, Khan MA, Hashim MJFF. Epidemiology of Alzheimer's disease and other dementias: Rising global burden and forecasted trends. 2021;10:425.
4. John A, Reddy PHJArr. Synaptic basis of Alzheimer's disease: Focus on synaptic amyloid beta, P-tau and mitochondria. 2021;65:101208.
5. Simunkova M, Alwasel SH, Alhazza IM, Jomova K, Kollar V, Rusko M, et al. Management of oxidative stress and other pathologies in Alzheimer's disease. 2019;93:2491-513.
6. Chen X, Zhang M, Ahmed M, Surapaneni KM, Veeraraghavan VP, Arulselvan P. Neuroprotective effects of ononin against the aluminium chloride-induced Alzheimer's disease in rats. *Saudi journal of biological sciences*. 2021;28(8):4232-9.
7. Martać L, Podgorac J, Petković B, Stojadinović GJJoHMT, Diseases. Aluminium neurotoxicity and neuroprotection. 2022;7(4):11.
8. Abd El-Aziz NM, Shehata MG, Alsulami T, Badr AN, Elbakatoshy MR, Ali HS, et al. Characterization of Orange Peel Extract and Its Potential Protective Effect against Aluminum Chloride-Induced Alzheimer's Disease. *Pharmaceuticals* (Basel, Switzerland). 2022;16(1).
9. Lakshmi BV, Sudhakar M, Prakash KS. Protective effect of selenium against aluminum chloride-induced Alzheimer's disease: behavioral and biochemical alterations in rats. *Biological trace element research*. 2015;165(1):67-74.
10. Zhang Z, Wu H, Qi S, Tang Y, Qin C, Liu R, et al. 5-Methyltetrahydrofolate Alleviates Memory Impairment in a Rat Model of Alzheimer's Disease Induced by D-Galactose and

Aluminum Chloride. International journal of environmental research and public health. 2022;19(24).

11. Arjmand Abbassi Y, Mohammadi MT, Sarami Foroshani M, Raouf Sarshoori J. Captopril and Valsartan May Improve Cognitive Function Through Potentiation of the Brain Antioxidant Defense System and Attenuation of Oxidative/Nitrosative Damage in STZ-Induced Dementia in Rat. *Advanced pharmaceutical bulletin*. 2016;6(4):531-9.
12. Siddiqui N, Husain A, Chaudhry L, Alam MS, Mitra M, Bhasin PSJJoAPS. Pharmacological and pharmaceutical profile of valsartan: a review. 2011(Issue):12-9.
13. Hamdan AME, Alharthi FHJ, Alanazi AH, El-Emam SZ, Zaghlool SS, Metwally K, et al. Neuroprotective Effects of Phytochemicals against Aluminum Chloride-Induced Alzheimer's Disease through ApoE4/LRP1, Wnt3/ $\beta$ -Catenin/GSK3 $\beta$ , and TLR4/NLRP3 Pathways with Physical and Mental Activities in a Rat Model. *Pharmaceuticals (Basel, Switzerland)*. 2022;15(8).
14. Sá F, Pinto P, Cunha C, Lemos R, Letra L, Simões M, et al. Differences between Early and Late-Onset Alzheimer's Disease in Neuropsychological Tests. *Frontiers in Neurology*. 2012;3.
15. Boeve BF. Mild cognitive impairment associated with underlying Alzheimer's disease versus Lewy body disease. *Parkinsonism & related disorders*. 2012;18:S41-S4.
16. Fiasal Zaher M, Abdelfattah Bendary M, Saeed Abd El-Aziz G, Shaker Ali A. Potential Protective Role of Thymoquinone on Experimentally-induced Alzheimer Rats. *Journal of Pharmaceutical Research International*. 2019;31(6):1-18.
17. Kawahara M, Kato-Negishi M. Link between Aluminum and the Pathogenesis of Alzheimer's Disease: The Integration of the Aluminum and Amyloid Cascade Hypotheses. *Int J Alzheimers Dis*. 2011;2011:276393.
18. Kumar V, Bal A, Gill KD. Aluminium-induced oxidative DNA damage recognition and cell-cycle disruption in different regions of rat brain. *Toxicology*. 2009;264(3):137-44.
19. Saba K, Rajnala N, Veeraiah P, Tiwari V, Rana RK, Lakhotia SC, et al. Energetics of excitatory and inhibitory neurotransmission in aluminum chloride model of Alzheimer's disease: Reversal of behavioral and metabolic deficits by Rasa Sindoor. *Frontiers in molecular neuroscience*. 2017;10:323.
20. Kinney JW, Bemiller SM, Murtishaw AS, Leisgang AM, Salazar AM, Lamb BT. Inflammation as a central mechanism in Alzheimer's disease. *Alzheimer's & Dementia: Translational Research & Clinical Interventions*. 2018;4:575-90.
21. Wang WY, Tan MS, Yu JT, Tan L. Role of pro-inflammatory cytokines released from microglia in Alzheimer's disease. *Ann Transl Med*. 2015;3(10):136.
22. Kaur K, Narang RK, Singh S. AlCl<sub>3</sub> induced learning and memory deficit in zebrafish. *Neurotoxicology*. 2022;92:67-76.
23. Luo Y, Niu F, Sun Z, Cao W, Zhang X, Guan D, et al. Altered expression of A $\beta$  metabolism-associated molecules from d-galactose/AlCl<sub>3</sub> induced mouse brain. *Mechanisms of ageing and development*. 2009;130(4):248-52.
24. Prabhakar O. Naringin Attenuates Aluminum Induced Cognitive Deficits in Rats. *Indian J Pharm Educ Res*. 2020;54:674-81.
25. Andersen JK. Oxidative stress in neurodegeneration: cause or consequence? *Nature medicine*. 2004;10(Suppl 7):S18-S25.

26. Braszko JJ. Valsartan Abolishes Most of the Memory-Improving Effects of Intracerebroventricular Angiotensin II in Rats. *Clinical and Experimental Hypertension*. 2005;27(8):635-49.
27. Hampel H, Mesulam M-M, Cuello AC, Farlow MR, Giacobini E, Grossberg GT, et al. The cholinergic system in the pathophysiology and treatment of Alzheimer's disease. *Brain*. 2018;141(7):1917-33.
28. Fodero LR, Mok SS, Losic D, Martin LL, Aguilar MI, Barrow CJ, et al.  $\alpha$ 7-Nicotinic acetylcholine receptors mediate an A $\beta$ 1-42-induced increase in the level of acetylcholinesterase in primary cortical neurones. *Journal of Neurochemistry*. 2004;88(5):1186-93.
29. Yang WN, Hu XD, Han H, Shi LL, Feng GF, Liu Y, et al. The effects of valsartan on cognitive deficits induced by aluminum trichloride and d-galactose in mice. *Neurological research*. 2014;36(7):651-8.
30. Li Z, Chen X, Lu W, Zhang S, Guan X, Li Z, et al. Anti-Oxidative Stress Activity Is Essential for Amanita caesarea Mediated Neuroprotection on Glutamate-Induced Apoptotic HT22 Cells and an Alzheimer's Disease Mouse Model. *International journal of molecular sciences*. 2017;18(8).
31. Zakrocka I, Targowska-Duda KM, Wnorowski A, Kocki T, Józwiak K, Turski WA. Angiotensin II type 1 receptor blockers decrease kynurenic acid production in rat kidney in vitro. *Naunyn-Schmiedeberg's archives of pharmacology*. 2019;392(2):209-17.
32. Bai R, Guo J, Ye XY, Xie Y, Xie T. Oxidative stress: The core pathogenesis and mechanism of Alzheimer's disease. *Ageing research reviews*. 2022;77:101619.
33. Anwar MM. Oxidative stress-A direct bridge to central nervous system homeostatic dysfunction and Alzheimer's disease. *Cell biochemistry and function*. 2022;40(1):17-27.
34. Li YR, Xie HB, Li H, Sun J. [Protective effects of dexamethasone combined with valsartan on chronic obstructive pulmonary disease in mice and its mechanism]. *Zhongguo ying yong sheng li xue za zhi = Zhongguo yingyong shenglixue zazhi = Chinese journal of applied physiology*. 2022;38(2):149-53.
35. Snow WM, Albeni BC. Neuronal Gene Targets of NF- $\kappa$ B and Their Dysregulation in Alzheimer's Disease. *Front Mol Neurosci*. 2016;9:118.
36. Shen W, Zhang C, Zhang G. Nuclear factor kappaB activation is mediated by NMDA and non-NMDA receptor and L-type voltage-gated Ca(2+) channel following severe global ischemia in rat hippocampus. *Brain Res*. 2002;933(1):23-30.
37. Schliebs R, Heidel K, Apelt J, Gniezdzińska M, Kirazov L, Szutowicz A. Interaction of interleukin-1 $\beta$  with muscarinic acetylcholine receptor-mediated signaling cascade in cholinergically differentiated SH-SY5Y cells. *Brain Research*. 2006;1122(1):78-85.
38. Sakon S, Xue X, Takekawa M, Sasazuki T, Okazaki T, Kojima Y, et al. NF-kappaB inhibits TNF-induced accumulation of ROS that mediate prolonged MAPK activation and necrotic cell death. *Embo j*. 2003;22(15):3898-909.
39. Zhao Y, Hill JM, Bhattacharjee S, Percy ME, Pogue AI, Lukiw WJ. Aluminum-induced amyloidogenesis and impairment in the clearance of amyloid peptides from the central nervous system in Alzheimer's disease. *Front Neurol*. 2014;5:167.
40. Wang Y, Wang D, Jin H, Zhang L, Yu M. Effects of Qingshen granules on Janus Kinase/signal transducer and activator of transcription signaling pathway in rats with unilateral ureteral obstruction. *Journal of traditional Chinese medicine = Chung i tsa chih ying wen pan*. 2018;38(2):182-9.