

EFFECTIVENESS OF THERACAL LC VERSUS MTA IN VITAL PULP THERAPY OF CARIOUSLY-EXPOSED YOUNG PERMANENT MOLARS: FIVE-YEAR FOLLOW UP OF A RANDOMISED CLINICAL TRIAL

Passant Nagi ^{1*}, Nouran Nabil Marzaban², Ahmed Elkhadem ³.

ABSTRACT

INTRODUCTION: Carious pulp exposure of young-vital first permanent molars (FPMs) is a widespread unfortunate event. Pulpotomy treatment is a treatment option; however, choosing capping materials is crucial.

OBJECTIVES: To compare tooth clinical/radiographic (survival) rate after one/five years following pulpotomy of cariously-exposed vital FPMs using TheraCal-LC (TLC) and Mineral-Trioxide-Aggregate (MTA).

METHODOLOGY: This was Randomised Clinical Trial (RCT), single-blinded, equivalence-framework. Twenty-two FPMs in children aged 6-8.5 years were randomly allocated to TLC/MTA groups. Pulpotomy was performed, followed by capping material and final restoration. Immediately, post-operative periapical radiographs were taken. A preliminary report was published after 1-year, and now this is the 5-years follow-up.

RESULTS: Average age of participants was 7.7 years. Using Absolute-risk/Absolute-risk reduction (ARR), Relative-Risk (RR) and their 95% confidence intervals (95% CI), following results were obtained: Clinically, risk of spontaneous pain/swelling was 7-times/5-times, more in TLC group respectively at 1-year and 2.6-times/5-times, more in TLC group respectively after 5-years. Radiographically, risk of periapical radiolucency/root resorption occurrence was 9-times/2-times more in TLC group, respectively, both after 1-year and 5-years. The probability of root maturation was 20% and 10% less in TLC group at 1-year/5-years, respectively. Surprisingly, 90% of teeth show complete apical closure even if pulp necrosis occurred. The final survival rate (clinical and radiographic) MTA was 90.9% /72.72% after 1-year/5-years respectively. The final survival rate (clinical and radiographic) for TLC was 18.18% after both 1-year and 5-year.

CONCLUSION: Within current study's limitations, TLC results were less promising than MTA in pulpotomy of young permanent molars.

KEYWORDS: TheraCal LC, MTA, pulpotomy, survival rate, permanent molars.

1- Lecturer at Pediatric Dentistry and Dental Public Health Department, Faculty of Dentistry, Cairo University, Egypt.

2- Lecturer, Oral and Maxillofacial Radiology, Faculty of Dentistry, Cairo University, Egypt.

3- Associate Professor of Pediatric Dentistry and Dental Public Health Department, Faculty of Dentistry, Cairo University, Egypt

*Corresponding author:

Passant.nagi@dentistry.cu.edu.eg

INTRODUCTION

Scientific background and explanation of the rationale

Carious pulp exposure of young First Permanent Molars (FPMs) in children is a very common unfortunate event. Pulpotomy for treating those teeth is a reliable technique to maintain pulp vitality to continue the thickening of dentinal walls at pulp chamber and root canals and subsequently prevent tooth fracture [1, 2]. Pulpotomy could be considered permanent final treatment or, if considered intermediate treatment, could help carry out root canal treatment if needed after complete apex closure. The choice of capping materials could have a massive influence on the success of vital pulp therapy (VPT). However, healing of dental pulp exposures may not depend on the type of pulp capping material as much as their capacity to prevent bacterial leakage [3].

MTA is the gold standard as a pulp dressing material. The most annoying properties of MTA are prolonged setting time (2 h and 45 min \pm 5 min), the handling difficulty, the expensive cost and the inherent potential for discolouring the tooth. TheraCal-LC (TLC) could be an excellent solution for this problem with controlled setting time (light cured) and not reported to cause discolouration. Gandolfi et al. named TLC "a novel light-curable MTA-like material" [4].

TLC consists of tricalcium silicate particles in a hydrophilic monomer, which provides significant calcium release. This calcium release stimulates hydroxyapatite and dentin bridge formation. TLC may be placed directly on pulpal exposures after control of bleeding, which makes it indicated for any pulpal exposures. TLC comprises approximately 45% wt mineral material (type III Portland Cement), 10% wt radiopaque component,

5% wt hydrophilic thickening agent (fumed silica) and approximately 45% resin. The resin is composed of; a hydrophilic component (containing hydrophilic monomers) such as hydroxyethyl methacrylate (HEMA) and polyethylene glycol dimethacrylate (PEGDMA), and a hydrophobic component (comprising hydrophobic monomers) such as urethane dimethacrylate (UDMA), bisphenol A-glycidyl methacrylate (BisGMA), triethylene glycol dimethacrylate (TriEDMA or TEGDMA) [4].

Many studies investigated TLC characters [4, 5] and gave promising results. Taking into consideration the easy manipulation of the TLC syringes and the controlled setting time, the comparable properties to MTA, and the lower cost (about 1/3 the price of MTA at the time of conducting the trial), we compared these two materials in pulpotomy of young permanent teeth. A preliminary report was published after 1-year as partial fulfilment of one of the authors' (PN) post-graduate degrees [6].

Null hypothesis

TLC pulpotomy had a similar survival success rate (clinically and radiographically) as MTA pulpotomy in cariously exposed FPMs, short term after 1-year and long term after 5-years, with a shorter chair side time of application.

OBJECTIVES

To compare tooth survival rate (clinical and radiographic) following pulpotomy of cariously-exposed vital young molars using TLC and MTA both short term after 1-year and long term after 5-years. Secondary outcomes, including root maturation and time laps till final restoration, were also compared [6].

MATERIALS AND METHODS:

Trial design

The current trial was a Randomised Clinical Trial (RCT) equivalence framework, allocation-blinded, two-arm, parallel-group trial with an allocation ratio of 1:1 and following the CONSORT statement 2010 for reporting RCTs [7].

Changes to methods after trial commencement: N/A

Clinical trial registration:

The trial was registered at ClinicalTrials.gov under the ID: NCT03119779 (Registration date: September 2015, prospectively registered as a PhD thesis). The official trial registration at Cairo University ID: "CEBD-CU-2014-09-15".

The time frame of the study :

The current study was approved by the paediatric dentistry counsel at Cairo University and research plan committee in October 2013. The protocol was approved by Evidence-based dentistry committee in December 2013 and Ethics committee in May 2014. The trial was registered at ClinicalTrials.gov in September 2015, and the 1-year follow-up ended on

30/4/2017. The 5-year recruitment of the participants ended in April 2022. Recruitment of the patients before the 5-year follow-up was not feasible, especially during the first period of the COVID-19 Pandemic.

Participants

Twenty-two participants were recruited for the current RCT.

Eligibility criteria:

We followed AAPD guidelines [8]; Inclusion criteria: Healthy children with no physical or mental disorders with cooperative behaviour. Age: 6-8.5 years and periapical x-ray was taken first to assure apex immaturity. Restorable permanent molars with deep caries and mild provoked pain could be relieved with analgesics or disappear immediately after the stimulus's removal, indicating reversible pulpitis.

Exclusion criteria: Pathological mobility, swelling or tenderness to percussion/palpation clinically. Teeth with periapical pathology are shown in the pre-operative radiographic as resorption, periradicular or furcation radiolucency, or a widened periodontal ligament space or if haemorrhage control is unachievable at the operative procedure.

Settings and locations where the data were collected

Setting was in the Pediatric Dentistry and Dental Public Health department - Faculty of Dentistry, Cairo University, Egypt. The operator was a post-graduate student (PN) without assistance.

Interventions:

For both groups, at the first visit after screening for eligibility and recruiting patients, the principal investigator (PN) explained the nature of the experiment and took verbal assent from the child and written consents from participants' legal guardians. Personal, medical, and dental histories and baseline records were collected, including photographs, periapical radiographs, and Impressions for constructing the acrylic stent [9] (Fig. 1) used for standardisation of the follow-up radiographs. The XCP dental x-ray film positioning device (Rinn Corporation©. Elgin, IL: Rinn Corporation) was assembled and attached to the acrylic stent to ensure film position at the same place intraorally every examination visit. Then, allocation was done by withdrawing an envelope which allocated participants.

At the second visit, administration of inferior alveolar nerve block (Septodont, Scandonest® 2% L Mepivacaine HCl. 2% and Levonordefrin 1:20,000 Injection, USP) followed by rubber dam isolation of teeth (Roeko Flexi-Dm - Purple Non-Latex Coltène/Whaledent Ltd., UK). Operator removed caries using a suitable round carbide bur under a copious amount of water coolant, then excavated pulp using spoon excavator. The wound was gently flushed with distilled water until bleeding was controlled. If bleeding was not

controlled within 5 min, we excluded the tooth from the study and treated it with single visit revascularisation technique [10]. All participants receive complete coronal pulpotomy except for two cases where the bleeding was controlled with continuous irrigation after removing few portion of the coronal pulp so partial pulpotomy was done [11].

Once hemostasis was achieved, allocations to the test groups were done by opening the envelope. Time-lapse till final restoration performed was calculated using a stopwatch in minutes, and the operator started the watch at this point. Average time was taken from the complete control of bleeding at pulpotomy procedures till final restoration applications.

Application of tested materials:

At the TLC group (Bisco, Inc. USA), the material was directly applied to the exposed pulp with a needle tip syringe in incremental layers not exceeding 1 mm deep and extended at least 1 mm onto sound dentin. Each increment layer was light-cured following manufacturer instructions [12, 13]. On the other hand, at the MTA group (Angelus, Industria de Produtos Odontofogicos Ltda, Londrina, Brazil) was manipulated in the ratio of 3:1 (powder: liquid) to obtain a putty mix according to manufacturer instructions immediately before use. MTA was gently placed and condensed over wet cotton, and the excess material was scraped off. Then, moistened cotton was applied for 15 minutes for initial setting.

Following the setting of the tested pulp dressing materials at both groups, the rest of the pulp chamber was filled with a 2-mm thick layer of a self-cure glass ionomer (Riva Self Cure Capsules regular set, A2, and A3, SDI, Cologne, Germany). Then, final restoration was done using composite (Zhermack SpA - Via Bovazecchino©, 100 45021 Badia Polesine (RO), Italy) [14]. Standardised apical radiographs were taken as a baseline record using the same cone positioner and the acrylic stent.

Outcomes:

We selected the most used Core Set of Outcomes for RCTs with multiple outcomes of pulp treatments [15]. The primary outcome was survival rate (which means absence of any complementary treatment or complication clinically and radiographically [16]).

Clinical observations included absence of spontaneous pain (binary outcome measured with Direct questioning to the patient) and absence of swelling (binary outcome measured visually at the clinic). Clinical success was monitored at 3, 6, 9, and 12 months and then recalled after 5 years. Visual examination, palpation, and percussion tests with the back of the mirror were assessed at all visits by the principal investigator PN and blinded assessor AE, and both recorded the presence/absence of pain at each visit. Digital

intraoral photographs were taken at each visit to record the presence/absence of gingival swelling, sinus or fistula and were reassessed at the 5-year visit.

Radiographic success was assessed as the absence of periapical radiolucency or internal/external root resorption (binary outcome detected with periapical radiograph). It was assessed independently by pre-calibrated 2 blinded assessors (NM and AE), and consensus resolved conflict. Precalibration session was done by to train and standardize the examiners, who were one pedodontics consultant (AE) and one radiologist consultant (NM) and the examiners used reference images. Periapical radiographs were examined at 6 and 12 months and after 5 years. The inter examiner agreement was calculated using Kappa score.

The overall inter-observer agreement for clinical and radiographic assessments has shown "very good" agreement between observers (Kappa= 0.806, SE of kappa = 0.131, 95% CI 0.549 to 1.000).

The secondary outcomes included timelapse from the control of bleeding after pulpotomy till final restoration performed (continuous outcome measured with a stopwatch in minutes) and were measured by the operator (PN). Also, another secondary outcome measured was root maturation (binary outcome detected with periapical x-ray and assessed by the same assessors of radiographic outcomes (NM and AE). The overall inter-observer agreement for root maturation was (Kappa= 0.854, SE of kappa = 0.215, 95% CI 0.353 to 1.000) and was considered "very good".

Sample size calculation:

Current study started with 22 FPMs of the outpatients attending the Pediatric Dentistry and Dental Public Health department clinic, Faculty of Dentistry, Cairo University, and were allocated to the two treatment groups equally.

We calculated the current study sample size using "sealedenvelop.com", the online sample size calculator (Sealed Envelope Ltd. 2012). Our clinical trial was "equivalence", as the null hypothesis was that MTA and TLC are similar. The nature of our outcomes was "Binary" or success/failure. So, we selected the Binary/equivalence calculator. This calculator required four percentages to calculate the sample size. The first reading was "Significance level (alpha)" and the second one was "Power (1-beta)". Typical controlled trials set the statistical significance level at 0.05 or 0.01 and the power at 80% or 90% [17]. So, we selected a 0.05 significance level and 90% power. The third reading was "Percentage 'success' in both standard and new treatment group." We calculated the success rate of MTA from previous studies that used MTA pulpotomy in young permanent carious

molars at the time of trial initiation. The average success rate from previous studies was 98.2 %. The null hypothesis was that TLC had a similar success rate as MTA. The fourth reading was "Equivalence limit, d", which defines the difference between the percentages of patients that had success or failure in both MTA and TLC groups within which we accept that the two medicaments are equivalent. We assumed that a 20% difference was acceptable.

After we set the previous four percentages, the site calculated that: "If there is truly no difference between the standard and experimental treatment, then 20 teeth are required to be 90% sure that the limits of a two-sided 90% confidence interval will exclude a difference between the standard and experimental group of more than 20%". With an estimated 10% annual dropout during follow-up [14, 18], we added two teeth to overcome this expected dropout.

Randomisation,

-Allocation concealment:

Allocation was concealed till the treatment visit to overcome performance bias. At the recruitment visit, the participants were asked to select an envelope from the 22 closed white envelopes and his name written on it. After performing hemostasis, the envelopes were opened at the treatment visit to allocate the participating tooth to the MTA/TLC group.

-Sequence generation:

By shuffling the envelopes and selecting randomly from them.

-Implementation:

The principal investigator (PN) and, with the help of (AE) they both generated the allocation sequence, enrolled participants, and assigned participants to intervention groups. NM and AE carried out almost all the outcome assessments.

Blinding

MTA and TLC are different in shape and manipulation, so they are apparent to the patient, parent and operator. However, performance bias was minimised by allocation concealment and using a standard technique following manufacturer instructions. Outcome assessors of the radiographic success rate could not be blinded, too, as there is a detectable difference in the radiopacity between MTA and TLC. We tried to minimise detection bias by detecting all the predetermined outcomes at the follow-up visits, and the assessors were pre-calibrated.

Statistical analysis:

The inter-examiner agreement was calculated using Kappa scores. The strength of agreement is considered 'very good' as discussed in the outcome section. We used the online calculator (<https://www.pedro.org.au/wp-content/uploads/Ccalculator.xls>) to calculate relative risk (RR) and absolute risk reduction (ARR) for survival rate (clinical and radiographic)

and root maturation outcomes. The following formulas were used at that site:

$$RR = (\text{Prob. of outcome in treatment group}) / (\text{Prob. of outcome in control group})$$

$$ARR = (\text{Prob. of outcome in unexposed group}) - (\text{Prob. of outcome in exposed group})$$

Confidence intervals for RR and ARR were calculated using the Wald method. Statistical analyses were performed using R version 4.0.2. Age, gender, and other potential confounders were adjusted in regression models [19]. The method used to calculate a confidence interval for a proportion is the Wilson score method without continuity correction. The method used to calculate a confidence interval for the difference between two proportions is the Newcombe-Wilson method without continuity correction. Also, the average time of application was calculated and published in the preliminary report after 1-year [6]. The significance level was set at $p < 0.05$ within all tests.

Ethical considerations:

The protocol and the specific informed consent forms (local Arabic language and English versions) were reviewed, approved and agreed upon by the Research Ethics Committee at the Faculty of Dentistry, Cairo University.

The patient's complete, detailed personal data was written on a separate sheet with the patient's serial number for further contact with the patient. Those sheets can be only seen by the operators and were stored with the corresponding author to assure the confidentiality of the participants and data protection. Consent in the local Arabic language was obtained from the legal guardians of the participants to use their data in the current study, and data will be maintained and secured for 10 years after the trial for further follow-up.

Cases that didn't respond to pulpotomy, unfortunately, and showed only radiographic failure, were followed up to see if they would heal or fail clinically and if the root apex would close. One of the cases (Fig. 2) of lower right FPM with apical radiolucency and no clinical complaint was followed up till the apex closed, then was referred to root canal treatment; however, the root canal quality was not good. On the same patient's left side (Fig. 2), FPM caused pain to the patient, and he went to extract it with another dentist. Luckily, the 2nd permanent molar moved bodily into FPM's space, coinciding with the UK national clinical guidelines for "the Extraction of FPMs in Children" recommendations [20]. Also, cases not indicated for extraction according to UK guidelines were treated with revascularisation, as shown in (Fig. 3) with a good result at 5-years, although the apex closed shorter than the contralateral FPM.

At the 5 years visit, some patients need further treatment, such as orthodontic treatment (Fig. 4), remake restoration (Fig. 3) or even crowns,

root canal treatment (Fig. 2) or extraction (Fig. 5). Each patient was provided with all treatments they need by the investigators. Consent was also obtained from the patients to use their data anonymously and restore it for 10 years if needed at future follow-ups.

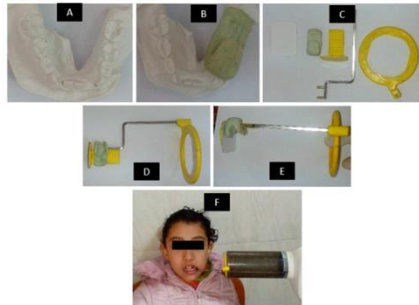


Figure 1: Acrylic stent and periapical radiograph standardization method:

- A: Gypsum Cast after taking impression to patients to construct their own acrylic stent
- B: The custom made acrylic stent used to standardise the radiographs position
- C: Conventional radiographic film, acrylic stent, and the 3 parts of XCP cone positioner
- D & E: occlusal and lateral view of the acrylic stent assembled with the XCP cone positioner
- F: Patient setting with the acrylic stent and the cone positioner, and the cone directed in perpendicular angle to the teeth for paralling technique

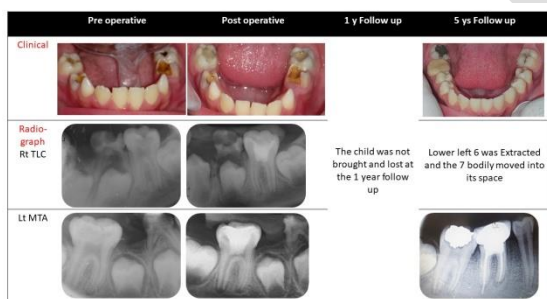


Figure 2: Case 1 showing Clinical and radiographic follow up photos at 1 and 5 years for lower right FPM treated with MTA and lower left FPM treated with TLC.

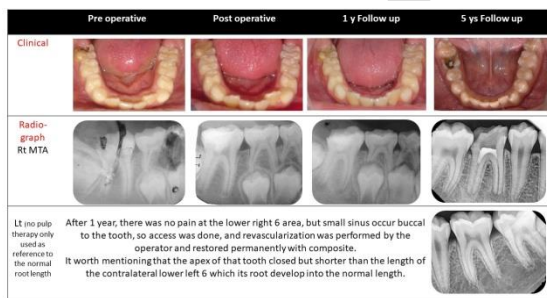


Figure 3: Case 2 showing Clinical and radiographic follow up photos at 1 and 5 years for lower right FPM treated with MTA.

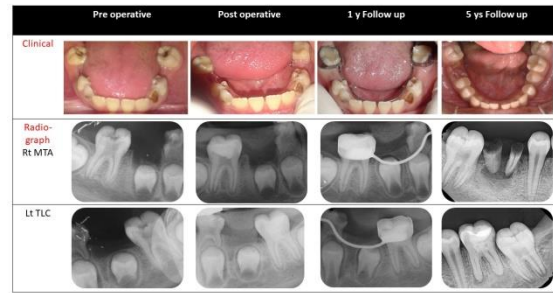

Figure 4: Case 3 showing Clinical and radiographic follow up photos at 1 and 5 years for lower right FPM treated with TLC and lower left FPM treated with MTA.

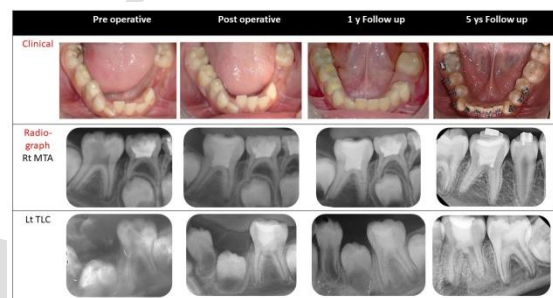

Figure 5: Case 4 showing Clinical and radiographic follow up photos at 1 and 5 years for lower right FPM treated with MTA and lower left FPM treated with TLC.

RESULTS

Participant flow and Recruitment

In the preliminary report, after 1-year, only 20 patients continued to follow up, and the dropout was 2 patients, one per each group. After 5-years, another patient dropped out of the TLC group (he lost follow-up at 12 months and extracted one of the participating teeth). So, the total number of patients who dropped out after 5 years was 3. Dropped-out patients were considered a failure as the worst-case scenario in the statistical analysis, and the 22 patients' data were analysed using the Intention-to-treat analysis (ITT). ITT is a method for analysing results in a prospective randomised study where all randomised participants are included in the statistical analysis and analysed according to the group they were initially assigned, regardless of what treatment (if any) they received [21]. A participant flow diagram is displayed in (Fig. 6), according to the CONSORT statement 2010 [7], and all results are shown in (Tab. 1) after 1 year and (Tab. 2) after 5 years.

Baseline data

The mean age of the patients was 7.7 years (6 - 8.5 years). The female-male ratio was 11: 9 and participant. There was no statistically significant difference between the two groups.

Numbers analysed

After 1 and 5 years, all participants in both groups were analysed using ITT and considered teeth lost to follow up as a failure in the worst-case scenario [21].

Table. 1: MTA and TLC pulpotomy outcomes after 1 year

Outcome after 1 year		+ out come in control MTA n. analyzed =11 (1 drop out) *	AR MTA (95% CI)	+ out come in intervention TLC n. analyzed =11 (1 drop out) *	AR TLC (95% CI)	ARR (95% CI)	RR (95% CI)
a) Clinical Survival rate	1-spontaneous pain	1	0.09 (0.02 to 0.38)	7	0.64 (0.35 to 0.85)	-0.55 (-0.77 to -0.14)	7 (1.02 to 47.08)
	2-swelling	1	0.09 (0.02 to 0.38)	5	0.45 (0.21 to 0.72)	-0.36 (-0.64 to 0.01)	5 (0.69 to 36.13)
Overall clinical success rate		10 (90.9%)	0.9 (0.62 to 0.98)	4 (36.36%)	0.36 (0.15 to 0.65)	0.55 (0.14 to 0.77)	0.4 (0.18 to 0.89)
b) Radiographic success rate	1-periapical radiolucency	1	0.09 (0.02 to 0.38)	9	0.82 (0.52 to 0.95)	-0.72 (-0.88 to -0.32)	9 (1.41 to 17.76)
	2-internal/ external root resorption	1	0.09 (0.02 to 0.38)	2	0.18 (0.05 to 0.48)	-0.09 (-0.40 to 0.22)	2 (0.21 to 18.98)
Overall radiographic success		9 (81.81%)	0.82 (0.52 to 0.95)	2/11 (18.18%)	0.18 (0.05 to 0.48)	0.64 (0.22 to 0.82)	0.22 (0.061 to 0.8)
c) Root maturation		10	0.90 (0.62 to 0.98)	8	0.73 (0.43 to 0.90)	0.18 (-0.15 to 0.48)	0.8 (0.53 to 1.2)

Table. 2: MTA and TLC pulpotomy outcomes after 5 years

Outcome after 5 years		+ out come in control MTA n. analyzed =11 (1 drop out)*	AR MTA (95% CI)	+ out come in intervention TLC n. analyzed =11 (2 dropouts one of them extracted)*	AR TLC (95% CI)	ARR (95% CI)	RR (95% CI)
a) Clinical Survival rate	1-spontaneous pain	3	0.27 (0.10 to 0.57)	8	0.73 (0.43 to 0.90)	-0.45 (-0.7 to -0.04)	2.6 (0.9 to 7.47)
	2-swelling	1	0.09 (0.02-0.38)	5	0.45 (0.21 to 0.72)	-0.36 (-0.64 to 0.01)	5 (0.69 to 36.13)
Overall clinical success rate		8/11 (72.72%)	0.73 (0.43 to 0.9)	3/11 (27.27%)	0.27 (0.1 to 0.57)	0.45 (0.04 to 0.7)	0.38 (0.13 to 1.05)
b) Radiographic success rate	1-periapical radiolucency	3	0.27 (0.10 to 0.57)	9	0.82 (0.52 to 0.95)	-0.54 (-0.76 to -0.13)	3 (1.09 to 8.19)
	2-internal/ external root resorption	1	0.09 (0.02 to 0.38)	2	0.18 (0.05 to 0.48)	-0.09 (-0.4 to 0.22)	2 (0.21 to 18.98)
Overall radiographic success		8/11 (72.72%)	0.73 (0.43 to 0.9)	2/11 (18.18%)	0.18 (0.05 to 0.48)	0.55 (0.13 to 0.76)	0.25 (0.07 to 0.92)
c) Root maturation		10	0.90 (0.62 to 0.98)	9	0.82 (0.52 to 0.95)	0.09 (-0.22 to 0.40)	0.9 (0.64 to 1.26)

MTA= Mineral trioxide aggregate TLC= TheraCal LC * dropout cases were included at the statistical analysis (intention to treat analysis) and considered as failure in the worst-case scenario

+ out come in control/intervention = positive outcome in control/intervention

AR = Absolute risk

95% CI= 95% Confidence interval CI in green color =Statistically significant CI in blue color =non-statistically significant

ARR= Absolute Risk Reduction ARR is considered statistically significant when the value of 0.0 is not in the 95% CI

RR= Relative Risk RR is considered statistically significant when the value of 1.0 is not in the 95% CI

Outcomes and estimation

Primary outcome

Using Absolute-risk/Absolute-risk reduction (ARR), relative risk (RR) and their 95% confidence intervals (95% CI), the following results were obtained:

All results are presented at Table 1 and Table 2 for the 1 and 5 years respectively. An example of the results interpretation is; clinically, the risk of spontaneous pain at 1-year was 7-times higher in the TLC group than in the MTA group (RR=7 and 95% CI= 1.02 to 47.08), which was statistically significant. The risk of spontaneous pain increased by 55% when using TLC pulpotomy rather than MTA pulpotomy (ARR= -0.55 and 95% from -0.77 to -0.14) which was statistically significant. However, the risk of spontaneous pain at 5-years was 2.6-times higher in the TLC group than the MTA group (RR=2.6 and 95% CI= 0.9 to 7.47), which was not statistically significant. The risk of spontaneous pain increased by 45% when using TLC pulpotomy rather than MTA pulpotomy (ARR= -0.45 and 95% from -0.7 to -0.04) which was statistically significant.

The final survival rate (clinical and radiographic) for MTA was 90.9% and 72.72% after 1-year and 5-years respectively, while unfortunately, the final survival rate for TLC was 18.18% both after 1-year and 5-years.

Secondary outcomes:

The probability of root maturation was 20% and 10% less in TLC group than in MTA group at 1-year and 5-years, respectively. Surprisingly, 90% of teeth show complete apical closure even if pulp necrosis occurred.

The average time-lapse till final restorations in both groups was reported in the preliminary report at 12 months, and it was 20 minutes and 6.8 minutes for both MTA and TLC, respectively [6].

DISCUSSION

The current study compared two pulp capping materials, MTA and TLC, to determine if TLC could serve as an inexpensive alternative to MTA with faster-controlled setting time. The first article which caught our attention to this possible similarity of the two materials was "Chemical–physical properties of TheraCal, a novel light-curable MTA-like material for pulp capping" [4] by Gandolfi et al. in 2012 and TLC was introduced as a promising pulp-capping biocompatible material.

We hypothesised that a good radiographic sign for pulpal healing after VPT is the formation of the hard tissue barrier. This hard tissue barrier was proved to be complete under TLC after 28 days [22], and this could suggest that if a failure occurs due to incomplete hard tissue barrier, it will happen after one month. In the current study, radiographic failure was evident during the 3rd month of follow-up. We anticipated that if a tooth survived one year without any clinical or radiographic failure, this could be a good sign that the tooth would survive longer symptom-free [12]. However, we plan to conduct follow-ups after trial termination for a longer period if feasible, and we tried to recall patients yearly. However, the COVID-19 pandemic hindered those attempts till the pandemic ended, so we recalled patients 5 years later.

The current study used the acrylic stent to standardise the radiograph's position at the follow up visits and help young children keep the film in the correct position during radiograph filming [9]. However, the most critical drawback of the acrylic stent is that it needs continuous adjustment with the child's growth and occlusion change.

The used film positioner helps increase dental radiograph images' dimensional accuracy. The XCP device has a collimator ring parallel with the film-holding plane of the X-ray film holder. This positioning helps to align the plane of the unseen, intraorally located X-ray film parallel with the plane of the cross-section of the X-ray beam [23], as young children cannot hold the film at the correct position. However, those stents were not needed on the 5-year visit as the participants were old enough to properly hold the film and the holder at the correct position. Also, the stents won't fit at the exact place as children's occlusion completely changed after 5 years.

For clinical interpretation, it is helpful to report both the RR and the risks per group with the ARR, so the current study used both. In addition, it is important to report their 95% confidence interval to give information about the precision of the result and the statistical significance. RR is considered statistically significant when the value of 1.0 is not in the 95% confidence interval. In contrast, ARR is considered statistically significant when the value of 0.0 is not in the 95% confidence interval [11].

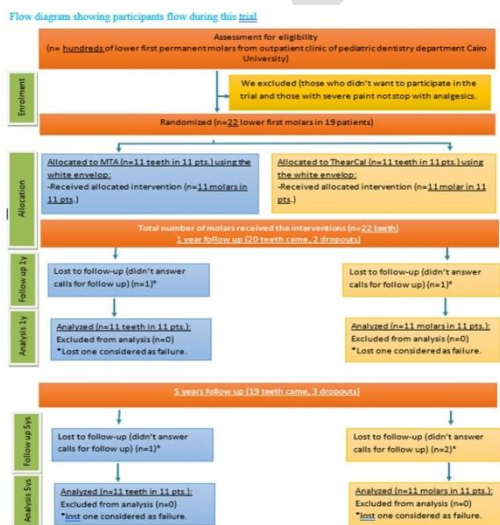


Figure 6: CONSORT Statement 2010 participants flow diagram till 5 years.

WHAT IS RISK? In a group free of the outcome of interest at the start of observation, risk is the ratio of the number of subjects developing the outcome of interest over a specific period to the total number of subjects followed over that same period of time. The sole reporting of RR has a major drawback because it may obscure the magnitude of the effect of an intervention. When RR is used to present a treatment's effects, it can make the treatment seem better than it actually is. An ARR provides the most information because it expresses what they can expect from specific treatment options. We followed the CONSORT Statement 2010, which recommended that 'For binary outcomes, presentation of both absolute and relative effect sizes is recommended' [14].

RR measures the probability of an event or outcome occurring in a treatment group compared to the probability of an event or outcome occurring in a control group. It is calculated as; $RR = (\text{Prob. of event in intervention group}) / (\text{Prob. of event in control group})$, and the interpretation of its values is; $RR < 1$ means, the event is less likely to occur in the intervention group, $RR = 1$ means, the event is equally likely to occur in each group and $RR > 1$ means, the event is more likely to occur in the intervention group [24].

ARR (*risk difference*) is the absolute difference in outcomes between one group (the control group), represented by the MTA-group and the group receiving intervention treatment, represented by the TLC-group. The percentage tells you how much the risk of adverse events (represented by failure in any of the outcomes measured in the current study) decreases if a specific intervention happens (represented as MTA/TPT pulpotomy). The following formula; $ARR = (\text{Control Event Rate}) - (\text{Experimental Event Rate})$ [24] within the 95% CIs. ARR is a way of measuring the size of a difference between two treatments. It simply tells you how much better or worse one treatment is compared with the other at reducing a particular outcome regarding the actual number of teeth experienced. If the outcome is treatment failure, ARR is calculated by subtracting the risk of treatment failure in the intervention group from the risk of treatment failure in the control group. ARR can be expressed as a percentage or a decimal number.

A positive ARR means that the intervention (represented by TLC) reduces the risk of the outcome (ex., spontaneous pain). In contrast, a negative ARR means that the intervention increases the risk of the outcome. So, $ARR = -0.55$ means that TLC pulpotomy increases the risk of spontaneous pain by 55%, and since 95% CI does not include the score 0,0, the result is statistically significant.

ITT is used in current study analysis as it allows the investigator (or consumer of the medical

literature) to draw accurate (unbiased) conclusions regarding the effectiveness of an intervention. This method preserves the benefits of randomisation. If an intervention is truly effective, ITT analysis will provide an unbiased estimate of the efficacy of the. It means analysing patients according to which group they were initially assigned. A process that has once been described as "once randomised, always analysed". Removing patients from either arm of the study disturbs the prognostic balance afforded by randomisation, leading to post-randomisation bias as attrition bias. Data from every subject in the trial are included in the data analysis, regardless of compliance, deviation from the treatment protocol, withdrawal, or any other event after randomisation [21].

The results of the current trial favoured MTA as a pulpotomy treatment rather than the TLC, which showed unfavourable results at 1 and 5 years. Accurate diagnosis of pulp inflammatory status before treatment could affect the results of pulpotomy. However, several studies have reported the successful outcome of VPT for irreversible pulpitis [14, 25, 26], and this would exclude misdiagnosis of pulp inflammation from the causes of pulpotomy failure.

Another cause of pulpotomy failure would be the formation of extra-pulpal blood clots. It must be removed before any final seal is placed as it prevents direct contact of the capping material with the pulp and interferes with its action. Also, it could act as a bacterial substrate or its degradation products and may interfere with healing. In the current trial, we ensured the blood clot removal using continuous irrigation of pulp stem with a saline stream, excluding this reason as a failure cause.

Removal of caries and prevention of leakage is also crucial in any VPT. Overlying tight-sealed restoration decreases bacterial leakage from the restoration-dentin interface. Considering the incompletely erupted molars and the limited mouth opening of the children, the conventional composite could be the restoration of choice. However, after 5 years of follow-up, the survival rate of composite restorations was questionable.

Clinically, the risks of spontaneous pain and swelling at 1-year were 7 and 5 times more in the TLC group than in the MTA group. Results may be interpreted as clinical failure mainly expressed as spontaneous pain rather than swelling. After 5 years, the risk of pain in the TLC group decreased to 2.5 times that in the MTA group, and this may be due to the early retreatment of cases suffered from pain at the time preceding the 5-years visit. Swelling risk, however, didn't change after 5 years, and this supports our hypothesis that swelling may or may not occur later after pain.

Radiographically, the risks of periapical radiolucency and external root resorption are 9 and

2 times more in the TLC group compared to the MTA group, respectively, after 1-year. Results could be interpreted that the radiographic failure is primarily expressed by periapical radiolucency or abscess rather than external root resorption. External root resorption may or may not follow apical radiolucency later on [6]. After 5-years, the risk of periapical radiolucency decreased to 3 times more in the TLC group than the MTA group, and this could also be attributed to the early retreatment for cases that showed periapical radiolucency associated with pain.

After 1-year, overall clinical and radiographic success rates for MTA were 90.9%. The MTA results coincide with previous studies that showed a very high success rate of MTA pulpotomy in cariously exposed young permanent molars [14, 27]. However, TLC's overall clinical and radiographic success rates were 18%. Higher success rates were expected, considering the results of previous studies. Our results did not coincide with the previous VPT trial using TLC [12]. This trial, unlike ours, gives a success rate of 66.6% in the TLC alone group.

After 5-years, the overall clinical and radiographic success rate for MTA was 90.9%. The MTA results coincide with previous studies that showed a very high success rate of MTA pulpotomy in cariously exposed young permanent molars [14, 18]. However, TLC's overall clinical and radiographic success rates were 18%. Higher success rates were expected, considering the results of previous studies. Our results did not coincide with the previous VPT trial using TLC [12]. This trial, unlike ours, gives a success rate of 66.6% in the TLC alone group.

In the current study, the significantly higher success rate of MTA pulpotomy over the TLC may be attributed to the chemical and physical properties, antibacterial activity, biocompatibility, and desirable sealing properties of MTA. Sealing ability may be questionable considering the inherent shrinkage of the resinous part of the TLC. A question may arise if TLC is toxic to pulp tissue. However, *in vitro* study [28] compared TLC with two other different resin-based light-cured liners on the culture of pulp cells. They found that TLC is less toxic to pulp cells than other liners.

Regarding the probability of root maturation, it is 20% less in the TLC group than in the MTA group, and this result is statistically insignificant. Results may indicate that root maturation may continue regardless of the status of the pulp or periapical tissues of the permanent teeth. This finding may coincide with the high success rates obtained in the clinical trials on pulpotomy of teeth with irreversible pulpitis or even apical periodontitis [25, 29].

The mechanical properties of pulp capping materials may affect their resistance to destruction

during the placement of final restorative material or while supporting an overlying restoration over a period of time. TLC had a higher early strength to potentially resist destruction during immediate installation of a final restorative material than MTA [30]. This excludes the probability that TLC was affected during the installation of the final restoration even after due to forces of mastication.

A distinction must be made between the pulp therapy's failure and the overlying restoration's failure [31]. Hypotheses may be made that leakage may occur later on after pulpotomy treatment has succeeded, especially since the overlying restoration is composite with its inherent property of polymerisation shrinkage. Maybe if the final restoration was crown, the success rate might increase, but previous study on VPT with TLC also used composite as final restoration and gave better results than ours [32].

Interestingly, the MTA group was unaffected by any of the previously mentioned causes of failure after 1-year. Studies conducted on MTA pulpotomy used composite [33], amalgam and crowns, and they all gave superior results [27, 34]. This may be attributed to the ability of MTA to prevent microleakage due to its capacity to expand during setting [35, 36]. However, another study found that resin composite restorations had a higher failure risk than stainless steel crowns at 111 months follow up after pulpotomy of permanent molars [37], and this coincides with our results after 5-years.

The average time-lapse till final restoration was more than 3 times longer in the MTA group than in the TLC group, as mentioned in the preliminary 1-year report. This could be attributed to the controlled setting time of TLC using light cure. However, nowadays, setting time of MTA is accelerated to reach 9.3 min, which corresponds to a time close to the point where the material can be overlaid with another restorative material to give a final restoration [38]. The controlled short setting time would have been an excellent advantage for TLC to decrease the chair time for children, increasing their cooperation. However, its clinical and radiographic success rates were not promising.

TLC has controversial biological properties, which hinder its recommendation as pulp capping materials [39], and that's why Bisco Inc., the manufacturer of TLC, introduced a new product called TheraCal PT (TPT) in May 2019. The manufacturer claims that TPT is most useful for pulpotomies (PT is short for Pulp Therapy) [40]. This was more like a hidden admission from the producing company that TLC had some drawbacks that needed improvement in the new product, TPT. Limitations:

The methodological limitation of this clinical trial concerns the blindness of the clinician as one operator performed all the procedures, but we

compensated for it by allocation concealment. The operator didn't know which pulp dressing material would be applied till the pulpotomy procedure was completed and bleeding control was achieved.

Researchers may also consider the sample size small. Another study could be carried out with a higher power of 95% and a lower accepted difference (less than 20). However, the results of TLC pulpotomy were not promising.

Generalisability:

Generalisation of current trial results should be performed cautiously through a limited number of populations first to evaluate the treatment and review the outcomes since the sample size would be considered small. It may describe the trial as a pilot study. Further studies with larger sample sizes might be needed for more conclusive results; however, TLC pulpotomy results were not promising.

CONCLUSION

The current study favours the use of MTA pulpotomy as a less technique-sensitive procedure to treat cariously exposed young permanent molars in children. The present research results don't encourage TLC pulpotomy due to its low success rate, which is a highly technique-sensitive procedure.

MTA pulpotomy is a reliable procedure with consistent outcomes.

TLC as a pulpotomy medicament does not show promising results.

FUNDING

This research received no external funding.

CONFLICTS OF INTEREST

The authors declare no conflict of interest.

REFERENCES

1. Camoni, N., et al., Partial Pulpotomy in Young Permanent Teeth: A Systematic Review and Meta-Analysis. *Children (Basel)*, 2023. 10(9)
2. Singh, D.V.V., S. Taneja, and S. Fatima, Comparative evaluation of treatment outcome of partial pulpotomy using different agents in permanent teeth-a randomized controlled trial. *Clin Oral Investig*, 2023. 27(9): p. 5171-5180.
3. Edwards, D., et al., Preserving pulp vitality: part two - vital pulp therapies. *Br Dent J*, 2021. 230(3): p. 148-155.
4. Gandolfi, M.G., F. Siboni, and C. Prati, Chemical-physical properties of TheraCal, a novel light-curable MTA-like material for pulp capping. *International Endodontic Journal*, 2012. 45(6): p. 571-9.
5. Poggio, C., et al., In vitro antibacterial activity of different pulp capping materials. *J Clin Exp Dent*, 2015. 7(5): p. e584-8.
6. Nagi, P., Waly, N., Elbardissy, A., Khalifa, M., The Effect of Pulpotomy Using Resin-Modified Calcium Silicate versus MTA on Survival Rate of Cariously-Exposed Vital Young Permanent Molars: A Randomized Clinical Trial 2017.
7. Schulz, K.F., D.G. Altman, and D. Moher, CONSORT 2010 statement: Updated guidelines for reporting parallel group randomised trials. *J Pharmacol Pharmacother*, 2010. 1(2): p. 100-7.
8. American Academy of Pediatric Dentistry, Pulp therapy for primary and immature permanent teeth. *The Reference Manual of Pediatric Dentistry*. Chicago, Ill.: American Academy of Pediatric Dentistry. 2023:457-65.
9. Sadek, S.A., et al., Using acrylic customized X-ray positioning stents for long-term follow-up studies. *Saudi Dent J*, 2020. 32(3): p. 120-128.
10. McCabe, P., Revascularization of an immature tooth with apical periodontitis using a single visit protocol: a case report. *International Endodontic Journal*, 2015. 48(5): p. 484-97.
11. George ,R., Is partial pulpotomy in cariously exposed posterior permanent teeth a viable treatment option? *Evid Based Dent*, 2020. 21(3): p. 112-113.
12. Cengiz, E. and H.G. Yilmaz, Efficacy of Erbium, Chromium-doped:Yttrium, Scandium, Gallium, and Garnet Laser Irradiation Combined with Resin-based Tricalcium Silicate and Calcium Hydroxide on Direct Pulp Capping: A Randomized Clinical Trial. *J Endod*, 2016. 42(3): p. 351-5.
13. BISCO, I., TheraCal LC Resin-Modified Calcium Silicate Pulp Protectant/Liner Instructions for Use. 2017.
14. Asgary, S. and M.J. Eghbal, Treatment outcomes of pulpotomy in permanent molars with irreversible pulpitis using biomaterials: a multi-center randomized controlled trial. *Acta Odontol Scand*, 2013. 71(1): p. 130-6.
15. Smail-Faugeron ,V., et al., Development of a core set of outcomes for randomized controlled trials with multiple outcomes--example of pulp treatments of primary teeth for extensive decay in children. *PLoS One*, 2013. 8(1): p. e51908.
16. Simon, S., et al., Should pulp chamber pulpotomy be seen as a permanent treatment? Some preliminary thoughts. *International Endodontic Journal*, 2013. 46(1): p. 79-87.
17. Wittes, J., Sample size calculations for randomized controlled trials. *Epidemiol Rev*, 2002. 24(1): p. 39-53.
18. Nosrat, A., A. Seifi, and S. Asgary, Pulpotomy in caries-exposed immature permanent molars using calcium-enriched mixture cement or mineral trioxide aggregate: a randomized clinical trial. *International Journal of Paediatric Dentistry*, 2013. 23(1): p. 56-63.
19. Yan, F., M. Robert, and Y. Li, Statistical methods and common problems in medical or biomedical science research. *Int J Physiol*

- Pathophysiol Pharmacol, 2017. 9(5): p. 157-163.
20. Cobourne, M.T., A. Williams, and M. Harrison, National clinical guidelines for the extraction of first permanent molars in children. *Br Dent J*, 2014. 217(11): p. 643-8.
 21. McCoy, C.E., Understanding the Intention-to-treat Principle in Randomized Controlled Trials. *West J Emerg Med*, 2017. 18(6): p. 1075-1078.
 22. Cannon, M., et al., Primate pulpal healing after exposure and TheraCal application. *J Clin Pediatr Dent*, 2014. 38(4): p. 333-7.
 23. Mamoun, J.S., Assembly and clinical use of the XCP dental x-ray film holder and orientation devices in dentistry. *Dent Assist*, 2011. 8 : (1)0p. 8, 10, 12-4 passim.
 24. Jiroutek, M.R. and J.R. Turner, Relative vs absolute risk and odds: Understanding the difference. *J Clin Hypertens (Greenwich)*, 2019. 21(6): p. 859-861.
 25. Asgary, S., M. Nourzadeh, and M.J. Eghbal, Miniature Pulpotomy of Symptomatic Mature Permanent Teeth: A Report of Two Cases. *Iran Endod J*, 2016. 11(1): p. 75-8.
 26. Kahler, B., et al., Vital pulp therapy for permanent teeth with diagnosis of irreversible pulpitis: biological basis and outcome. *Aust Dent J*, 2023. 68 Suppl 1: p. S110-S122.
 27. Chailertvanitkul, P., et al., Randomized control trial comparing calcium hydroxide and mineral trioxide aggregate for partial pulpotomies in cariously exposed pulps of permanent molars. *International Endodontic Journal*, 2014. 47 : (9) p. 835-42.
 28. Hebling, J., et al., Cytotoxicity of resin-based light-cured liners. *Am J Dent*, 2009. 22(3): p. 137-42.
 29. Barnkgkei, I.H., E.S. Halboub, and R.S. Alboni, Pulpotomy of symptomatic permanent teeth with carious exposure using mineral trioxide aggregate. *Iran Endod J*, 2013. 8(2): p. 65-8.
 30. Nielsen, M.J., et al., Mechanical properties of new dental pulp-capping materials. *Gen Dent*, 2016. 64(1): p. 44-8.
 31. Akhlaghi, N. and A. Khademi, Outcomes of vital pulp therapy in permanent teeth with different medicaments based on review of the literature. *Dent Res J (Isfahan)*, 2015. 12(5): p. 406-17.
 32. Parvin, M.K., et al., Evaluation of Radiological Outcomes of Theracal Light Cured (TLC) And Calcium Hydroxide As Indirect Pulp Capping Agents In The Treatment Of Deep Carious Lesion Of Permanent Molar Teeth. *Mymensingh Med J*, 2018. 27(4): p. 859-865.
 33. Nosrat, A., A. Seifi, and S. Asgary, Pulpotomy in caries-exposed immature permanent molars using calcium-enriched mixture cement or mineral trioxide aggregate: a randomized clinical trial. *Int J Paediatr Dent*, 2013. 23(1): p. 56-63.
 34. Qudeimat, M.A., K.M. Barrieshi-Nusair, and A.I. Owais, Calcium hydroxide vs mineral trioxide aggregates for partial pulpotomy of permanent molars with deep caries. *Eur Arch Paediatr Dent*, 2007. 8(2): p. 99-104.
 35. Torabinejad, M., et al., Bacterial leakage of mineral trioxide aggregate as a root-end filling material. *J Endod*, 1995. 21(3): p. 109-12.
 36. Torabinejad, M., et al., Comparative investigation of marginal adaptation of mineral trioxide aggregate and other commonly used root-end filling materials. *J Endod*, 1995. 21(6): p. 295-9.
 37. Ngamthum, I., et al., Outcomes of coronal pulpotomy on permanent first molars in children: a retrospective cohort study. *Clin Oral Investig*, 2023. 27(12): p. 7473-7488.
 38. Ha, W.N., et al., Methodologies for measuring the setting times of mineral trioxide aggregate and Portland cement products used in dentistry. *Acta Biomater Odontol Scand*, 2016. 2(1): p. 25-30.
 39. Jeanneau, C., et al., Light-cured Tricalcium Silicate Toxicity to the Dental Pulp. *J Endod*, 2017. 43(12): p. 2074-2080.
 40. Rodriguez-Lozano, F.J., et al., Cytocompatibility and bioactive properties of the new dual-curing resin-modified calcium silicate-based material for vital pulp therapy. *Clin Oral Investig*, 2021. 25(8): p. 5009-5024.