


# INTERNATIONAL JOURNAL OF MEDICAL ARTS



Volume 5, Issue 12, December 2023

<https://ijma.journals.ekb.eg/>




Print ISSN: 2636-4174

Online ISSN: 2682-3780





Available online at Journal Website  
<https://ijma.journals.ekb.eg/>  
 Main Subject [Plastic Surgery]



## Original Article

### Evaluation of Morphological and Histological Changes in Transplanted Hair Follicles

Mahmoud Mohamed Mahmoud Khalil <sup>\*1</sup>, Ahmed Maged El Mofty <sup>1</sup>, Mahmoud Abdelfattah Nasef <sup>1</sup>, Mohammed Abdoh Eisa <sup>2</sup>, Mostafa Khairy <sup>3</sup>

<sup>1</sup> Department of Plastic and Reconstructive Surgery, Faculty of Medicine, Al-Azhar University, Cairo, Egypt

<sup>2</sup> Department of Histology and Cell Biology, Faculty of Medicine, Al-Azhar University, Cairo, Egypt

<sup>3</sup> Department of Dermatology, Faculty of Medicine, Al-Azhar University, Cairo, Egypt

## ABSTRACT

### Article information

Received: 14-12-2023

Accepted: 16-01-2024

DOI:  
10.21608/IJMA.2024.257710.1897.

\*Corresponding author

Email:  
[dr\\_maghraby1188@yahoo.com](mailto:dr_maghraby1188@yahoo.com)

**Citation:** Khalil MMM, El Mofty AM, Nasef MA, Eisa MA, Khairy M. Evaluation of Morphological and Histological Changes in Transplanted Hair Follicles. IJMA 2023 December; 5 [12]: 3958-3968. doi: 10.21608/IJMA.2024.257710.1897.

**Background:** For the management of extensive loss of hair, the follicular unit extraction technique [FUE] procedure for hair transplantation is a popular operative operation.

**The Aim of the work:** The goal of this investigation was to evaluate the morphological and histological changes in the transplanted hair follicles [HFs] after FUE for cases of androgenetic alopecia [AGA].

**Patients and Methods:** It's a prospective interventional study that was carried out at Al Azhar University Hospitals between May 2018 and May 2023. In this investigation, 15 patients, ages 25 to 60, who were candidates for FUE hair transplantation and suffered from androgenetic alopecia were included. After 10–14 months following the procedure, the morphological and histological alterations in the transplanted FUs were contrasted with those of the native donor follicles.

**Results:** There was a substantial variation [p-value = 0.002] between the donor and recipient sites regarding sebaceous gland degeneration. The donor site in all studied patients [100%] had no Arrector pili muscle degeneration while at recipient site, there were 5 patients [33.3%] with no Arrector pili muscle degeneration, four patients [26.7%] with [+] Arrector pili muscle degeneration, four patients [26.7%] with [++] Arrector pili muscle degeneration and two patients [13.3%] with [+++] Arrector pili muscle degeneration. Regarding outer root sheath degeneration, this data demonstrates a very substantial variation [p-value < 0.001] between the donor and recipient sites. Regarding inner root sheath degeneration, this data demonstrates a very substantial variation [p-value < 0.001] between the donor and recipient sites.

**Conclusion:** The effect of the FUE procedure on the transplanted follicles is obvious morphologically and histologically, so it needs more interest, especially in the long run.

**Keywords:** Follicular unit extraction; Hair transplantation; Androgenetic alopecia.



This is an open-access article registered under the Creative Commons, ShareAlike 4.0 International license [CC BY-SA 4.0] [<https://creativecommons.org/licenses/by-sa/4.0/legalcode>].

## INTRODUCTION

When it comes to character and identity, hair is crucial. The critical roles of hair shafts include thermal regulation, sensory information gathering, defence against stress from the surroundings, social interaction, and disguise. Approximately 5 million hair follicles [HF] are present in each human, of which 80,000–150,000 are found on the scalp<sup>[1]</sup>.

The general word for loss of hair is alopecia, which refers to a decrease in noticeable hair. Alopecia comes in a lot of forms. Androgenetic alopecia [AGA] is the most prevalent type of alopecia that can be surgically treated<sup>[2]</sup>. By the time they turn 70, it's expected that between 70% and 80% of white men will have noticeable androgen-influenced alopecia<sup>[3]</sup>.

Follicular units [FUs], naturally occurring hair clusters, are the foundation for today's hair transplantation. These FUs can be obtained by strip harvesting or extracting them using a tiny punch, typically between 0.8 and 1.2 mm in diameter<sup>[4]</sup>. The more established of the two methods, follicular unit transplantation [FUT], was initially reported in 1995. Its process involves a stereomicroscopic incision to extract FUs from a donor scalp skin strip that had been removed. **Rassman et al.**<sup>[5]</sup> provided an alternative to microdissection procedures by producing follicular grafts using tiny punches to remove undamaged FUs, a process known as follicular unit extraction [FUE]. Nevertheless, FUs can essentially be collected by any method<sup>[3,5]</sup>.

The quality of the outcome is mainly influenced by the surgeon's technique as well as the patient's [age, graft availability, and anticipated AGA progression]<sup>[3]</sup>. FUE has grown in popularity among hair transplant practitioners in the last few years. This is primarily due to its benefits for individuals, who experience less discomfort and scarring in the donor areas than with FUT using strip harvesting<sup>[6]</sup>. Moreover, FUE can replace traditional FUT to restore the hairline, modify areas with high graft density, or get more grafts when FUT is no longer an option<sup>[7]</sup>.

The effects of therapeutic hair transplantation procedures on the biological function of grafted HFs have yet to be well understood, despite the fact that thousands of surgeons worldwide conduct these procedures since they are the most effective way to restore scalp hair to a natural appearance. A surgical technique's definition, justification,

application and methodology are the main topics of most papers<sup>[8]</sup>.

This work aimed to evaluate the morphological and histological changes in the transplanted hair follicles [HFs] after FUE for cases of AGA.

## PATIENTS AND METHODS

It's a prospective interventional study that was carried out at Al-Azhar University Hospitals between May 2018 and May 2023. In this investigation, 15 patients, ages 25 to 60, who were candidates for FUE hair transplantation and suffered from androgenetic alopecia were included. After 10–14 months following the procedure, the morphological and histological alterations in the transplanted FUs were contrasted with those of the native donor follicles. Our study followed the Helsinki declaration principals, and was approved from the ethical committee of our institution. Written informed consent was obtained from every patient at the time of recruitment. We included the patents according to the following criteria:

**The Inclusion criteria were:** [1] Healthy patients suffering from AGA, [2] Age group between 25 years and 60 years, and [3] Patients with all types of hair, and Failure or intolerance of medical management to alopecia.

**The Exclusion criteria were:** [1] Patients with other types of alopecia rather than AGA, [2] Patients with any associated local scalp infections, [3] Patients with unrealistic expectations, [4] Patients with total loss of hairs as there is no suitable donor site.

### Data collection

An objective and subjective examination of the 15 patients in the current research was conducted and depending on the donor and the number of grafts that needed to be harvested again, the extraction time ranged from one to four hours. The total average time of operation ranged from 4 to 8 hours. Following transplantation, morphological and histological alterations were assessed 10 and 14 months later. The morphological alterations for the donor and recipient regions were evaluated with a folliscope, dermoscope, and unaided eye. Moreover, the histological alterations of both donor and recipient follicles were evaluated by employing parts dyed with hematoxylin and eosin

## Surgical Technique

The FUE transplantation method utilized in this study included Jewelers Micro Forceps [Extraction & implantation], punches measuring 0.85 mm, and a needle holder with a slitter or blade knife number 11. The new hairline was made between 7 and 9 cm away from the glabella, depending on the exact distance. Donor site: the sides and rear of the scalp. Adrenaline [1 mg] and 2% xylocaine concentration were administered locally to the donor and receiver. In order to do the ring block at the donor site, we first made a 30 ml xylocaine solution and added 30 ml of normal saline with an adrenaline [1:1000] concentration for the recipient and donor blocks. To blockade the posterior occipital nerve properly, we inject near the posterior hairline. For the purpose of blocking the supraorbital and supratrochlear nerves, we dispersed the injection medially and laterally to the supraorbital notch. For the recipient area's ring blockage, we injected 3 cm on both sides. To finish the ring blockage of the recipient site and stop the zygomatico-temporal nerve, we injected the hairline in the temporal area.

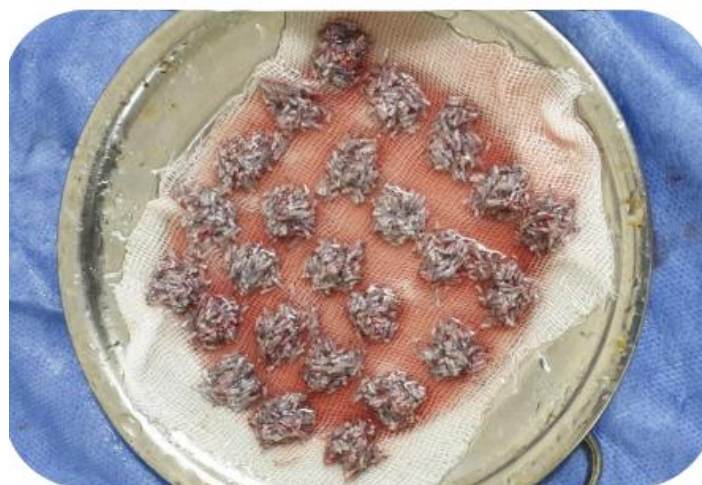
We employed sharp punches with 0.85 mm diameter to extract FUs. The preservation of hair follicle grafts is depicted in Figure 1, where the grafts were kept throughout the process in a cold, normal saline solution. The recipient areas are created in the recipient area using a scalpel knife No. 11 on a needle holder, or a blade width of roughly 1.1 mm. Graft insertion was done by the use of implantation jewelers.

Depending on the patient's tolerance and the site, the dressing was either exposed or closed; the closed dressing was eliminated 2-4 days after surgery.

All patients were followed 10 to 14 months by examining the native and transplanted follicular units to evaluate morphological and histological changes. They were assessed by the naked eye and by Dermoscopy and Folliscope [Figure 2] regarding hair color, curl pattern, and shaft diameter [Figures 3, 4].

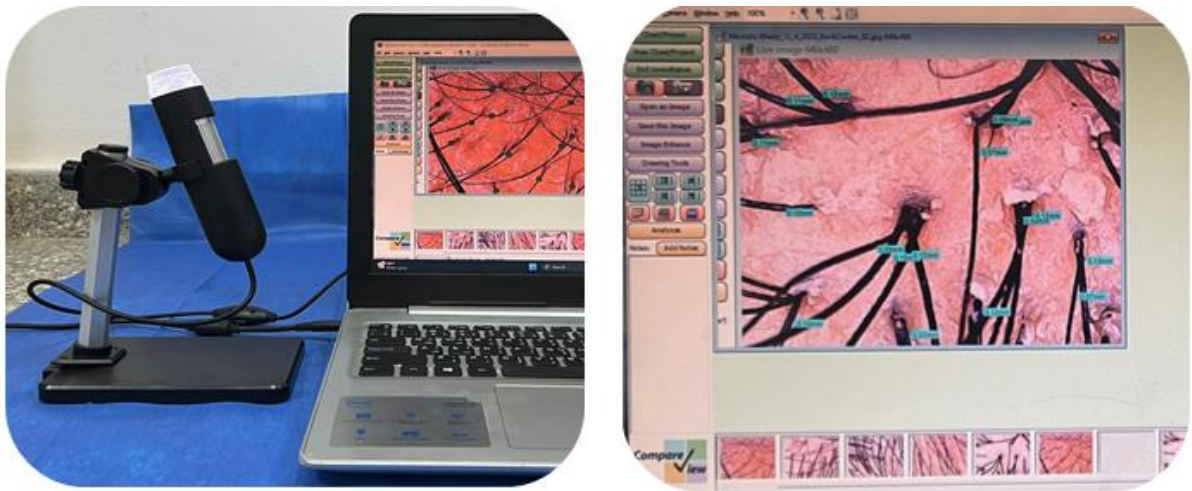
A punch of 4 mm diameter was used to extract FUs biopsy from each native and recipient scalp area. The collected FUs were prepared for microscopic examination on slides and stained with hematoxylin and eosin. Assessment of slides of native and transplanted FUs under the microscope was done to examine the microscopic changes in hair follicle cells [outer and inner root sheath cells], Sebaceous glands, and Arrector pili muscles [Figures 5-9].

**Statistical analysis:** Version 24 of the Statistical Program for Social Science [SPSS] was used to analyze the data. Percentages and frequencies were used to convey qualitative data. The statistical information was presented as mean  $\pm$ SD [standard deviation]. When comparing customarily distributed data between two arms, the independent sample T-test [T] was employed; for non-parametric data, the Chi-square test; and for probability [P-value]: P-values less than 0.05 were regarded as significant, P-values less than 0.001 as very substantial, and P-values greater than 0.05 as inconsequential.

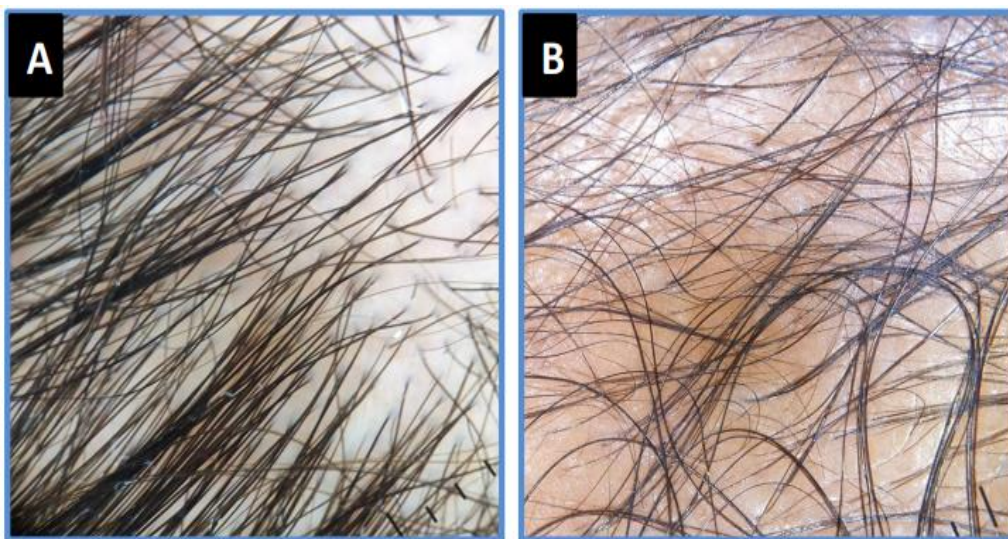


**Figure [1]:** The harvested grafts

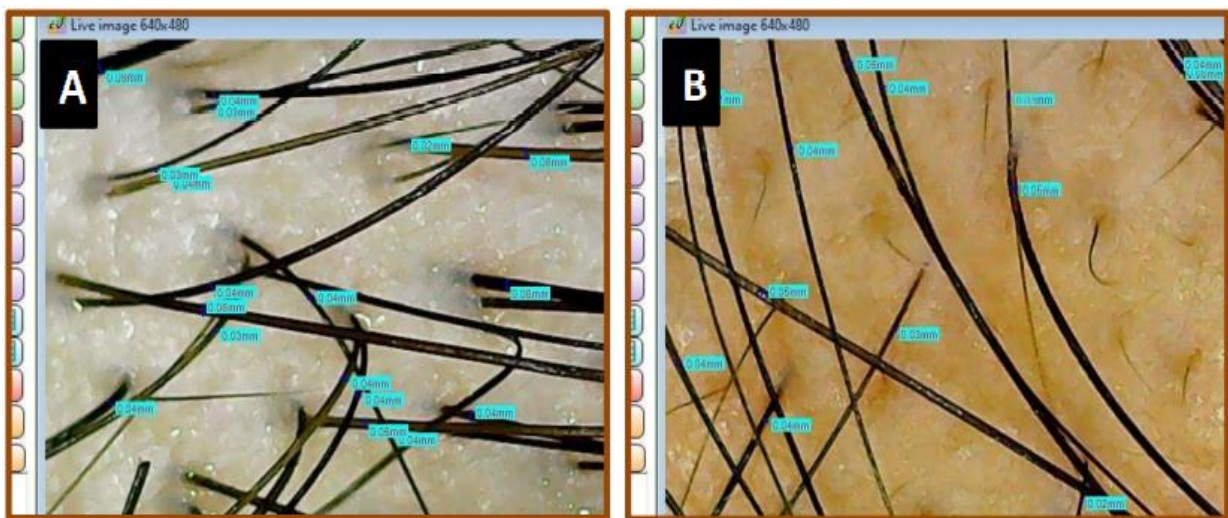




**Figure [2]:** Folliscope and its system screen

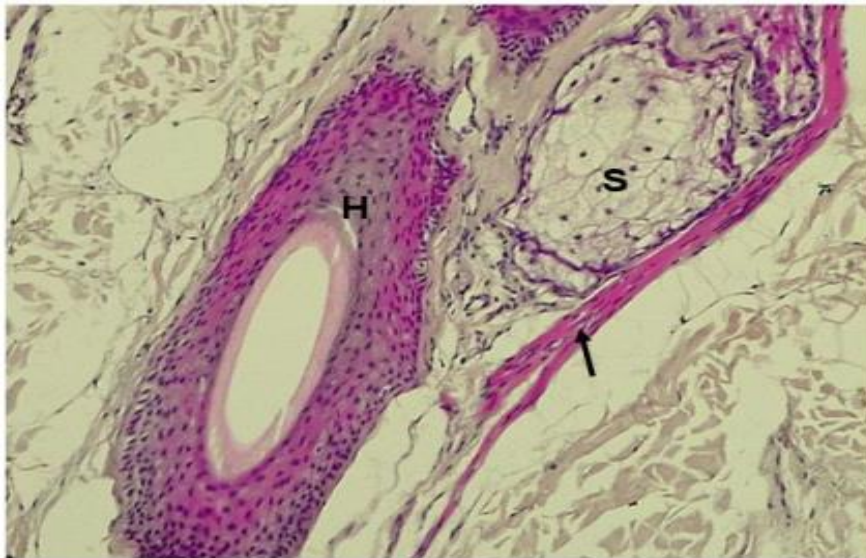


**Figure [3]:** Dermoscope image for the donor [A] and recipient [B] areas after 12 months of FUE showing changing in the curl pattern from straight hair in the donor to wavy hair in the recipient

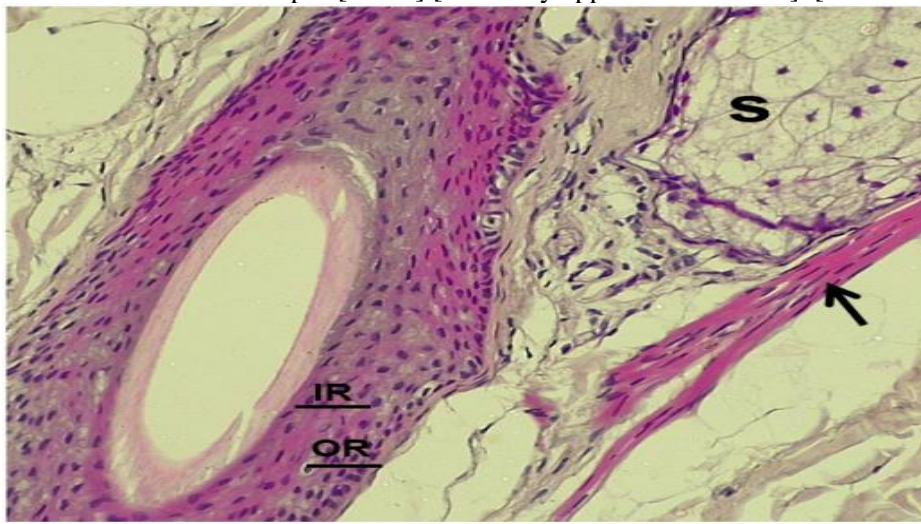


**Figure [4]:** Folliscope screen measuring the hair shafts diameter in the donor [A] and recipient [B]

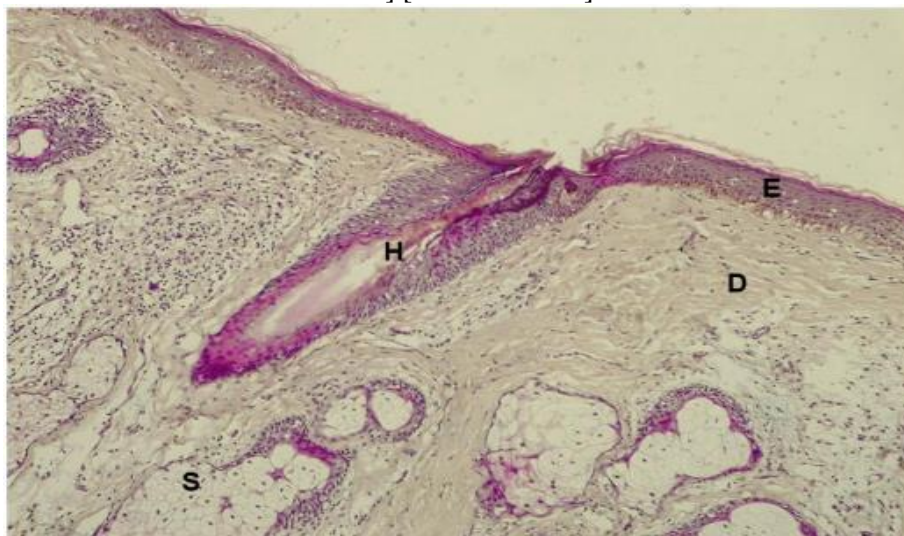




**Figure [5]:** Photomicrograph of section in donor hair follicle showing hair follicle [H] with surrounding sebaceous glands [S] associated with the hair follicle and a small bundle of smooth muscle known as the arrector pili [arrow] [Normally appeared structures]. [Hx & E x 100]

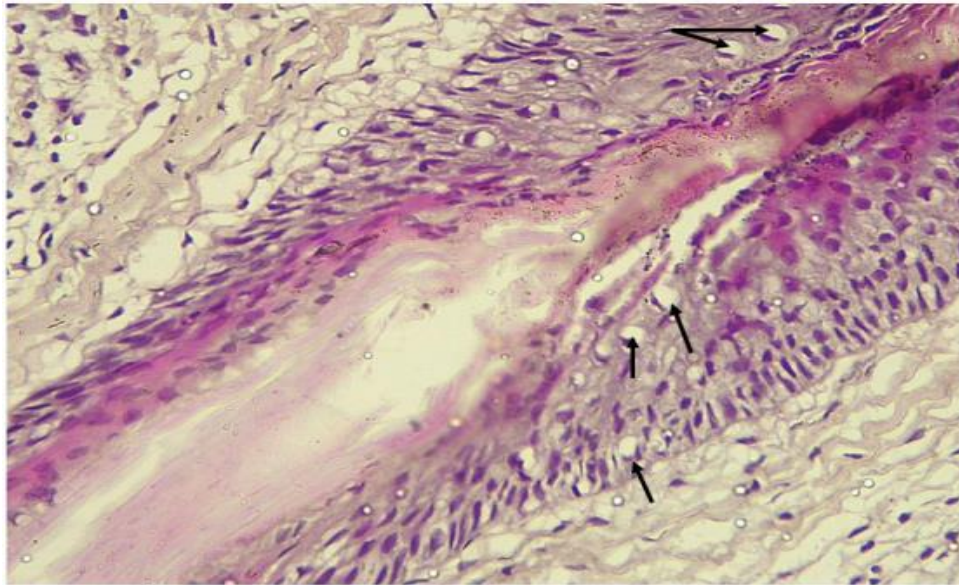


**Figure [6]:** Higher magnification of previous section showing layers of hair follicle; outer root sheath [OR], inner root sheath [IR], sebaceous gland [S] and arrector pili muscle [arrow] [Normally appeared structures] [Hx & E x 400 ].

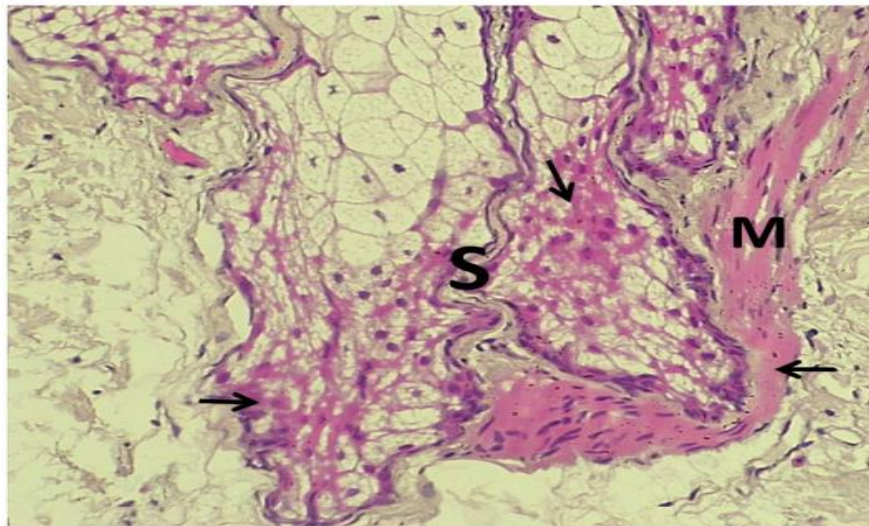


**Figure [7]:** Photomicrograph of section in recipient hair follicle after 12 months showing epidermis [E] and dermis [D] with small hair follicle [H] and sebaceous glands [S]. [Hx & E x 100]





**Figure [8]:** Higher magnification of the previous section showing hair follicle with some vacuolation [hydropic degeneration] in cells of root sheath internal and external [arrows] [Hx & E x 400]



**Figure [9]:** Photomicrograph of section in recipient site after 12 months showing some degenerative changes [arrows] in sebaceous glands [S] and arrector pili muscle [M] in the form of acidophilic homogeneity [hyaline degeneration] [Hx & E x 400]

## RESULTS

The demographic information for each individual under study is described in table 1. With a minimum age of 25 and a maximum age of 45, the mean age of all the individuals under study was  $34.3 \pm 6.5$  years. Regarding alopecia grade, among all the individuals under study, there were two individuals [13.3%] with grade III, three patients [20%] with grade IV, three patients [20%] with grade V, four patients [26.7%] with grade VI, and three patients [20%] with grade VII. Regarding graft count, the average number of grafts across all patients under study was  $1146.7 \pm 450.1$  grafts, with a

minimal number of 600 grafts and a maximum of 2200 grafts.

Table 2 demonstrates a substantial variation [p-value = 0.002] between the donor and recipient sites regarding sebaceous gland degeneration. The donor site in all studied patients [100%] had no sebaceous gland degeneration while at recipient site, there were 5 patients [33.3%] with no sebaceous gland degeneration, 4 patients [26.7%] with [+] sebaceous gland degeneration, 4 patients [26.7%] with [++] sebaceous gland degeneration and 2 patients [13.3%] with [+++] sebaceous gland degeneration. Regarding the degeneration



of the arrector pili muscle, there was a substantial variation [p-value = 0.002] between the donor and recipient sites. The donor site in all studied patients [100%] had no Arrector pili muscle degeneration while at recipient site, there were 5 patients [33.3%] with no Arrector pili muscle degeneration, 4 patients [26.7%] with [+] Arrector pili muscle degeneration, 4 patients [26.7%] with [++] Arrector pili muscle degeneration and 2 patients [13.3%] with [+++] Arrector pili muscle degeneration [Table 3].

Regarding outer root sheath degeneration, this data demonstrates a very substantial variation [p-value < 0.001] between the donor and recipient sites. The donor site in all studied patients [100%] had no Outer Root Sheath degeneration while at recipient site, there were 4 patients [26.7%] with [+] Outer Root Sheath degeneration, 9 patients [60%] with [++] Outer Root Sheath degeneration and 2 patients [13.3%] with [+++] Outer Root Sheath degeneration [Table 4].

Regarding inner root sheath degeneration, this data demonstrates a very substantial variation [p-value < 0.001] between the donor and recipient sites. The donor site in all studied patients [100%] had no Inner Root Sheath

degeneration while at recipient site, there were 4 patients [26.7%] with [+] Inner Root Sheath degeneration, 9 patients [60%] with [++] Inner Root Sheath degeneration and 2 patients [13.3%] with [+++] Inner Root Sheath degeneration [Table 5].

According to the hair color, there is no substantial variation in hair color between the donor and recipient sites [p-value = 1.0]. In both donor and recipient sites, there were 13 patients [86.7%] with black skin and 2 patients [13.3%] with dark brown skin [Table 6].

Regarding the curl pattern, this table demonstrates a very substantial variation [p-value < 0.001] between the donor and recipient sites. At the donor site, there were 11 patients [73.3%] with straight patterns and 4 patients [26.7%] with wavy patterns. At the recipient site, there was 1 patient [6.7%] with a straight pattern, 8 patients [53.3%] with a wavy pattern, and 6 patients [40%] with a curly pattern [Table 7].

Regarding the mean hair shaft diameter, this table demonstrates that there is no substantial variation [p-value = 0.05] between the donor and recipient sites. It was  $0.048 \pm 0.006$  mm at the donor site versus  $0.043 \pm 0.006$  mm at the recipient site [Table 8].

**Table [1]:** Description of demographic data in all studied patients

		Studied patients [N = 15]	
Age [years]	Mean ±SD	34.3 ± 6.5	
	Min - Max	25 - 45	
Grade of baldness	Grade III	2	13.3%
	Grade IV	3	20%
	Grade V	3	20%
	Grade VI	4	26.7%
	Grade VII	3	20%
Number of grafts	Mean ±SD	1146.7 ± 450.1	
	Min - Max	600 - 2200	
Follow up duration [months]	Mean ±SD	12 ± 1.25	
	Min - Max	10 - 14	

**Table [2]:** Comparison of sebaceous gland degeneration between donor and recipient sites

Sebaceous gland degeneration	Donor [N = 15]		Recipient [N = 15]		Stat. test	P-value
	Nil					
	Nil	15	100%	5	33.3%	<b>X<sup>2</sup> = 15</b> <b>0.002 S</b>
	+	0	0%	4	26.7%	
	++	0	0%	4	26.7%	
	+++	0	0%	2	13.3%	

**Table [3]:** Comparison of Arrector pili muscle degeneration between donor and recipient sites

Arrector pili muscle degeneration	Donor [N = 15]		Recipient [N = 15]		Stat. test	P-value
	Nil					
	Nil	15	100%	5	33.3%	<b>X<sup>2</sup> = 15</b> <b>0.002 S</b>
	+	0	0%	4	26.7%	
	++	0	0%	4	26.7%	
	+++	0	0%	2	13.3%	

**Table [4]:** Comparison of Outer Root Sheath degeneration between donor and recipient sites

Outer Root Sheath degeneration		Donor [N = 15]		Recipient [N = 15]		Stat. test	P-value
	Nil	15	100%	0	0%	$X^2 = 30$	< 0.001
	+	0	0%	4	26.7%		
	++	0	0%	9	60%		
	+++	0	0%	2	13.3%		

**Table [5]:** Comparison of Inner Root Sheath degeneration between donor and recipient sites

Inner Root Sheath degeneration		Donor [N = 15]		Recipient [N = 15]		Stat. test	P-value
	Nil	15	100%	0	0%	$X^2 = 30$	< 0.001 HS
	+	0	0%	4	26.7%		
	++	0	0%	9	60%		
	+++	0	0%	2	13.3%		

**Table [6]:** Comparison of hair color between donor and recipient sites

Hair color		Donor [N = 15]		Recipient [N = 15]		Stat. test	P-value
	Black	13	86.7%	13	86.7%	$X^2 = 0.0$	1.0 NS
	Dark brown	2	13.3%	2	13.3%		

**Table [7]:** Comparison of curl pattern between donor and recipient sites

Curl pattern		Donor [N = 15]		Recipient [N = 15]		Stat. test	P-value
	Straight	11	73.3%	1	6.7%	$X^2 = 15.6$	< 0.001 HS
	Wavy	4	26.7%	8	53.3%		
	Curly	0	0%	6	40%		

**Table [8]:** Comparison of mean hair shaft diameter between donor and recipient sites

Mean hair shaft diameter [mm]		Donor [N = 15]	Recipient [N = 15]	Stat. test	P-value
		Mean	Mean		
	Mean	0.048	0.043	T = 2.04	0.05 NS
	$\pm$ SD	0.006	0.006		

## DISCUSSION

AGA, sometimes referred to as male pattern hair [MPHL], is typified by a progressive reduction in the amount of hair fiber that scalp hair follicles produce and the consequent miniaturization of those follicles. The cause of MPHL/AGA is a result of both androgen action and genetic susceptibility. While testosterone is required for the onset of male pattern baldness, dihydrotestosterone, a more potent metabolite of testosterone, is what drives follicular regression [9].

Currently, available medicinal treatments for pattern hair loss include topical minoxidil and 5 $\alpha$ -reductase inhibitors [dutasteride and finasteride], both of which have limited efficacy and need to be used often. The potassium channels in the smooth muscles of the peripheral arteries are opened by minoxidil. This potassium channel activity is thought to be necessary for the cell cycle to advance to the G1 stage, for cellular proliferation, and finally for the growth of hair. Patients' access to surgical alternatives is limited by the high cost and scarcity of donor hair follicles [10].

Those who detest baldness and wish to have a hairy scalp are the ones who should have hair transplants. FUT is a recently developed method with promising outcomes [11]. In this study, we operated by FUE 15 patients suffering from AGA, the age group above 25 years old with established alopecia at the line & below 45 years. The study was conducted in the Plastic and Reconstructive Surgery Department at Al-Azhar University Hospitals. The duration of follow-up of cases in the study ranged from 10 to 14 months.

*Yoo et al.* [12] operated on 15 patients with cicatricial alopecia using FUE, with a mean age of 28.53 years [range 16 to 42 years]. *Shao et al.* [13] operated on 37 patients with cicatricial alopecia using FUE with a mean age of 24.68 years [range 12 to 42 years] years.

The mean age of patients in this study is 34.3 years [range 25 to 45 years]; this difference is due to the different types of alopecia, as in AGA, it is better to wait until the alopecia is established at the hairline. A prevalent issue in dermatological practice is hair loss. Despite

being viewed as a relatively benign medical condition, hair loss has been shown to have significant psychosocial effects, particularly in women. It should come as no surprise that the hair-loss industry in the US makes around \$4 billion a year, considering its prevalence and related effects <sup>[14]</sup>.

Despite its prevalence, minoxidil and finasteride are the only FDA-approved treatments for AGA, which affects up to 50% of males between the ages of 40 and 49.2 However, noncompliance and side effects frequently compromise the use and efficacy of these treatments. A more permanent option is provided by hair restoration surgery, but many people find it to be too expensive and the intrusive nature of the procedure to be appealing <sup>[15]</sup>.

In the study of **Bansal et al.** <sup>[16]</sup>, Alopecia areata was the presenting condition in 22 individuals [73.3%], alopecia universalis in six [20%], and alopecia totalis in Two [6.7%]. Four individuals [13.3%] with patterned hair loss were among the 22 with patchy hair loss. Among them, one [3.3%] patient had a reticular pattern, and three [10%] individuals had an ophiasis pattern. In the study in our hands, all patients suffered from AGA with variable degrees of baldness from type III to type VII. According to the Norwood-Hamilton scale, FUE was used for all patients with a number of grafts ranging from 600 to 2200.

Unable to orient the grafts as the punch progresses at the proper angle is likely the biggest short-term failure with FUE. Many surgeons need to routinely check the quality of their FUE throughout the procedure, despite this issue being easily identified with adequate quality control mechanisms in place. For each removed transplant, every anatomical component of the FUs will be identified under a microscope, along with any damage to these components <sup>[17]</sup>.

Rapidity and precision are the two key components of FUE success that are developed via experience and time. Contrary to the strip technique, graft harvesting in FUE is a blind process, which increases the likelihood of graft damage during punching. When contrasted with FUT, a significant disadvantage of FUE is transection, or physical harm to the grafts, which is one of the main causes of graft failure. There are variations in size, structure, sharpness, and layout for the FUE punches <sup>[18]</sup>.

In the Plastic and Reconstructive surgery department at Al-Azhar University hospitals, we agree with the previous studies, so for all FUE patients we are always starting the FUE by harvesting a small number of grafts to test the angle of direction and depth of follicles and examine them for transection. Injection of tumescent and counter traction on the scalp by dry gauze helps to erect the follicles and reduce the transection rate. Shortening of the overall duration of either harvesting or implanting the grafts and avoidance of overheating caused by increasing motor speed, also gentle handling of grafts helps to achieve better results.

FUE Mega sessions are characterized by FUE graft counts exceeding 2000 in Caucasian individuals with average hair density. Accordingly, an average FUE mega session for an Asian would involve 1600 grafts, while an intermediate session for an African would have 1200 grafts. Many physicians find themselves operating into the "non-permanent zone" of the donor area when the frequency of extractions rises in order to obtain the quantity of grafts that the recipient region needs <sup>[19]</sup>.

During our investigation, we discovered that an adequate hairline requires a minimum of 1200 grafts. The degree of baldness determines the proper overall number of grafts. Finding a safe donor region before surgery is essential since removing grafts from a hair-loss-prone area is the primary cause of grafted loss of hair and unfavorable results from different surgeries <sup>[19]</sup>.

The effects of therapeutic hair transplantation procedures on the biological function of grafted HFs have yet to be well understood, despite the fact that thousands of surgeons worldwide conduct these procedures since they are the most effective way to restore scalp hair to a natural appearance. A surgical technique's definition, justification, application, and methodology are the main topics of most papers. On the other hand, only pathological problems such as necrosis, lichen planopilaris, or post-operative superficial folliculitis are reported as alterations in the recipient area <sup>[3]</sup>.

The transplantation procedure, which includes harvesting the graft, inserting it back into the recipient site's skin, and spending some time between ex vivo, exposes the transplanted HFs to nonphysiological stress. This covers harm to the graft that may result from dehydration, starvation due to an interruption in blood



supply, or mechanical breakdown of follicular components. Another important factor contributing to graft modifications is the transformation of the perifollicular surroundings in the recipient location. Since physical traumas cause localized inflammation and wound-healing reactions in the graft and the place of insertion, this primarily relates to the transplantation process [3]. In this study, we completely agree with this point of view, and therefore, we tried to address this issue to study the changes after FUE.

When FUE was carried out on two patients with an average outcome, transplanted hair follicles were visually inspected six months after the procedure, and no differences in the size, shape, or color of the transplanted versus native hair follicles could be seen in the recipient area. However, after six months in the recipient site, the hair follicles grafted by FUE showed a marked loss in length histologically. Six months after transplantation, there was a decrease in the donor-provided follicles' DP size. The hair follicles transplanted from the occipital to the frontal region exhibited the most noticeable reduction in length. Still, this diminution of FUs was irrespective of the follicle region of origin [20]. In the study in our hands, the post-transplantation changes were examined after 10 to 14 months of FUE. The changes in shaft diameter and color between the grafted and native hair are statistically non-significant, but the curl pattern is changed after FUE, where the transplanted hair tends to be rougher.

The histological changes appeared in the form of degenerative changes in the root sheath cells which may explain the shrinkage of follicular size after FUE in the last study of Azar et al. [3].

In the study by Azar et al. [3], examining the recipient locations of the two patients' standard hair transplants two and five years after FUT revealed distinct hair features in each patient. The darker and messier hair resulting from FUT transplants looked more natural. One patient's hair shaft examined using an electron microscope showed noticeably larger hair shaft widths in the FUT-grafted HF arm. The morphologic examination revealed that the hair produced by FUT-grafted HFs had thickened in a single patient, as hair shaft specimens from the recipient areas had a diameter of 98.1  $\mu\text{m}$  [0.098 mm], despite the donor scalp hair shaft specimens having an average thickness of 66.8  $\mu\text{m}$  [0.067 mm]. One

patient's HF samples' histomorphometric examination showed an overall growth of every component found in the hair bulb, including the DP [dermal papilla], HM [hair matrix], and DS [dermal sheath].

Unlike the last study, this study in our hands evaluated the changes in hair follicles after FUE, not FUT. The change in hair shaft diameter was statistically non-significant, and the mean shaft diameter was 0.048 mm [0.006 SD] for donor scalp hair and 0.043 mm [0.006 SD] for the recipient hair, with a p-value=0.05. Our study, together with the last 2 studies of Azar et al. [3] reinforces the idea that restorative hair operation actually alters the transplanted hair and typically affects the identification of grafts. Additionally, variations in the technique and graft preparation may specify the precise result and significantly impact the final texture of the hair.


**Conclusion:** The implication of the FUE procedure on the transplanted follicles is obvious histologically and morphologically. Histologically, the degenerative changes occurred in the hair follicle root cells, which were statistically significant, but the degenerative changes in the sebaceous glands and arrector pili muscles were statistically non-significant. The morphological changes were statistically highly significant in the curl pattern where the hair becomes rougher after FUE; the mean hair shaft diameter was decreased after FUE; however, it was statistically non-significant, with no change in hair colour after FUE. Therefore, more research using biopsies conducted at extended follow-up times will be required to determine how long these results will last. Even in cases where aberrant results were observed histologically, our patients have had good outcomes from their procedures thus far.

**Financial and non-financial relations and activities of interest:** None

## REFERENCES

1. Araújo R, Fernandes M, Cavaco-Paulo A, Gomes A. Biology of human hair: know your hair to control it. *Adv Biochem Eng Biotechnol.* 2011; 125:121-43. doi: 10.1007/10\_2010\_88.
2. Vogel JE, Jimenez F, Cole J, Keene SA, Harris JA, Barrera A, Rose PT. Hair restoration surgery: the state of the art. *Aesthet Surg J.* 2013 Jan;33[1]: 128-51. doi: 10.1177/1090820X12468314.
3. Azar RP, Thomas AH, Maurer M, Lindner G. Alterations in Hair Follicle Morphology and Hair

- Shaft Production After Follicular Unit Transplantation. *Am J Dermatopathol.* 2016 Oct;38[10]:732-8. doi: 10.1097/DAD.0000000000000526.
4. Rose PT. Advances in Hair Restoration. *Dermatol Clin.* 2018;36[1]:57-62. doi: 10.1016/j.det.2017.09.008.
  5. Rassman WR, Bernstein RM, McClellan R, Jones R, Worton E, Uyttendaele H. Follicular unit extraction: minimally invasive surgery for hair transplantation. *Dermatol Surg.* 2002 Aug;28[8]:720-8. doi: 10.1046/j.1524-4725.2002.01320.x.
  6. Umar S. Use of body hair and beard hair in hair restoration. *Facial Plast Surg Clin North Am.* 2013 Aug;21[3]:469-77. doi: 10.1016/j.fsc.2013.05.003.
  7. Epstein GK, Epstein J, Nikolic J. Follicular Unit Excision: Current Practice and Future Developments. *Facial Plast Surg Clin North Am.* 2020 May;28[2]:169-176. doi: 10.1016/j.fsc.2020.01.006.
  8. Harris JA. Follicular unit extraction. *Facial Plast Surg Clin North Am.* 2013 Aug;21[3]:375-84. doi: 10.1016/j.fsc.2013.05.002.
  9. Avci P, Gupta GK, Clark J, Wikonkal N, Hamblin MR. Low-level laser [light] therapy [LLLT] for treatment of hair loss. *Lasers Surg Med.* 2014 Feb;46[2]:144-51. doi: 10.1002/lsm.22170.
  10. Adil A, Godwin M. The effectiveness of treatments for androgenetic alopecia: A systematic review and meta-analysis. *J Am Acad Dermatol.* 2017 Jul;77[1]:136-141.e5. doi: 10.1016/j.jaad.2017.02.054.
  11. Rogers N. Commentary on Autologous platelet-rich plasma: a potential therapeutic tool for promoting hair growth. *Dermatol Surg.* 2012 Jul;38[7 Pt 1]:1047-8. doi: 10.1111/j.1524-4725.2012.02386.x.
  12. Yoo H, Moh J, Park JU. Treatment of Postsurgical Scalp Scar Deformity Using Follicular Unit Hair Transplantation. *Biomed Res Int.* 2019 May 13;2019:3423657. doi: 10.1155/2019/3423657.
  13. Shao H, Hang H, Yunyun J, Hongfei J, Chunmao H, Zhang J, *et al.* Follicular unit transplantation for the treatment of secondary cicatricial alopecia. *Plast Surg [Oakv].* 2014 Winter;22[4]:249-53. doi: 10.4172/plastic-surgery.1000885.
  14. Tabolli S, Sampogna F, di Pietro C, Mannooranparampil TJ, Ribuffo M, Abeni D. Health status, coping strategies, and alexithymia in subjects with androgenetic alopecia: a questionnaire study. *Am J Clin Dermatol.* 2013 Apr;14[2]:139-45. doi: 10.1007/s40257-013-0010-3.
  15. Alfonso M, Richter-Appelt H, Tosti A, Viera MS, García M. The psychosocial impact of hair loss among men: a multinational European study. *Curr Med Res Opin.* 2005 Nov;21[11]:1829-36. doi: 10.1185/030079905X61820.
  16. Bansal A, Relhan V, Garg VK, Saran RK. A cross-sectional study of the histopathology and immunology of alopecia areata: Unearthing the role of the Janus kinase-signal transducer and activator of transcription pathway. *Indian J Dermatol Venereol Leprol.* 2019 Sep-Oct;85[5]:455-461. doi: 10.4103/ijdv.IJDVL\_738\_17.
  17. Rassman W, Pak J, Kim J. Combining Follicular Unit Extraction and Scalp Micropigmentation for the Cosmetic Treatment of Alopecias. *Plast Reconstr Surg Glob Open.* 2017 Nov 7;5[11]:e1420. doi: 10.1097/GOX.0000000000001420.
  18. Sharma R, Ranjan A. Follicular Unit Extraction [FUE] Hair Transplant: Curves Ahead. *J Maxillofac Oral Surg.* 2019 Dec;18[4]:509-517. doi: 10.1007/s12663-019-01245-6.
  19. Parsley WM, Perez-Meza D. Review of factors affecting the growth and survival of follicular grafts. *J Cutan Aesthet Surg.* 2010 May;3[2]:69-75. doi: 10.4103/0974-2077.69014.
  20. Azar RP, Thomas AH, Lindner G. Hair Follicle Plasticity with Complemented Immune-modulation Following Follicular Unit Extraction. *Int J Trichology.* 2015 Jan-Mar;7[1]:16-23. doi: 10.4103/0974-7753.153451.



# International Journal

<https://ijma.journals.ekb.eg/>

Print ISSN: 2636-4174

Online ISSN: 2682-3780

# of Medical Arts