

Research Article

Role of Corticomedullary phase in increasing detection sensitivity of Urinary bladder cancer



Hosny Sayed Abd El-Ghany¹, Tamer El Zaeem¹ and Radwa Gamal El-Deen Saad¹

¹Department of Radiology- Faculty of Medicine EL-Minia University.

DOI: 10.21608/MJMR.2024.265286.1648

Abstract

Background: Urinary bladder cancer is one of the most common tumors among the lower urinary tract, computed tomography urography (CTU) is noninvasive technique touse to detect urinary tract lesions and it consists of unenhanced phase. nephrographic phase and excretory phase. Corticomedullary phase may be added to role out urinary bladder lesions. **Aims:** This study aims to examine of correlation of adding corticomedullary phase and sensitivity of detection of urinary bladder cancer. **Patient and methods:** This is a prospective study conducted on 25 urinary bladder cancer patients from department of the radiology, Minia Oncology Center from December 2022 to January 2024. **Results:** Enhancement of corticomedullary phase were significantly higher than other phases (unenhanced phase, nephrogenic phase, excretory phase). **Conclusion:** By adding corticomedullary phase to computed tomography urography(CTU) can detect urinary bladder lesions with high accuracy even with negative CTU.

Keywords: Urinary bladder cancer (UB), computed tomography urography (CTU), corticomedullary phase (CMP).

Introduction

The development of abnormal tissue in the bladder lining tissue, and in some cases, the tumours growing into the bladder muscle, is known as urinary bladder cancer (UBC). Tumors may develop when more cancer cells proliferate. Over time, these tumors may spread to other parts of the body, which called metastasis. ⁽¹⁾

As estimated by Global Cancer Observatory (GLOBOCAN) in December 2020, UBC is the third most prevalent cancer in Egypt with (26,986) patients with a mortality of (6170) patients in 2020, also bladder cancer remains the second most common cancer among Egyptian males. ⁽²⁾ Urinary obstruction, frequent urination, urgency, gross hematuria,

and recurrent UTIs are the most common symptoms of UBC. ⁽³⁾

The International Agency for Research on Cancer (IARC) has reported sufficient evidence for UBC risk factors that may be mainly because of tobacco smoking. ⁽⁴⁾ Although a small tumour that is located within the bladder might remain undetected by conventional techniques, early detection of bladder cancer can improve treatment outcomes. ⁽⁵⁾

The gold standard technique to detect UBC is a cystoscopy, which can be performed while the patient is either under local or general anesthesia. Some of the disadvantages of cystoscopy include the possibility of to miss

a small flat tumor, hematuria, UTI, and urethral damage from the equipment used during the procedure. ⁽⁶⁾

Computed tomography urography (CTU) is a widely used procedure that takes at least one series of images during a CT scan of the bladder, ureters, and kidneys. Any CTU protocol starts with the plain phase, also known as the unenhanced phase (UP), and continues with imaging in the nephrogenic phase (NP) and excretory phase (EP), after intravenous administration of a contrast agent. ⁽⁷⁾

Standard CTU may miss small UBC because it is might difficult to observe especially in excretory phase (EP) due to the fluid level and contrast agent may mixed with urine in this phase so bladder lesions may be missed or detected as filling defect. This may leads to decrease the detection sensitivity and accuracy of UBC. ⁽⁸⁾

To increase the sensitivity of detecting of UBC a new technique called Multiphasic CTU that consists of four phases which are an unenhanced phase (UN), a corticomedullary phase (CMP) also known as an arterial phase, a nephrographic phase (NP), and a excretory phase (EP). In addition, to increase the sensitivity and accuracy of the excretory phase bladder expansion is needed so that patients were given about 500 mL of fresh water prior to the CT scan So that avoiding missing flat tumors by blooming effect. Multiphasic CTU may be similar sensitive in detecting UBC as cystoscopy and more sensitive than three phases CTU. ⁽⁹⁾

Patients & Methods

This is a prospective cohort study conducted on 25 suspected urinary bladder cancer patients were referred from department of radiology at Minia Oncology Center from December 2022 to October 2023 and after ethical approval by department committee. Written and informed consent was obtained from all patients with risk explanation prior to

the CT scanning.

1- Inclusion criteria:

- Patients with gross hematuria.
- Patients suspected with bladder cancer by ultrasound.
- Patients with positive urine cytology.
- Age older than 18 years.
- Both Sexes.

2- Exclusion criteria:

- Pregnant women.
- Patient with history of contrast allergy.
- Patient with renal insufficiency.
- Patient less than 18 years' old.

Methods:

All patients were subjected to the followings:

1- Complete full history taking including:

- All patients will give written consent before inclusion in the study.
- Family history and daily habits.
- History of previous surgeries or previous diseases.
- History of any CT contraindications.
- Patients will have required laboratory test (Renal function) before using contrast medium.

2- Laboratory examination:

- Complete blood picture (CBC): hemoglobin concentration (Hb %), red blood cells (RBCs), white blood cells (WBCs), platelet count.
- Renal function test.
- Cystoscopy and pathological examination.

3- Radiological investigations:

- Computed Tomography (CT) by MDCT Canon Aquilion prime SP 160 scanner with a maximum rating output of X-ray of 120 KV -600 mA.
- Contrast material diffused by Medrad Slaint injector.
- Analyzing CT images in axial plane, coronal plane and sagittal plane.
- Comparing enhancement pattern of four

Role of Corticomedullary phase in increasing detection sensitivity of Urinary bladder cancer

phases (UP, CMP, NP and EP) for detection of bladder lesion.

Data management and Statistical Analysis:

All data were collected, tabulated and statistically analyzed using statistical package of special science SPSS version 26 statistical package software (IBM; Armonk, New York, USA) as following:

1. Editing and coding.
2. Data entry in computer.
3. Numerical data were presented as mean, standard deviation (SD), median & interquartile range. Mann Whitney test were used for statistical analysis for non-parametric variables.
4. Categorical data were presented as numbers and percentages.

5. The chi-squared test and fisher exact were used for statistical analysis.

6. Correlations was made to the study in comparing numerical variables.

7. All statistical comparison were two tailed with significance level of $p\text{-value} \leq 0.05$ indicates significant, $p\text{-value} > 0.05$ indicates non-significant difference

Results

This study included 25 patients referred to radiology department, El Minia oncology institute, from March 2023 to October 2023. All patients were suspected to have UB lesion. The age of the patient ranged between 20-84 years (mean age was 63.08 ± 14.5). The mean age of males was (64.18 ± 14.18) and the mean age of females was (60.75 ± 16.02).

Table (1): Frequency distribution of socio-demographic characteristics of the studied patients.

Socio-demographic characteristics	Number	Percent
Age (years)		
Mean (SD) Median (IQR)		63.08(14.5)
Min-max		66(57.50-72) 20-84
Sex		
Male	17	68%
Female	8	32%
Marital state		
Single	3	12%
Married	20	80%
Widow	2	8%
Smoker		
No	11	44%
Yes	14	56%

Table (1): Shows that the mean age of studied patients was (63.08 ± 14.5), 68% of patients are males, 80% are married and 56 % are smokers.

Table (2): Frequency distribution of main clinical symptoms of the studied patients.

Clinical presentation	Number	Percent
Hematuria		
No	5	20%
Yes	20	80%
Burning micturition(dysuria)		
No	23	92%
Yes	2	8%
Urgency		
No	24	92%
Yes	2	8%
Pain (loin/pelvic)		
No	23	96%
Yes	1	4%

Table (2): Shows that 80% of patients have hematuria, 8% have burning micturition, 8% have urgency and 4% of patients have flank pain.

Figure (1): Shows the Frequency distribution of main clinical symptoms of the studied patients.

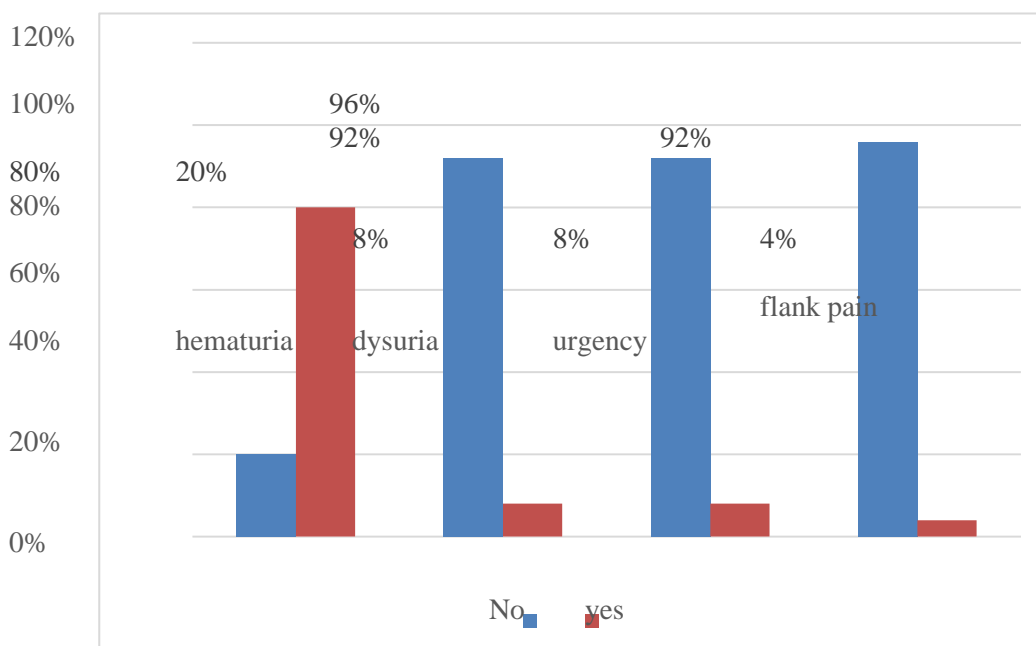


Table (3): Frequency distribution of tumor characteristics of studied patients.

Tumor characteristics	Number	Percent
Tumor pathology		
Transitional cell carcinoma	24	96%
Squamous cell carcinoma	1	4%
Tumor pathological stage		
PT1	12	48%
PT2	13	52%
Tumor size Tumor length(cm)		
Mean (SD)	4.15(2.5)	
Median (IQR)	4(1.98-5.65)	
Min-max	0.8-12	
Tumor width(cm)		
Mean (SD)	3(2.06)	
Median (IQR)	2.8(1.5-3.93)	
Min-max	0.2-10.5	
Tumor height(cm)		
Mean (SD)	3(2.45)	
Median (IQR)	2.35(1.13-3.95)	
Min-max	0.6-11	

Table (3): shows that 96% of tumor pathologies is transitional cell carcinoma, 52% of tumor pathological stages lies in stage II, mean length of the tumor is 4.15 ± 2.5 , mean width of the tumor is 3 ± 2.06 and mean height of the tumor is 3 ± 2.45 .

Table (4): Frequency distribution of multiphasic CTU phases in detection of the lesions of studied patients and enhancement of each phase.

Multiphasic CTU phases	Number	Percent
Unenhanced phase		
negative	(9/25)	36%
positive	(16/25)	64%
Corticomedullary phase		
negative	(1/25)	4%
positive	(24/25)	96%
Nephrographic phase		
negative	(6/25)	24%
positive	(19/25)	76%
Excretory phase		
Negative	(10/25)	40%
positive	(15/25)	60%
Enhancement according to Hounsfield unit (HU) in all phases		
CMP	(21/25)	84%
NP	(2/25)	8%
EP	(2/25)	8%

Table (4): Shows the frequency distribution of each phase in Multiphasic CTU and the enhancement phase, 64% of tumors are detected in unenhanced phase, 96% of tumors are detected in the corticomedullary phase, 76% of tumors are detected in the nephrographic phase and 60% of tumor are detected in the secretory. Also (21/25) 84% of tumors show more enhancement in the CMP according to Hu.

Figure (2): Frequency distribution of multiphasic CTU phases in detection of the tumors of studied patients.

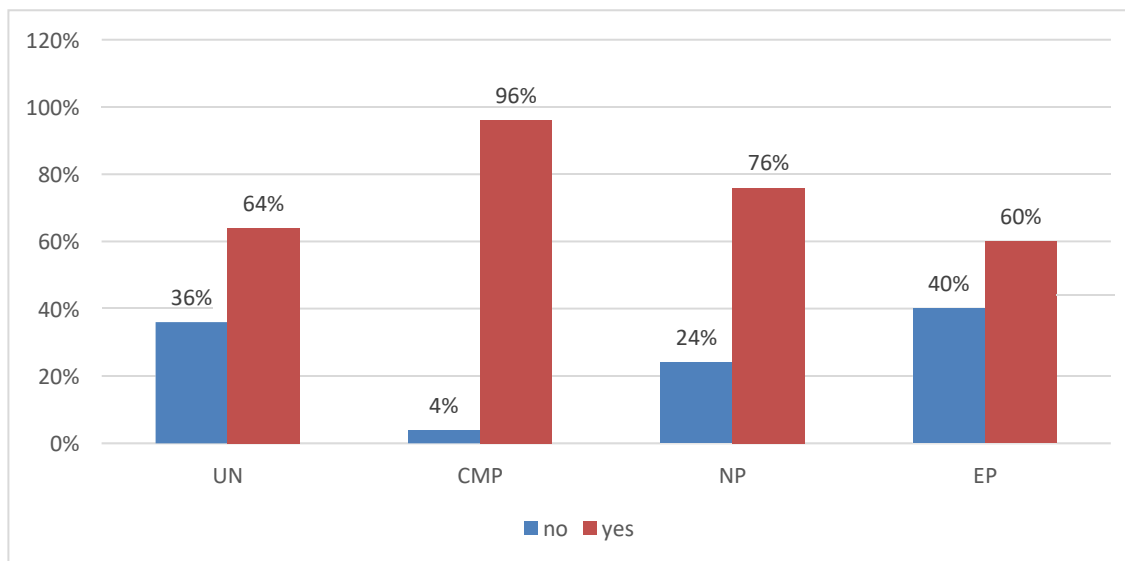


Figure (3): Frequency distribution of tumor enhancement according to Hounsfield unit (HU) in different CTU phases.

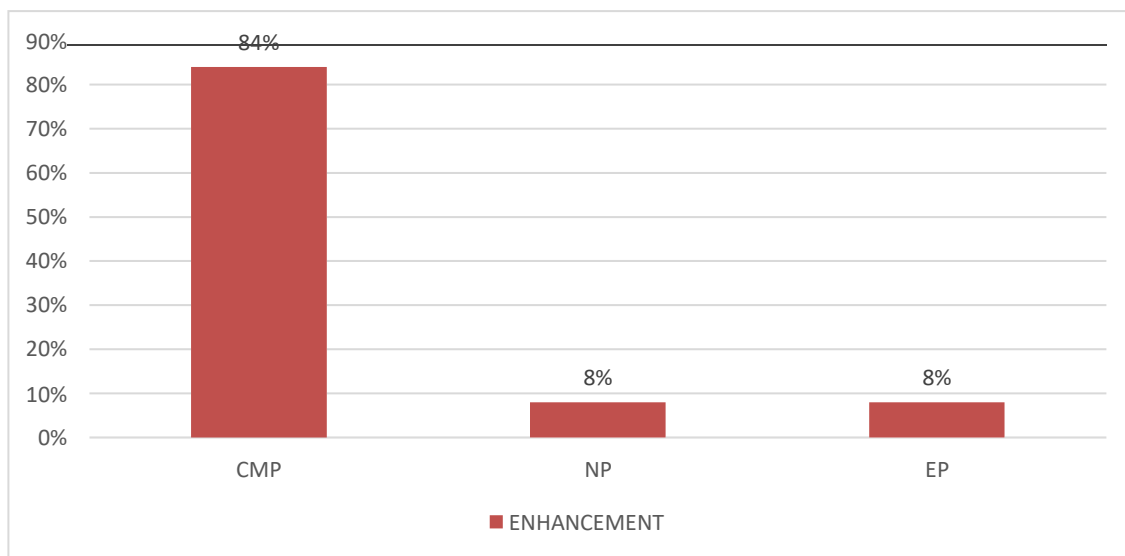


Table (5): Shows sensitivity of Multiphasic CTU (UN, CMP, NP, EP) and other phases (UN, NP, EP) in detection of UBC.

Protocol	Sensitivity (%)
Multiphasic CTU	24/25 (96 %)
Other phases	20/25 (80%)

Table (5): Shows that the Sensitivity of Multiphasic CTU were (96%) which is higher than other phases in the detection of UBC.

Discussion

According to (Ibrahim J et al., 2023) UBC become common and presents a serious public health concern around the world. In 2020, there were 213,000 deaths and 573,000 new cases of the disease. The developed countries exhibited the highest incidence rates. According to predictions of UBC incidence (based only on changes in population), Africa is expected to face the largest percentage growth in incident BC patients from 2020 to 2040 (101%). also, UBC remained the second most common cancer among Egyptian males. UBC has a 4:1 male to female ratio, with a significant male preponderance. This might be because male farmers who are more exposed to the Nile water have greater incidence of Schistosomiasis hematobium also because tobacco smoking.⁽¹⁰⁾

The aim of our research was to investigate the role of CMP in increasing the sensitivity of standard CTU in detecting of UBC with high accuracy specially small and flat lesion, which may be missed due to blooming effect in EP.

This is a prospective cohort study performed on 25 suspected urinary bladder cancer patients were referred from department of radiology at Minia Oncology Center

In our current study, the studied their age from 20 to 84 years with the mean age of (63.08) years \pm standard deviation (14.5). The study included 17 male (68%) with mean (64.18) years \pm standard deviation (14.18) and 8 female (32%) with mean age of (60.75) years \pm standard deviation (16.02).

The results are in agreement with (Zaho X et al., 2022) who concluded that the percentage of BC risk attributed to nonsmoking patients were estimated to be 44%.⁽¹¹⁾ However (Jacoub L et al., 2018) found that approximately 50% of BC cases are caused by tobacco smoking while our results were 56% of patient are smoking.⁽¹²⁾

Our study included 76 % of patient presenting

with painless hematuria, 12% dysuria 8 % urgency and symptoms 4% flank pain which approximately agree with (Hisham H et al., 2021) who recorded that more than 80% of patients present with, which is the most common presenting symptom. In addition, 20 % of patients have others symptoms such dysuria, urgency and flank pain and may also present alone without hematuria such as⁽¹³⁾ According to (Biardeau X et al., 2017) The American Urological Association (AUA) and the American College of Radiology (ACR) both recommended the use of CTU and cystoscopy for the examination of hematuria. The cornerstone of UBC diagnosis and follow-up is cystoscopy. However, it is expensive, invasive and time-consuming procedure, which may cause pain when urination, increases frequency of urination, visible hematuria, UTIs, and has a low reported sensitivity for the detection of UB tumors due to small or flat tumors such as Tis may remain undetected. Additionally, cystoscopy has difficulty distinguishing benign masses from malignant lesions, particularly prior to TURB.⁽¹⁴⁾

According to (Tony T et al., 2017) CTU performed with three-phase protocol was used which included a non-contrast scan of the abdomen and pelvis followed IV administration of iodinated contrast material then after 100 s a nephrographic scan. Finally after 10–15 min from administration contrast material excretory phase scan of the abdomen and pelvis. CT urography can be used to detect bladder cancer with a sensitivity of 86%.

⁽¹⁵⁾ While (Lee H et al., 2017) reported in a study of 687 patients, 710 CTU were evaluated to detect UBC. CTU had 91.5% (650/710).⁽¹⁶⁾

According to (Ola A et al., 2019). CTU is noninvasive, shorter time and wider coverage than cystoscopy so that CTU is the radiologic modality utilized in assessment of patients

with UBC. However, it is still limited in the characterization of small UBC⁽¹⁷⁾. also (Martingano P et al., 2010) reported that UBC less than 1 cm and in those whom recent resection has been performed, are more likely to be falsely negative in CTU also detection is dependent on the morphology and size of the tumor. Therefore, new CTU protocols can eliminate this limitation.⁽¹⁸⁾

Our results agree with (Ljungberg A et al., 2021) who reported that EP with a small attenuation difference between contrast-enhanced urine and surrounding tissues is preferred, as tiny tumors may be hidden by the contrast blooming effect. Furthermore, since urine containing contrast medium does not easily mix with normal urine, if the patients does not empty bladder prior to the EP, the bladder will be layered with non-enhanced urine anteriorly and contrast-enhanced urine posteriorly, hiding tumors located anteriorly. This is similar to our study, which showed that only 8% of patients had more enhanced in the EP and that 40% of patients had false negative results.⁽¹⁹⁾ In line with our study (Suleiman A et al., 2022) suggested that CTU containing a corticomedullary phase (CMP) in order to detect UBC with a greater sensitivity which could be similar to cystoscopy.

Also may be eliminate the missing of flat or small tumors by three phases CTU. A four-phase protocol initiated with unenhancement phase (UN) of the abdomen and pelvis then followed by a CMP of the abdomen and pelvis 20 seconds after IV administration of iodinated contrast medium, then nephrographic phase (NP) 40 second after IV administration. Finally excretory phase (EP) of the abdomen and pelvis at least 7.5 min after IV that protocol agree with our study, Additionally, the results showed that the false negative ratio for CTU with CMP were low at 7%, while in our study were 5%. Therefore, in most patients with macroscopic hematuria, cystoscopy may be omitted.⁽²⁰⁾ Also our results shows that when adding CMP to three

phase CTU the sensitivity were 95% while (Helenius M, et al., 2015) reported that the sensitivity were 87 % when adding CMP.⁽²¹⁾

According to (Andres M et al., 2014) Variations in contrast enhancement were significant throughout all phases with 88% of cases showing greater contrast enhancement in CMP than other phases while in our study were 84%, this is meaning CMP is preferred for detecting UBC due to its significantly better contrast enhancement compared to NP and EP.⁽²²⁾

The results agree with (Wolfman J et al., 2020) who recommended that Multiphasic CTU as the first line imaging method in patients with micro-hematuria and suspected with UBC. Which consist of three post-contrastographic phases including corticomedullary (CMP), nephrographic, and excretory phases because of this protocol is also described as the most sensitive for transitional cell carcinomas which agree with our results as (21/25) of our studied patient were TCC and all of them were detected by multiphasic CTU.⁽²³⁾

Conclusion

- When assessing the UBC, the gold standard Radiological method is Multiphasic CTU.
- CMP can increase the sensitivity of multiphasic CTU with high ability to detect small and flat tumors also can show more enhancement pattern than other phases.

Conflict of interest

The authors declare that they have no competing interest.

Acknowledgments

I would like to express my sincere gratitude and deep appreciation to **Prof. Dr. Hosny Sayed Abd El-Ghany, and Dr. Tamer El Zaem Esmaeel**, for there continuous scientific guidance. Words cannot adequately express my great thanks and gratitude to

Role of Corticomedullary phase in increasing detection sensitivity of Urinary bladder cancer

theme.

References

1. Sattam A, Halaseh S, Yaman A, Mohannad E and Mohammad J. A Review of the Etiology and Epidemiology of Bladder Cancer: All You Need To Know. (2022) Cureus vol14 issue 7.
2. Humaid O, Faryal I, Ibrahim H, Aydah A. Cancer in arab world first edition. (2022)
3. Katharine C. De-George M, Harry R and Stephanie C. Bladder Cancer:Diagnosis and Treatment. American Family Physician (2017),vol 96 No 8 p 507-520.
4. Yan H, Ying Y, Xie H, Li J, Wang X and He L. Secondhand smoking increases bladder cancer risk in nonsmoking population: a meta-analysis. Cancer Management and Research (2018),vol 10 p 3781-3791
5. Mohammed Shabara, Soumaya Eteba, Wafaa El-Beshbishi and Shimaa E. Attia. Clinicoepidemiological study of locally advanced bladder cancer: single institution experience. International Journal Of Cancer And Biomedical Research (IJCBR) (2022) Vol 6 issue 3 p 1:10.
6. Chao-Zhe Zhu, Hua-Nong Ting, Kwan-Hoong Ng and Teng-Aik Ong.A review on the accuracy of bladder cancer detection methods. Journal of Cancer 2019, Vol. 10 p 4038:4044.
7. Trinh TW, Glazer DI, Sadow CA, Sahni VA, Geller NL and Silverman SG. Bladder cancer diagnosis with CT urography: test characteristics and reasons for false-positive and false-negative results. Abdom Radiol NY(2018),vol 43 page663:671.
8. Song W, Jeon HG, Jeong BC, Seo SI, Jeon SS and Choi HY. Clinical significance of incidentally detected bladder wall thickening on computed tomography. Int Urol Nephrol. (2019),Vol 49 page191:196.
9. Witjes JA, Bruins HM, Cathomas R, Comperat EM, and Cowan NC. European association of urology guides on muscle-invasive and metastatic bladder cancer.Eur Urol. (2021),Vol 79 issue 1 p 82–104.
10. Ibrahim J , Sean O, Laura B, Peter C, Eva G, Ashish , Lambertus K, Nathan L, Seth P,Joshua M, Holger M, Andrea N, Valeria P, Srikala S,Ariana Z, James W and Marcus G. Epidemiology of Bladder Cancer in 2023: A Systematic Review of Risk Factors. EUROPEAN UROLOGY (2023),Vol 84 P 176 -190.
11. Zhao X, Wang Y and Liang C. Cigarette smoking and risk of bladder cancer: a dose-response meta-analysis. Int Urol Nephrol (2022),Vol 54 P 1169-1185.
12. Jacob L, Freyn M, Kalder M, Dinas K and Kostev K. Impact of tobaccosmoking on the risk of developing 25 different cancers in the UK: a retrospective study of 422,010 patients followed for up to 30 years. Oncotarget (2018),Vol 9 P 17420-17429.
13. Hisham R, Mohamad M, Mostafa A and Mohamed A. Urinary bladder carcinoma pattern at urology Minia university hospital. MJMR (2021)Vol 32 No 1 P 36-43.
14. Biardeau X, Lam O, Campeau L and Corcoos J. Prospective evaluation of anxiety, pain and embarrassment associated with cystoscopy and urodynamic testing in clinical practice. Can.Urol.Assoc. J (2017)Vol 11 P 104-110.
15. Tony T, Daniel G, Chery S, Anik S , Nina G and Stuart S. Bladder cancerdiagnosis with CT urography: test characteristics and reasons for false positive andfalse-negative results. Abdom Radiol (2018),Vol 43 P 663–671.
16. Lee C, Tan H, Faria S and Kundra V. Role of imaging in the local staging of urothelial carcinoma of the bladder. Am J Roentgenol. (2017),Vol 208 P 1193–1205.
17. Ola A, Sahar E and Ali N. Urinary bladder neoplastic masses finding

- through multidetector row CT urography. *Med. J. Cairo Univ.* (2019), Vol 87 No 7 P 4093-4101.
18. Martingano P, Stacul F, Cavallaro M, Casagrande F, Cernic S, Belgrano M and Cova M. 64-Slice CT urography: 30 months of clinical experience. *Radiol Med* (2010), Vol 115 P 920–935.
 19. Ljungberg A, Segelsjö M, Dahlman P, Helenius M, Magnusson M, and Magnusson A. Comparison of quality of urinary bladder filling in CT urography with different doses of furosemide in the work-up of patients with macroscopic hematuria. *Radiography* (2021), vol 27 P 136-141.
 20. Suleiman A, Carl H, Dragan V, Staffan J, Henrik L and Henrik K. Computed tomography urography with corticomedullary phase can exclude urinary bladder cancer with high accuracy, *BMC Urology* (2022), vol 22 issue 60.
 21. Helenius M, Brekkan E, Dahlman P, Lonnemark M and Magnusson A. Bladder cancer detection in patients with gross haematuria: computed tomography urography with enhancement-triggered scan versus flexible cystoscopy. *Scand J Urol.* (2015), Vol 49 No 5 P 377–381.
 22. Andre M, Marie L, Mats M, Dahlman P and Malin H. Contrast enhancement in bladder tumor examined with CT urography using traditional scan phases. *Sage Journals* (2014), Vol 55 issue 9.
 23. Wolfman J, Marko P, Khatri G, Dogra S, Ganeshan D, Goldfarb S, Gore Land Gupta T. Expert Panel on Urological Imaging: ACR Appropriateness Criteria of Hematuria. *J. Am. Coll. Radiol.* (2020), Vol 17 P 91–103.