

# Evaluation of Therapeutic Potentials of $\alpha$ -Lipoic Acid Versus Stem Cells-Derived Microvesicles Against Experimentally-Induced Gastric Ulcer in Adult Male Albino Rats (Light and Electron microscopic study)

Original  
Article

Sherifa Abd El-Salam<sup>1</sup>, Eman M. Faruk<sup>1</sup>, Hanan Fouad<sup>2</sup>

<sup>1</sup>Department of Histology and Cell Biology, Faculty of Medicine, Benha University, Egypt

<sup>2</sup>Department of Medical Biochemistry, Faculty of Medicine, Cairo University, Egypt

## ABSTRACT

**Background:** Alpha-Lipoic acid (ALA), is an antioxidant endogenous substance. It is available in small amounts in food. Mesenchymal stem cells (MSCs) derived microvesicles (MSC-MVs) have numerous paracrine protective effects against tissue injury that are mediated by inflammatory, apoptotic and oxidative stress.

**Aim of the Work:** Our study was done to assess the protective effects of Alpha Lipoic Acid versus MSC-MVs on indomethacin-induced gastric ulcer in rats.

**Material and Methods:** Forty adult male rats were divided into: Group I (10 rats) represented control animals, and Group II (30 rats) involved ulcerated rats. The ulcerated group received a single gavage of indomethacin (30mg/kg B.Wt.) and was equally subdivided into: Subgroup II-a (ulcerated subgroup), subgroup II-b ulcerated rats that received a single intravenous dose of MSCs-MVs (0.5 mg/mL) and subgroup II-c ulcerated rats that received ALA (100 mg/kg) orally for 3 days before ulcer induction. Antioxidant enzymes and ulcer index were assessed. Gastric tissue was examined by light and transmission electron microscopes.

**Results:** Indomethacin caused marked damage of the gastric mucosa and ulcer index was significantly higher as compared to the control group. There was loss of the normal histological architecture and inflammatory cells infiltration. Ultrastructure sections revealed increased mucin granules in surface mucous secreting cells. Parietal cells showed dilatation of intracellular canaliculi. In ALA and in MSCs-MVs treated rat groups, there was a significant increase in antioxidant enzyme activities. The structure of the mucosa was significantly improved with a significant decrease in gastric ulcer area. Erosions, necrosis and inflammatory cell infiltration were significantly decreased. No major damage of endothelial cells was observed. The parietal cells count and the VEGF -positive cells were significantly decreased as compared with the control group.

**Conclusion:** MSCs-MVs have significant superior therapeutic effects on gastric mucosa against indomethacin-induced gastric ulcer than the protective effects of  $\alpha$ -Lipoic acid (ALA).

**Received:** 27 May 2019, **Accepted:** 09 June 2019

**Key Words:**  $\alpha$ -Lipoic acid, indomethacin, parietal cell and VEGF, ulcer.

**Corresponding Author:** Eman M. Faruk, MD, Department of Histology and Cell Biology, Faculty of Medicine, Benha University, Egypt, **Tel.:** +20 133221937, **E-mail:** faruk\_eman@yahoo.com

**ISSN:** 1110-0559, Vol. 42, No. 4

## INTRODUCTION

Gastritis is inflammation of the stomach mucosal lining. It can range from mild, asymptomatic to severe ulcerative form, which if untreated could lead to perforation<sup>[1]</sup>. Peptic ulcer diseases (PUDs) are painful sores or ulcers that affected the lining mucosa of the stomach or the first part of the duodenum<sup>[2]</sup>. Major complications of PUDs are bleeding, penetration, perforation or obstruction<sup>[3,4]</sup>. Numerous causes that induce development of PUDs include: *H. pylori* infection, NSAIDs intake, smoking, alcoholism, Zollinger-Ellison syndrome, family history and others<sup>[5]</sup>.

"Indomethacin induced damage" is considered as standard model of gastric ulcer in rats in order to study

pharmacological and pathophysiological effects<sup>[1]</sup>. Prokaryotic and eukaryotic cells are the main site of Alpha lipoic acid (ALA) as it acts as an effector in the mitochondrial enzymes pathway. Also, ALA is present in all types of foods especially in spinach, yeast extract, liver, and kidney<sup>[6]</sup>. Alpha-Lipoic acid (ALA) has beneficial effect as it is considered a strong antioxidant so, it can be used to protect and to treat many diseases<sup>[7,8]</sup>.

On the other hands, (MSCs) derived micro vesicles (MSCs-MVs) mediate various biological effects and might be the main paracrine mechanism of communications between stem cells and injured cells. Yang *et al.*,<sup>[9]</sup> evaluated the effects of MSCs-extracellular vesicles on experimental colitis. The therapeutic effects of MSCs-extracellular vesicles were mediated by the free radical scavenging

activity, down regulation of the proinflammatory cytokine levels, inhibition of NFκBp65 signal transduction pathway and inhibition of the apoptosis<sup>[9]</sup>.

The present study was conducted to compare and evaluate the antiulcerogenic and antioxidant effects of Alpha lipoic acid versus MSC-MVs on Indomethacin-induced gastric lesions in rats.

## **METHODS**

---

### ***Animal grouping***

Male rats (40 animals, 150-250 g B. Wt) were obtained from an inbred colony in the animal house of Faculty of Veterinary Medicine, Benha University, Animals were kept at temperature (22 ± 2oC) and humidity (60%), with light: dark cycle alternates every 12 hours and free access to food and water. They received a balanced diet. All animal procedure was done accordance to the proper recommendations in the use and care of experimental animals. Animals were divided into two groups, Group I (Control group) involved 10 rats, Group II (ulcerated group) involved 30 rats that was equally subdivided into: Subgroup II-a (ulcerated subgroup), Subgroup II- b (ulcerated rats received MSCs-MVs). Animals received a single dose of MSCs-microvesicles (MSCs-MVs) at concentration of 0.5 mg/mL injected intravenously via the tail vein and Subgroup II-c (ulcerated rats received alpha lipoic acid).

### ***Chemicals***

1. Indomethacin (Sigma-Aldrich, MERCK, Cat. No. I7378-10G) was dissolved in distilled water. Two mL was given by intragastric gavage (30 mg/kg B.Wt.) to induce acute gastric ulcer<sup>[10]</sup>.
2. Alpha lipoic acid (ALA) (Sigma Aldrich, MERCK Cat No. Q4951-10G) was dissolved in tween solution 0.2% (0.5 mL) before administration to animals (tween is a non-ionic detergent used as an emulsifying agent in biochemical applications -Cat No.9005-64-5). Alpha- lipoic acid was delivered by oral gavage once daily (100 mg/Kg) for three consecutive days before induction of gastric ulcer by Indomethacin<sup>[11]</sup>.

### ***Isolation of MSC-derived Microvesicles***

Microvesicles were separated from the supernatants of 1st, 2nd and 3rd passages of MSCs. Centrifugation at 2000 xg for 20 minutes was conducted to remove the debris. Centrifugation at 100,000 xg for 1 hour at 4oC was done for the cell-free supernatant by using ultracentrifuge of Beckman Coulter Optima L 90 K (AQ11). The pellet was washed by serum-free medium and by HEPES 25 mM (Sigma Aldrich, USA), then an ultracentrifugation was conducted for the 2nd pellet under the same conditions<sup>[12]</sup>.

### ***Identification and detection of MSC-derived Microvesicles***

For detection of homing of MSCs-MVs into gastric tissue in rats, vesicles were labeled with Fluorescent PKH26 Red Cell Linker Kit (Sigma-Aldrich, Egypt) and injected into the tail vein of the Ulcerated group. Fluorescence microscope was used to examine the gastric tissue to visualize homing of PKH26 stained vesicles<sup>[13,14]</sup>.

### ***Macroscopic and Ulcer index study***

All animals were fasted for 12-14 hours and allowed for drinking water only during the last day of experiment. Next day, scarification of all animals were done by cervical dislocation.

The stomach tissues were ligated around the cardiac and pyloric sphincters and filled with 3 mL distilled water. Gastric juice was collected in sterile tubes. Stomachs were incised longitudinally and washed with saline. Lesion in the glandular portion was examined under 10x magnifying lens to evaluate the ulcer formation, number of ulcers per stomach and the severity of ulcers. Mean ulcer score of every animal was stated as ulcer index. Curative percentage and ulcer index were calculated by using formulas previously described<sup>[15,16]</sup>.

### ***Biochemical Studies***

#### ***Measurement of gastric enzymes***

Gastric levels of glutathione (GSH), superoxide dismutase (SOD) and catalase (CAT) enzyme activities were assayed. Half gram of gastric tissue was ground in liquid nitrogen and homogenized in the appropriate buffer on ice for 15 minutes. Homogenates were used for assessment of enzyme activities according to the kit's recommendations<sup>[17,18]</sup>.

Glutathione (GSH) assay. Glutathione was determined by colorimetric detection kit (ThermoFisher Scientific, Cat. No. EIAGSHC) according to manufacturer's recommendations. Results of the GSH were expressed as nmol/mg tissue<sup>[19]</sup>.

#### ***Superoxide dismutase (SOD) and Catalase (CAT) assay***

Commercial kits were used to assess SOD and CAT in stomach tissue according to manufacturer's recommendations (Thermo-fisher Scientific, Cat No. EIASODC for SOD and Cat. No. EIACATC for CAT). Results were presented as mMol/min/mg tissue<sup>[20]</sup>.

### ***Histological study***

#### ***Light microscopic study***

Upper part of the fundus of stomach tissues was fixed in 10% formalin for preparation of Paraffin blocks. Serial

sections of 5  $\mu\text{m}$  in thickness were subjected to HandE staining for histological details,

### **Immunohistochemical study**

Immunohistochemical study for vascular endothelial growth factor (VEGF) (index for angiogenesis) was done by VEGF primary antibodies (monoclonal antibody from Novus Biologicals, USA, Cat. No. NB100-664SS). Citrate buffer and Mayer's hematoxylin were purchased from Thermo-Scientific (Fremont, California USA). For antigen retrieval boiling of citrate buffer (10 mol/L) for 10 min was conducted. Sections were left for 20 min to cool down at room temperature. Primary antibodies were added to sections and incubation for 1 h was done. Secondary antibody was added (Biotin conjugated, Novus biologicals, USA, Cat No. MKB-2225-NB). Reaction was visualized using DAB; 3,3'-diamino-benzidine peroxidase substrate kit (Vector Labs, USA, Cat No. SK-4100). Mayer's hematoxylin was used for counterstaining (Cat. No. TA-060-MH). Finally, Diaminobenzidine (DAB) chromogen solution was added and counter staining was done with Mayer's hematoxylin. For the negative control section, the primary antibodies were excluded. Positive reaction for VEGF appeared in the form of brown cytoplasmic staining. The protocol was previously described by University of Rochester Medical Center. A positive control was taken from a section of human placenta<sup>[21]</sup>.

### **Transmission electron microscopic study (TEM)**

Fixation in 2.5% phosphate-buffered glutaraldehyde (pH 7.4) was conducted for 1mm of the upper part of the fundus of the stomach specimens. Stomach tissues were post fixed using 1% Osmium-Tetroxide at 4oC. The fixed gastric tissue samples were processed till embedding in Epon. Ultrathin sections (50 – 60 nm) were prepared by using ultramicrotome. Sections were subsequently mounted on copper grids and stained with lead citrate and uranyl acetate<sup>[22]</sup>. Ultrathin sections were assessed and photographed by using a JEM-1200EXII, TEM in Faculty of Science, Ain-Shams University.

### **Morphometric study**

Image - Pro Plus program (version 6.0; Media Cybernetics Inc., Bethesda, Maryland, USA.) was used for morphometric study at the Pathology department, Faculty of Medicine, Cairo University for measuring: First; the mean number of cells lining fundic glands (surface cell, mucous neck cell, chief cell and parietal cell) from all experimental groups stained by hematoxylin and eosin-staining, 10 cells per section were observed (per high power field ) at X 40 objective from each animal of all groups and Second; the mean percentage of VEGF immunoexpression. Statistical analyses were carried out using IBM SPSS statistics software for Windows (version 19; IBM Corp., Armonk, New York, USA).

### **Statistical Analysis**

Results were exhibited as mean  $\pm$  SE. Student paired

t-test, one-way analysis of variance (ANOVA) and post-hoc tests were used for multiple sample groups comparisons. Statistical significance was considered at  $p < 0.05$ . All tests were conducted by statistical package for social science (SPSS, version 19).

## **RESULTS**

### **Ulcer index result**

The ulcer index in group IIa was very high,  $42.50 \pm 0.83$  which confirm ulcer formation. The ulcer index for rats treated with MSCs-MVs was  $17.53 \pm 0.86$ , a value significantly lower than that of group IIa and group IIc ( $p < 0.05$ ). However, rats taken  $\alpha$ -Lipoic acid showed an ulcer index of  $25.58 \pm 0.57$  which was significantly lower than that of group IIa ( $p < 0.05$ ). (Table 1).

### **Biochemical result**

#### **Effect on the antioxidant markers**

The antioxidant markers, GSH, SOD and CAT were significantly decreased in the indomethacin group when compared with the control group. Moreover, treatment with either lipoic acid or MSCs-MVs improved the antioxidant markers towards the normal group values. Alpha-Lipoic acid showed higher therapeutic effects as compared to MSCs-MVs (Table 2).

### **Histological result**

#### **MSCs-MVs characterization and homing**

Transmission electron microscope revealed that the MSCs-MVs were rounded in shape (diameter less than 100 nm) (Figure 1A). Microvesicles labelled with PKH26 fluorescent dye were identified *in vitro* by a fluorescent microscope as strong red fluorescence (Figure 1B).

#### **Light microscope findings**

Stained sections by HandE of the control group showed normal architecture of the gastric mucosa. The gastric glands appeared narrow, numerous, straight, and perpendicular to the surface epithelium and filling the whole thickness of the mucosa. Smooth muscle fibers and blood vessels were present in the lamina propria. The gland has mucous cells (columnar with pale cytoplasm), parietal cells (central rounded nuclei) and chief cells in the basal region (columnar with basal oval nuclei, basal basophilic cytoplasm, and pale apical part) (Figure 2 AandB). The resulting mucosal lesions in subgroup IIa showed superficial damage with distorted shape of the gastric glands. The cells lining the damaged glandular area appeared shrunken with deeply acidophilic cytoplasm (Figure 2C). Basal part of the gland showed loss of architecture with inflammatory cells in the lamina propria with dilated and congested capillaries (Figure 2D).

Stained sections by HandE in subgroup IIb showed deep eosinophilic cytoplasmic epithelial cells with vacuolization of some cells, also increase in mucus secreting cells with inflammatory cells in lamina propria and widened gastric pits (Figure 2E).

In subgroup IIc sections showed that the gastric mucosa was more or less similar to the control group with inflammatory cells infiltration and congested blood vessels in the lamina propria (Figure 2F).

### **Immunohistochemical result**

Stained sections by VEGF of the control group showed moderate positive reaction for VEGF in the cells of the fundic glands (Figure 3A), while in subgroup IIa showed negative reaction for VEGF compared to the control group (Figure 3B). Both subgroup IIb and subgroup IIc showed strong positive reaction for VEGF (Figure 3CandD).

### **Electron microscope result**

Examination of the gastric mucosa of control group revealed normal ultrastructure of different cells covering gastric mucosa. The chief cells showed rounded euchromatic nuclei with smooth nuclear membrane and their cytoplasm showed mitochondria and apical pale zymogenic secretory granules (Figure 4A). Also, the gastric mucosa of the control group showed parietal cells that had numerous mitochondria, euchromatic nuclei with narrow intracellular canaliculi (Figure 4B) and the surface mucous-secreting cells showed rounded, multiple and electron-lucent mucous vacuoles in the cytoplasm with euchromatic nuclei. (Figure 4C).

The resulting electron microscopic examination of the mucosal lesions in subgroup IIa showed severe damage of the chief cells with small indented nuclei, few secretory granules and dilated cisterna of rough endoplasmic reticulum (Figure 4D). Some parietal cells had marked dilation of the intracellular canaliculi. Others showed electron-dense cytoplasm containing mitochondria (Figure 4E). Also showed surface mucous cells containing apical electron-lucent mucoid granules of different sizes with irregular nuclei (Figure 4F).

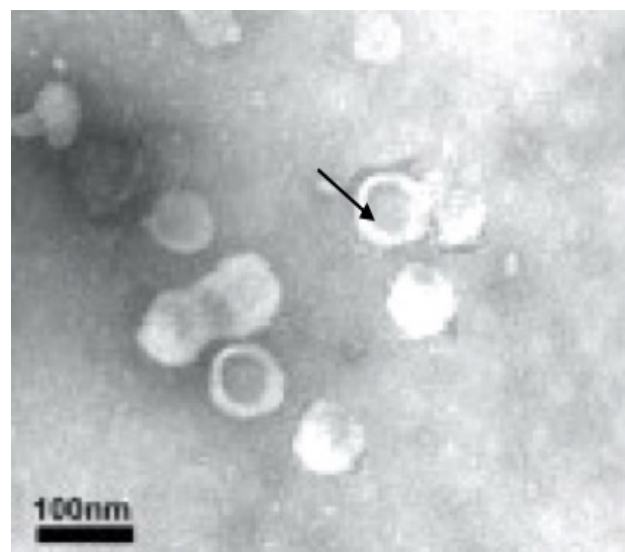
Examination of the gastric mucosa of subgroup IIb showed nearly the same ultrastructural features as the control group in which chief cells showed euchromatic nuclei, zymogenic granules and rough endoplasmic reticulum (Figure 5A). The parietal cells were nearly similar to control, having euchromatic nuclei, intact intracellular canaliculi with large number of mitochondria (Figure 5B). While the mucous cells in subgroup IIc showed different shapes of granules. The chief cells restored the normal shape of its nucleus and zymogenic granules (Figure 5C). Presence of a typical tubulovesicular appearance together with intracellular canaliculi was characterized in the cytoplasm of the parietal cells (Figure 5D).

### **Morphometric result**

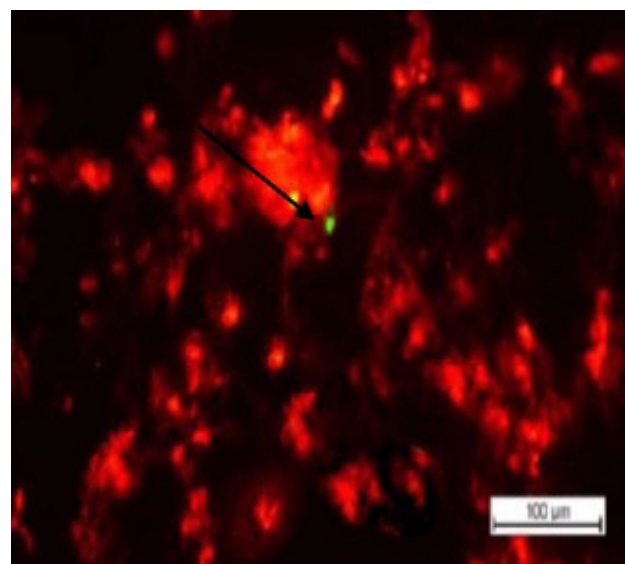
The mean count of different cells lining the fundic glands in control group were: mucous neck cells  $8.46 \pm 0.48$ ; parietal cells  $11.16 \pm 2.24$  and chief cells  $36.84 \pm 2.04$ . There was non-significant difference ( $p$  value  $> 0.05$ ) in the count of different cells lining the gastric glands after MSCs-MV administration in comparison to that of the control group as

shown in (Table 3). In ulcerated group, most cells lining the fundic glands (mucous neck cells, parietal cells and chief cells) showed high significant decrease ( $p$  value 0.01) in count in comparison to that of the control. Treatment with both Alpha lipoic acid and MSCs-MV significantly restore the count of all cells that lining the gastric glands when compared with indomethacin group. In addition, there was non-significant decrease ( $p$  value  $> 0.05$ ) in diameter of all cells lining the gastric glands after treatment with both Alpha lipoic acid and MSCs-MVs when compared with control group as shown in (Table 3).

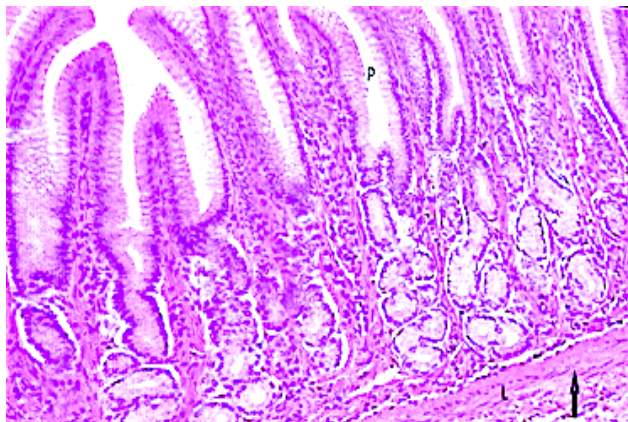
The mean number of VEGF -positive cells showed a significant reduction in subgroups IIa as compared to the control group, whereas the other treated groups showed a significant elevation as compared to control group and indomethacin treated group as shown in (Table 3).



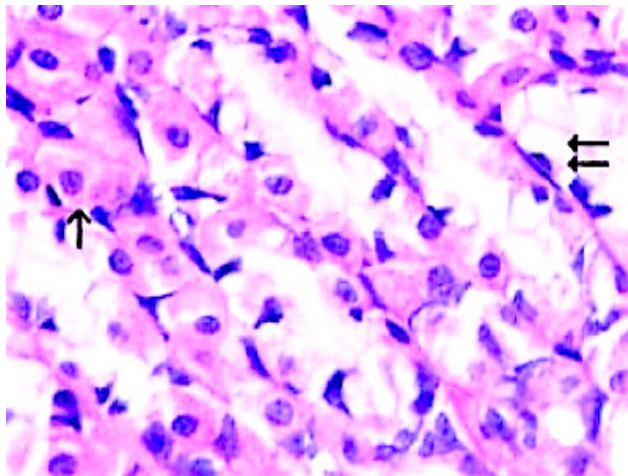
**Fig. 1A:** Representative electron microscopy image of identified microvesicles isolated from fibroblasts and MSCs using ultracentrifugation (arrow). Scale bar: 100 nm.



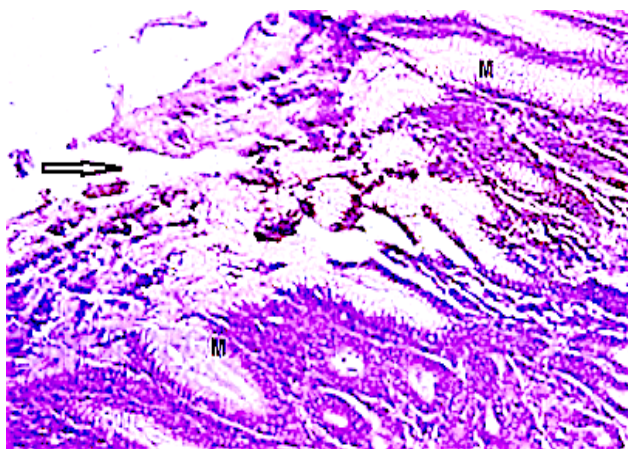
**Fig. 1B:** A fluorescent microscope photograph showing micro-vesicle labelled with PKH26 fluorescent dye in gastric mucosa (arrow) ( $\times 1000$ ).



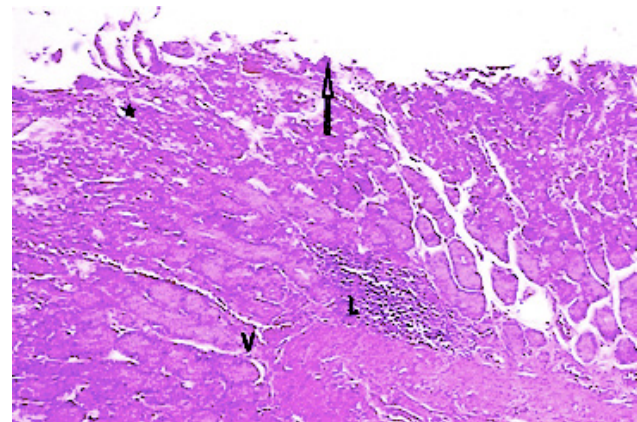
**Fig. 2: (A)** A photomicrograph of a section of the upper part of the fundus of the stomach from control group showing normal architecture of the gastric mucosa with gastric pits (P), lamina propria containing gastric glands (L) which appeared narrow, numerous tightly packed, straight, and perpendicular to the surface epithelium and occupying the whole thickness of the lamina propria. The lamina propria contained blood vessels and smooth muscle fibers(arrow), HandE X 200



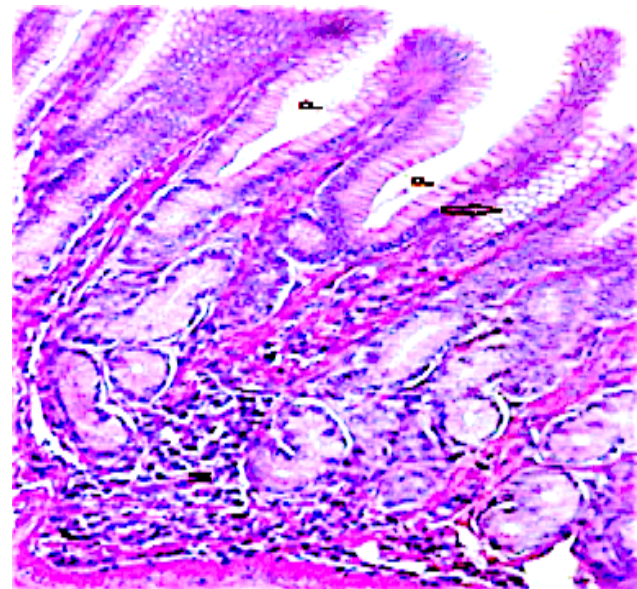
**Fig. 2: (B)** A section of the upper part of the fundus of the stomach from control group showing surface columnar mucous cells with pale cytoplasm (two arrow) and parietal cells (one arrows) with central rounded nuclei and eosinophilic cytoplasm, HandE X 400.



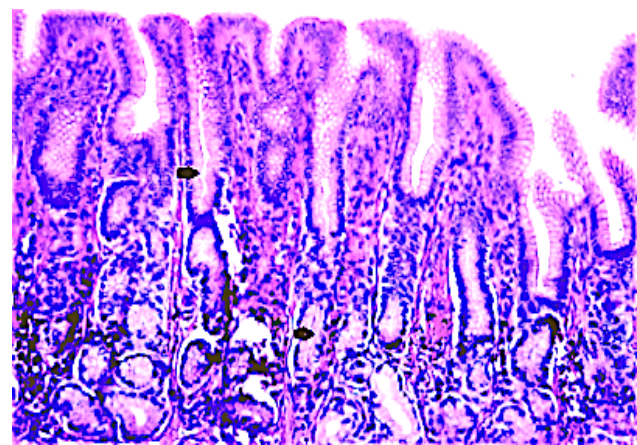
**Fig. 2: (C)** A section of the upper part of the fundus of the stomach from the indomethacin subgroup IIa showing epithelial erosion (arrow) with increased mucous cells with distorted nuclei and lightly stained cytoplasm (M). HandE X 400.



**Fig. 2: (D)** A section of the upper part of the fundus of the stomach from the indomethacin subgroup IIa showing loss of architecture of superficial epithelium and gastric pits (arrow). Mononuclear cellular infiltration in the lamina propria (L) with congested blood capillaries (V). Notice the damaged glandular area with loss of cellular arrangement (\*). HandE X 400

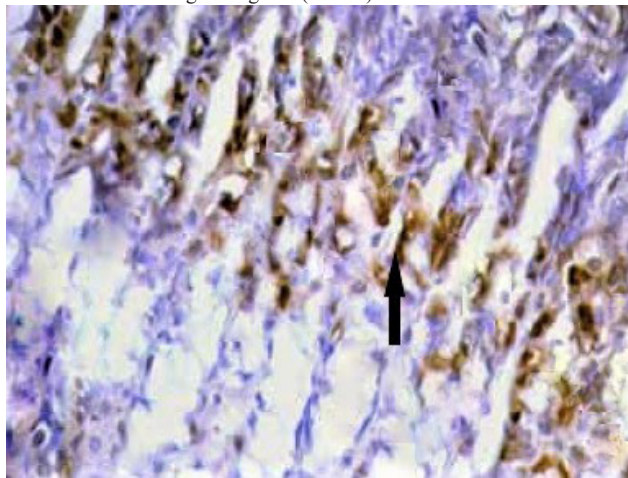


**Fig. 2: (E)** A section of the upper part of the fundus of the stomach from the MSCs-MVs subgroup showing almost normal gastric mucosa with wide gastric pits (P) and increase mucous cells (arrow). HandE X 400

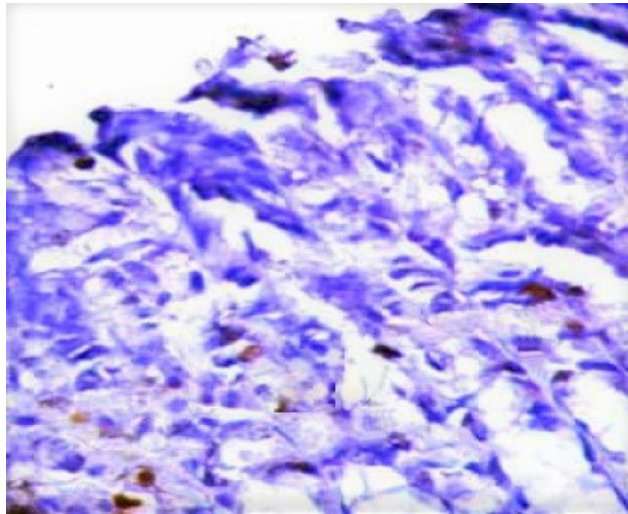


**Fig. 2: (F)** A section of the upper part of the fundus of the stomach in rats treated by alpha-lipoic acid subgroup showing almost normal gastric

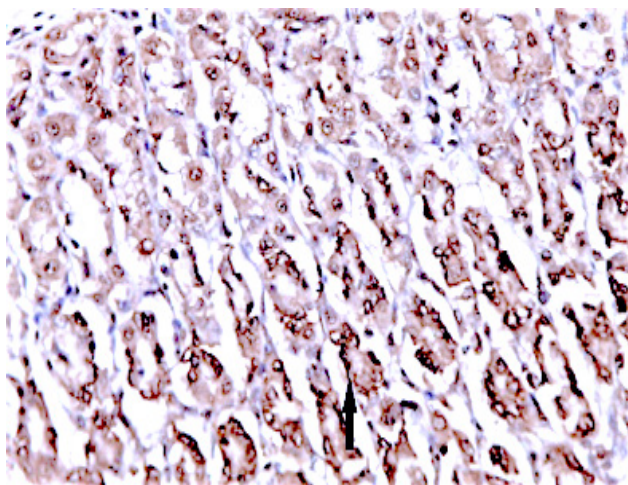
mucosa with normal gastric gland (arrows) HandE X 400.



**Fig. 3:** (A) A photomicrograph of a section of the upper part of the fundus of the stomach showing: (A) A moderate positive reaction for VEGF in the cells of the fundic glands of control group. VEGF immunostaining X 400.

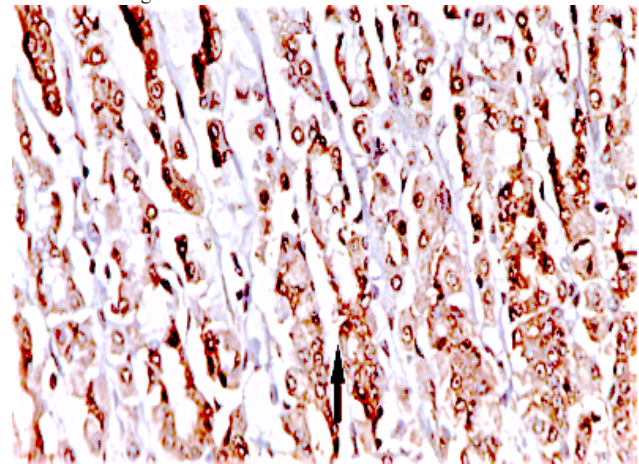


**Fig. 3:** (B) A negative reaction for VEGF in the cells of the upper part of the fundic glands of indomethacin subgroup IIa. (VEGF immunostaining X 400).

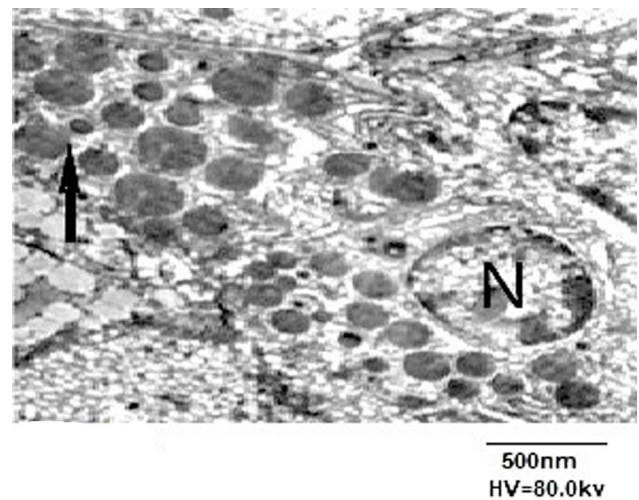


**Fig. 3:** (C) A strong positive reaction for VEGF (arrow) in the cells of the upper part of the fundic glands of MSCs-MVs subgroup. VEGF

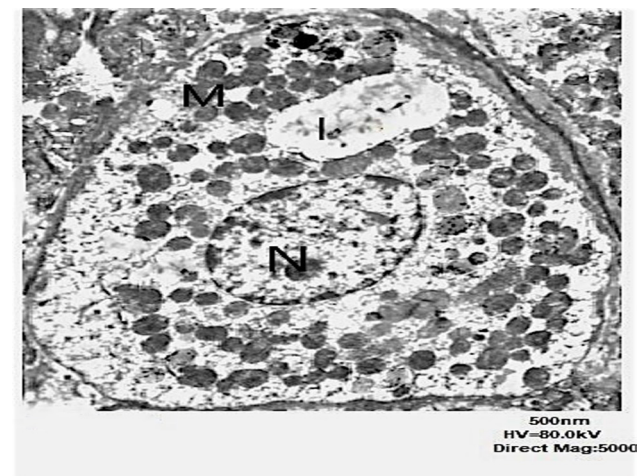
immunostaining X 400.



**Fig. 3:** (D) A strong positive reaction for VEGF (arrow) in the cells of the upper part of the fundic glands of alpha-lipoic acid subgroup. VEGF immunostaining X 400.

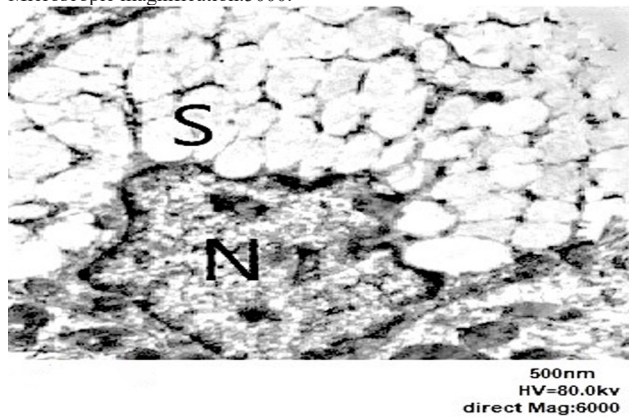


**Fig. 4:** (A) A photoelectron micrograph of a section of the glandular of the upper part of the fundic mucosa of a control rat showing a pyramidal chief cell with a basal rounded nucleus (N), zymogenic granules in the apical part of the cell (arrow). (E. M X 5000).



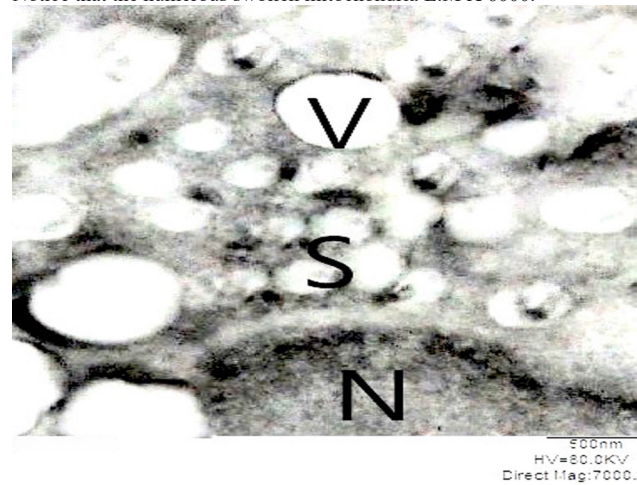
**Fig. 4:** (B) A section of the upper part of the fundic mucosa of stomach of a control rat showing a parietal cell with a euchromatic nucleus (N), numerous mitochondria (M), and narrow intracellular canaliculi (I).

Microscopic magnification.5000.

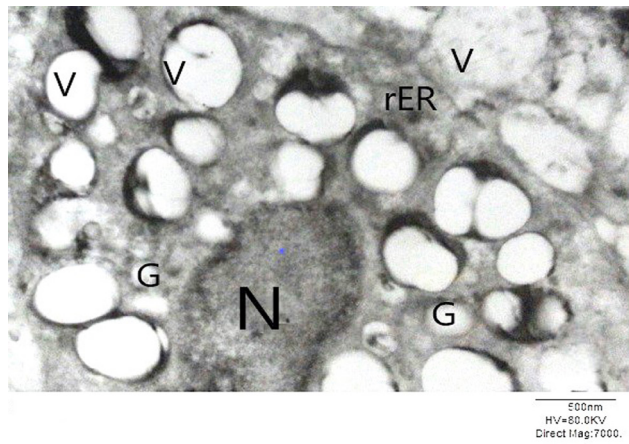


**Fig. 4: C)** A section of upper part of the fundic mucosa of control rat showing surface mucous cell lining of gastric fundic gland with basal nucleus (N) and apical electron lucent secretory granules (S). E.M X 6000.

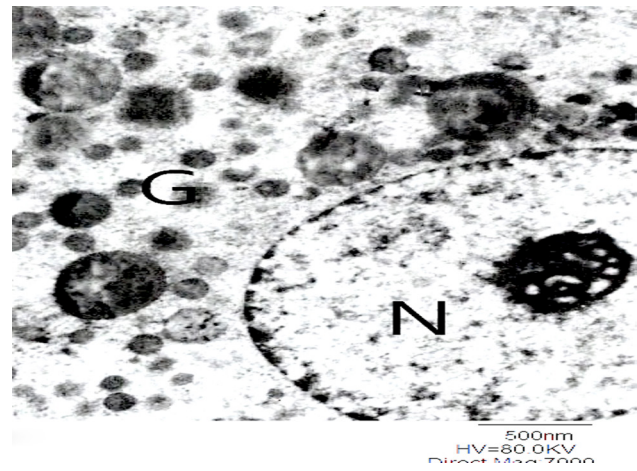
Notice that the numerous swollen mitochondria E.M X 6000.




**Fig. 4: (F)** A photoelectron micrograph of a section of the upper part of the fundic mucosal epithelial cells of stomach of indomethacin subgroup showing irregular basal nucleus (N), mucus secretory granules (S) and cytoplasmic vacuoles (V). E.M X 7000.




**Fig. 4: (D)** A photoelectron micrograph of a section of upper part of the fundic mucosal epithelial cells of stomach of indomethacin subgroup IIa showing chief cell with irregular heterochromatic nucleus (N), multiple degenerated zymogenic secretory granules (G) and vacuolation (V). Notice, degenerated rough endoplasmic reticulum (rER) in between the vacuoles. E.M X 7000.



**Fig. 5: (A)** A photoelectron micrograph of a section of the glandular of the upper part of the fundic mucosa of MSCs-MVs subgroup showing normal chief cell with intact nucleus (N), and apical zymogenic granules (G). (E. M X 7000).

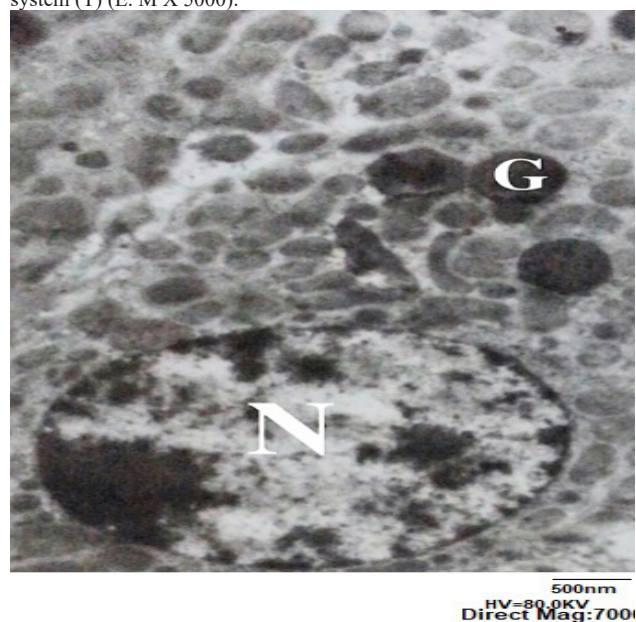


**Fig. 4: (E)** A photoelectron micrograph of a section of upper part of the fundic mucosal epithelial cells of stomach of indomethacin subgroup showing parietal cell with small irregular pyknotic nucleus (N), cytoplasmic vacuoles (V) with dilatation intracellular canaliculi (I).

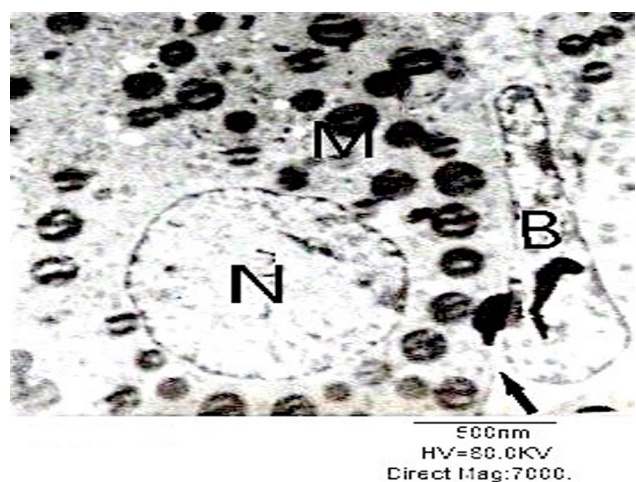


**Fig. 5: (B)** A photoelectron micrograph of a section of the glandular of the upper part of the fundic mucosa of MSCs-MVs subgroup showing normal parietal cell showing nearly similar to control rounded euchromatic basal nucleus (N), numerous mitochondria (M) and extensive tubulovesicular

system (T) (E. M X 5000).



**Fig. 5:** (C) A photoelectron micrograph of a section of the upper part of the fundic mucosa from alpha-lipoic acid treated subgroup showing chief cell with intact nucleus (N), and apical zymogenic granules (G). (E. M X 7000).



**Fig. 5:** (D) A photoelectron micrograph of a section of the glandular of the upper part of the fundic mucosa from alpha-lipoic acid treated subgroup showing Normal shaped parietal cell with regular cell membrane (arrow), normal nucleus (N) and mitochondria (M). Notice that the blood vessels(B). (E. M X7000).

**Table 1:** Ulcer Index in the studied rat groups

Group	ulcer index (GI) ± SD	% Curative ratio
I	00.00	-----
IIa	42.50mm±0.83	-----
IIb	18.52mm±0.86* #	58.16
IIc	24.59mm±0.17* #	28.64

All values are expressed as mean ± SD.

\* Significant difference between MSCs-MVs subgroup (IIb) vs Indomethacin treated subgroup (IIa), *p* < 0.05.

# Significant difference between MSCs-MVs subgroup (IIb) vs Alpha-lipoic acid treated subgroup (IIc), *p* < 0.05.

GI mean gastric index and mm= size in millimeter

**Table 2:** Effects of different treatment protocols on the level of various antioxidant markers in the studied rat groups

Group	GSH μmol/L	SOD U/ml	CAT μmol/L
I	5.65±0.08	47.76±0.86	232.40±2.88
IIa	1.02±0.03	22.92±0.64	103.40±2.13
IIb	3.23±0.02*	39.70±0.68*	186.55±3.47*
IIc	4.19±0.03*#	42.45±0.71*#	206.58±4.16*#

All values are expressed as mean ± SD.

\* Significant difference between MSCs-MVs subgroup (IIb) vs Indomethacin treated subgroup (IIa), *p* < 0.05.

# Significant difference between MSCs-MVs subgroup (IIb) vs Alpha-lipoic acid treated subgroup (IIc), *p* < 0.05.

**Table 3:** Mean count of cells lining glands in control and experimental rats

Group	Mucous neck cell number	Parietal cell number	Chief cell number	Number of VEGF -positive cells/HPF
I	8.46±0.48	11.16±2.24	36.84±2.04	23.60±5.03
IIa	4.16±1.01*	18.82±1.64*	28.94±5.04*	3.30±0.92*
IIb	8.26±0.51	12.12±1.24	37.24±1.04	23.70±5.41
IIc	7.86±1.44	10.85±0.54	34.64±2.12	24.25±8.42

Values are mean ± SD *P* > 0.05 (NS). \* *P* < 0.01 (HS)

## DISCUSSION

The pathogenesis of Indomethacin-induced gastric ulceration has been attributed to its inhibitory effects on prostaglandin synthesis as well as free radical formation<sup>[23]</sup>. Indomethacin as one of NSAIDs is frequently used as analgesic. Due to its inherent common side effects and the high cost of gastric ulcer pharmaceuticals, several studies evaluated the effect of natural products of plant origin which proved to be affordable, efficacious and non-toxic. The present study was conducted to evaluate the protective effects of Alpha lipoic acid versus MSC-MVs on indomethacin-induced gastric ulcer in rats.

The histological observations in the ulcerated subgroup IIa revealed areas of loss of superficial epithelium and ulceration. Moreover, there was destruction of the mucosal epithelial cells that showed pyknotic nuclei and highly eosinophilic cytoplasm that extended along the length of fundic glands from the neck to the base. These results agreed with previous studies<sup>[24,25]</sup>. Moreover, the antioxidant markers; GSH, SOD and CAT were significantly decreased. These results explain that indomethacin-induced damaging effect was due to the generation of reactive oxygen species (ROS) such as hydroxyl radicals and superoxide radical anions and. Decreased antioxidant markers, together with indomethacin-induced prostaglandins suppression, lead to occlusion of the micro-vessels and subsequent overproduction of ROS metabolites. Especially, indomethacin leads to gastric ulcerations, decreased glutathione peroxidase enzyme activity and increased lipid peroxidation.



Treatment of the ulcerated subgroups with either Alpha lipoic acid or MSCs-MVs showed significant amelioration of the gastric mucosal injury with normal white mucosal rugae and significant decrease in the ulcer index. However, the therapeutic benefits of Alpha lipoic acid significantly exceeded that of MSCs-MVs. This observation could be attributed to the repeated doses of  $\alpha$ -Lipoic acid whereas, MSCs-MVs was administered as a single dose.

Our results revealed that the pretreatment with  $\alpha$ -Lipoic acid lead to a significant decrease in the ulceration of the stomach suggested by presence of normal appearance of the gastric mucosa with a significantly decreased in ulcer index. Similar results were reported<sup>[25,26]</sup>. On the other hand, pretreatment with  $\alpha$ -Lipoic acid improved the decrease in the antioxidant markers; GSH, SOD and CAT levels which occurred after experimentally induced gastric ulcer. Other studies that used other animal models were showed the antioxidant activities of ALA<sup>[27]</sup>. Moreover, Kaplan *et al.*<sup>[28]</sup> stated that  $\alpha$ -Lipoic acid protects against gastric mucosal inflammation, oxidations and apoptosis caused by indomethacin by affecting the levels of apoptosis regulator BCL-2-associated protein X (BAX), and by the enhance in the antioxidant system.

As regards effects of injection of microvesicles (MSCs-MVs), our results showed their significant therapeutic effects by amelioration of the gastric mucosal injury induced by indomethacin. Stained sections by HandE of subgroup Iib (MSCs-MVs) were nearly similar in structure as normal gastric mucosa with inflammatory cells infiltration in lamina propria and enlarged gastric pits. Results of transmission electron microscopy (TEM) showed that MSCs-MVs treated group had surface mucous-secreting cells filled with mucin granules of variable size. Some were electron lucent and other electron-dense and had many vacuolations in the cytoplasm. The presence of many dilated intracellular canaliculi in parietal cells suggested their activity. There was also a significant elevation in the antioxidant marker levels (GSH, SOD, CAT) but their levels were not normalized as compared to control group. Immunohistochemical evaluation of VEGF revealed that there was a significant increase in VEGF expression in both subgroups treated with ALA or MSCs-MVs. Our findings coincided with previous studies conducted by Kang *et al.*<sup>[29]</sup> and El-Azab *et al.*<sup>[30]</sup> who stated that healing of gastric ulcers is accelerated via regulation of VEGF and angiogenesis. Furthermore, MSCs exert significant therapeutic effects in gastric ulcer via secretion of growth factors such as VEGF which induces angiogenesis and preserves the blood supply to gastric mucosa. Stem cells have a significant anti-inflammatory potential by decreasing inflammatory cytokines associated with gastric inflammation as reported by El-Azab *et al.*<sup>[28]</sup>.

To the best of our knowledge this is the first study conducted to evaluate the effects of microvesicles from MSCs in the treatment of experimental gastric ulcer. However, previous studies were conducted to evaluate

MSCs or microvesicles on other pathological types of ulcers such as diabetic foot ulcer.

Li *et al.*<sup>[31]</sup> showed that induced pluripotent stem cells derived exosomes (iPS-Exos) exerted a significant therapeutic effect on experimental diabetic ulcer wound healing via promotion of fibroblast migration *in vitro* and *in vivo*. Exosome is a microvesicle that is exocytosed with the phospholipid bilayer and surface antigens. It was reported that exosomes contain miRNA and proteins that could mediate their therapeutic effect by transmitting genetic and non-genetic information communicating cells<sup>[32]</sup>. Another study conducted on experimental colitis with ulceration showed that Intravenous injection of MSCs-MVs attenuated the severity of colitis as shown by the decrease in the histological colonic damage and the disease activity index. The beneficial therapeutic effects of MSCs-MVs were mediated by modulation of anti-oxidant/ oxidant balance, down regulation of pro-inflammatory cytokines levels, suppression of the apoptosis and inhibition of NF- $\kappa$ Bp65 signal transduction pathways<sup>[10]</sup>. The aforementioned studies stated that exosomes or microvesicles derived from stem cells contain diverse proteins, micro-RNAs, mRNA that could mediate several biological functions and might be the main paracrine mechanism for stem cells-injured cell communication.

In conclusion, Alpha-Lipoic acid (AL) and MSCs-MVs have significant protective effects on gastric mucosa against indomethacin -induced gastric ulcer. Alpha-Lipoic acid showed higher significant antioxidant effect in comparison to the MSCs-MVs, whereas, MSCs-MVs is better than ALA in other parameters so, assessment of the optimal dosage schedule of stem cells derived microvesicles is highly recommended.

#### CONFLICT OF INTEREST

There are no conflict of interest.

#### REFERENCES

1. Sipponen . P, Maaros. HI. Chronic. gastritis. Scand . J. Gastroenterol. 2015; . 50(6):657-667.
2. Lanas . A, . Chan . FKL. . Peptic . ulcer . disease. . Lancet . 2017; . 390(10094):613-624.
3. Milosavljevic. T, Kostić-Milosavljević. M, Jovanović. I, Krstić. M. Complications . of . Peptic . Ulcer. Disease. Dig. Dis. 2011; 29: 491–493.
4. Asefa. Z, G/eyesus. A. Perforated. peptic. ulcer. disease. in. Zewditu . Hospital. . Ethiop . Med . J . . 2012; . 50(2):145-151. .
5. Sayehmiri . K, . Abangah . G, . Kalvandi . G, . Tavan . H, . Aazami . S. . Prevalence . of . peptic . ulcer . in . Iran . . Systematic . review . and . meta-analysis . methods. . J . Res . Med . Sci . 2018; . 23:8. .
6. Liu . YH, . Zhang . ZB, . Zheng . YF, . Chen . HM, . Yu . XT, . Chen . XY, . Zhang . X, . Xie . JH, . Su . ZQ, . Feng . XX, . Zeng . HF, . Su . ZR,. Gastroprotective . effect . of . andrographolide.

- sodium bisulfite against indomethacin-induced gastric ulceration in rats. *Int Immunopharmacol* . 26 . (2015) . 384–391.
7. Goraca . A ., Huk-Kolega . H ., Piechota . A ., Kleniewska . P ., Ciejka . E ., Skibska . B .  $\alpha$ -Lipoic acid biological activity and therapeutic potential. *Pharmacol Rep* . 2011; . 63 . (4) : . 849–858 . .
  8. Byun . E ., Lim . JW ., Kim . JM ., Kim . H .  $\alpha$ -Lipoic acid inhibits helicobacter pylori-induced oncogene expression and hyperproliferation by suppressing the activation of NADPH oxidase in gastric epithelial cells. *Mediators Inflamm* . 2014; . 2014 : . 380830 .
  9. Yang . J ., Liu . XX ., Fan . H ., Tang . Q ., Shou . ZX ., Zuo . DM ., Zou . Z ., Xu . M ., Chen . QY ., Peng . Y ., Deng . SJ ., Liu . YJ . Extracellular vesicles derived from bone marrow mesenchymal stem cells protect against experimental colitis via attenuating colon inflammation, oxidative stress and apoptosis. *PLoS One* . . 2015; . 10(10) : . e0140551 . .
  10. Chatterjee . A ., Chatterjee . S ., Biswas . A ., Bhattacharya . S ., Chattopadhyay . S ., Bandyopadhyay . SK . Gallic Acid Enriched Fraction of *Phyllanthus emblica* Potentiates Indomethacin-Induced Gastric Ulcer Healing via e-NOS-Dependent Pathway. *Evid Based Complement Alternat Med* . . 2012; . 2012 : . 487380 . .
  11. Şehirli . Ö ., Tatlıdede . E ., Yüksel . M ., Erzik . C ., Çetinel . S ., Yeğen . BC ., Şener . G . Antioxidant effect of alpha-lipoic acid against ethanol-induced gastric mucosal erosion in rats. *Pharmacology* . 2008; . 81(2) : . 173–180 . .
  12. Gorgun . C ., Reverberi . D ., Rotta . G ., Villa . F ., Quarto . R ., Tasso . R . Isolation and flow cytometry characterization of extracellular-vesicle subpopulations derived from human mesenchymal stromal cells. *Curr Protoc Stem Cell Biol* . 2019; . 48(1) : . e76 . .
  13. Nassar . W ., El-Ansary . M ., Sabry . D ., Mostafa . MA ., Fayad . T ., Kotb . E ., Temraz . M ., Saad . AN ., Essa . W ., Adel . H . Umbilical cord mesenchymal stem cells derived extracellular vesicles can safely ameliorate the progression of chronic kidney diseases. (2016). *Biomater Res* . 2016; . 20 : . 21 .
  14. Faruk . EM ., El-desoky . RE ., Al-Shazly . AM ., Taha . NM . Do exosomes derived bone marrow mesenchymal stem cells restore ovarian function by promoting stem cell survival on experimentally induced polycystic ovary in adult female albino rats? (histological and immunohistochemical study).. (2018) . *Stem Cell Res Ther* . 2018; . 8(12) : . 442 . .
  15. Arafa . Keshk . W ., Zahran . SM ., Katary . MA ., Abd-Elaziz . Ali . D . Modulatory effect of silymarin on nuclear factor-erythroid-2-related factor 2 regulated redox status, nuclear factor- $\kappa$ B mediated inflammation and apoptosis in experimental gastric ulcer. *Chem Biol Interact* . . 2017; . 273 : . 266-272 .
  16. Nabavizadeh . F ., Alizadeh . AM ., Adeli . S ., Golestan . M ., Moloudian . H ., Kamalinejad . M . Gastroprotective effects of *Stachys Lavandulifolia* extract on experimental gastric ulcer. *Afr J Pharm Pharmacol* . 2011; . 5(2) : . 155-159 . .
  17. Aziz . RS ., Siddiqua . A ., Shahzad . M ., Shabbir . A ., Naseem . N . Oxyresveratrol ameliorates ethanol-induced gastric ulcer via downregulation of IL-6, TNF- $\alpha$ , NF- $\kappa$ B, and COX-2 levels, and upregulation of TFF-2 levels. *Biomed Pharmacother* . 2019; . 110:554-560 . .
  18. Freitas . FF ., Fernandes . HB ., Piauilino . CA ., Pereira . SS ., Carvalho . KI ., Chaves . MH ., Soares . PM ., Miura . LM ., Leite . JR ., Oliveira . RC ., Oliveira . FA . Gastroprotective activity of *Zanthoxylum rhoifolium* Lam.in animal models. *J Ethnopharmacol* . 2011; . 137(1) : . 700-708 . .
  19. Wu . X ., Huang . Q ., Xu . N ., Cai . J ., Luo . D ., Zhang . Q ., Su . Z ., Gao . C ., Liu . Y . Antioxidative and anti-inflammatory effects of water extract of *acrostichum aureum* linn. against ethanol-induced gastric ulcer in rats. *Evid Based Complement Alternat Med* . 2018; . 2018 : . 3585394 . .
  20. Atalay . F ., Odabasoglu . F ., Halici . M ., Cadirci . E ., Aydin . O ., Halici . Z ., Cakir . A . N-Acetyl Cysteine has both gastro-protective and anti-inflammatory effects in experimental rat models: its gastro-protective effect is related to its in vivo and in vitro antioxidant properties. *J Cell Biochem* . 2016; . 117(2) : . 308-319 .
  21. Chris . M ., Lorine . B ., Marloes . E ., Hanneke . P ., Peter . T ., Onno . J ., Anti-human vascular Endothelial Growth Factor (VEGF) Antibody Selection for Immunohistochemical Staining of Proliferating Blood Vessels. *Histochem Cytochem* . 2010 . Feb; . 58(2) : . 109–118 .
  22. Schmidli . C ., Rima . L ., Arnold . SA ., Stohler . T ., Syntychaki . A ., Bieri . A ., Albiez . S ., Goldie . KN ., Chami . M ., Stahlberg . H ., Braun .
-

- T. Miniaturized sample preparation for transmission electron microscopy. *J. Vis. Exp.* 2018; (137): 57310.
23. Sabiu S, Garuba T, Sunmonu T, Ajani E, Sulyman A, Nurain I, Balogun A. Indomethacin-induced gastric ulceration in rats: Protective roles of *Spondias mombin* and *Ficus exasperate*. *Toxicol. Rep.* 2015; 2: 261-267.
24. Arunachalam K, Damazo AS, Pavan E, Oliveira DM, Figueiredo FF, Machado MTM, Balogun SO, Soares IM, Barbosa RDS, Alvim TDC, Ascêncio SD, Martins DTO. *Cochlospermum regium* (Mart. ex Schrank) Pilg.: Evaluation of chemical profile, gastroprotective activity and mechanism of action of hydroethanolic extract of its xylopodium in acute and chronic experimental models. *J. Ethnopharmacol.* 2019; 233:101-114.
25. Yehia NM, Abdel Salam NF, Saleh HA, Bayomi NS. Effect of  $\alpha$ -lipoic acid on fundic gastric mucosal damage induced by acetyl salicylic acid: a histological study. *Egypt J. Histol.* 2014; 37(2): 280-291.
26. Veskovic M, Mladenovic D, Jorgacevic B, Stevanovic I, de Luka S, Radosavljevic T. Alpha-lipoic acid affects the oxidative stress in various brain structures in mice with methionine and choline deficiency. *Exp. Biol. Med.* (Maywood). 2015; 240(4): 418-425.
27. Ali SO, Darwish HA, N.A. Ismail NA. Curcumin, silybin phytosome® and alpha-R-lipoic acid mitigate chronic hepatitis in rat by inhibiting oxidative stress and inflammatory cytokines production. *Basic. Clin. Pharmacol. Toxicol.* 2016; 118 (5): 369-380.
28. Kaplan KA, Odabasoglu F, Halici Z, Halici M, Cadirci E, Atalay F, Aydin O, Cakir A. Alpha-lipoic acid protects against indomethacin-induced gastric oxidative toxicity by modulating antioxidant system. *J. Food. Sci.* 2012; 77(11): H224-30.
29. Kang JM, Kim N, Kim B, Kim JH, Lee BY, Park JH, Lee MK, Lee HS, Kim JS, Jung HC, Song IS. Enhancement of gastric ulcer healing and angiogenesis by cochinchina *Momordica* seed extract in rats. *J. Korean. Med. Sci.* 2010; 25(6):875-881.
30. El-Azab NE, Mansy AE, El-Mahalaway AM, Sabry D. Comparative study of the therapeutic effect of pomegranate alone or in combination with bone marrow mesenchymal stem cells on experimentally induced gastric ulcer in adult male rats: A histological and immunohistochemical study. *EJH.* 2018; 41(2):150-166.
31. Li G, Fu J, Zhao Y, Ji K, Luan T, Zang B. Alpha-lipoic acid exerts anti-inflammatory effects on lipopolysaccharide-stimulated rat mesangial cells via inhibition of nuclear factor kappa B (NF-kappaB) signaling pathway. *Inflammation.* 2015; 38(2): 510-519.
32. Kobayashi H, Ebisawa K, Kambe M, Kasai T, Suga H, Nakamura K, Narita Y, Ogata A, Kamei Y. <Editors' Choice> Effects of exosomes derived from the induced pluripotent stem cells on skin wound healing. *Nagoya J. Med. Sci.* 2018; 80(2): 141-153.

## الملخص العربي

# تقييم الاحتمالات العلاجية لحمض ألفا-ليبويك مقابل الحويصلات الصغيرة المشتقة من الخلايا الجذعية الوسيطة ضد قرحة المعدة المستحدثة تجريبياً في الجرذان البيضاء البالغة (دراسة بالمجهر الضوئي والمجهر الإلكتروني)

شريفه عبد السلام<sup>١</sup>، إيمان فاروق<sup>١</sup>، حنان فؤاد<sup>٢</sup>

<sup>١</sup> قسم الأنسجة وبيولوجيا الخلية، كلية الطب، جامعة بنها

<sup>٢</sup> قسم الكيمياء الحيوية الطبية، كلية الطب، جامعة القاهرة

**المقدمة:** حمض ألفا ليبويك وهو مادة داخلية مضادة للأكسدة. وهو متوفر بكميات صغيرة في الغذاء. الحويصلات الصغيرة المشتقة من الخلايا الجذعية الوسيطة لها العديد من الآثار الوقائية على النسيج المصابة نتيجة للالتهابات او نتيجة موت الخلايا المبرمج أو الاكسدة.

**الهدف من البحث:** أجريت هذه الدراسة لتقييم الآثار الوقائية لحمض ألفا ليبويك مقابل الحويصلات الصغيرة المشتقة من الخلايا الجذعية الوسيطة على قرحة المعدة التي يسببها الإندوميثاسين في الجرذان البيضاء البالغة.

**مواد وطرق البحث:** تم تقسيم أربعين جرذان من الذكور البالغة إلى: المجموعة الأولى (عشرة جرذان) وتمثل الحيوانات الضابطة، والمجموعة الثانية (ثلاثون جرذ) تضم الجرذان المتقرحة. تلقت المجموعة المصابة بالقرحة جرعة واحدة من الإندوميثاسين (٣٠ مجم / كجم) وتم تقسيمها إلى: المجموعة الثانية أ (المجموعة المتقرحة)، المجموعة الثانية ب والتي تلقت جرعة واحدة في الوريد من الحويصلات الصغيرة المشتقة من الخلايا الجذعية الوسيطة (٠.٥ ملغم / مل) و المجموعة الثانية ج التي تلقت ( ألفا ليبويك ١٠٠ ملغ / كلغ) عن طريق الفم لمدة 3 أيام قبل استحداث القرحة. تم تقييم الانزيمات المضادة للاكسدة ومؤشر القرحة وايضا تم فحص أنسجة المعدة بواسطة المجهر الضوء والمجهر الإلكتروني.

**النتائج:** تسبب الإندوميثاسين في حدوث أضرار ملحوظة في الغشاء المخاطي في المعدة وكان مؤشر القرحة أعلى بكثير بالمقارنة مع المجموعة الضابطة. كان هناك فقدان للبنية النسيجية الطبيعية، ووجود الخلايا الالتهابية. كشفت التركيب الدقيق عن زيادة حبيبات الغشاء المخاطي في خلايا إفراز الغشاء المخاطي. وأظهرت الخلايا الجدارية عن وجود القناني داخل الخلايا. اما بالنسبة للجرذان المعالجة بألفا ليبويك والحويصلات الصغيرة المشتقة من الخلايا الجذعية الوسيطة كانت هناك زيادة كبيرة في أنشطة مضادات الأكسدة كما تم تحسين التركيب الغشاء المخاطي بشكل كبير مع انخفاض كبير في منطقة قرحة المعدة. وانخفضت بشكل ملحوظ التقرحات والتخرو ووجود الخلايا الالتهابية. لم يلاحظ أي ضرر كبير للخلايا البطانية كما انخفض عدد الخلايا الجدارية والخلايا الايجابية لعامل نمو بطانة الاوعية الدموية بشكل ملحوظ مقارنة مع مجموعة الضابطة.

**الاستنتاج:** الحويصلات الصغيرة المشتقة من الخلايا الجذعية الوسيطة لها تأثيرات علاجية كبيرة على الغشاء المخاطي في المعدة ضد قرحة المعدة المستحدثة باستخدام الإندوميثاسين عن التأثير الوقائي لحمض ألفا ليبويك.