

Mechanical Allodynia and Thermal Hyperalgesia in Diabetic Mice and Neurodegenerative Changes in the Spinal Cord and Sciatic Nerves: Modulation by Topiramate

FATEN ABBAS, MD.*; HOWAIDA S. ALI, M.D.** and DALIA IBRAHIM, M.D.*

The Department Physiology, Faculty of Medicine, Suez Canal University and Pharmacology Department**, Faculty of Medicine, Assiut University*

Abstract

Background: Diabetes-related pathological alterations in body organs may take place due to immunological reactions and inflammatory/oxidative burden.

Aim of Study: The current study aimed to test the neuroprotective effect of topiramate in an animal model of peripheral diabetic neuropathy (DN) and test its ability to suppress the spinal cord inflammatory burden and glial reactivity.

Material and Methods: The study was carried out in Faculty of Medicine, Suez Canal University, Male adult mice were assigned as vehicle group, DN group (alloxan 180mg/kg, i.p.), DN+topiramate 10-mg/kg and DN+topiramate 30-mg/kg. Mice received topiramate therapy for four weeks then tested for allodynia and hyperalgesia. Spinal cord specimens were examined by molecular assays, light microscopic technique and neurofilament heavy chain (NEFH) immunostaining. Sciatic nerves were examined microscopically.

Results: Indicated that DN mice had lower the hotplate latency time (0.46-fold of latency to licking) and lower the von-Frey test pain threshold (0.6-fold of filament size). In contrast, treatment with topiramate increased these values. Sciatic nerve showed axonal degeneration, demyelination, loss of some central axons, and shrunken Schwann cells. Further, spinal cords of DN mice had elevated levels of GFAP (5.6-fold) and lower GAP-43 (0.25-fold), inflammatory cytokines (-3 or 4-fold) and neuronal degeneration with dystrophic neurons.

Conclusion: Topiramate produced neuroprotection and increased pain thresholds in mice with DN, suppressed spinal cord inflammation and GFAP but enhanced plasticity as indicated by higher GAP-43 protein level. Hence, our study reinforces topiramate as neuroprotection and suggests it for alleviating neuropathic pain.

Key Words: GFAP — Mouse diabetic neuropathy — Neurofilament — Pain test — Sciatic nerve — Spinal cord.

Introduction

NEUROPATHIC pain is defined as "pain caused by a lesion or disease of the somatosensory system" that may take place as a result of nerve damage. Still, it is often followed by changes in the CNS [1]. Half of patients with DN present with chronic peripheral neuropathic pain [2,3] which is often hard to treat or manage. The pain reduces the quality and adds a burden on patients life and increases the associated health costs [4].

Various molecular pathways are correlated with impaired nerve function and pathological abnormalities in neurons including production of advanced glycation end-products and enhanced glucose metabolism via oxidative metabolism and oxidative stress. In addition, recent advances suggest that the neuronal death occurs via generation of reactive oxygen species (ROS) and mitochondrial dysfunction [5,6]. Oxidative stress is a common mediator of all of the hyperglycemia-induced pathways included in the pathology of diabetes. Therefore, reducing oxidative stress may protect nerves from the damage caused by hyperglycemia [4]. Extensive production of ROS results in enhanced inflammatory cytokine production, and vice versa; this cyclical process motivates a vast pro-inflammatory state [7]. The neuronal cytoskeleton consists of cross-linked proteins. The cytoskeleton has fundamental role in the cell response toward the harmful oxidative stress and the produced neurodegenerative changes [8,9].

Substantial evidences point to immunopathic mechanisms leading to DN development. The occurrence of pro-inflammatory reactions is evident in DN cases, promoting recruitment of inflammatory cells, production of cytokines and diminished blood flow. Hence, these mechanisms augment hypoxia and ischemia in peripheral nerves, rendering it difficult to regenerate [in Astrocytes are abundant in the CNS playing a crucial role in regulating

Correspondence to: Dr. Faten Abbas,
[E-Mail: faten_abbas@med.suez.edu.eg](mailto:faten_abbas@med.suez.edu.eg)

neuronal homeostasis for maintenance of the CNS physiological function such as keeping the BBB integrity, regulating synapse activity and modulation of cell motility, proliferation and interaction between astrocytes and neurons. Cell injury such as longstanding diabetes mellitus, results in a group of leading to altered expression of glia fibrillary acidic protein (GFAP). The later is an astrocyte-specific intermediate cytoskeletal filament protein. Growth-associated protein-43 (GAP-43) is an activity-dependent plasticity protein enriched in axons to support axonal regeneration. In astrocytes, the basal expression level of GAP-43 is low, although it is essential for astrocyte differentiation. The GAP-43 contributes to plasticity and growth of the presynaptic terminal [7].

Despite having three drugs that obtained approval from the FDA for treating pain associated with DN (duloxetine, pregabalin, and extended-release tapentadol) [ill], the treatment of DN remains inadequate. This is because of the inherent variability and complex nature of the disease. The current goal of therapy is to target the harmful signaling pathways that are upregulated in DN. However, there are no therapeutic options for DN that mitigate oxidative stress or inflammation. Hence, there is a need to find outnew therapeutic options for DN [in

Topiramate, is a sulfamate derivative of d-fructose, it is an antiepileptic drug that acts mainly through γ -aminobutyric acid (GABA) agonistic activity, negatively modulating voltage-activated Na^+ and L-type high voltage-activated Ca^{+2} channels and selective blocking of AMPA/kainate glutamate receptors. These various modulating mechanisms mediate the anticonvulsive, antinociceptive and putative neuroprotective properties of topiramate [in Topiramate provides a positive effect in the treatment of neuropathic pain although other drugs fail to do so [14,15]. Topiramate was documented to offer an advantage over other agents used for DN as it relieves pain in addition to possessing neuroprotective potential [16]. However, the prewise mechanism for these pleotropic effects is not yet well understood.

Overall, allodynia and excruciating leg pain are common in diabetic patients. This could be so painful for them that they are unable to go about their daily lives, which could have an effect on their work and social lives. Chronic pain and social isolation are common causes of depression [17]. Given the limited options for alleviating DN, the aim of our study was to delineate the possible molecular mechanisms of topiramate by which it acts as anti-nociceptive and neuroprotective agent in an experimental model of DN in mice. We focused on examining its antioxidant and glia suppressing activity leading to preserving to the integrity of central and peripheral neuronal structures.

Material and Methods

Alloxan-induced diabetes mellitus in mice and experimental design.

The protocol of this study obtained approval from the Animal Research Ethics Commicee of Suez Canal University (201906A3a).

The study was carried out in Faculty of Medicine, Suez Canal University for 4 months from January 2022 to May 2022.

We purchased a total of 28 male Swiss mice 8-10 weeks of age, weighing 19-25g from MousfataRashed Company in Giza (Egypt). Mice were kept in plastic cages with continuously available food and tap water in controlled hygienic conditions. Following acclimatization, we recorded the body weight and the fasting blood glucose.

The vehicle control group (n=7) received one intraperitoneal (i.p.) injection of saline (group 1) parallel to alloxan. Alloxan powder (SD fine chemicals, Mumbai, India) was employed to induce diabetes mellitus by injecting a dose equals 180mg/kg via the intraperitoneal route [18] in group 2,3&4. Five days following alloxan injection, fasting blood glucose (FBG) was assessed using an Accu-Check glucometer (USA). Mice showed FBG concentration >200mg/dL were used in this experiment.

The four groups were maintained for a period of 9 weeks to allow DN and associated pathologic changes to develop and then the following treatment approaches were launched [18]: Group 2: Received distilled water by oral gavage, Groups 3&4: Received topiramate by oral gavage [10mg/kg or 30mg/kg] [19] for a period of four weeks. At the end of the experimental phase, we assessed DN and mice were euthanized and killed by applying the cervical dislocation method.

Spinal cords as well as sciatic nerves were carefully dissected. Cervical spinal cords from were kept at -80°C or fixed in phosphate-buffered formalin (PBF). Alternatively, sciatic nerves were fixed in %10 PBF for subsequent use in H&E staining or immunohistochemistry (IHC) studies.

Pain testing procedures:

Von Frey filaments test:

The presence of mice behavioral reactions to a mechanical stimulus is usually estimated by the manual procedures of von Frey test. We measured the reaction toward mechanical stimuli after applying ascending forces by von Frey filaments (0.16-300g) starting with the least force following the up-down method as detailed previously [20]. Briefly, mice were placed in individual pa ern in small cages with a mesh-like penetrable boom. Each filament was perpendicularly applied at the plantar surface of the hind paw till the mouse withdraw the paw.

The mechanical threshold response is the minimum force that initiates at least 3 withdrawals witnessed (out of 5 consecutive trials) [20].

Hot-plate test:

For measuring the latency to an acute thermal stimulus, mice were positioned individually on the hot metal plate (55°C, Lsi LETICA, Italy). The glass cylinder (with dimensions = 25cm in high and 15cm in diameter) was put on the hot surface to prevent the any possible trial of escape. The latency (in sec) prior to any animal reactions such as licking the hind paw or jumping out the glass cylinder was recorded, with 45 sec set as cut-off time [21].

Oxidative and inflammatory markers:

Tissues from the spinal cords were frozen immediately after sacrifice and then homogenized in phosphate-buffered saline (PBS) and centrifuged for 10min at 1500 x g. The clear supernatants were withdrawn [53] and used in the following assays: Lipid peroxidation level was assessed by measuring the concentration of malondialdehyde (MDA) using Biodiagnostic kits (Cairo, Egypt) which applies the thiobarbituric acid (TBA) method. The assay relies on the reaction of TBA with MDA in acidic pH and 95°C which produces a colored reaction product that was quantified using a UV-spectrophotometer (Shimadzu, Japan) at 534nm [22].

TNF- α ELISA kit (catalog no. MBS2507393, My Bio Source, Inc., San Diego), and IL-113 (catalog no. E-EL-R0012c, Elabsience Houston, TX, USA) were used to determine these markers, and the final color was measured spectrophotometrically using an ELISA reader.

Histopathology of the spinal cords:

The formalin-fixed spinal cords were embedded in paraffin. Cut sections (5 μ m) from the cervical part of the spinal cord were prepared, allowed to dry for an overnight at 37°C and stained with hematoxylin and eosin (HE) and Cresyl violet. HE stained sections were examined and imaged at x400 and x1000 magnifications, by a PC-driven digital camera [Leica] on Leica light microscope [Model: DM 1000], for necrotic cells with cytoplasmic and nuclear changes and shrunken perikarya. However, neurons showing central, vesicular nuclei and basophilic cytoplasm were considered normal. We blindly scored the histopathological changes in the spinal cord in four fields/section and three sections/mouse for eosinophilic foci, including degenerated neurons and gliosis, as [0: Absent, 1: Mild, 2: Moderate, 3: Severe, 4: very severe, and 5: Extremely severe] as demonstrated previously [23]. Additionally, Cresyl violet stain identified (Nissl substance as large, dark staining granules in the perikarya of neurons. The colored area percentage for Cresyl violet stain was measured by ImageJ (NIH).

Immunohistochemistry for neurofilament:

NEFH immunostaining is a neurofilament marker that comprises the axoskeleton and maintains neuronal caliber. Also, they may play a role in intracellular transport. Immunohistochemistry of 5 μ m thick paraffin sections from the spinal cord blocks was done following, deparaffinization for 2 times, ten minutes each time and then rehydrated and exposed to antigen retrieval using Tris-EDTA at pH=9. Sections were covered for an overnight with rabbit polyclonal antibodies against Neurofilament type IV intermediate filament (ABclonal, Catalog No.: A19084) at dilution of 1:100 at 4°C then rinsed with PBS three times. The next step was visualization of the reaction by using a Power-Stain™ 1.0 polyclonal horseradish-peroxidase-conjugated (HRP) diaminobenzidine (DAB) kit and a biotinylated secondary anti rabbit antibody for 30min (Genemed Biotechnologies@, South San Francisco, USA). Counterstaining was done using Mayer's hematoxylin and slides were mounted with neutral balsam. Slides were examined and images were captured at magnification powers x400 and x1000 using a Leica digital camera fixed on a Leica light microscope [Model: DM 1000]. The mean color area percentage of positive immune-reactive areas was determined using ImageJ (NIH, Maryland, USA).

Histological assessment of the sciatic nerve:

Each sciatic nerve was dissected, fixed in 10% buffered formalin, paraffin embedded, prepared as paraffin blocks followed by sectioning at 5 μ m. Specimens were stained with H&E [for the general architecture] and silver stains to detect the nerve fibers. The histopathological changes of the H&E stained sections within one to two fields [x40] / section, and three sections/mouse. The severity of sciatic nerve fiber degeneration, myelinopathy, and axonopathy were classified into the following degrees: [0: Absent, 1: Mild, 2: Moderate, 3: Severe, 4: Very severe, and 5: extremely severe] [16]. Slides were examined and imaged at magnification powers x400 and x1000 by an experienced histologist who was blinded to the study groups. ImageJ software was used to measure the optical density of the silver-stained sections.

Western blotting for GFAP, iNOS and GAP43:

Total proteins were extracted from the spinal cords. In brief, spinal cord specimens were homogenized in RIPA buffer (Thermo Fisher, USA) supplemented protease inhibitors (Thermo Fisher). Next, homogenates were cleared by centrifugation for 15min at 15000 rpm. Concentration of protein was estimated by the bicinchoninic acid assay (Thermo Fisher) according to the standard protocols. A total of 50 μ g proteins were resolved on a 10% SDS polyacrylamide gel electrophoresis and moved to PVDF membrane. Membranes were blocked at room temperature in 5% non-fat dried milk for 1h. The membranes were then incubated with anti-(β -actin

antibody (Thermo Fisher, catalog #PA1-183), 1:100 anti-GFAP antibody (#sc-166458, Santa Cruz Biotechnology, USA), anti-iNOS (Abcam, ab178945) or anti-GAP43 (1:500, Cat #ab75810, Abcam, Cambridge, MA, USA) antibodies at 4°C for an overnight. The next day, membranes were subjected to a second incubation procedure with the corresponding goat anti-mouse or goat anti-rabbit conjugated antibody. Membranes were finally allowed to react with enhanced chemiluminescent substrate (ECL, Amersham Bio Sciences, Buckinghamshire, UK) according to the manufacturer protocol.

Data curation and statistical analysis:

Using the SPSS program, quantitative data were first examined by Shapiro-Wilk test to check if they show normal distribution or not. Data which showed normal distribution were demonstrated as means \pm SD and differences between groups were proven by applying one-way analysis of variance (ANOVA) and Tukey's post-hoc test. However, ordinal data of histopathologic scores were demonstrated in box plots and analyzed by non-parametric ANOVA and Dunn test using the GraphPad Prism x. p-value <0.05 was considered to be statistically significant.

Results

Pain tests:

In the current mouse model, testing thermal hyperalgesia by the hotplate test indicated that diabetic neuropathy control group showed shorter latency to licking and latency to jump compared to the vehicle control group (6.71 ± 1.98 vs. 14.57 ± 2.37 & 20.57 ± 3.05 vs. 44.71 ± 0.76 Fig. 1A&B) whereas mice with DN and treated with topiramate (10 and 30-mg/kg) prolonged the latency to licking in a dose-dependent manner (10 ± 1.15 and 13.42 ± 2.76) and latency to jumping (28.57 ± 1.98 and 39.42 ± 2.44) compared to the DN control group (Fig. 1A&B). Testing mechanical allodynia was done by von Frey filaments. DN control group showed lower pain threshold as expressed by the filament size (3.93 ± 0.16 vs. 6.59 ± 0.1) compared to the vehicle group (Fig. 1C). Diabetic mice received topiramate (10 or 30-mg/kg) significantly downregulated the pain threshold values versus the DN control group (Fig. 1C).

ELISA results:

The results highlighted that spinal cords of DN group showed high content of MDA (3.87-fold), TNF- α (2.85-fold) and IL-113 (4.1-fold) versus the vehicle group. Treatment with topiramate 10 or 30mg/kg was able to significantly and dose-dependently reduce these markers (89.4 ± 9.81 and 61.6 ± 7.64 , 1.03 ± 0.06 and 0.77 ± 0.09 , 522.8 ± 69 and 381.2 ± 26.34 , respectively) in the spinal cords compared to the DN control group (Table 1).

Table (1): Effect of topiramate on spinal MDA, TNF- α and IL-113 levels.

Group	MDA (ymol/g)	TNF- α (/4g/g)	IL-113 (ng/g)
Vehicle	31.6 \pm 4.83	0.35 \pm 0.04	244.2 \pm 28.47
DN	122.4 \pm 3.36*	1.43 \pm 0.12*	696.1 \pm 18.93*
DN+topiramate 10mg/kg	89.4 \pm 9.81^	1.03 \pm 0.06^	522.8 \pm 69^
DN+topiramate 30mg/kg	61.6 \pm 7.64*^&	0.77 \pm 0.09*^&	381.2 \pm 26.34*^&

- Data are mean \pm SD, *versus vehicle group, ^Versus DN group and & Versus the DN+topiramate 10mg/kg group (p<0.05).

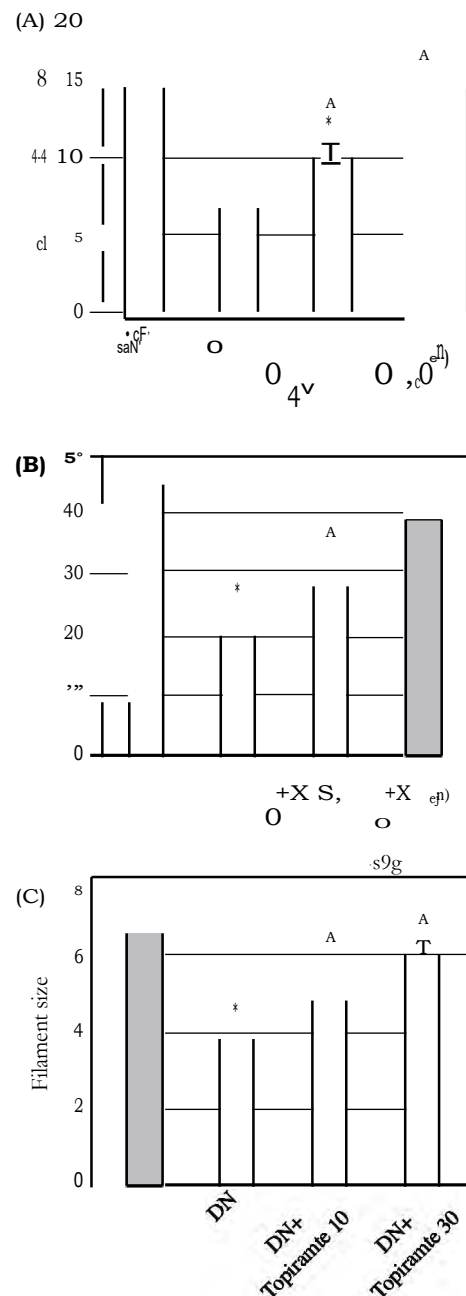


Fig. (1): Effect of topiramate on pain thresholds in diabetic mice. Mice were tested in the hotplate (panel A&B) and the von-Frey filaments test (panel C). Data are mean \pm SDM, *versus vehicle group, ^Versus DN group and & Versus the DN+topiramate 10mg/kg group (p<0.05).

Western blot for GFAP, iNOS and GAP43:

The Western blot gels are demonstrated in (Fig. 2A). Diabetic animals showed increased GFAP protein compared to vehicle (Saline) control mice. Treatment with topiramate reduced the level of GFAP (Fig. 2B). Administration of 10mg topiramate lowered the level of GFAP; however the 30mg topiramate had stronger effect in decreasing its level. Examining the protein level of iNOS followed the pattern of GFAP. Level of iNOS protein was markedly increased in diabetic mice (Fig. 2C). Treatment with topiramate reduced iNOS expression, the expression of iNOS was ameliorated by the two doses (10 or 30mg/kg) of topiramate. Further, the diabetic mice had low level of GAP-43 protein, and treating diabetic mice with topiramate produced significant increments in GAP-43 protein level (Fig. 2D).

Histopathology in the spinal cord specimens:

Microscopic investigation of H&E stained mice spinal cords:

Cervical parts of the vehicle group displayed normal structure of the grey and white maters. The

grey mater had multipolar neurons with their processes, large perikarya, large vesicular nuclei, basophilic cytoplasm and prominent nucleoli. Glial cells with small, rounded basophilic nuclei and scanty cytoplasm were seen. White mater had primarily nerve fibres where the myelin dissolved, leaving vacant spaces (Fig. 3A). However, the DN group had shrunken neurons. Nuclei of these cells are either eccentric or fading; others are pyknotic or karyolytic. Eosinophilic cytoplasm, discontinuous cytoplasmic processes and vacuolated neuropil were also observed in addition to pale basophilic glial cell nuclei (Fig. 3B). Differently, DN+topiramate 10mg/kg and DN+topiramate 30mg/kg groups showed less histopathological changes and basophilic glial cell nuclei (Fig. 3C&D). Scoring of the spinal cord sections revealed significant increase in histopathological changes as degenerated neurons, eosinophilic foci and gliosis in the DN group.

DN+topiramate 10mg/kg and DN+topiramate 30 groups showed significant improvement compared to the DN group (Fig. 3E).

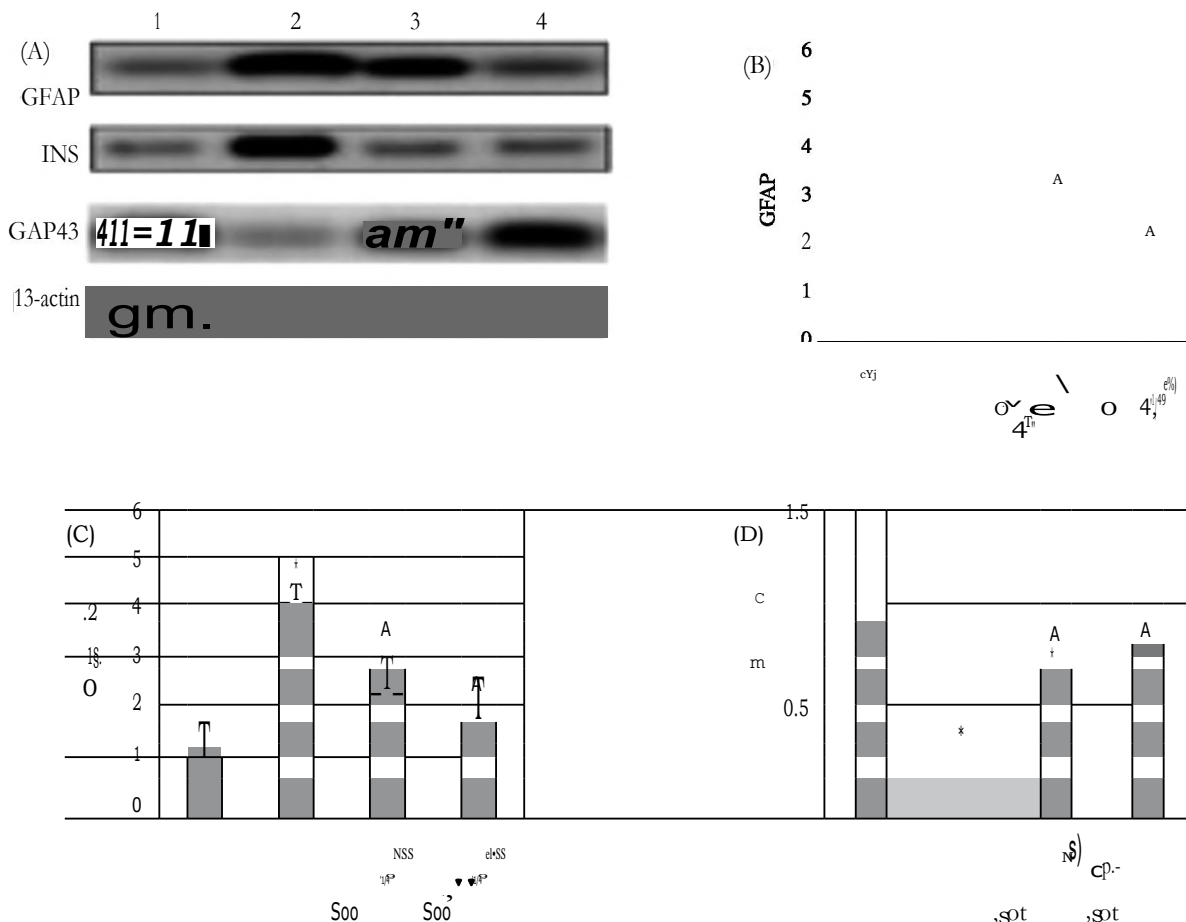


Fig. (2): Effect of topiramate on the spinal proteins. (A) Western blots for the target proteins & mean relative concentration of (B) GFAP, (C) iNOS and (D) GAP-43. Group 1 (Vehicle group), Group 2 (Diabetic neuropathy, DN group), Group 3 (DN+topiramate 10) and Group 4 (DN+topiramate 30). Data are mean \pm SDM, *versus vehicle group, ^Versus DN group and &Versus the DN+topiramate 10mg/kg group ($p < 0.05$).

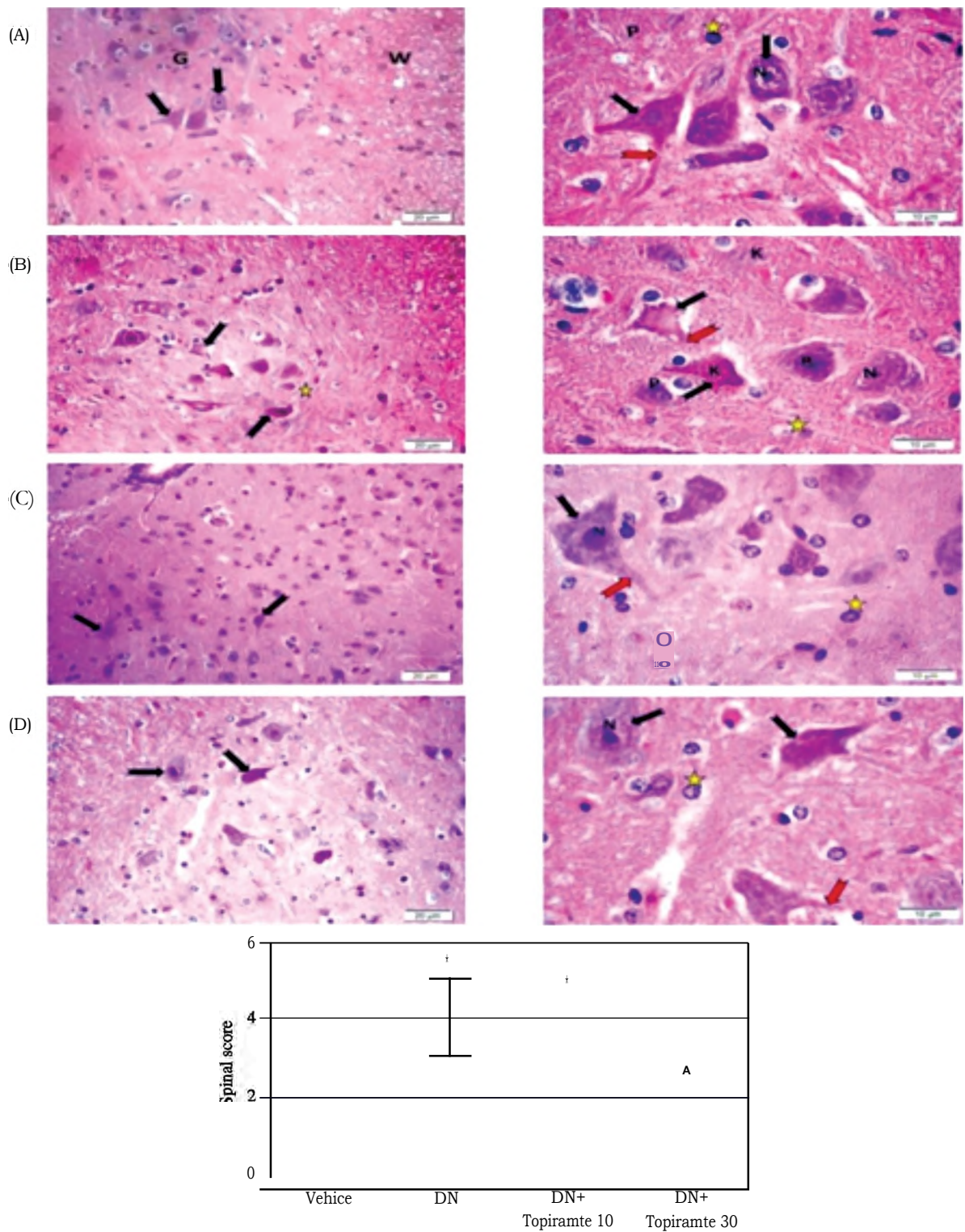


Fig. (3): Histopathological abnormalities in hematoxylin and eosin stained spinal cord sections from the study groups. Photomicrographs of sections in the spinal cord, [A] Control group show the grey matter (G) with multipolar neurons (black arrow) with processes (red arrow), large perikarya, basophilic cytoplasm, vesicular nuclei (N), and prominent nucleoli. Glial cells (*) with small rounded nuclei and scanty cytoplasm. White matter packed with axons (W). [B] DN group showing most of the perikarya of multipolar neurons are shrunken (black arrow); the nuclei are pyknotic (P) and karyolytic (K), some nuclei are eccentric (N). There are vacuoles in the neuropil with discontinuous cytoplasmic processes (red arrow). Glial cell nuclei (*) are also detected. [C] [DN+topiramate 10] group showing less apparent shrunken neurons with pyknotic nuclei. Normal multipolar neurons (black arrow) with large nucleus (N), basophilic cytoplasm, and extended processes (red arrow). Glial cell nuclei (*) and less vacuoles in the neuropil. [D] [DN+topiramate 30] group showing near normal neurons (black arrow), with large nucleus and prominent nucleoli (N), basophilic cytoplasm, and extended processes (red arrow). Glial cell nuclei (*) are noticed. H&E stain: (x 400 & x 1000). E: Box whisker plots representative to the medians for the scores. Kruskal-Wallis ANOVA was used and Dunn's test at $p < 0.05$. *Versus vehicle group, ^Versus DN group and &Versus the DN+topiramate 10 mg/kg group ($p < 0.05$).

Examination of Cresyl violet stained spinal cord specimen:

The vehicle group showed nerve cells enclosing Nissl granules (Fig. 4A). In contrast, DN group mice exhibited neurons with faint Nissl stain and loss of Nissl substances (Fig. 4B). DN+topiramate 10mg/kg and DN+topiramate 30mg/kg groups presented more Nissl granules in nerve cells than the DN control mice (Fig. 4C&D). The mean color area percentage of Nissl granules in Cresyl violet stained spinal cord specimens in the DN group decreased significantly compared to the control group. DN+topiramate 10 and DN+topiramate 30 groups displayed enhanced Cresyl violet staining compared to the DN group (Fig. 4E).

Stained sections of the spinal cord of the vehicle treated mice exhibited neurofilaments staining as dark brown granules in the cytoplasm of nerve cells, but their nuclei were negative (Fig. 5A). The DN group showed mild staining of the neurofilament in the nerve cell's perikarya and processes. Apparent dystrophic neurons were observed (Fig. 5B). DN+topiramate 10 and DN+topiramate 30 groups showed increased neurofilament staining of the soma and processes of nerve cells, with few dystrophic neurons compared to the DN group (Fig. 5C&D). The mean colour area percentage of neurofilaments in NEFH immunostained sections in the DN group was decreased versus the vehicle group. DN+topiramate 10 and DN+topiramate 30 groups showed improved NEFH staining compared to DN group (Fig. 5E).

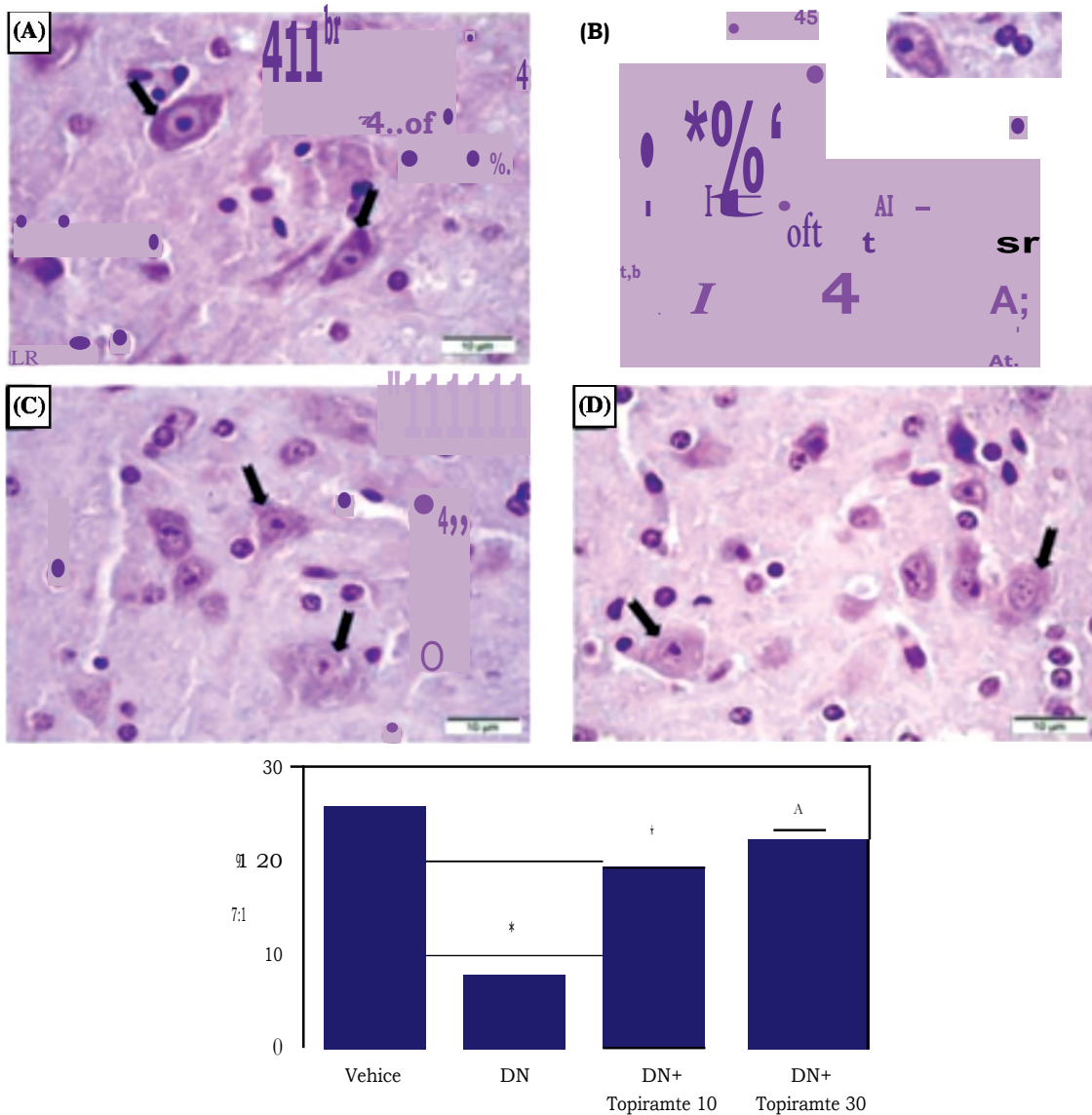


Fig. (4): Histopathological abnormalities in Cresyl violet stained spinal cord sections. Photomicrographs of sections in the spinal cord, [A] group I neurons have abundant Nissl granules (arrow). [B] DN group shows fading of Nissl granules in nerve cells (indicated by the arrow). [C&D] nerve cells of [DN+topiramate 10] & [DN+topiramate 30] groups contain more Nissl granules (arrow) compared to the DN group, [Cresyl Violet stain x 1000]. E. Mean color area percentage of Cresyl violet stained sections. Data presented as mean \pm SD and analyzed via one-way ANOVA followed by Tukey's multiple comparisons test. *:Versus vehicle group, A:Versus DN group and &:Versus the DN+topiramate 10mg/kg ($p < 0.05$).

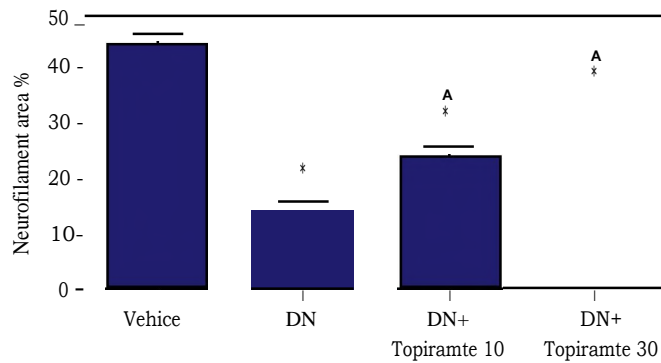
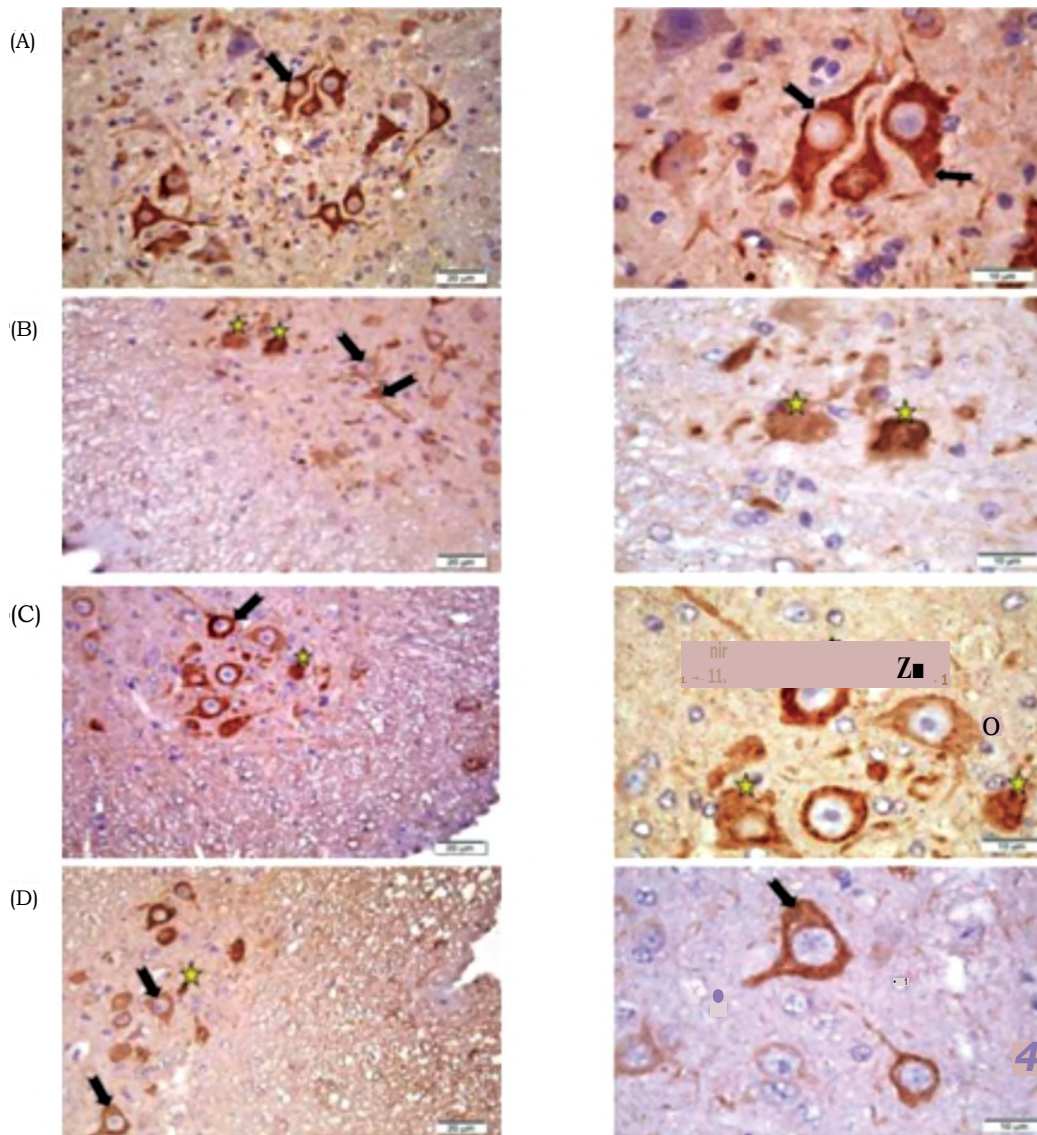


Fig. (5): Immunohistochemical staining for neurofilament heavy chain in spinal cord sections. Photomicrographs of sections in the spinal cord, [A] Control group demonstrates strong positive brown immunoreaction in neuronal perikarya and processes (black arrow). [B] DN group showing weak immunostaining of neurofilaments in neuronal perikarya and processes (black arrow) with apparent dystrophic neurons (*). [C&D] [DN+topiramate 10] & [DN+topiramate 30] groups showing moderate immunoreactive neurofilaments (black arrow), few dystrophic neurons (*), [Anti-NEFH x 400 & x 1000]. E: Graph with error bars showing mean \pm SD of the color area percentage of NEFH expression among different experimental groups (p-value <0.05). Data are mean \pm SD, *Versus vehicle group, ^Versus DN group and &Versus the DN+topiramate 10mg/kg group (p<0.05).

Histopathological examination of the sciatic nerves:

Examination and scoring of H&E stained sciatic nerves:

The vehicle group with densely packed nerve fibres were arranged in fasciculi of different sizes enveloped by a regular vascular connective tissue (the perineurium). The nerve fibres were mainly myelinated nerve fibres of variable diameters. Each myelinated nerve fibre was formed of a central axon surrounded by a poorly preserved myelin sheath and an outer circle of the eosinophilic cytoplasm of the Schwann cell. Schwann cell has elongated or crescent-shaped nuclei between the nerve fibres (Fig.

6A). The DN group showed the sciatic nerve with an irregular epineurium, loss of some central axons, and less myelinated nerve fibres. Most Schwann cells showed shrunken, pyknotic nuclei (Fig. 6B). DN+topiramate 10 and DN+topiramate 30 groups showed near normal sciatic nerves, closely packed nerve fibres with dark stained Schwann cells nuclei. Areas of myelinated nerve fibres and preserved central axons were seen (Fig. 6C&D). Scoring the histopathological findings of the sciatic nerves showed the DN group was significantly increased versus the vehicle group. DN+topiramate 10 and DN+topiramate 30 groups showed significant improvement compared to the DN group (Fig. 6E).

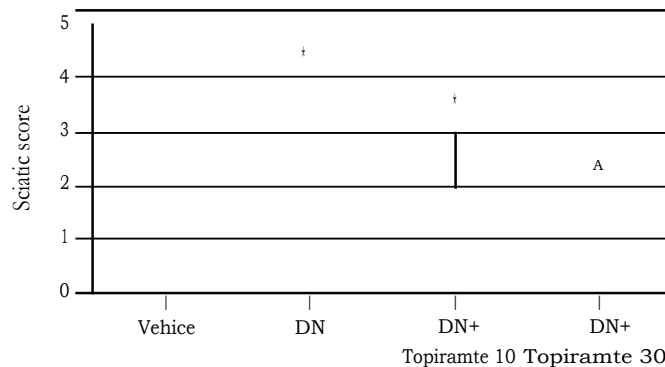
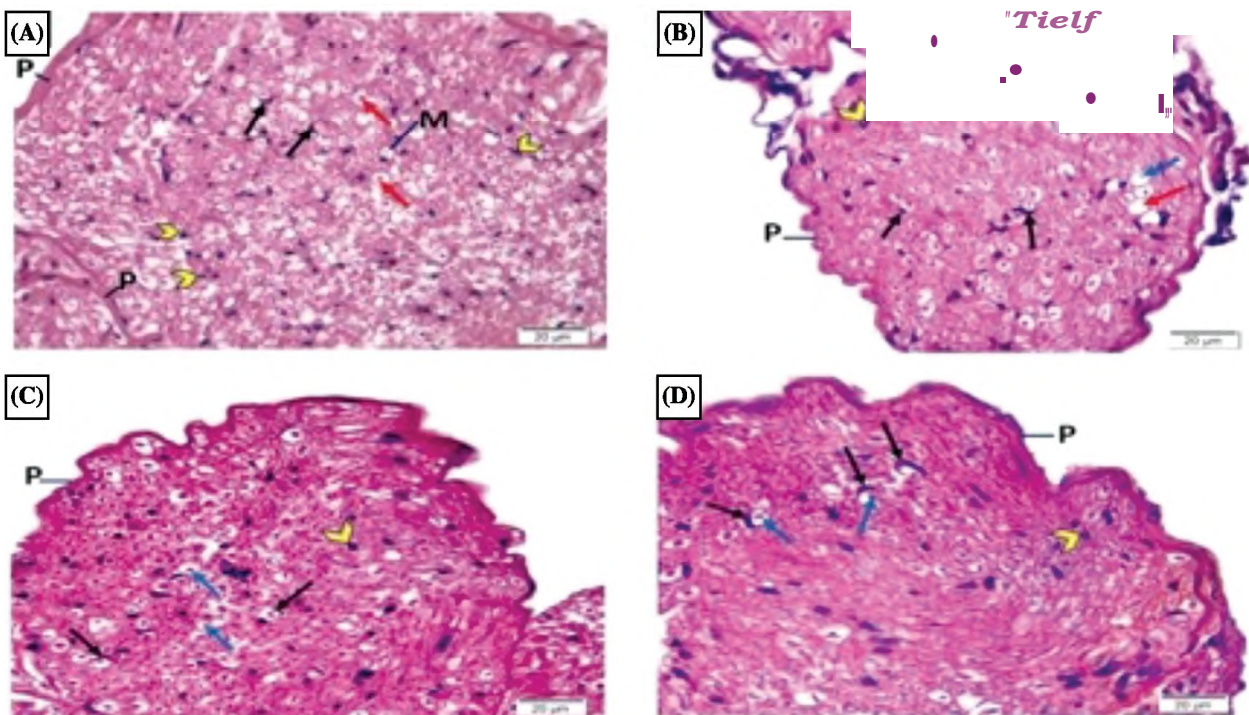


Fig. (6): Hematoxylin and eosin staining of the sciatic nerves. Photomicrographs of cross sections in sciatic nerve of [A] group I, showing connective tissue perineurium (P) surrounds the endoneurium containing densely packed, myelinated nerve fibers. Each nerve fiber formed of a central nerve axon (red arrow) surrounded by empty space myelin sheath (M), crescent-shaped nuclei of Schwann cells (black arrow), and some nuclei of endoneurial cells (arrow head). [B] DN group showing irregular perineurium (P) surrounding less myelinated nerve fibers (red arrow), with loss in some central axons (blue arrow), pyknotic nuclei in Schwann cells (black arrow) and a number of nuclei of endoneurial cells (arrow head). [C&D]: [DN+topiramate 10] and [DN+topiramate 30] groups showing closely packed nerve fibers with dark stained Schwann cells nuclei (black arrow). However, areas of myelinated nerve fibers and preserved central axons (blue arrow) and some nuclei of endoneurial cells (arrow head) still noticed. HEx400. Scoring (0 to 4) was performed based on the histopathologic findings [E] Data from the scoring of the sciatic nerve Box whisker plots representing the median values. Analysis used the Kruskal-Wallis ANOVA and then Dunn's test, $p < 0.05$. *Versus vehicle group, ^Versus DN group.

Examination and scoring of silver stained sciatic nerves:

The vehicle group revealed brown to black, faintly stained, thread-like nerve fibres in the nerves (Fig. 7A). The DN group presented thin, weakly stained threads of nerve fibres (Fig. 7B). DN+topiramate 10 and DN+topiramate 30 groups showed well stained,

thread-like nerve fibres compared to the diabetic group. (Fig. 7C&D). The nerve fibre optical density detected in DN group was significantly decreased compared with the vehicle group (0.84 ± 0.07 vs. 1.36 ± 0.13). DN+topiramate 30 group showed improved silver staining (1.04 ± 0.04 vs. 0.84 ± 0.07) compared to DN groups (Fig. 7E).

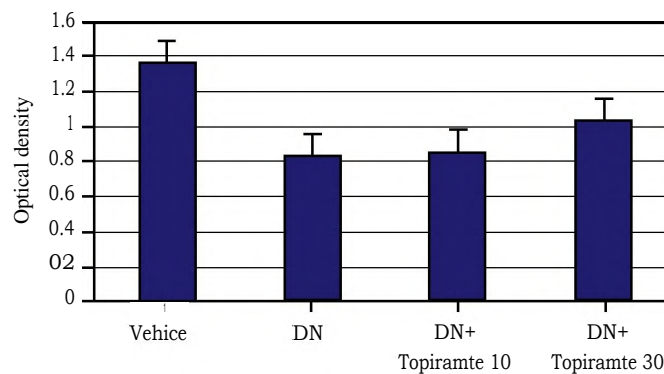
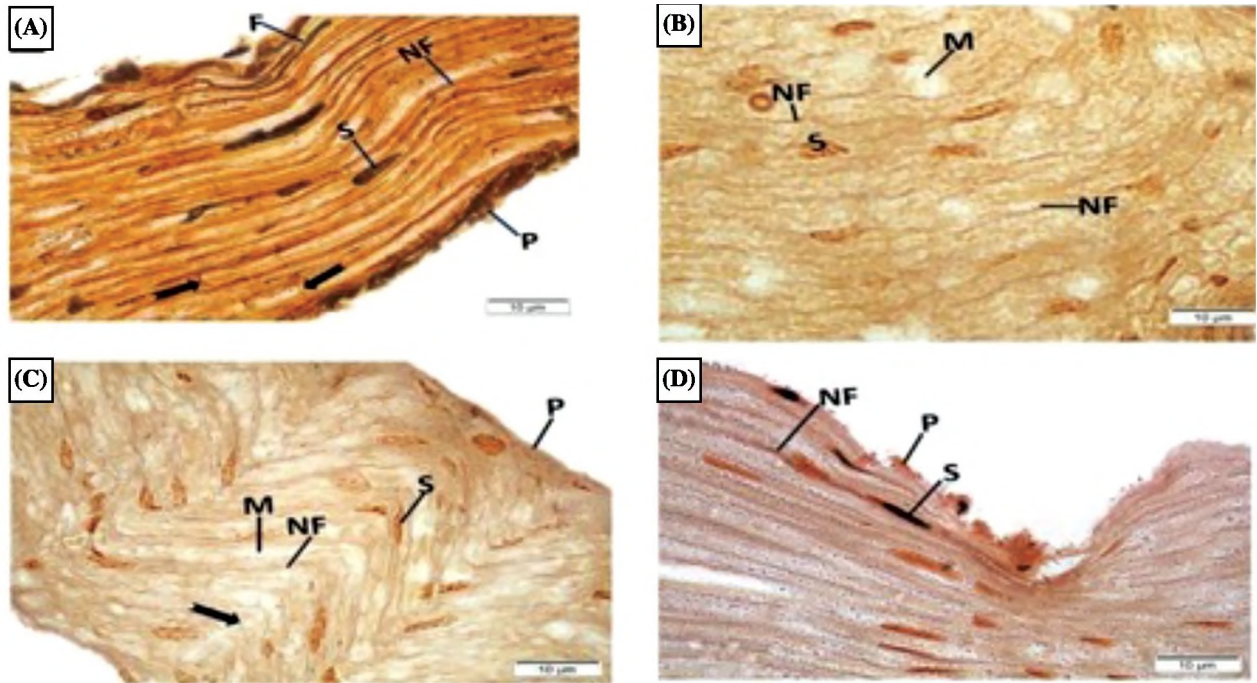


Fig. (7): Silver stain of the sciatic nerves. Photomicrographs of sections in the sciatic nerve. A. group I shows a single sciatic nerve fascicle in the longitudinal section contains many slender, deeply stained threads and pursues a wavy nerve fibers course (NF). Note the deeply stained perineurium (P) and the node of Ranvier (arrows). B. The DN group shows thin, weakly stained threads of nerve fibers (NF). Nodes of Ranvier are not apparent. C. [DN+topiramate 10] group shows mild improvement of nerve fibers (NF), the node of Ranvier is apparent (arrow). D. [DN+topiramate 30] group shows near normal, well stained, thread-like nerve fibers (NF) compared to DN group, (x 1000). E. The presented data are means±SDM and one-way ANOVA was applied for comparison of the groups followed by Tukey's test. *Versus vehicle group, ^Versus DN group and & Versus the DN+topiramate 10 mg/kg ($p < 0.05$).

Discussion

The present study tested the effectiveness of topiramate, an antiepileptic drug with promising neuroprotective properties, in alleviating mouse DN. Nine weeks following chemical induction of DM in mice, DN was confirmed by the presence of lower pain threshold in mechanical allodynia testing and shorter latency time in thermal hyperalgesia testing; this was in agreement with a recent report [6]. In addition to greater pain responses, DN mice showed marked neurodegeneration and greater pathology score in the spinal cord and sciatic nerves. Importantly, mice showed greater spinal MDA and cytokine level and GFAP protein but lower NEFH production.

Astrogliosis or astrocytosis is defined as massive activation of astrocytes that occurs due to the exposure to CNS insults, such as inflammation or excitotoxicity, to keep homeostasis and afford trophic support. Hence, astrogliosis can be considered the pathological hallmark in various neurodegenerative conditions, confirmed by upregulated GFAP. Upon activation, astrocytes initiate inflammatory reactions leading to detrimental possessions and neuronal death [11]. In the current study, DN control mice showed elevated spinal MDA and inflammatory cytokine levels. MDA is a main product of polyunsaturated fatty acids peroxidation and showed high cytokine levels. These findings can be interpreted, at least in part, within the context of the multiple factor documented to provoke the complex nature of DN in neurons [24]. For example, long standing hyperglycemia impairs polyol pathway leading to ROS overproduction [25]. In addition, hyperglycemia generates both overactive microglia and microangiopathy [26]. The former provokes an inflammatory loop leading to hypersensitization of nociceptor neurons. The latter mechanism lessens neuronal ability to access oxygen, glucose or nutrients and encouraging sensation loss [27]. Indeed, nociception takes place through special ion channel receptors localized at the sensory neurons. Voltage-gated or ligand-gated channels, cytokine receptors and injury of myelin sheath [28], and neuronal death [29] enhances pain sensation.

In the DN group, scoring of the spinal cord sections revealed a significant increase in histopathological changes as degenerated neurons, eosinophilic foci, and gliosis that was associated with a significant decrease in the Nissl granules and NEFH. Since, neurofilaments, which are exclusively expressed in neurons and function along with other cytoskeleton proteins (like microtubules and microfilament) in forming and maintaining the cell integrity via contributing to particles and organelle delivery within the cytoplasm. In central and peripheral neuronal degenerative diseases, neurofilaments have a crucial role. Reduced size of the myelinated fibers in addition to losing axonal neu-

rofilament content in the peripheral nerve have been reported in diabetic rats. Further, a decline in the neurofilament subunit expression to the distal axon has been proposed as a crucial role in degeneration of the axons [30].

It is well documented that neuronal histopathological changes during hyperglycemia may result from immunological reactions, oxidative stress, and inflammation [31,32,33]. In DM, chronic fluctuations between hyper/hypoglycemia impairs the function and metabolism of neurotransmitters, rendering the CNS more prone to degeneration as a result of inefficient glucose [34]. Extensive production of ROS results in enhanced inflammatory cytokine production and vice versa. This cyclical process motivates a vast pro-inflammatory status, all together contribute to development of diabetic neural complications.

The current study highlighted that neurofilament protein content of the spinal cords in DN group was lower than the vehicle group but improved in mice treated with topiramate. Neurofilament protein in the neuronal cytoskeleton comprises of microtubules, actin filaments and neurofilaments. One possible explanation for the observed reduction in NEFH is that the regulation of cytoskeleton components occurs in the level of expression and post-translational modifications and that oxidative stress is also able to disturb the regulation of neuronal cytoskeleton. Therefore, the cytoskeleton has a fundamental effect in cell responses toward oxidative stress and the onset of the produced neurodegenerative changes [16,28]. Studies in streptozotocin-diabetic rats showed reduced sensory neuron expression of neurofilament mRNA and deficient axonal transport of neurofilament in sensory and motor axons which explained as hyperglycemia and/or lack of insulin signaling may result in the direct inhibition of neurofilament synthesis [35].

Further, the current animal model highlighted that DN was accompanied by down regulation in synaptic plasticity as demonstrated by low GAP-43 protein content. In agreement, one previous study was done on the same mouse model of DN and demonstrated lower synaptic plasticity in the spinal cord that was enhanced by using an antiepileptic medication, valproate sodium, which was also capable to reduce pain sensation [36]. Likewise, another study showed that enhancing GAP-43 is accompanied by neuroprotection in diabetic mouse models [37].

In the peripheral nerves of rats with type 1 DM, exaggerated inflammatory indicators such as elevated macrophage infiltration and proliferation were detected in a previous study [36] while hyperglycemic type 2 diabetic mice showed greater number of macrophages in their sciatic nerves, which was coupled with axonal destruction and a damage of myelinated and unmyelinated nerve fibres [38]. The limited research into early stages of demyelination

has largely failed to develop a sufficiently robust predictive model, as initial degradation appears to have little effect on nerve conduction velocity [39]. According to Holland [20] and Levy [40], the sensory and motor nerve fiber types may be affected differently, explaining in part the wide variety of symptoms associated with painful DN. Inflammation of nerve tissue could be one facet of a multimodal pathogenic causes in DN. Several researchers found that animals with experimental DN exhibited activated inflammatory reaction, with mild invasion and proliferation of macrophages and T cells, as well as higher soluble cytokine abundances in the sciatic nerve [41-44]. Furthermore, intraepidermal small nerve fibres were one of the most common sites of axonal degeneration [42,43,44].

Our results show that diabetic mice showed hyperalgesia and allodynia in response to the hot-plate test and von Frey filaments. Importantly, the response to the hot-plate test involves higher brain functions and is considered to be supraspinally mediated response. The medial prefrontal cortex controls unconditioned defensive mechanisms provoked upon fear. In our study, the two used doses of topiramate alleviated pain in DN mice and topiramate in 30 mg/kg was more effective than the 10 mg/kg dose. Our result agree with Philip Raskin et al. [45] who found that monotherapy with topiramate lessened pain sensation more efficiently compared to placebo in diabetic patients suffering painful DN. Also Surena Nazarboghi et al., [35] found that gabapentin and topiramate suppressed neuropathic pain in patients with polyneuropathy. Differently, Lopes et al. [46] found that topiramate (80mg/kg) revealed antinociceptive activity in the hot plate test but did not provide an inhibitory effect on capsaicin-elicited pain in mice.

Furthermore, our findings demonstrated that treatment of DN mice with topiramate in both doses significantly improved histopathological changes. Similarly, light microscopic examination of sciatic nerves sections in the DN group highlighted the sciatic nerve with thick epineurium, loss of central axons, and less myelinated nerve fibres. In addition, most Schwann cells showed shrunken and dark elongated nuclei. Scoring the histopathological findings of the sciatic nerves showed the DN group was greater than the vehicle group while treatment with topiramate produced significant improvement.

Topiramate is known to enhance GABA activity, negatively modulate voltage-activated sodium channels and selectively block AMPA/kainate glutamate receptors, negatively modulates L-type voltage activated calcium channels and prevents carbonic anhydrase isozyme activity. This multiple-mechanistic action mediates its anticonvulsive, antinociceptive, and neuroprotective properties [8,16].

One study disclosed partial recovery from the diabetes induced histopathological changes in the

spinal cords and the sciatic nerves upon treatment with an antiepileptic drugs regulating ion channels such as valproate sodium especially higher doses, which suggests valproate sodium for treating polyneuropathy caused by diabetes [16]. Another study used levetiracetam for this purpose which showed very promising neuroprotective activity, suppressing spinal glia and suppression of pain sensation in streptozotocin-diabetic mice [35]. In agreement with these studies, carbamazepine was also utilized for a similar purpose; authors found that reduction of pain sensation was accompanied by lowering of spinal GFAP and enhancing neuronal plasticity [36]. In accordance with this notion, the antidepressant drug, duloxetine, which modifies neurotransmitter reuptake for norepinephrine and serotonin, showed considerable spinal and sciatic neuroprotective activity and raised pain thresholds in diabetic mice [47].

Conclusions:

The present study supports the view about the utility of topiramate as a neuroprotective remedy for DN and highlighted that the antioxidant effect and glia suppressing activity are the mechanisms, at least partly, mediates this activity.

Acknowledgments:

Authors are thankful to Dr. Nema Soliman, Department of Histology & Cell Biology, Faculty of Medicine, Suez Canal University, Ismailia, Egypt.

References

- 1- MOISSET X. and BOUHASSIRA, D.: Brain imaging of neuropathic pain. *Neuroimage*, 37: S80-S88, 2007.
- 2- ELSHERBINY N.M., AHMED E., KADER GA., ABDEL-MO ALEB Y., ELSAYED M.H., YOUSSEF A.M. and ZAITONE S A • Inhibitory effect of valproate sodium on pain behavior in diabetic mice involves suppression of spinal histone deacetylase 1 and inflammatory mediators. *Int. Immunopharmacol.*, 70,16-27,2019.
- 3- TANG H.Y., JIANG A.J., MA J.L., WANG F.J. and SHEN G.M.: Understanding the Signaling Pathways Related to the Mechanism and Treatment of Diabetic Peripheral Neuropathy. *Endocrinology*, 160 (9): 2119-2127,2019.
- 4- JENSEN T.S., KARLSSON P., GYLFAOIR S.S., ANDERSEN S.T., BENNE DL., TANJUSI H., FINNERUP N.B., TERKELSEN A.J., KHAN K. and THEMISTOCLEOUS A.C.: Painful and non-painful diabetic neuropathy, diagnostic challenges and implications for future management. *Brain*, 144 (6): 1632-1645,2021.
- 5- ALARE K., ALARE T., ODUNITAN T., ADETUNJI B. and OWONIKOKO O.11.0 DR.R.: SRC/JDRR-120, R. Neurological and Molecular Basis of Diabetic Neuropathy, 3,2020.
- 6- ALOMAR S.Y., GHEIT R., ENAN E.T., EL-BAYOUMI K.S., SHOAEIR MZ., ELKAZAZ A.Y., AL THAGFAN S.S., ZAITONE SA. and EL-SAYED R.M.: Novel Mechanism for Memantine in A enuating Diabetic Neuropath-

- is Pain in Mice via Downregulating the Spinal HMGB1/TRL4/NF-kB Inflammatory Axis. *Pharmaceuticals (Basel)*, 14 (4): 307,2021.
- 7- SHARMA A., TATE M., MATHEW G., VINCE JE., RITCHIE R.H. and DE HAAN LB.: Oxidative Stress and NLRP3-Inflammasome Activity as Significant Drivers of Diabetic Cardiovascular Complications: Therapeutic Implications. *Front Physiol*, 9: 114,2018.
 - 8- DAVEREY A. and AGRAWAL S.K.: Curcumin alleviates oxidative stress and mitochondrial dysfunction in astrocytes. *Neuroscience*, 333: 92-103,2016.
 - 9- LOUWSMA J., BRUNGER A.F., BIJZET J., KROESSEN B J., ROELOFFZEN W.W.H., BISCHOF A., KUHLE J., DROST G., LANGE F., KUKS J.B.M., GANS R.OB., HAZENBERG B.P.C. and NIENHUIS H.L.A.: Neurofilament light chain, a biomarker for polyneuropathy in systemic amyloidosis. *Amyloid*, 28 (1): 50-55,2021.
 - 10- FELDMAN EL., CALLAGHAN B.C., POP-BUSUI R., ZOCHODNE D.W., WRIGHT DE., BENNE DL., BRIL V., RUSSELL J.W. and VISWANATHAN V.: Diabetic neuropathy. *Nat Rev Dis Primers*, 5 (1): 41,2019.
 - 11- YANG H., SLOAN G., YE Y., WANG S., DUAN B., TESHAYE S. and GAO L.: New Perspective in Diabetic Neuropathy: From the Periphery to the Brain, a Call for Early Detection, and Precision Medicine. *Front Endocrinol. (Lausanne)*, 10: 929,2019.
 - 12- SUN Q., WANG C., YAN B., SHI X., SHI Y., QU L. and LIANG X.: Jinmaitong Ameliorates Diabetic Peripheral Neuropathy Through Suppressing TXNIP/NLRP3 Inflammasome Activation In The Streptozotocin-Induced Diabetic Rat Model. *Diabetes Metab. Syndr. Obes.*, 12: 2145-2155,2019.
 - 13- Cardenas-Rodriguez, N.; Coballase-Urrutia, E.; Huerta-Gertrudis, B.; Garcia-Cruz, M.; Pedraza-Chaverri, J.; Coria-Jimenez, R.; Bandala, C.; Ruiz-Garcia, MJN.S. Antioxidant activity of topiramate: an antiepileptic agent. 2013,34(5), 741-747.
 - 14- CARROLL D.G., KLINE K.M. and MALNAR K.F.: Role of topiramate for the treatment of painful diabetic peripheral neuropathy. *Pharmacotherapy: The Journal of Human Pharmacology and Drug Therapy*, 24 (9): 1186-1193,2004.
 - 15- GROUP TDN.P.S., THIENEL U., NETO W., SCHWABE S. and VIJAPURKAR U.: Topiramate in painful diabetic polyneuropathy: [20] Holland NR., Stocks A., Hauer P., Cornblath DR., Griffin J.W., McArthur J.C. Intraepidermal nerve fiber density in-findings from three double blind placebo controlled trials *Acta. Neurologica Scandinavica*, 110 (4): 221-231,2004.
 - 16- CARDENAS-RODRIGUEZ N., COBALLASE-URRUTIA E., RIVERA-ESPINOSA L., ROMERO-TOLEDO A., SAMPIERI III A., ORTEGA-CUELLAR D., MONTESINOS-CORREA H., FLORIANO-SANCHEZ E., CARMONA-APARICIO L.J.O.M. and LONGEVITY C.: Modulation of antioxidant enzymatic activities by certain antiepileptic drugs (valproic acid, oxcarbazepine, and topiramate): evidence in humans and experimental models, 2013,2013.
 - 17- QUA RINI C. and TESHAYE S.: Understanding the impact of painful diabetic neuropathy. *Diabetes Metab. Res. Rev.*, 19 Suppl 1 (S1): S2-8, 2003.
 - 18- REDA H.M., ZAITONE S.A. and MOUSTAFA Y.M.: Effect of levetiracetam versus gabapentin on peripheral neuropathy and sciatic degeneration in streptozotocin-diabetic mice: Influence on spinal microglia and astrocytes. *Eur. J. Pharmacol.*, 771: 162-172,2016.
 - 19- LEE M.H., HONG I., KIM M., LEE B H , KIM LH., KANG K.S., KIM HL., YOON B J., CHUNG H., KONG G. and LEE M O • Gene expression profiles of murine fa y liver induced by the administration of valproic acid. *Toxicol. Appl. Pharmacol.*, 220 (1): 45-59,2007.
 - 20- Choi, D.C.; Lee, J.Y.; Lim, E.J.; Balk, H.H.; Oh, T.H.; Yune, T.Y. Inhibition of ROS-induced p38MAPK and ERK activation in microglia by acupuncture relieves neuropathic pain after spinal cord injury in rats. *ExpNeurol*, 2012, 236(2), 268-282.
 - 21- RIPOLL N., HASCOET M. and BOURIN M.: The four-plates test: Anxiolytic or analgesic paradigm? *ProgNeuropsychopharmacolBiol Psychiatry*, 30 (5): 873-880,2006.
 - 22- OHKAWA H., OHISHI N. and YAGI K.: Assay for lipid peroxides in animal tissues by thiobarbituric acid reaction. *Anal Biochem*, 95 (2): 351-358,1979.
 - 23- CAO L. and DELEO J A.LEJ.0 J.: CNS infiltrating CD4+ T lymphocytes contribute to murine spinal nerve transection induced neuropathic pain, 38 (2): 448-458,2008.
 - 24- EDWARDS J.L., VINCENT A.M., CHENG H.T. and FELDMAN E.L.: Diabetic neuropathy: Mechanisms to management. *Pharmacol. Ther.*, 120 (1): 1-34,2008.
 - 25- BURMA NE., BONIN RP., LEDUC-PESSAH H., BAIMEL C., CAIRNCROSS Z.F., MOUSSEAU M., SHANKARA J.V., STEMKOWSKI PL., BAIMOUKHA-METOVA D. and BAINS J.S.J.N.M.: Blocking microglial pannexin-1 channels alleviates morphine withdrawal in rodents, 23 (3): 355-360,2017.
 - 26- DAS EVCIMEN N. and KING GL.: The role of protein kinase C activation and the vascular complications of diabetes. *Pharmacol. Res.*, 55 (6): 498-510,2007.
 - 27- CEVIKBAS F., KEMPKE C., BUHL T., MESS C., BUD-DENKO E.J. and STEINHOFF M.: *Frontiers in Neuroscience; Role of Interleuldn-31 and Oncostatin M in Itch and Neuroimmune Communication. In: Itch: Mechanisms and Treatment*, Carstens E., Akiyama T., Eds.; CRC Press/Taylor & Francis© 2014 by Taylor & Francis Group, LLC.: Boca Raton (FL), 2014.
 - 28- KIKUMOTO Y., SUGIYAMA H., INOUE T., MORINAGA H., TAKIUE K., KITAGAWA M., FUKUOKA N., SAEKI M., MAESHIMA Y., WANG D.H., OGINO K., MASUOKA N. and MAKINO H.: Sensitization to alloxan-induced diabetes and pancreatic cell apoptosis in acatalasemic mice. *Biochim. Biophys Acta.*, 1802 (2): 240-246, 2010.
 - 29- INOUE KJP.: *Therapeutics. The function of microglia through purinergic receptors: Neuropathic pain and cytokine release*, 109 (1-2): 210-226,2006.

- 30- QIAO X., ZHANG S., ZHAO W., YE H., YANG Y., ZHANG Z., MIAO Q., HU R., LI Y. and LU B.: Serum Phosphorylated Neurofilament-Heavy Chain, a Potential Biomarker, is Associated With Peripheral Neuropathy in Patients With Type 2 Diabetes. *Medicine (Baltimore)*, 94(44), e1908, 2015.
- 31- ALOMAR S.Y., B MB., ELDOSOKY M., ATEF H., MOHAMED A.S., ELHAWARY R., EL-SHAFFEY M., YOUSSEF A.M., ELKAZAZ A.Y., GABR A.M., ELASICARY AA., SALIH M AK , ALOLAYAN S.O. and ZAITONE S A.: Protective effect of metformin on rat diabetic retinopathy involves suppression of toll-like receptor 4/nuclear factor-k B expression and glutamate excitotoxicity. *Int. Immunopharmacol.*, 90: 107193,2021.
- 32- KHODEER D.M., ZAITONE SA., FARAG N.E. and MOUSTAFA Y.M.: Cardioprotective effect of pioglitazone in diabetic and non-diabetic rats subjected to acute myocardial infarction involves suppression of AGE-RAGE axis and inhibition of apoptosis. *Can J. Physiol. Pharmacol.*, 94 (5): 463-476,2016.
- 33- SAID E., ZAITONE S A , ELDOSOKY M. and ELSHERBINY N.M.: Nifuroxazide, a STAT3 inhibitor, mitigates inflammatory burden and protects against diabetes-induced nephropathy in rats. *Chem. Biol. Interact.*, 281: 111-120,2018.
- 34- MCCALL AL.: The impact of diabetes on the CNS. *Diabetes*, 41 (5): 557-570,1992.
- 35- FERNYHOUGH P. and SCHMIDT RE.: Neurofilaments in diabetic neuropathy. *Int. Rev. Neurobiol.*, 50: 115-144, 2002.
- 36- EL-SHERBEENY NA., IBRAHIEM A.T., ALI H.S., FARAG NE., TORAIH EA. and ZAITONE SA.: Carbamazepine conquers spinal GAP43 deficiency and sciatic Nav1.5 upregulation in diabetic mice: Novel mechanisms in alleviating allodynia and hyperalgesia. *Arch. Pharm. Res.*, 43 (7): 724-734,2020.
- 37- MOHAMMAD H.M.F., SAMI M.M., MAKARY S., TORAIH EA., MOHAMED A.O. and EL-GHAIESH S.H.: Neuroprotective effect of levetiracetam in mouse diabetic retinopathy: Effect on glucose transporter-1 and GAP43 expression. *Life Sci.*, 232: 116588,2019.
- 38- KOSACKA J., NOWICKI M., KLOTING N., KERN M., STUMVOLL M., BECHMANN I., SERKE H. and BLUHER M.: COMP-angiopoietin-1 recovers molecular biomarkers of neuropathy and improves vascularisation in sciatic nerve of ob/ob mice. *PLoS One*, 7 (3): e32881, 2012.
- 39- WILDING C., BELL K , FUNKE S., BECK S., PFEIPPER N. and GRUS F.H.: GFAP antibodies show protective effect on oxidatively stressed neuroretinal cells via interaction with ERP57. *J. Pharmacol. Sci.*, 127 (3): 298-304, 2015.
- 40- LEVY D.M., TERENGI G., GU X.H., ABRAHAM RR., SPRINGALL D.R. and POLAK J.M.: Immunohistochemical measurements of nerves and neuropeptides in diabetic skin: Relationship to tests of neurological function. *Diabetologia*, 35 (9): 889-897,1992.
- 41- BAUM P., TOYKA K.V., BLUHER M., KOSACKA J. and NOWICKI M.J.I.J .O .M .S .: Inflammatory Mechanisms in the Pathophysiology of Diabetic Peripheral Neuropathy (DN) *New Aspects.*, 22 (19): 10835,2021.
- 42- KOSACKA J., BAUM P., ESTRELA-LOPIS I., STOCKINGER M., KLOTING N., BLUHER M., CLASSEN J., THIERY J., BECHMANN I. and TOYKA K.J.D.U.S.: The role of nerve inflammation and exogenous iron load in experimental peripheral diabetic neuropathy (PDN), 11 (03): LB15,2016.
- 43- KOSACKA J., WOYDT K., TOYKA K.V., PAESCHKE S., KLOTING N., BECHMANN I., BLUHER M., THIERY J., OSSMANN S., BAUM P. and NOWICKI M.: The role of dietary non-heme iron load and peripheral nerve inflammation in the development of peripheral neuropathy (PN) in obese non-diabetic leptin-deficient ob/ob mice. *Neurol. Res.*, 41 (4): 341-353,2019.
- 44- PAESCHKE S., BAUM P., TOYKA K.V., BLUHER M., KOJ S., KLOTING N., BECHMANN I., THIERY J., KOSACKA J. and NOWICKI M.: The Role of Iron and Nerve Inflammation in Diabetes Mellitus Type 2-Induced Peripheral Neuropathy. *Neuroscience*, 406: 496-509,2019.
- 45- RASKIN P., DONOFRIO PD., ROSENTHAL N R., HEWIDJ., JORDAN D.M., XIANG J., VINIK Ai., GROUP C.-S.: Topiramate vs placebo in painful diabetic neuropathy: Analgesic and metabolic effects. *Neurology*, 63 (5): 865-873,2004.
- 46- LOPES L.S., PEREIRA S.S., SILVA L.L., FIGUEIREDO K.A., MOURA BA., ALMEIDA F.R. and SOUSA F.C.: Antinociceptive effect of topiramate in models of acute pain and diabetic neuropathy in rodents. *Life Sci.*, 84 (3-4): 105-110,2009.
- 47- WANG Y.X., BOWERSOX S.S., PE US M. and GAO D.: Antinociceptive properties of fenfluramine, a serotonin reuptake inhibitor, in a rat model of neuropathy. *J. Pharmacol. Exp. Ther.*, 291 (3): 1008-1016,1999.

آلام الظهر الميكانيكية وفرط التألم الحرارى فى الفئران المصابة بالسكرى والتغيرات التنكسية العصبية فى الحبل الشوكى والأعصاب الوركية: التعديل بواسطة توبييراميت

قد تحدث التغيرات المرضية المرتبطة بمرض السكرى فى أعضاء الجسم بسبب التفاعلات المناعية والعبء الالتهابى / التاكسدى.

الهدف من الدراسة: تهدف الدراسة الحالية إلى اختبار التأثير الوقائى العصبى للتوبييراميت فى نموذج حيوانى للاعتلال العصبى السكرى المحيطى واختبار قدرته على قمع العبء الالتهابى للحبل الشوكى والتفاعل الدبقى.

المواد والطرق: أجريت الدراسة فى كلية الطب جامعة قناة السويس ، وتم تعيين ذكور الفئران البالغة كمجموعة مركبات الوكسان ١٨٠، ومجموعة توبييراميت. DN + توبييراميت ١٠ مجم / كجم و DN. + i.p ٣٠ مجم/كجم، تلقت الفئران علاج توبييراميت لمدة أربعة أسابيع ثم اختبرت للألم الخيفى وفرط التألم. تم فحص عينات الحبل الشوكى تم فحص الأعصاب (NEFH) بواسطة المقاييسات الجزيئية والتقنية المجهرية الخفيفة وسلسلة الخيوط العصبية الثقيلة الوركية المجهرية.

النتائج: أشارت إلى أن الفئران التى تلقت العلاج تحسنت ويوجد بها زيادة فى عتبات الألم. كما يوجد فى الفئران المصابة بالسكرى أظهر العصب الوركى تنكس محورى، وإزالة الميالين، وفقدان بعض المحاور المركزية، وتقلص خلايا شوان. و GAP43 علاوة على ذلك، كان لدى الحبال الشوكية لفئران مستويات وهذه النتائج تحسنت باستخدام التوبييراميت GFAP وانخفاض السيتوكينات الالتهابية وتنكس الخلايا العصبية مع الخلايا العصبية الضمور.

الخلاصة: أنتجت توبييراميت حماية عصبية وزيادة عتبات الألم فى الفئران المصابة ومن ثم، فإن دراستنا تعزز توبييراميت كحماية عصبية ويقترح ذلك لتخفيف آلام الأعصاب.