

## What is Beyond Chronic Knee Pain? A Comparative Ultrasound and MRI Study to Assess the Contribution of Various Pathological Entities in the Painful Knee Joint

ASMAA H. HABIB, MD.; ALAA SOBHI, M.D.; SAFTA B. SAYED, M.D. and HODA M. ABBAS, M.D.

The Department of Radiology, Faculty of Medicine, Cairo University

### Abstract

**Background:** Chronic knee pain is a common increasing musculoskeletal complaint. As a result, selecting a dependable screening tool at a reasonable cost is essential. Although magnetic resonance imaging (MRI) is the gold standard imaging modality for knee soft tissue structures, its high cost has led to widespread abuse.

**Aim of Study:** The main aim of this study is to spot ultrasonography's diagnostic efficacy as a quick imaging method for evaluating painful knee joints in comparison with MRI.

**Patients and Methods:** A prospective study was conducted on 110 patients with clinically confirmed chronic knee pain/limited mobility. Both ultrasonography and MRI examinations of the knee were done for all study groups. The diagnostic effectiveness of ultrasonography in comparison to MRI was examined for evaluating different findings of possible causes of chronic knee pain.

**Results:** A total of 120 knees were included in the study; Ultrasonography and MRI reported 9 different pathological entities of possible causes of chronic knee pain or related to it. Joint effusion was the most common finding (91.6%) followed by OA changes (41.6%) and peri-articular baker cyst (25%). The overall sensitivity of ultrasonography was 85.5% and 100% specificity. The ultrasonography provided the highest sensitivity (100%) in detecting effusion, baker cyst, hematoma, torn menisci, Meniscal horn extrusion, vascular anomalies, and hemangioma, followed by periarticular cystic and solid lesions with sensitivities of 86.6% and 88.8% respectively.

**Conclusion:** With the advantages of being widely accessible, affordable, and having no contraindications, ultrasound should be the primary imaging modality of choice when evaluating chronic knee pain. It can be used as an effective and acceptable screening imaging modality. For ambiguous ultrasound results, MRI can be reserved.

**Key Words:** Chronic knee pain — Ultrasound — MRI— Diagnostic accuracy.

**Correspondence to:** Dr. Asmaa H. Habib,  
E-Mail: [semsem145@hotmail.com](mailto:semsem145@hotmail.com)

### Introduction

**CHRONIC** knee pain can be severely debilitating and frequently has a significant influence on the patient's quality of life. 25% of adults' experience knee discomfort, and in the last 20 years, the prevalence has climbed by 65%. It is characterized as pain that lasts for at least three months [1].

The knee articulation is one of the body's biggest and most complex one. It has two synovium-lined hinge joints between the medial and lateral tibial and femoral condyles, as well as a gliding joint between the patella and the anterior femoral articular surface. The medial and lateral collateral and cruciate ligaments, and extensor tendons (quadriceps and patellar tendons) are the main stabilizers of the joint. The menisci are fibro-cartilaginous structures that maintain the joint in flexion and extension, distribute weight over the articular cartilage, absorb shock, contribute to joint lubrication and act as a shock absorber [2,3].

Chronic knee pain may be caused by a variety of circumstances and may present as confined or widespread symptoms. It is primarily brought on by osteonecrosis (avascular necrosis), stress fractures,

---

### Abbreviations:

MRI : Magnetic resonance imaging.

US : Ultrasound.

OA : Osteoarthritis.

AVM : Arterio-venous malformation.

USG : Ultrasonography.

MR : Magnetic resonance.

MCL : Medial collateral ligament.

LCL : Lateral collateral ligament.

ACL : Anterior cruciate ligament.

PPV : Positive predictive value.

NPV : Negative predictive value.

PVN : Pigmented villondularsynovitis.

CT : Computed tomography.

arthritis, cystic lesions around the joint (including bursae), tendonous and cartilaginous pathologies, chronic inflammatory and infective conditions, and avulsion injuries [4].

Taking good history and performing the physical examination of the patient are of utmost significance in determining the underlying cause. Imaging tests are used in addition to the physical examination to produce an accurate diagnosis that will serve as the basis for creating an effective treatment plan [5].

To determine the severity of the bone and soft tissue anomaly and to direct therapeutic intervention, if necessary, an imaging workup is important. Ultrasonography and magnetic resonance imaging are the most beneficial diagnostic methods for assessing soft tissue alteration. Computed tomography is not advised, and plain radiography has limited utility [6].

The imaging required to generate high-resolution pictures to assess menisci, ligaments, and tendons are made possible by advancements in MRI technology. The imaging of the postoperative knee has also been enhanced. Thanks to recent developments in MRI techniques, which also reduce metal artifacts, and enable the imaging of tumors, cartilage evaluation, and nerve visualization. Understanding the proper use of these developments in MRI of the knee will show to be useful for clinical practice as therapeutic and surgical management methods change. Additionally, for many knee diseases, MRI has taken the position of diagnostic arthroscopy as the primary diagnostic technique [7].

MRI is costly and occasionally impractical, despite having the highest sensitivity. Due to the existence of a pacemaker or other absolute or relative MRI contraindications, it can be challenging to perform MRI on some individuals. Today, ultrasonography is a method that holds promise for determining soft tissue anomalies [8].

The accessibility and multi-planar capabilities of ultrasound are benefits, as well as its cost-effectiveness. Ultrasound is affordable, easily available and radiation free. Additionally, it has the capacity to compress, and dynamically evaluate structures, is less time-consuming, and easily contrasts with the opposite side. It has the ability to guide percutaneous interventions aspiration or intra-articular injections. The evaluation of para-articular regions is a significant benefit of knee ultrasonography. With the aid of ultrasound, the underlying anatomical structures and accompanying pathology can be connected to the patient's area of clinical soreness, it can easily show knee effusions, bursitis, ligamentous and tendinous injuries as well as occult fractures [8].

For the assessment of some knee problems, ultrasonography (US) is a promising approach since it

differs from MRI imaging in a number of important ways; the US offers a higher spatial resolution which may be useful for thoroughly assessing the knee's surface structures, dynamic evaluation, which is particularly useful for distinguishing between partial and full tears and enabling simple comparison with the opposing knee [7].

In this study, we are going to discuss the role of high-resolution ultrasonography as a growing and useful diagnostic tool in the evaluation and assessment of different painful knee pathologies compared to MR imaging, it can be a promising primary screening tool in the evaluation of knee pain.

### Patients and Methods

This study is an observational analytical study that was approved by our university's review board after being revised by the ethics committees of the Radiology departments. A convenient sample of population was taken. All of the participants gave written informed consent for their data for this research study use. This study was conducted during periods between May 2020 till December 2021.

Our study included 100 patients, referred from the Outpatient Clinics of the Orthopedics and Rheumatology Departments to the Radiology Department of Cairo University Hospitals for ultrasonography and MRI examination of the knee joint. They included both sexes. Their ages ranged from 15-70 years with a mean age of 35.

In our study our patients were divided into two subgroups less than 55 years old and more than 55 years, patients with younger ages had more incidences of traumatic causes of knee pain, older patients had more incidence of osteoarthritic changes as a cause of knee pain.

#### *Inclusion criteria:*

Any patient complaining of chronic knee pain of at least 3 months' duration and/or knee joint limitation of movements.

#### *Exclusion criteria:*

- Patients with absolute contraindications to MR examination as a cardiac pacemaker, aneurysmal clipping, and claustrophobia.
- Patients with acute knee pain of duration less than 3 months.
- Patients underwent knee surgeries of a duration of fewer than 3 months.
- Acute traumatic insult to knee joint as fractures.
- Pregnant females.
- Prisoners.
- Impaired mental health.

Full clinical history was taken from our patients including; age, sex, occupation, and analysis of the

complaint: onset, course, and duration of knee pain. Determining the points of maximum pain and tenderness, and any relevant previous surgical history as well as any previous imaging if present were also recorded.

All patients had the followings:

1- *Clinical examination:* Was done for the patients before doing the MR and US examination by an orthopedic surgeon/Rheumatologist with + 15 years of practice. It included assessment of; skin scars, sinuses, swelling, muscle atrophy, shape and symmetry, tenderness as well as examination of active and passive movements.

2- *Ultrasonographic examination:* Ultrasound examinations were performed using GE Logic pro6 and TOSHIBA Xario 100 ultrasonographic devices (7-14 MHz) transducers. The routine US examination of the knee starts with its anterior aspect, followed by the medial, lateral, and posterior aspects in both longitudinal and transverse planes by 2 radiologists with 8-10 years of experience. All patients had standardized ultrasonography of the knee joint with excess gel was used instead of the gel pad. The patella was used as the principal acoustic window.

- a- The anterior knee joint compartment: A tiny pillow is positioned beneath the popliteal area to help the patient's knee flex at a 20°-30° angle while they are lying on their back. The quadriceps tendon, supra, medial, and lateral patellar recesses, medial and lateral patellar retinacula, patellar tendon, infra and pre patellar bursae, The V-shaped hypoechoic hyaline cartilage covering the femoral trochlea was examined with the knee in full flexion, and anterior horn of both menisci are meticulously inspected in this posture as the knee is carefully examined from cranial to caudal.
- b- The medial knee joint compartment: The leg was externally rotated with careful examination for the following; Medial collateral ligament. Pessanserinus complex and bursa, medial aspect of the joint space.
- c- The lateral knee joint compartment: Was examined by asking the patient to rotate the leg internally with careful examination for the following; Distal segment of the iliotibial band, Lateral aspect of the joint space, Lateral collateral ligament, and distal part of the Biceps femoris tendon.
- d- The posterior knee joint compartment: It was examined in prone position with the knee joint extended; Semimembranosus-gastrocnemius bursa, Baker cyst if present, posterior horn of both menisci, and Popliteal vessels.
- e- Dynamic examination: Was collected at various knee flexion and extension angles to aid in the evaluation of healthy and pathological structures.

f- Color and Power-Doppler imaging: Was used to detect inflammatory/infective conditions of the knee joint, eg: Tendinopathy, synovitis as well as detection and diagnosis of knee vascular anomalies and neoplastic soft tissue masses.

*Definition of the knee ultrasound findings:*

- Effusion: Detection of anechoic or hypoechoic intra-articular fluid (more than 4 mm) in the cavity of the knee joint.
  - A cyst: A well defined anechoic lesion, usually measured in axial and craniocaudal dimensions.
  - Bursitis: The presence of increased fluid in the bursa and/or thickening of the wall of the bursa.
  - Tendinitis: Increased thickness and/or hypo-hyperechoic signal in the tendon.
  - Tenosynovitis: Peritendinous fluid accumulation with internal echoes within the fluid with areas of increased vascularity by Doppler flow.
  - Osteophytes: Joint margins bony finger-like protrusions.
  - Degenerated cartilage: The presence of at least two of these criteria: Focal or total cartilage thinning (less than 2mm); loss of sharpness or homogeneity of the cartilage layer.
  - Degenerative menisci: Linear or nodular hypoechoic/echogenic regions that do not include an articular surface or loss of uniform internal echo structure.
  - Torn menisci: Abrupt alterations in the meniscal contours, blunting of its surface, and/or linear or echogenic clefts extending to the articular edges of the meniscus or through the meniscus.
  - Suprapatellar plica: A hypoechoic band inside joint effusion.
  - Subcutaneous lipoma: Rather well defined hypo- or hyper-echoic compressible lesion similar to adjacent subcutaneous fat, it usually shows minimal/no vascularity with homogeneous echo texture.
  - Vascular malformation: Heterogeneous echogenic compressible areas, variable vascularity, ± calcification.
  - Hematoma: A vascular variable echogenicity (hyper if acute, and anechoic if chronic) encapsulated area, history of trauma or anticoagulant might help.
- 3- *MRI Examination:* MRI was performed using Intera or Achieva (1.5 T) by knee coil in all cases.
- Positioning: The examined joint was fully or nearly fully extended in the knee coil while the patients were in the supine position.

• Protocol: The MRI studies were done included: Sagittal T1, PD, T2 and T2 fat suppressed WIs, Axial T2WIs, Coronal STIR WIs, and T1 post-contrast if indicated. The following parameters were applied; slice thickness 4 mm slice gap 4 mm, field of view ranging from 12 to 16 cm and matrix 256/192 or 512/224.

4. *Other radiological tests:* X-ray for 4 cases, angiography for 7 cases, CT angiography for one case, and US-guided aspiration or true cut biopsy performed for 7 cases.

*Statistical analysis:* Statistical analysis was conducted using the statistical package for the Social Sciences (SPSS) version 28. Data were presented using relative frequencies (percentages) for categorical variables as well as the mean and standard deviation for quantitative variables and frequencies (number of cases). For comparing categorical data between ultrasonography and MRI to detect sensitivity, specificity, positive predictive values, and negative predictive value Chi-square ( $X^2$ ) and McNamara tests were performed. The Exact test was used instead when the expected frequency is less than 5. Correlations between quantitative variables were done using the Pearson correlation coefficient.  $p$ -value  $>0.05$  was considered non-significant,  $p$ -value  $<0.05$  was considered significant and  $p$ -value  $<0.01$  was considered highly significant.

*Sample size calculation:* The sample size was computed using the following parameters (Buderer, 1996): Predicted sensitivity 89%, specificity 82%, disease prevalence 20%, precision 20%, confidence interval 95%, and level of significance 0.05. The sample size was estimated to be research group  $N=110$ .

## Results

**Our study included** 120 knees from 110 patients (44 males and 66 females; mean age,  $35.7 \pm 13.9$  years; range, 15-70 years). The most common age group was between 35 and 55 years (55%). Most of the cases had unilateral knee pain apart from the ten cases examined. The main complaint we encountered was knee pain and/or limited mobility, not less than 3 months

### *Ultrasonography and MRI findings:*

Both ultrasonography and MRI agreed and reported nine different pathological entities of possible causes of chronic knee pain or related to it. The US detected 373 different findings in 120 examined knee joints, while the MRI detected 436 findings in the same examined knee joints. The distribution of those findings that were detected by all utilized imaging modalities in 120 knee joints is displayed in Table (1).

Table (1): Distribution of nine different pathological entities by both US and MRI.

Pathological entities	Frequency/Total N-120	Percentage
<i>Ligamentous lesions:</i>	30/120	25%
MCL sprain	15/25	
LCL sprain	5/25	
ACL sprain	10/25	
<i>Tendinous lesions:</i>	5/120	4.1%
Patellar tendinopathy	2/5	
Quadriceps tendinopathy/or Enthesopathy	2/5	
Popliteal tendinopathy	1/5	
<i>Synovial lesions:</i>	32/120	26.6%
Suprapatellar synovial plica	20/32	
Synovial sarcoma	1/32	
PVN	1/32	
Rheumatoid arthritis	4/32	
Hemophilia	1/32	
Reactive 'non-specific'	5/32	
<i>Peri articular cysts:</i>	40/120	33.3%
Uncomplicated Baker's cyst	25/40	
Complicated Baker's cyst	5/40	
Ganglion cyst	4/40	
Simple synovial cyst	2/40	
Cystic hematoma	1/40	
Meniscal cyst	3/40	
<i>Periarticular soft tissue lesions:</i>	10/120	8.3%
Hematoma	2/10	
Intramuscular recurrent rhabdomyosarcoma	1/10	
Subcutaneous lipoma	4/10	
Fibromatosis	2/10	
Schwannoma	1/10	
<i>Vascular malformations:</i>	8/120	6.6%
Low flow AVM	4/8	
High flow AVM	2/8	
Hemangioma	2/8	
Total N of examined knee joints	120	100%
Other associated findings distributed among 120 examined knees		
Joint effusion	110/120	91.6%
<i>Bursitis:</i>	35/120	29.1%
Pesanserinus	15/35	
Infra patellar	20/35	
<i>OA changes:</i>	50/120	41.6%
Femoral/patellar cartilage thinning/defect	35/50	
Femoral/tibial osteophytes	45/50	
Subcortical Pseudocysts	20/50	
Meniscal degeneration	34/50	
Torn menisci	22/50	
Meniscal horn extrusion	10/50	

In our study among the ligamentous pathologies, there were 15 cases diagnosed as MCL sprain by MRI representing (12.5%). Ultrasonography agreed with it in 14 cases (11.6%) missing one case. Five cases (4.1%) presented with LCL injury by MRI (Fig. 5), and the US detected three cases (2.5%) from them. Statistical analysis of these results showed significant agreement ( $p$ -value  $<0.001$ ) and no significant statistical difference between the two

modalities in the detection of both collateral ligamentous injuries. On the other hand, the US agreed with the MRI in reporting only one case (0.8%) out of ten (8.3%) presented with ACL injury showing statistically significant differences ( $p=0.0054$ ) between both modalities. Table (2).

Table (2): Comparison between US and MRI in ligamentous pathologies detection.

Parameter	Results	US	MRI	
MCL sprain	Positive	N 14	15	
	Total n=120	% 11.6	12.5	
	Negative	N 106	105	
	Total n=120	% 88.3	100	
Sensitivity 93.3%	Specificity 100%	PPV 100%	NPV 98.91%	Accuracy 99.05%
LCL sprain	Positive	N 3	5	
		% 2.5	4.1	
	Negative	N 117	115	
		% 97.5	95.8	
Sensitivity 60%	Specificity 100%	PPV 100%	NPV 98.2%	Accuracy 98.3%
ACL sprain	Positive	N 1	10	
		% 0.8	8.3	
	Negative	N 119	110	
		% 99.1	91.6	
Sensitivity 10%	Specificity 100%	PPV 100%	NPV 92.4%	Accuracy 92.5%
Total positive findings		18/120	30/120	

In our study, MRI diagnosed 5 cases (4.1%) with tendinous pathologies including; 2 patellar, 2 quadriceps, and 1 popliteal tendinopathies. The US agreed with it in two cases (1.6%) including; 1 case for each patellar and quadriceps tendinopathies with no significant difference between them ( $p=0.2455$ ). Table (3).

Both US and MRI reported 28 cases (23.3%) with synovial thickening (Fig. 3). Another four cases (26.6%) were diagnosed by the MRI, and the US could not detect them. Synovial joint effusion was easily detected by both imaging modalities in 110 cases. These showed significant agreement ( $p$ -value  $<0.001$ ) and no significant statistical difference between the two modalities in the detection of synovial effusion ( $p=1$ ) and thickening ( $p=0.5$ ). Table (4). The definition of the exact etiology of synovial thickening was aided by MRI to reach the final diagnosis in three cases out of 32; suggesting PVN and rheumatoid arthritis changes, as correlated to clinical and histopathological findings.

Seventy-five cases (62.5%) presented with peri-articular cystic lesions detected by MRI in our study (Fig. 6). Ultrasound was agreed upon in 65 cases (54.1%) Table (5). No significant statistical difference between the two modalities ( $p=0.1$ ). The

definitions of those cystic lesions were described in Table (5), and they were defined as related to anatomical structures by both imaging modalities. The ten missed cases by the US might be due to increased BMI and a large amount of subcutaneous fat in 2 patients despite using superficial and deep probes.

Table (3): Comparison between US and MRI in tendinous pathologies detection.

Parameter	Results	US	MRI	
Patellar tendinopathy	Positive	N 1	2	
	Total n=120	% 0.8	1.6	
	Negative	N 119	118	
	Total n=120	% 99.1	98.3	
Sensitivity 50%	Specificity 100%	PPV 100%	NPV 99.1%	Accuracy 99.1%
Quadriceps tendinopathy/or Enthesopathy	Positive	N 1	2	
		% 0.8	1.6	
	Negative	N 119	118	
		% 99.1	98.3	
Sensitivity 50%	Specificity 100%	PPV 100%	NPV 99.1%	Accuracy 99.1%
Popliteal tendinopathy	Positive	N 0	1	
		% 0	0.8	
	Negative	N 120	119	
		% 100	99.1	
Sensitivity 0%	Specificity 100%	PPV 100%	NPV 99.1%	Accuracy 99.1%
Total positive findings		2/120	5/120	

Table (4): Comparison between US & MRI in the detection of the synovial thickening and joint effusion.

Parameter	Results	US	MRI	
Suprapatellar synovial plica	Positive	N 18	20	
	Total n=120	% 15	16.6	
	Negative	N 102	100	
	Total n=120	% 85	83.3	
Sensitivity 50%	Specificity 100%	PPV 100%	NPV 99.1%	Accuracy 99.1%
Synovial thickening	Positive	N 10	12	
		% 8.3	10	
	Negative	N 110	108	
		% 91.6	90	
Sensitivity 83.3%	Specificity 100%	PPV 100%	NPV 98.1%	Accuracy 98.3%
Total positive findings		28/120	32/120	
Joint effusion	Positive	N 110	110	
		% 91.6	91.6	
	Negative	N 10	10	
		% 8.3	8.3	
Sensitivity 100%	Specificity 100%	PPV 100%	NPV 100%	Accuracy 100%

Table (5): Comparison between US & MRI in the detection of periarticular cystic lesions.

Parameter	Results		US	MRI
Baker cyst	Positive	N	30	30
	Total n=120	%	25	25
	Negative	N	90	90
	Total n=120	%	75	75
Sensitivity 100%	Specificity 100%	PPV 100%	NPV 100%	Accuracy 100%
Cystic hematoma	Positive	N	1	1
			0.8	0.8
	Negative	N	119	119
			99.1	99.1
Sensitivity 100%	Specificity 100%	PPV 100%	NPV 100%	Accuracy 100%
Meniscal cyst	Positive	N	2	3
		%	0	0.8
	Negative	N	118	117
		%	100	99.1
Sensitivity 66.6%	Specificity 100%	PPV 0%	NPV 99.1%	Accuracy 99.1%
Bursitis	Positive	N	30	35
		%	25	29.1
	Negative	N	90	85
		%	75	70.8
Sensitivity 85.7%	Specificity 100%	PPV 100%	NPV 94.4%	Accuracy 95.8%
Other cystic lesions	Positive	N	2	6
		%	1.6	5
	Negative	N	8	80
		%	98.3	95
Sensitivity 33.3%	Specificity 100%	PPV 100%	NPV 96.6%	Accuracy 96.6%
Total positive findings			65/120	75/120

Among different pathological entities detected in our study, OA changes in the knee joint were the most common cause of knee pain representing 50 cases (41.6%). The detailed findings by both US and MRI were described in Table (6). The sensitivity and accuracy of ultrasound were excellent in the detection of trochlear cartilage thinning (85.7%, 95.8%), articular osteophytes (84.4%, 94.1%), Subcortical Pseudocysts (70%, 95%), meniscal degeneration (58.8%, 88.3%), Torn menisci and Meniscal horn extrusion (100%) (Fig. 6). The overall sensitivity of the US in the detection of the positive findings of OA changes was 80.7%.

Our US and MR examinations agreed on the detection of different 16 cases (13.3%) presented with periarticular soft tissue lesions, this makes their sen-

sitivity, specificity, PPV, NPV, and accuracy 100% Table (7). Two cases with subcutaneous lipomas were missed by the US. The lesions included; hematoma, lipoma, hemangioma, and AVM (Fig. 2) which were easily identified by both imaging modalities. Using the color Doppler study, US was able to distinguish 4 low flow AVM and 1 high flow AVM, which MR was unable to do. However, the MR was more useful in accurately detecting their extension.

Table (6): Comparison between US & MRI in the detection of OA changes in knee joint.

Parameter	Results		US	MRI
Femoral/patellar cartilage thinning/ defect	Positive	N	30	35
	Total n=120	%	25	29.1
	Negative	N	90	85
	Total n=120	%	75	70.8
Sensitivity 85.7%	Specificity 100%	PPV 100%	NPV 94.4%	Accuracy 95.8%
Femoral/tibial osteophytes	Positive	N	38	45
		%	31.6	37.5
	Negative	N	82	75
		%	68.3	62.5
Sensitivity 84.4%	Specificity 100%	PPV 100%	NPV 91.4%	Accuracy 94.1%
Cortical irregularities Subcortical Pseudocysts	Positive	N	14	20
		%	11.6	16.6
	Negative	N	106	100
		%	883	833
Sensitivity 70%	Specificity 100%	PPV 0%	NPV 94.3%	Accuracy 95%
Meniscal degeneration	Positive	N	20	34
		%	16.6	28.3
	Negative	N	100	86
		%	833	71.6
Sensitivity 58.8%	Specificity 100%	PPV 100%	NPV 86%	Accuracy 88.3%
Torn menisci	Positive	N	22	22
		%	18.3	18.3
	Negative	N	98	98
		%	81.6	81.6
Sensitivity 100%	Specificity 100%	PPV 100%	NPV 100%	Accuracy 100%
Meniscal horn extrusion	Positive		10	10
			8.3	8.3
	Negative		110	110
			91.6	91.6
Sensitivity 100%	Specificity 100%		NPV 100%	Accuracy 100%
Total positive findings			134/120	166/120

Four cases of peri-articular soft tissue lesions were reported by both imaging modalities without a definite diagnosis Table (7). With the aid of the interventional modality of the US and the correlation of their results with histopathology, we could reach the final diagnosis of three of them; one case of schwannoma and two cases of fibromatosis (Figs. 1,4). The other case was clinical-pathologically reported as recurrent rhabdomyosarcoma.

In comparison with the gold standard MRI, our overall sensitivity of the US in the detection of 436 findings in 120 examined knee joints was 85.5% Table (8). The highest sensitivity, specificity, PPV, NPV, and accuracy of 100% were in detecting joint effusion, baker cyst, hematoma, torn menisci, Meniscal horn extrusion, AVM, and hemangioma, followed by peri-articular cystic and solid lesions with sensitivities of 86.6% and 88.8% respectively Table (8).

Table (7): Comparison between US & MRI in the detection of periarticular soft tissue lesions.

Parameter	Results	US	MRI
Hematoma	Positive	N 2	2
	Total n=120	% 1.6	1.6
	Negative	N 118	118
	Total n=120	% 98.3	98.3
Sensitivity 100%	Specificity 100%	PPV 100%	NPV 100%
Subcutaneous lipoma	Positive	N 2	4
	Total n=120	% 1.6	3.3
	Negative	N 118	116
	Total n=120	% 98.3	96.6
Sensitivity 50%	Specificity 100%	PPV 100%	NPV 983%a
AVM	Positive	N 6	6
	Total n=120	% 5	5
	Negative	N 114	114
	Total n=120	% 95	95
Sensitivity 100%	Specificity 100%	PPV 0%	NPV 100%
Hemangioma	Positive	N 2	2
	Total n=120	% 1.6	1.6
	Negative	N 118	118
	Total n=120	% 98.3	98.3
Sensitivity 100%	Specificity 100%	PPV 100%	NPV 100%
Other periarticular soft tissue lesions without a definite radiological diagnosis	Positive	N 4	4
	Total n=120	% 3.3	3.3
	Negative	N 116	116
	Total n=120	% 96.6	96.6
Sensitivity 100%	Specificity 100%	PPV 100%	NPV 100%
Total positive findings		16/120	18/120

Table (8): The overall US diagnostic accuracy of the aforementioned pathological entities detection in knee joints.

Parameter	Sensitivity	Specificity	PPV	NPV	Accuracy
Ligamentous injury	60%	100%	100%	88.2%	90%
Tendinopathies	40%	100%	100%	97.4%	97.5%
Synovial thickening	87.5%	100%	100%	95.6%	96.6%
Joint effusion	100%	100%	100%	100%	100%
Periarticular cystic lesions including bursitis	86.6%	100%	100%	81.8%	91.6%
OA changes	80.7%	100%	100%	60.9%	85.1%
Periarticular soft tissue lesions	88.8%	100%	100%	98.0%	98.3%
Overall	85.5%	100%			

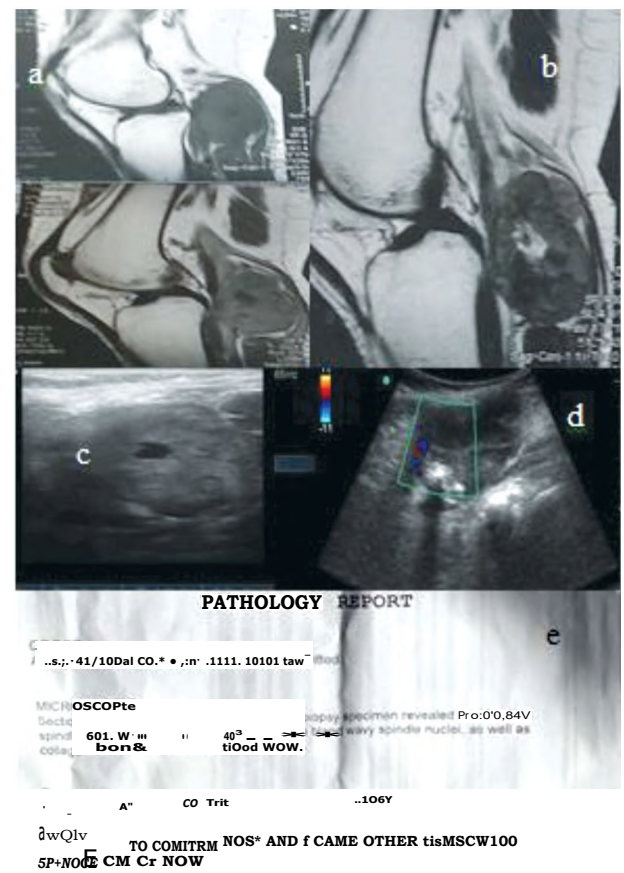


Fig. (1): 33 year old female patient with a swelling at the back of her right knee joint incidentally discovered with slowly progressive course.

- A: MR images sagittal T1 pre and post contrast and axial T1 post contrast of the right knee joint showing well-circumscribed popliteal lesion eliciting low T1 with evident post contrast enhancement and non-enhancing low center .
- B: Sagittal T2 image shows a well-circumscribed mass lesion being low SI in T2 with high T2 signal of its center.
- C&D: US gray scale and color Doppler images of the mass lesion showing isoechoic mass lesion with anechoic center and punctuate calcific foci, moderate vascularity were seen by color doppler.
- E: US guided tru cut biopsy was done and the pathology report revealed spindle cell tumor likely schwannoma.



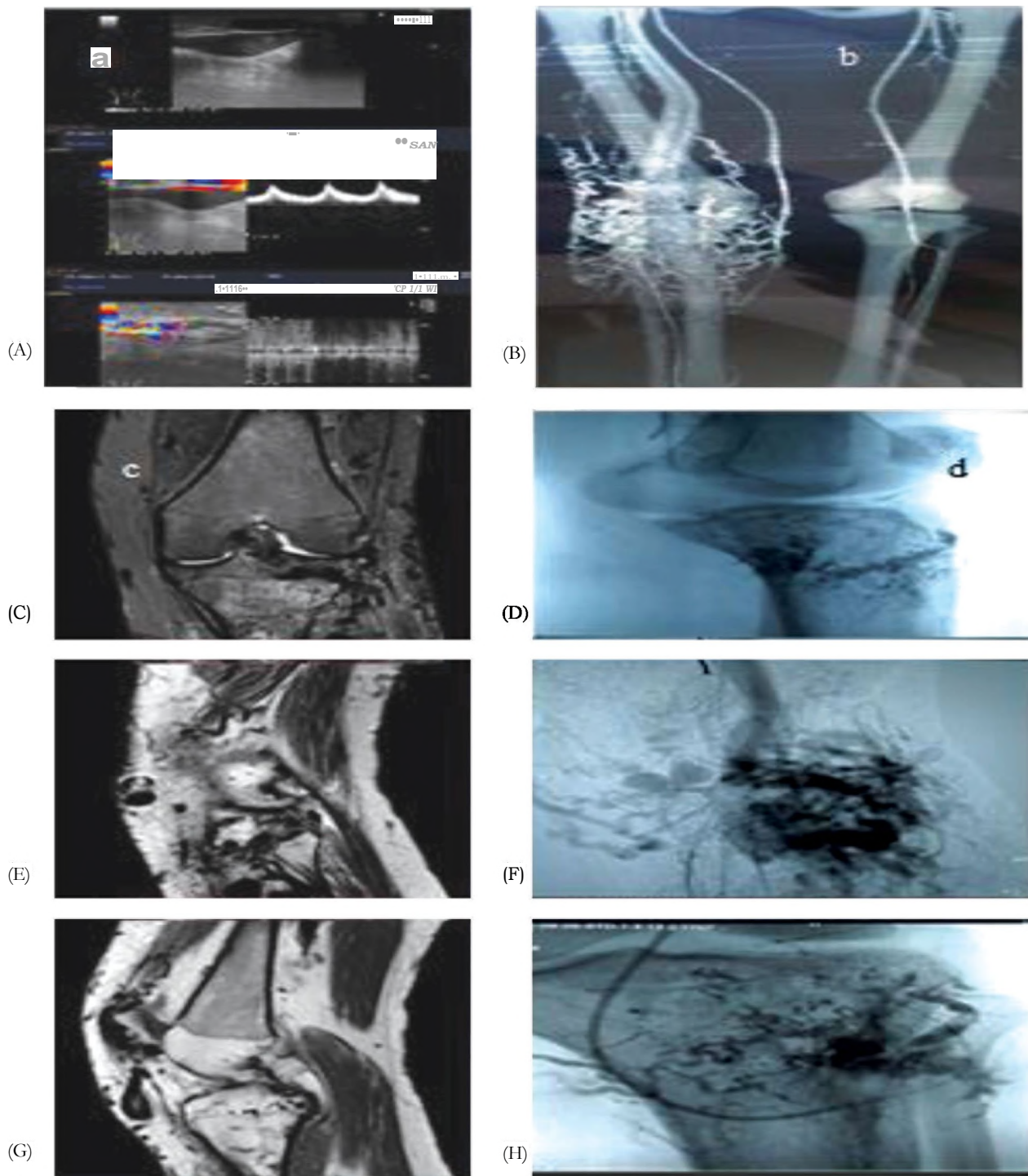


Fig. (2): 22 year old male patient complaining of multiple right knee joint pain, bluish swellings with eczema, ulcerations and redness of the right leg. A: Grey scale and color Doppler study of the right knee joint showed multiple dilated vascular channels with high flow detected on pulsed wave study. B: Reconstructed CT angiography image showing multiple dilated vascular channels around the knee joint. C: MR images STIR coronal and sagittal T1 and T2 showing multiple serpiginous signal void structures in all varicose veins and Diagnosis: High flow AVM with 2pulse sequences. D: Conventional angiography images lateral and oblique views showing part of the AVM embolization, Angiography and endo-vascular embolization was done on several sessions for the patient.



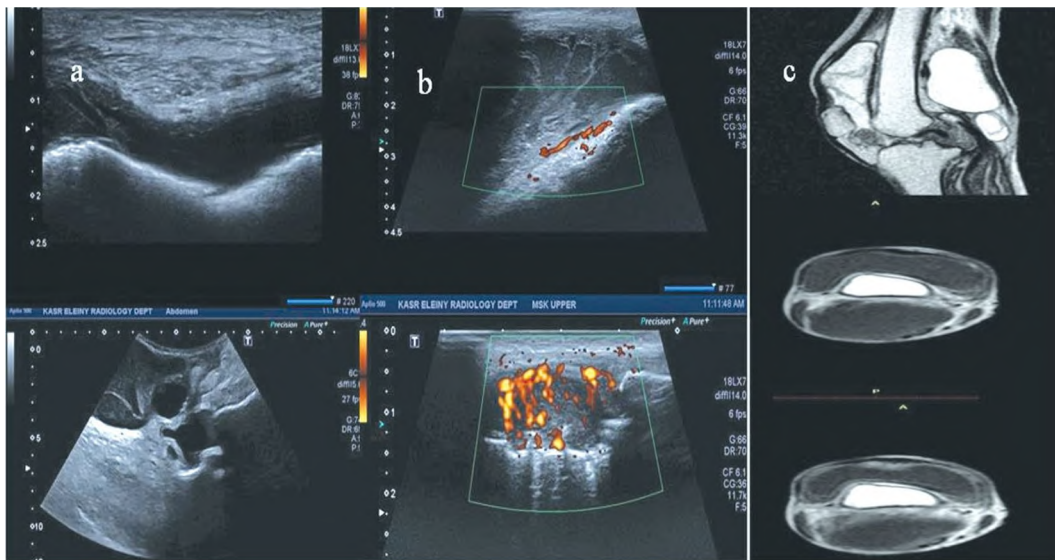


Fig. (3): 50 year old female patient known to have rheumatoid arthritis coming to clinic complaining from right knee swelling and pain.  
 A: Grey scale US examination showing marked right knee joint effusion and thickening of the synovial membrane with internal septations  
 B: Power Doppler study showing marked increase in the vascularity of the synovial thickening  
 C: MR images sagittal T2, axial T1 pre and post-contrast showing marked knee joint effusion, synovial hypertrophy with contrast uptake suggesting active inflammation.  
**Diagnosis:** Active rheumatoid arthritis with active synovitis and rheumatoid pannus formation of the right knee joint.

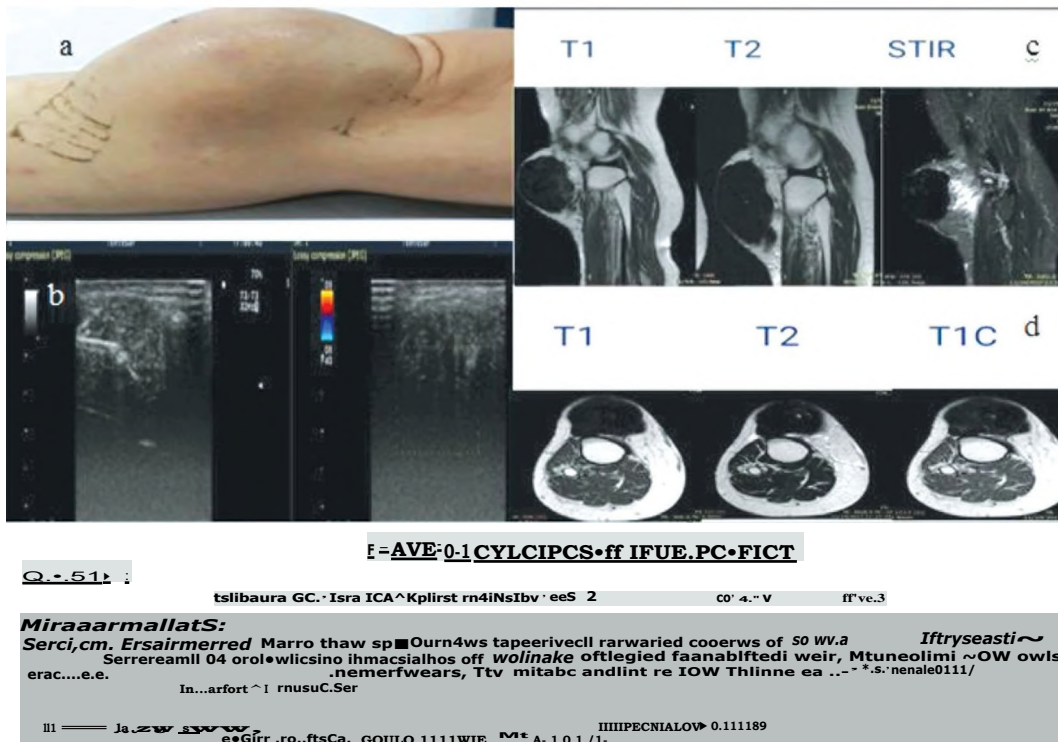


Fig. (4): 50 year old female patient presented by painless anterior knee swelling with insidious onset, slowly progressive course for 17 years with recent history of trauma then the swelling became painful.  
 A: Picture showing anterior knee swelling by inspection.  
 B: US images showing hypo-echoic mass lesion is seen with thin small slightly echogenic areas in between and no appreciable vascularity on color Doppler study.  
 C: MR study of the anterior knee mass lesion displaying very low signal intensity in all pulse sequences.  
 D: Pre and Post contrast MR study showing minimal contrast uptake within the lesion.  
 E: Pathology report of the tru cut biopsy from the lesion revealing fibromatosis of the anterior compartment of the knee joint.

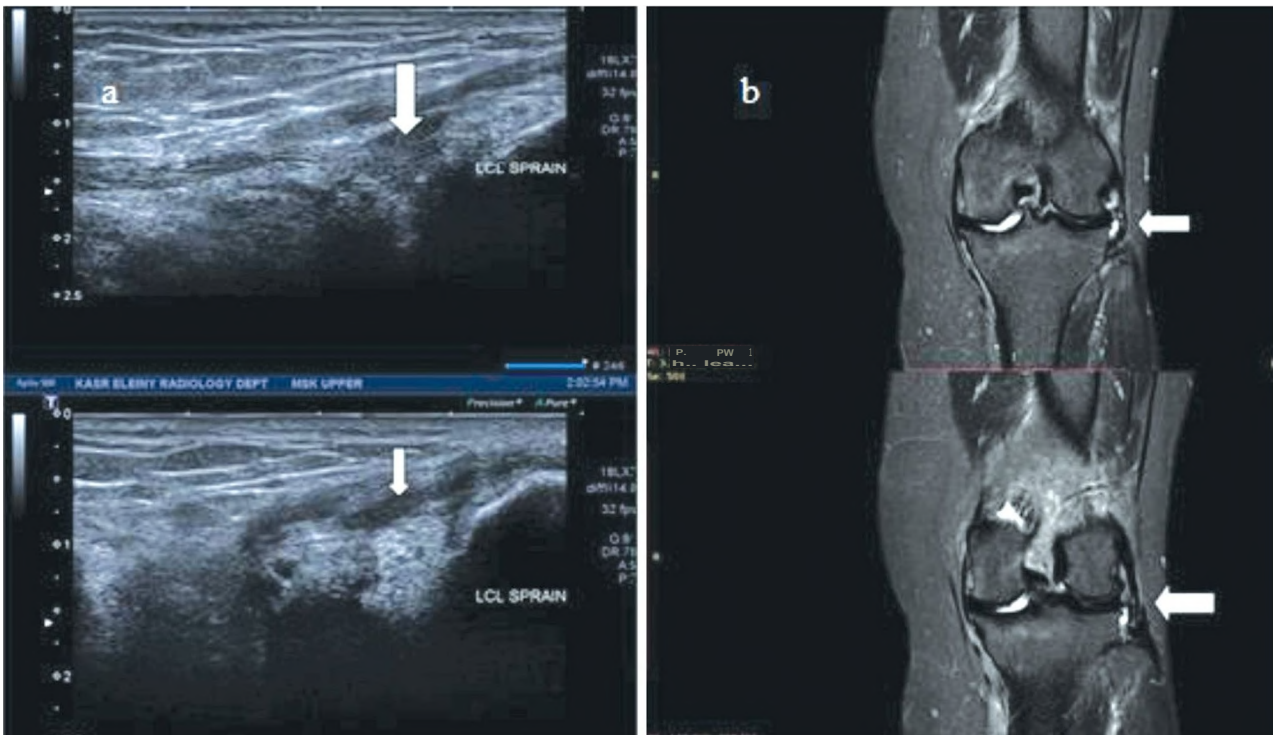


Fig. (5): 54 year old female patient had history of a verus injury to her right knee followed by knee pain and limitation of movement.  
 A: US examination of the lateral compartment of the knee joint LS and TS respectively showed peri-ligamentous and intra-ligamentous decreased echogenicity with rim of fluid collection suggestive of LCL sprain "white arrows".  
 B: MR coronal STIR images of the knee joint showed sprain of the LCL and mild knee joint effusion "white arrows" Diagnosis: LCL sprain.

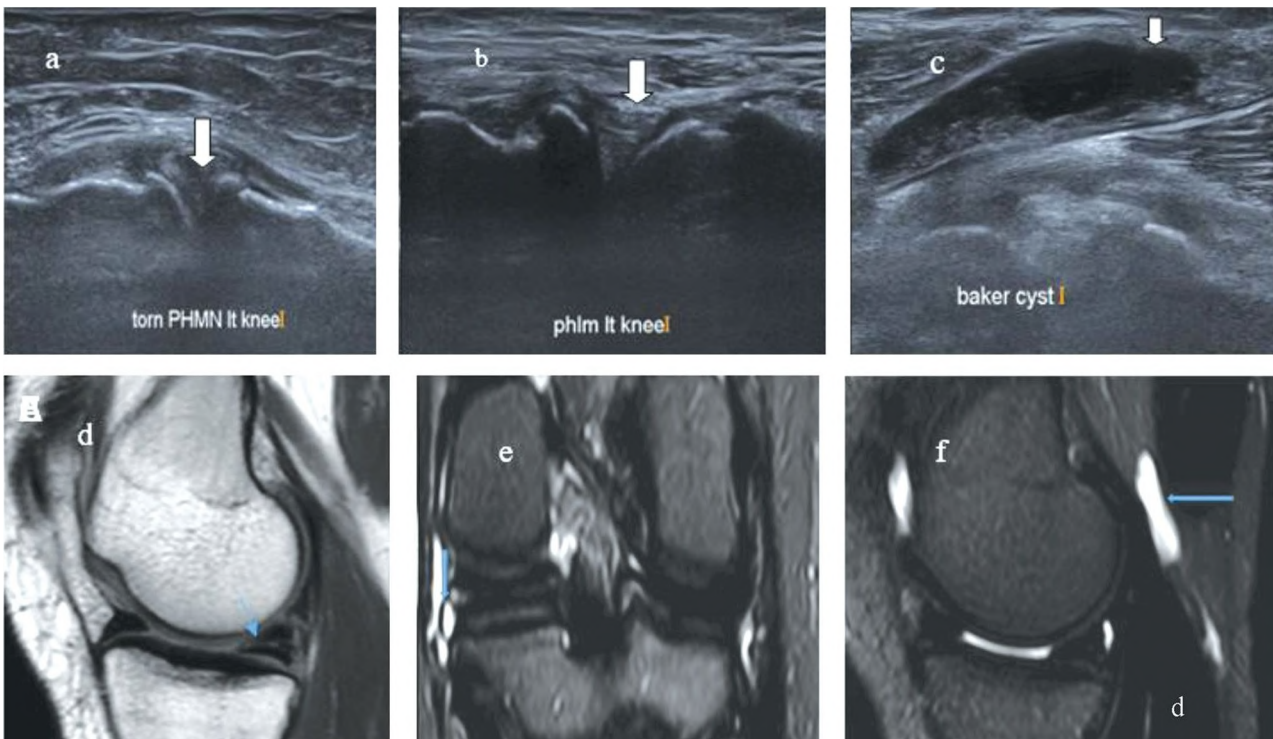


Fig. (6): 50 year old male patient with chronic knee pain; Grey scale ultrasonographic pictures of the knee joint showing PHMM tear reaching its menisco-capsular attachment (a), Intact PHLM (b), Baker's cyst with debris inside (c), Sagittal PD showed a linear intrasubstance tear of high SI of the PHMN reaching up to its root. (arrowed) (B) coronal T2 STIR showed the torn PHMN with a meniscal cyst (arrowed) (C) sagittal PD with fat suppression showed a small baker cyst (arrowed).

## Discussion

This study contrasted the MRI and ultrasound to determine how the latter can highlight its role for what is beyond chronic knee pain. 110 participants with a clinical diagnosis of chronic knee pain of at least 3 months' duration participated in our study. With ages ranging from 15 to 70, there were 66 females and 44 males. The female predominance was similar to a study by Muhammad R. A. Ali et al. While male predominance was noted by both Basha et al. and Mostafa et al. [6].

Compared to MRI. Ultrasonography detected 373 out of 436 findings (85.5%) detected by MRI in 120 examined knee joints with 10 cases having bilateral knee affection. Those findings might be the cause or contribute to the main participant complaint which is chronic knee pain. Nine different pathological entities were reported in our study by both US and MRI. So with the well-known advantages of the US, the orthopedic may be able to begin the patient care plan without the typical delay for requesting and scheduling MRI examinations, which would have a positive effect on the patient's recovery, thanks to the early and quick diagnosis provided by ultrasonography.

Our US findings percentage of 85.5% of 9 different pathological entities compared to MRI was very close to a study by Basha et al., [6] who examined 155 knee joints presented with anterior knee pain with 12 cases having bilateral affection, Ultrasonography detected 195 out of 259 findings (75.2%) detected by MRI of 11 different pathological entities. Our overall sensitivity, specificity, and **PPV** of US were 85.5%, and 100% respectively which were also similar to Basha et al., [6] (85.3% sensitivity, 100%, specificity, 100% **PPV**).

Concerning ligamentous entities, our study revealed a sensitivity of US in detecting MCL and LCL injuries of (93.3%, 100%) and (60%, 100%) respectively. For MCL injury, both Ghosh et al. (2017) showed sensitivity and specificity of 67% and 83% respectively and Muhammad R. A. Ali reported values of 75% and 100% in his study sensitivity and specificity respectively.

Our US modality reported 50% sensitivity and 100% specificity in the diagnosis of Patellar and quadriceps tendinopathies while Basha et al., [6] reported sensitivities of 84% and 87.5% for both Patellar and quadriceps tendinopathies respectively. These were due to the smaller sample size of the true positive cases (4) in our study compared to the latter study whose true positive sample size was 41 cases.

A frequently disregarded etiology of chronic knee pain is knee synovial plica syndrome. Anatomically speaking, there are three types; infra-patellar plica, supra-patellar plica, and medial patellar plica.

Our US examination succeeded to reveal 18 out of 20 cases with supra-patellar type with a sensitivity of 50% and a specificity of 100% which was close to Basha et al., [6] who reported a sensitivity and specificity of about 78.5% and 100% respectively with a predominance of the suprapatellar type.

Draghi et al., [in reported that ultrasonography had 81.3% sensitivity and 100% specificity in detecting knee effusion. While in Basha et al., [6] study, ultrasonography showed a sensitivity of 91.5% and specificity of 95.8% in detecting knee effusion.

Our study revealed 100% sensitivity and specificity of US in detecting Baker's cyst which agreed with Muhammad R. A. Ali that showed 100% sensitivity and specificity. Also, we noticed 20 patients with baker cysts in our study had been associated with OA changes in their knee joints. The US in our study also highlighted whether it is straightforward or complex. Slender septa and there may be a multi-lobulated configuration as well. These associative findings were matched with Hassanein et al., [12] whose study included 50 symptomatic knee joints with OA US findings showed irregular articular surface and narrow joint space in 36 (72.0%) knees, marginal osteophytes in 32 (64.0%) knees and Baker's cyst in 10 (20.0%) knees.

Our study showed that ultrasonography can be effectively utilized to evaluate knee OA parameters such as popliteal cyst, medial and lateral meniscal degeneration, joint effusion, and denuded femoral articular cartilage. In our study, the overall sensitivity and specificity as well as the accuracy of the ultrasound in the assessment of knee OA parameters were good (80.7%, 100%, and 85.1% respectively). This was very close to a study by Samar M.I. Shaaban [8] that revealed the US sensitivity was 89.3%, the overall accuracy was excellent (90%) and the overall specificity was 93.1%.

Concerning the cartilaginous OA changes, in the pertinent literature trochlear cartilage is referred to be the goal for US study as patellar cartilage cannot be well assessed by the US as the patella typically shades it. The changes ranged from reduction of its thickness either local or diffuse (<1mm), loss of normal definition of cartilage interface, and increased its echogenicity. In our study, we revealed the US resulted in 85.7% and 100% in sensitivity and specificity respectively. Basha et al., showed a sensitivity of 71.9% and a specificity of 98.4% in detecting trochlear cartilage defects. We agreed with them that the missed cartilage defect by the US may be buried deep within the intercondylar foramen. Also, the defects in patellar cartilage could not be assessed by ultrasonography because of the patellar shadow.

Koski et al., [13], Podlipska et al., [15], and Abdel Razek A.A. and El-Basyouni S.R., [14] studies



reported that ultrasound is sensitive in the determination of osteophytes and meniscal extrusion with an excellent inter-observer agreement with the MRI. In this study, we agreed with those meta-analyses as our US sensitivities for osteophytes, torn menisci, and meniscal extrusion was (84.4%, 100%, and 100%) and specificities of 100%. In contrast, Muhammad R. A. Ali [7] showed lower sensitivity in meniscal extrusion of 60%.

We agreed with Mostafa et al. [10] on the detection of meniscal degeneration, as our US sensitivity and specificity were 58.8% and 100%. The latter study reported sensitivity and specificity of 63.6% and 88.9% respectively. Samar M.I. Shaaban [8] detected higher sensitivity for both menisci degeneration; medial and lateral meniscal degeneration (94.4% and 93.3%), and a specificity of 80% for lateral meniscal degeneration. On other hand, a study by Muhammad R. A. Ali [7] showed that US sensitivity of 16.7% and specificity of 100% for meniscal degeneration. These statistical variations might be a result of operator dependence in the US.

The US enables the evaluation of the bone surfaces due to the different acoustic impedance between soft tissues and the bone cortex. Considering the cortical irregularities and subcortical pseudocysts, we had a sensitivity of 70% and specificity of 100%. This is matched with both Muhammad R. A. Ali and Schafer [7] who revealed higher sensitivities of (100%, and 95%) and specificities of (100%, and 98 %) respectively.

PrabakaranPalanisamy studied the role of Ultrasound in the study of tumors around the Knee joint and stated that; Cystic and solid as well as neoplastic benign and malignant lesions can be distinguished by USG. Additionally, USG displayed calcifications better than MR. Doppler with the grey scale parameters helped with diagnosis and the distinction between benign and malignant tumors.

In contrast to MRI and without regard to histopathology, this investigation demonstrated that the US is 100% sensitive, specific, and accurate in the detection and anatomical evaluation of soft tissue lesions around the knee joint. Also, we were able to reach the final diagnosis of 12 cases in agreement with the MRI as hematoma, lipoma, AVM, and hemangioma. Two cases of lipoma could not be diagnosed by the US alone as they showed atypical findings (calcifications and abundant vascularity). With the help of clinical examinations, we were able to identify schwannoma in one of the other four cases of peri-articular soft tissue lesions found by both US and MRI because knee pain is connected to neuropathic pain that radiates down the back of the calf and into the middle third of the leg. In the US, the mass was noticed along the continuity of the posterior tibial nerve.

In light of this, ultrasonography can be utilized for chronic knee pain diagnosis and can be detected during patient screening used in place of an MRI when one was not available or not recommended. Our study had several limitations; First; Joint effusion is the most frequent discovery in the present study. Despite the excellent enhanced ultrasonography's overall sensitivity in its diagnosis, it covered up its inability to detect other entities like an infrapatellar and a patellar cartilage problem plica, in addition to the acoustic interference window which is determined by the joint anatomy of the patient. Second; the US is an operator-dependent method, and the lack of inter and intra-observer agreements in our study might affect reliability. Third; the participants in this trial were already patients scheduled for an MRI test, which may result in a biased selection.

#### *Conclusion:*

As a result, the US showed high sensitivity and sufficient specificity for the evaluation of the painful knee joint when MRI is not accessible or is not recommended, this procedure safe and affordable. The US is showing promise in the early identification of osteoarthritis which is highly crucial as being a leading cause for chronic knee pain, describing the types of bone and cartilage and their extents of damage. It is a fantastic tool for detecting soft tissue lesions, especially vascular malformation.

#### *Declarations:*

##### *Ethics approval and consent to participate:*

- The current study had been approved by Kasr Al-Aini Hospital, Research and Ethical committee.
- We obtained IRB approval from Kasr Al-Aini Committee at Cairo University.
- Informed written consent was obtained from all individual participants included in the study.
- The committee's reference number is not applicable.

##### *Consent for publication:*

The authors affirm that human research participants provided written informed consent for publication of the images in the figures.

##### *Availability of data and material:*

The datasets used and/or analyzed during the current study are available from the corresponding author on reasonable request.

##### *Competing interests:*

The authors have no relevant financial or non-financial interests to disclose.

##### *Funding:*

No funding was obtained for this study.

**Authors' contributions:**

- SB and HM analyzed and interpreted the patient data regarding the magnetic resonance knee findings.
- AS and AH analyzed and interpreted the patient data regarding the ultrasonographic knee findings.
- HM and AH revised all the data interpreted by other authors.
- All authors read and approved the final manuscript.
- All authors agreed with the content and all gave explicit consent to submit.

**Acknowledgements:**

We thank all the participants and colleagues who provided insight and expertise that greatly assisted the research. We are also grateful for the comments offered by the anonymous peer reviewers.

**References**

- 1- MURPHY LB., MOSS S., DO B.T., et al.: Annual Incidence of Knee Symptoms and Four Knee Osteoarthritis Outcomes in the Johnston County Osteoarthritis Project. *Arthritis Care Res (Hoboken)*, 68: 55-65, 2016.
- 2- MAY, DAVID A., WILLIAM B. MORRISON and JEFFREY A.: *Belair. Musculoskeletal Imaging: The Core Requisites E-Book*. Elsevier Health Sciences, 2021.
- 3- STOCCO, ELENA, et al.: "Meniscus regeneration by 3D printing technologies: Current advances and future perspectives." *Journal of Tissue Engineering*, 13: 20417314211065860, 2022.
- 4- LARBI A., VIALA P., CYTEVAL C., et al.: Imaging of tumors and tumor-like lesions of the knee. *Diagn. Interv. Imaging*, 97: 767, 2016.
- 5- GHOSH N., KRUSE D. and SUBEH M.: Comparing Point-of-care-ultrasound (POCUS) to MRI for the Diagnosis of Medial Compartment Knee Injuries. *Journal of Medical Ultrasound*, 25 (3): 167-172, 2017.
- 6- MOHAMMAD ABD ALKHALIK BASHA, DIAA BAKRY ELDIB, SAMEH ABDELAZIZ ALY, et al.: Diagnostic accuracy of ultrasonography in the assessment of anterior knee pain *Insights into Imaging*, 11: 107, 2020.
- 7- MUHAMMAD REDA ABDULLAH ALI, AHMED ABDUL FATAH MAHMOUD ABO-RASHED and AHMED MUHAIVIMAD MOUSTAFA: Role of ultrasound in the evaluation of painful knee a comparative study to MRI. *Al-Azhar Med. J.(Medicine)*. Vol. 50 (3): July, 2351-2362, 2021.
- 8- SAMAR M.I. SHAABAN, M.Sc., MARWA I. FAHMY, M.D. and TAREK W. HEMADA, MD.: The Role of High-Resolution Ultrasound in the Assessment of Knee Osteoarthritis *Med. J. Cairo Univ.*, Vol. 87, No. 7, December: 4729-4735, 2019.
- 9- N.M. BUDERER: Statistical methodology: I. Incorporating the prevalence of disease into the sample size calculation for sensitivity and specificity *Acad. Emerg. Med.*, Sep. 3 (9): 895-900, 1996.
- 10- MOSTAFA H., ABOU ELFOTUH A. and ALSAKKA M.: MRI Versus Ultrasound in Diagnosis of Meniscal Tear In *Knee Joint*, 74 (2): 303-309, 2019.
- 11- DRAGHI F., FERROZZI G., URCIUOLI L., BORTOLLO C., et al.: Hoffa's fat pad abnormalities, knee pain and magnetic resonance imaging in daily practice. *Insights Imaging*, 7 (3): 373-383, 2016.
- 12- HASSANEIN, SHAIMAA A., ESRAA A. ZAHRA and MOHAMED R. EL KHOLY: "Role of ultrasonography in evaluation of knee osteoarthritis." *Menoufia Medical Journal*, 34.3: 1028, 2021.
- 13- KOSKI J.M., KAMEL A., WARIS P., et al.: Atlas-based knee osteophyte assessment with ultrasonography and radiography: Relationship to arthroscopic degeneration of articular cartilage. *Scand J. Rheumatol.*, 45 (2): 158-64, 2016.
- 14- ABDEL RAZEK AA. and EL-BASYOUNI SR.: Ultra-sound of knee osteoarthritis: Interobserver agreement and correlation with Western Ontario and McMaster Universities Osteoarthritis Clin. *Rheumatol.*, 35: 997-1001, 2016.
- 15- PODLIPSKA J., AROKOSKI JP., GUERMAZI A., et al: Comparison of Diagnostic Performance of Semi-Quantitative Knee Ultrasound and Knee Radiography with MRI: *Oulu Knee Osteoarthritis Study Scientific Reports*, 6: 22365, 2016.
- 16- SCHAAFER V.S., SCHMIDT WA., BACKHAUS M. and HARTUNG W.: Arthritis of the Knee Joint in Rheumatoid Arthritis - Evaluation of Treatment Response by Ultrasound in Daily Clinical Practice, 10: 81-87, 2016.
- 17- PRABAKARAN PALANISAMY, SUJATA PATNAIK, ABHISHEK ARORA, et al.: Role of Ultrasonography in Imaging of Tumors Around Knee Joint. *Journal of Clinical and Diagnostic Research*. Jun, Vol. 12 (6): TC01-TC06, 2018.



ما هو ابعء من الام الركبة المزمنة؟  
دراسة مقارنة بالموجات فوق الصوتية والرنين المغناطيسى  
لتقييم مساهمة الحالات المرضية المختلفة فى مفصل الركبة المؤلم

آلام الركبة المزمنة هى شكوى متزايدة وشائعة. نتيجة لذلك ، يعد اختيار أداة فحص يمكن الاعتماد عليها بتكلفة معقولة أمراً ضرورياً. على الرغم من أن التصوير بالرنين المغناطيسى هو الأداة الأساسية لتصوير لأنسجة الركبة فى الركبة ، إلا أن تكلفته المرتفعة كانت عائقاً. الهدف من هذه الدراسة هو اكتشاف فعالية التشخيص بالموجات فوق الصوتية كطريقة تصوير سريعة لتقييم ألم مفاصل الركبة بالمقارنة مع التصوير بالرنين المغناطيسى، والتي ستساعد لاحقاً فى التشخيص المبكر لأسباب آلام الركبة أو صعوبة الحركة.