

## Standalone Interbody Fusion Using PLIF for Treatment of Lumbar Disc Herniation with Collapsed Disc Height

MAHMOUD A. GOMAA, MD.\*; HANY MOHAILABA, M.D.\*\* and MOSTAFA M.A. ABDELLATIF, MD.\*

*The Department of Neurosurgery, Faculty of Medicine, Fayoum\* and Beni-Suer\* Universities*

### Abstract

**Background:** Chronic low back pain (LBP) and radicular pain due to lumbar disc prolapse affect a large number of people. Interbody fusion represents a valid surgical treatment in degenerative lumbar spine diseases, achieving satisfying results in the majority of patients. PLIF stabilizes the painful motion segment and may provide indirect decompression of the neural elements, and restore lordosis and disc height.

**Aim of Study:** To assess the clinical and radiological outcome of patients with lumbar disc prolapse with collapsed disc height operated by discectomy and Standalone PLIF fusion to restore disc height.

**Patients and Methods:** This is a prospective study that had been occurred between October 2022 until October 2023 on 57 patients with single-level lumbar disc prolapse indicated for surgery in the Neurosurgery department at Fayoum University Hospital and Neurosurgery Department at Beni-Suef University Hospital.

**Results:** There was a statistically significant change in the disc height which increased from a mean preoperative height of  $7.68 \pm 1.13$  mm to a mean postoperative height of  $10.40 \pm 1.43$  mm, with a mean difference of 2.73 mm (95% CI: 2.55 to 2.90), p-value <0.001.

There was a statistically significant change in LBP and radicular pain. Post-hoc analysis using the Bonferroni method showed that the mean LBP score on VAS score, 3 months post-operative was  $1.86 \pm 1.04$ ; which was a lower score compared with the mean preoperative LBP score of  $4.44 \pm 1.88$ .

**Conclusion:** We concluded that the PLIF technique without screws fixation is a valid modality of treatment of discogenic low back pain associated with radicular lower limb pain. Restoration of disc height improves radicular pain by foramen decompression and fusion improves Low back pain.

**Key Words:** Disc prolapse — Lumber — PLIF — Disc height.

### Introduction

**LOW** back pain is the most important factor causing limitation of activity in patients younger than 45 years old, the second most common symptom for physician's visits, and the third most common indication for surgical intervention [1]. The spectrum of degenerative spinal diseases includes degenerative disc diseases, facet joint arthritis, spinal stenosis, degenerative spinal scoliosis, and spondylolisthesis [2].

Spinal fusion has been long considered the best option to treat lower back pain generated from disc degeneration in which conservative treatments were not satisfactory, and in combination with decompression performed due to discogenic spinal canal stenosis [3].

Direct and clear comparative data available on the evidence of spinal fusion for managing discogenic low back pain is scarce. The comparative evidence mostly compares spinal fusion with other options for the treatment of discogenic back pain. Bydon et al., [4] conducted a systematic review and meta-analysis of five randomized studies with two groups: 523 patients were allocated to the lumbar fusion group and 134 patients were managed by non-fusion options. The results revealed significant improvement in the lumbar fusion groups in three of the included trials.

There have been randomized controlled trials showing no significant improvement in short-term outcomes in instrumented fusion compared to non-instrumented fusion. Nevertheless, treatment strategies have moved towards fusion based on that restoration of lordosis, sagittal balance, and neural foramen decompression due to restoration of the disc height would result in better clinical outcomes [5].

Degenerative lumbar spine disorders are the most common causes of low back pain. Lumbar fusion techniques contributed to solving this com-

**Correspondence to:** Dr. Mahmoud A. Goomaa,  
E-Mail: [Mam36@fayoum.edu.eg](mailto:Mam36@fayoum.edu.eg)

plaint. PLIF is one of the modern techniques of lumbar interbody fusion which showed an effective role in treating low back pain caused by degenerative lumbar spine disorders [6].

### Patients and Methods

This is a prospective study including 57 patients with single-level lumbar disc prolapse indicated for surgery. It had been conducted between October 2022 until November 2023 at the Neurosurgery Department, Fayoum University Hospital, Fayoum, Egypt. The Institutional Review Board (IRB) number for this trial is R-259 and Neurosurgery Department, Beni-Suef University Hospital, Beni-Suef, Egypt.

#### Inclusion criteria:

All patients with single-level Lumbar disc prolapse (de novo or recurrent) with degenerative collapsed disc space (decreased height) are indicated for surgical decompression.

#### Exclusion criteria:

Patients with the following characteristics were excluded; patients with evident preoperative radiological instability, patients with disc infection (discitis), and patients with multiple levels of disc prolapse in need of surgery.

#### Clinical assessment (Preoperative):

A detailed history is taken from all patients fulfilling all general and neurological symptoms. Back pain and Radicular Lower Limb pain were assessed using a Visual Analogue Score (VAS) graded from zero to 10, Zero means no pain at all, 1-3 means mild pain, 4-6 for moderate pain, 7-9 means severe pain and 10 for agonizing worst pain.

Full neurological assessment of motor function: Power, reflexes, tone, sensory function, coordination, and gait assessment.

#### Preoperative imaging studies:

**MRI** Lumbosacral spine was done for all patients, X-ray Lumbar spine with flexion and extension positions were done for all patients to assess stability, and CT Lumbar spine sagittal cut to measure the disc height in millimeters; Figs. (1,2).

#### Disc height measurement:

The disc height was assessed on CT by measuring the space between the midpoint of the Lower endplate of the vertebra above and the midpoint of the upper endplate of the vertebra below in the mid-sagittal plane.

**Counseling and Consent:** Patients were informed about the underlying neurological problems, rule of surgery, surgical technique, post-operative care, and expected mortality & morbidity and their percentages.

#### Preoperative preparation:

Patients were usually admitted the day before the operation, Antibiotic was given at the induction of the anesthesia for all patients.

#### Technical note:

All patients were operated on under general anesthesia in the prone position on Wilson's frame. An image by C-arm just before skin incision to make sure of correct surgical disc level was done. A median skin incision is performed, followed by bilateral sub-periosteal muscles separation to expose the lamina bilaterally with facet capsule preservation.

Hemilaminotomy was done in cases with unilateral disc prolapse and bilateral laminotomies were done in cases with large central disc prolapse or bilateral neural compression, then conventional discectomy was carried out. Good preparation of disc space was achieved by curettage of both endplates using curettes and reamers with the removal of all disc fragments and then washing by tapped saline inside evacuated disc space to wash any flail fragments.

The disc space is then filled with bone graft harvested locally from the lamina, cage size was measured by fluoroscopy assistance by comparing the height of the disc above and below the surgical level or the level above only in case of operating L5-S 1 Level, then the cage is filled by bone granules and adjusted from one side with gentle root and dural sac retraction.

**Post-operative care:** Clinical assessment of motor power immediately after recovery.

#### Follow-up and evaluation after operation:

- Assessment of back pain and lower limb pain was done by the patient using VAS oneweek post-operative and 3 months later.
- Follow-up X-ray was done 24 and 48 hours post-operative as a routine to ensure the cage placement in the disc space and Ct sagittal cut was done 3 months post-operative to judge disc height and compare it with preoperative measure; Fig. (3).

#### Statistical analysis:

Descriptive statistics are presented in the form of mean and standard deviation for numerical variables, while numbers and percentages are used for categorical variables. Comparison of the disc height preoperative and 3 months postoperative was done using the paired-samples t-test, while the comparison of LBP and radicular pain was done using repeated-measures ANOVA.

IBM SPSS 28 for windows software was used for the analysis, and a p-value <0.05 is considered statistically significant.

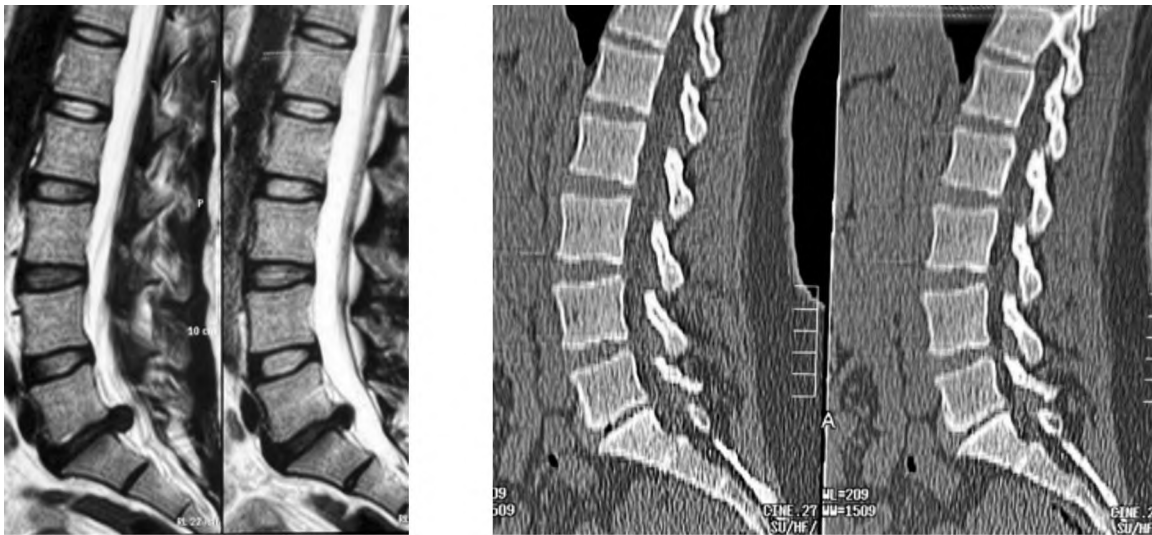

Fig. (1): Ct & MRI LSS Sagittal cuts showing L-5S1 disc prolapse with collapsed disc space at index level "preoperative".

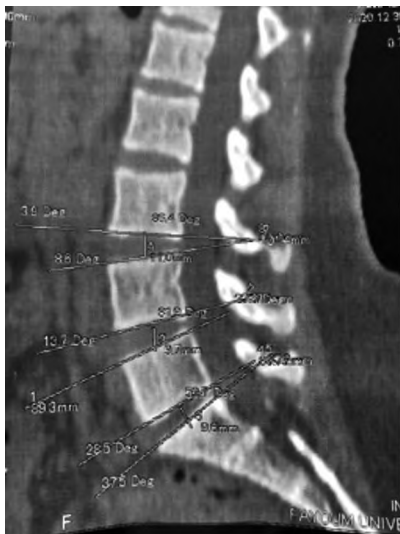

Fig. (2): Ct LSS with measurement of disc height of 9.6 mm in the midpoint.

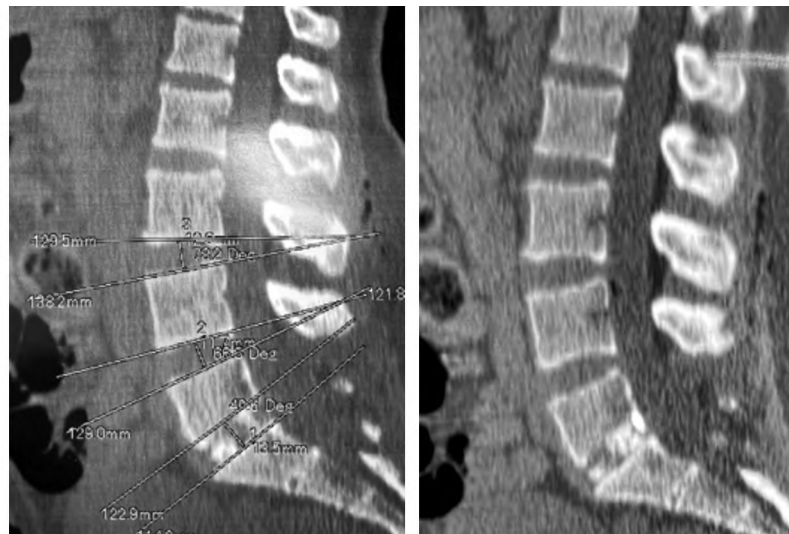


Fig. (3): Ct LSS showing L-5S1 disc interbody cage with the restoration of disc height 135 mm "post-operative".

**Results**

A total of 57 patients were included in our study. 63.3% were males while 36.8% were females with a mean age of  $41.33 \pm 7.82$  years. The level most affected in this study was L4-5 followed by L5-S1 and lastly L3-4 level. 56.1% of our patients had an operation at the L4-5 disc, 36.9% at the L5-S1 level, and only 7% at the L3-4 level. The mean operative duration was  $65.96 \pm 10.26$  minutes and the mean blood loss was  $217.63 \pm 101.72$  ml, no patients need blood transfusion intraoperative or postoperative. General characteristics of the study population are shown in Table (1).

Unintended durotomy occurred in 10 patients representing 17.5% which is a big percentage but

this is not related to PLIF insertion as most of this occurred during laminotomy or flavectomy. One patient was complicated by a CSF leak for 4 days which was managed conservatively by prone position and prophylactic antibiotics. Superficial wound infection occurred in two cases which were managed by repeated dressing and antibiotics with no further wound problems and healed well. Worsening of back pain occurred in two patients, MRI LSS & X-ray LSS were done for both to exclude surgical problems like discitis or instability but no further diagnosis was reached and epidural injection was done for both with good outcomes in one patient and the other patient did not improve.

Comparison of pre and post-operative clinical data are mentioned in Table (2).

Table (1): Characteristics of the study participants and operation (n=57).

	N	%
<b>Sex:</b>		
Male	36	63.2
Female	21	36.8
Age, mean (SD)	41.33 (7.82)	
<b>Level:</b>		
L4-3	4	7.0
L5-4	32	56.1
L-5S1	21	36.9
Operative duration (min), mean (SD)	65.96 (10.26)	
Bloodloss (ml), mean (SD)	217.63 (101.72)	
Dural tear	10	17.5
<b>Other Complications:</b>		
CSF leak for 4 days	1	1.8
Superficial wound infection	2	3.5
Worsening of back pain	2	3.5

Table (2)• Comparison of the disc height and pain level pre and post-operative.

	Mean	SD	p-value
<b>Disc height, nun:</b>			
Disc height pre	7.68	1.13	<0.001
Disc height post 3 months	10.40	1.43	
<b>LBP:</b>			
LBP preoperative	4.44	1.88	<0.001*
LBP post 1 week	3.88	1.39	
LBP post 3 month	1.86	1.04	
<b>Radicular pain:</b>			
Radicular pain preoperative	7.65	1.37	<0.001**
Radicular pain post 1 week	2.19	1.23	
Radicular pain post 3 months	0.96	0.93	

\* 3m less than preoperative and lw-post operative.

\*\* 3m less than lw less than preoperative.

There was a statistically significant change in the disc height which increased from a mean pre-operative height of  $7.68 \pm 1.13$ mm to a mean postoperative height of  $10.40 \pm 1.43$ mm, with a mean difference of 2.73mm (95% CI: 2.55 to 2.90), p-value <0.001; Fig. (4).

Using the VAS score for pain assessment; there was a statistically significant change in LBP and radicular pain. Post-hoc analysis using the Bonferoni method showed that the mean LBP score on VAS 3 points post-operative ( $1.86 \pm 1.04$ ) was lower than the mean LBP level preoperative ( $4.44 \pm 1.88$ ) and the mean LBP 1-week post-operative ( $3.88 \pm 1.39$ ); Fig. (5). There was no statistically significant difference in the back pain level between preoperative and 1-week postoperative.

For the radicular pain, there was a statistically significant change across the three-time points. The pain score on VAS decreased from a mean preoperative score of ( $7.65 \pm 1.37$ ) to ( $2.19 \pm 1.23$ ) one week post-operative, then it decreased again to ( $0.96 \pm 0.93$ ) three months post-operative, Fig. (6).

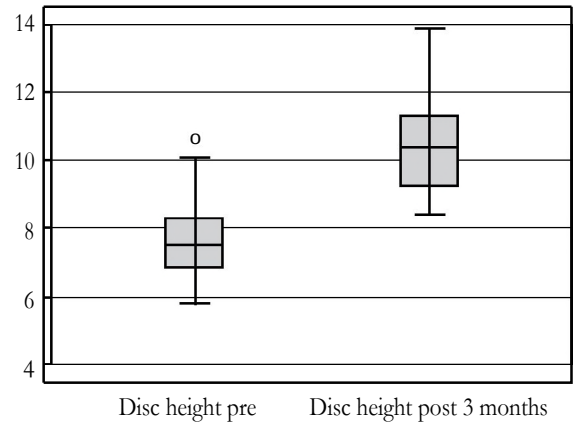


Fig. (4): Change of disc height.

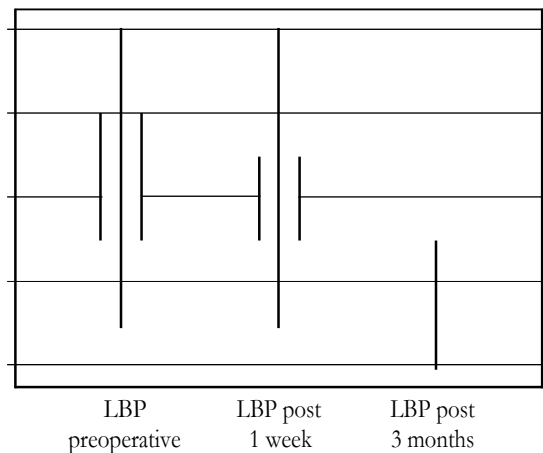


Fig. (5): LBP preoperative, 1 week and 3 months postoperative.

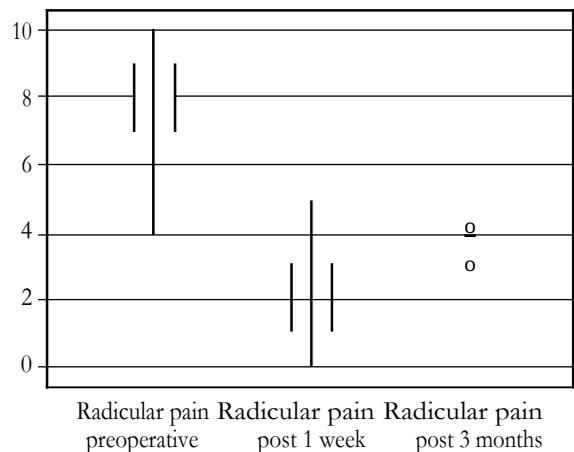


Fig. (6): Radicular pain preoperative, 1 week and 3 months postoperative.

## Discussion

Disc herniation means the protrusion of part or all the nucleus pulposus through the annulus fibrosus. The most common causes of this herniation include degeneration with age and trauma such as occupational trauma [7]. The main aim of this study was to analyze the results achieved in a series of 57 patients with symptomatic lumbar disc prolapse associated with degenerated disc space with collapsed disc height, who was operated upon by discectomy and interbody fusion using standalone Lumbar PLIF cage without screws fixation.

We found that the PLIF technique without screws fixation is a valid modality of treatment of discogenic low back pain associated with radicular lower limb pain. Patients showed post-operative improvement compared to their preoperative measures. Post-hoc analysis revealed a statistically significant change in LBP and radicular pain. The mean LBP score on VAS score, 3 months post-operative was  $1.86 \pm 1.04$ ; which was a lower score compared with the mean preoperative LBP score of  $4.44 \pm 1.88$ . Moreover, compared to the preoperative measurements there were a statistically significant change in the postoperative disc height with a mean difference of 2.73mm (95% CI: 2.55 to 2.90), p-value <0.001.

The majority of our patients were males (63.2%) in their middle age, which coincides with the fact that herniation occurs more commonly in males than in females in a ratio that can reach 2:18. This is explained by the fact that in our community males are more amenable to complaining of disc prolapse than females due to occupational factors [7].

In our study, we used surgical interbody fusion as a surgical modality of treatment of degenerative disc disease and this has shown great efficacy in treating the painful motion segment and may allow indirect decompression of the neural tissue and restore lumbar lordosis and disc height [9]. This technique is considered a minimally invasive surgery, avoiding most of the morbidities and complications [10]. Using the VAS score for pain assessment; our patients' scores decreased by 3 points 3 months postoperatively compared with the preoperative measures. However, there was no statistically significant difference in the back pain level between preoperative and one-week postoperative measures. This could be explained by surgical wound pain and muscle spasm that occurred after surgery.

Our findings coincide with the results of a study by Costa, Francesco, et al., [10], who used a standalone cage for posterior lumbar interbody fusion. They included the analysis of 116 patients; 110 of them had their VAS score improved more than 3 points within 2 years postoperatively [10]. This could be explained as the fusion attained in PLIF avoided painful nerve root irritation from postoperative perineural fibrosis [11]. Furthermore, the

appropriate laminotomy, mesial facetectomies, and foraminotomy in PLIF, all decrease the incidence of expected bony compression of the nerve roots [12].

The PLIF technique has many advantages. The first advantage is that the PLIF approach is considered a classical and familiar approach for the majority of spine neurosurgeons and is an easy technique to do. Secondly, the posterior exposure enables good visualization of the nerve roots. Additionally, PLIF permits effective interbody height restoration allowing for root decompression by increasing foramen height while preserving posterior support structures [13]. However, using this technique, there is difficulty in restoring lordosis and coronal imbalance. In addition, endplate preparation may be difficult compared to anterior fusion approaches and there is a potential risk of retraction injury of nerve roots and hence radiculopathy [14,15].

Some studies compare Posterior Lumbar Interbody Fusion (PLIF) and other approaches such as Transforaminal Lumbar Interbody Fusion (TLIF), Anterior Lumbar Interbody Fusion (ALIF), Lateral Lumbar Interbody Fusion (LLIF), and others for the treatment of lumbar degenerative diseases. Tao Lan et al., discussed this and found that both TLIF and PLIF could achieve similar clinical satisfaction and fusion rate in the management of degenerative lumbar diseases [16]. Although TLIF was associated with a better postoperative visual analog scale than PLIF, however, there was no statistical difference regarding these results [16].

However, we didn't face any major complications rather than the ordinary risk of any lumbar surgery, and blood loss was accepted with no patients needing blood transfusion intraoperative or postoperative. Surgery time was also accepted with no prolonged anesthesia complications. Superficial wound infection occurred in two patients and improved on medical treatment with no need for debridement.

**Limitations:** The main limitation of our study is the small sample size which limits the generalizability of our results. However, it is still a safe and applicable option for those patients. We recommend conducting multicentric studies with a variation of the demographic and clinical characteristics of the included patients to generalize the results and reach reliable and applicable evidence for the general population. Another major limitation of this study is the lack of a comparison control group, which can be addressed in future studies. Overall this was a good study and the findings contribute significantly to the body of existing literature.

### Conclusion:

In our opinion, Standalone PLIF can be regarded as a valid surgical option of treatment of chronic low-back pain and lower limb pain due to lumbar disc prolapse. It restores the disc height which im-

proves radicular pain by foramen decompression; while the intervertebral fusion improves low back pain. This technique can be considered safe and successful, as shown by the accepted clinical and radiological outcomes.

#### Declarations:

**Ethics approval and consent to participate:** Ethical approval was obtained from the **IRB**. (IRB number: R-259). All patients signed an informed consent to participate in this study.

**Consent for publication:** An informed consent for publication was obtained from all participants in this study.

**Availability of data:** All data are available through contacting the corresponding author.

**Competing interests:** None.

**Funding:** All authors confirm that no fund was received from any source.

**Acknowledgment:** Not applicable.

#### References

- 1- ANDERSSON GB.: Epidemiological features of chronic low-back pain. *Lancet* (London, England), 354 (9178): 581-585, 1999. [https://doi.org/10.1016/S0140-6736\(99\)01312-4](https://doi.org/10.1016/S0140-6736(99)01312-4).
- 2- MIDDLETON K. and FISH D.E.: Lumbar spondylosis: Clinical presentation and treatment approaches. *Current reviews in musculoskeletal medicine*, 2 (2): 94-104, 2009. <https://doi.org/10.1007/s12178-009-9051-x>.
- 3- GIBSON J N.A. and WADDELL G • Surgery for degenerative lumbar spondylosis: updated Cochrane Review. *Spine*, 30 (20): 2312-2320, 2005. <https://doi.org/10.1097/01.brs.0000182315.88558.9c>.
- 4- BYDON M., DE LA GARZA-RAMOS R., MACKI M., BAKER A., GOKASLAN A.K. and BYDON A.: Lumbar fusion versus nonoperative management for treatment of discogenic low back pain: A systematic review and meta-analysis of randomized controlled trials. *Journal of spinal disorders & techniques*, 27 (5): 297-304, 2014. <https://doi.org/10.1097/BSD.0000000000000072>.
- 5- !!! INVALID CITATION !!! (5-7).
- 6- SHUNWU F., XING Z., FENG DONG Z. and XIANG-QIAN F.: Minimally Invasive Transforaminal Lumbar Interbody Fusion for the Treatment of Degenerative Lumbar Diseases. *Spine*, 35 (17), 2010.
- 7- WOORIDUL SPINE HOSPITAL D., HONG PARK C., SOO PARK E., et al.: Observational Study Risk Factors for Early Recurrence After Transforaminal Endoscopic Lumbar Disc Decompression.
- 8- FJELD O R , GROVLE L., HELGELAND J., et al.: Complications, reoperations, readmissions, and length of hospital stay in 34 639 surgical cases of lumbar disc herniation. *The bone & joint journal*, 101-B (4): 470-477, 2019. <https://doi.org/10.1302/0301-620X.101B4.BB-2018-1184.R1>.
- 9- MOBBS R.J., PHAN K., MALHAM G., SEEX K. and RAO P.J.: Lumbar interbody fusion: Techniques, indications and comparison of interbody fusion options including PLIF, TLIF, MI-TLIF, OLIF/ATP, LLIF and ALIF. *Journal of spine surgery (Hong Kong)*, 1 (1): 2-18, 2015. <https://doi.org/10.3978/j.issn.2414-469X.2015.10.05>.
- 10- COSTA F., SASSI M., ORTOLINA A., et al.: Stand-alone cage for posterior lumbar interbody fusion in the treatment of high-degree degenerative disc disease: Design of a new device for an "old" technique. A prospective study on a series of 116 patients *European Spine Journal*, 20 (Suppl 1): 46-46, 2011. <https://doi.org/10.1007/500586-011-1755-0>.
- 11- BUNNELL WP.: Anterior spinal fusion: Experimental evaluation of technique. *Journal of pediatric orthopedics*, 2 (5): 469-477, 1982. <https://doi.org/10.1097/01241398-198212000-00002>.
- 12- LIN P.M., CAUTILLI R.A. and JOYCE M.F.: Posterior lumbar interbody fusion. *Clinical Orthopaedics and Related Research*, 180: 154-168, 1983. <https://doi.org/10.1097/00003086-198311000-00019>.
- 13- LESTINI W.F., FULGHUM J.S. and WHITEHURST LA.: Lumbar spinal fusion: Advantages of posterior lumbar interbody fusion. *Surgical technology international*, 3: 577-590, 1994.
- 14- BODEN SD., SUMNER D.R., ANDERSSON GB.J., et al.: Biologic Issues in Lumbar Spinal Fusion Introduction. *Spine*, 20: 102S-102S, 1995. <https://doi.org/10.1097/00007632-199512151-00006>.
- 15- ZHANG Q ., YUAN Z., ZHOU M., LIU H., XU Y. and REN Y.: A comparison of posterior lumbar interbody fusion and transforaminal lumbar interbody fusion: A literature review and meta-analysis. *BMC Musculoskeletal Disorders*, 15 (1), 2014. <https://doi.org/10.1186/1471-2474-15-367>.
- 16- LAN T., HU S.Y., ZHANG Y.T., et al.: Comparison Between Posterior Lumbar Interbody Fusion and Transforaminal Lumbar Interbody Fusion for the Treatment of Lumbar Degenerative Diseases: A Systematic Review and Meta-Analysis. *World Neurosurgery*, 112: 86-93, 2018. <https://doi.org/10.1016/J.WNEU.2018.01.021>.

## الدمج المستقل للفقرات القطنية بإستخدام القفص القطنى بين الفقرات من الخلف لعلاج الإنزلاق الغضروفى القطنى مع هبوط حجم الغضروف الناتج عن الإنزلاق

الخلفية: تصيب آلام الظهر المزمنة وآلام عرق النسا قطاع كبير من المرضى. التدخل الجراحي لإلتئام ودمج الفقرات يعتبر أحد الحلول العلاجية التي يمكن أن تحسن الأعراض بشكل كبير. إستخدام القفص القطنى الخلفى لدمج الفقرات يؤدي إلى عودة ارتفاع فراغ الغضروف إلى وضعه الطبيعي مما يؤدي لإزالة الضغط الواقع على جذور الأعصاب وعودة الإنحناء الطبيعي للفقرات القطنية .

الهدف من الدراسة: عرض النتائج السريرية الطبية ونتائج الأشعات لمرضى الإنزلاق الغضروفى القطنى الذين تم علاجهم بإستخدام تقنية الدمج الخلفى للفقرات بإستخدام القفص القطنى الخلفى لعلاج هبوط حجم فراغ الغضروف الناتج عن الإنزلاق الغضروفى القطنى.

الطرق والمرضى: تم عمل هذه الدراسة فى الفترة من شهر أكتوبر ٢٠٢٣ وحتى شهر نوفمبر ٢٠٢٣ على ٥٧ مريض يعانون من إنزلاق غضروفى قطنى وذلك بقسم جراحة المخ والأعصاب بمستشفيات جامعة الفيوم وقسم جراحة المخ والأعصاب بمستشفيات جامعة بنى سويف وتم تحليل البيانات التى تم جمعها من الحالات لتقديم النتائج.

النتائج: أظهرت نتائج الأشعة وجود نتيجة إيجابية ملموسة فى زيادة إرتفاع فراغ الغضروف المنزلق من ٦,٦٨ ملليمتر قبل الجراحة تقريبا إلى ١٠,٤٠ تقريبا بعد الجراحة وذلك بمتوسط زيادة تقريبا ب ٣,٧٣ ملليمتر. كان هناك أيضا تحسن ملموس فى الحالة الطبية للمرضى بتحسن آلام الظهر والطرفين السفليين بعد الجراحة بثلاثة أشهر بشكل ملحوظ عما كان الوضع عليه قبل إجراء العملية الجراحية.

الخلاصة: نستخلص من هذه الدراسة أن علاج الإنزلاق الغضروفى القطنى المنزلق عن طريق الدمج الخلفى للفقرات بإستخدام القفص القطنى الخلفى بدون تثبيت الفقرات بمسامير ودعامات معدنية هو أحد طرق العلاج الفعالة والناجحة فى تحسين آلام الظهر والطرفين السفليين مع زيادة ارتفاع قرص الغضروف المنزلق إلى وضعه الطبيعي مما يؤدي إلى رفع الضغط الواقع على جذور الأعصاب.