



ORIGINAL ARTICLE

Presentation of Allergic Fungal Rhinosinusitis in Sinonasal polyposis

Atef taha El Bahrawy, Magdy Mohamed Abd El Fattah, Wael Fayez Nasr, Peter Beshara Shafick Beshara

Otorhinolaryngology department, Faculty of medicine zagazig university

Corresponding author :

Peter Beshara Shafick Beshara

drpeterent@gmail.com

M.B.B.CH

Faculty of medicine
zagazig university

Submit Date 2019-04-09

Revise Date 2019-06-09

Accept Date 2019-06-11

ABSTRACT

Background: Allergic fungal rhinosinusitis (AFRS) was first reported as a distinct clinical disorder in 1976. There is no convincing evidence for clinical improvement of CRS with anti-fungal therapy. The fungi causing AFRS have a great diversity. This study aimed to assess presentation of AFRS in patients with sinonasal polyposis.

Patients and methods: This prospective study was carried out in OLR-HNS Department, Zagazig University on 36 patients having sinonasal polyposis scheduled for functional endoscopic sinus surgery. All patients were subjected to full history taking, general and local examinations, routine preoperative laboratory and radiological assessments, assessment of Total IgE level and removal of the nasal polypi with microbiological study and histopathological examination for fungal elements.

Results: 13.9% of the studied patients show positive fungal stain. 80% of them show *Aspergillus Fumigates* on fungal culture while 20% show *Candida Albicans*. 80% of the patients diagnosed with AFRS were from rural areas. 72.2% of the studied patients had allergy. IgE levels in AFS patients ranged between 572.10 – 623.10 IU/ml while those in patients with polyposis only ranged between 191.20 – 381 IU/ml. Most of the studied patients presented with mild polyp, thick mucopurulent discharge and had total opacification in all sinuses and obstructed OMC.

Conclusion: Diagnosing AFRS in patients with sinonasal polyposis could improve the outcome of surgery and reduce the recurrence rate by proper treatment postoperatively.

Key Words: paranasal sinus, mycology, Allergic fungal rhinosinusitis

INTRODUCTION

Allergic fungal rhinosinusitis (AFRS) was reported for the first time as a unique clinical disorder in 1976. AFRS is defined largely by the presence of allergic fungal mucin, which is a thick, tenacious and eosinophilic secretion with characteristic histologic findings [1].

In 1994, Bent and Kuhn had published their diagnostic criteria focusing on the histologic, radiographic, and immunologic characteristics of the disease including: Type I hypersensitivity, Nasal polyposis, Characteristic findings on CT scan, Presence of fungi on direct microscopy or culture and allergic mucin containing fungal elements without tissue invasion [2].

According to the recent literature, the histopathological features is the most essential criteria for the diagnosis of Allergic fungal sinusitis [3]. Although there are many defects in the natural and acquired immunity of Chronic rhinosinusitis (CRS) patients that might reduce their ability to react to fungi, there are a few studies that suggest a **disease modifying role** of fungi in CRS [4].

According to **Stammberger [5]**, AFRS is IgE mediated condition in response to different fungi present in the sinonasal eosinophilic mucin. The theory is confirmed by identification of specific IgE in cultures. Currently, the most widely accepted hypothesis excludes the allergic etiology and recommends the term “eosinophilic fungal sinusitis”.

AFRS causative fungi have a great variety. In 1998, Manning and Holman reported 168 positive cultures, 87 % of the cases showed dematiaceous fungi, and 13 % showed *Aspergillus* species. Interestingly, *Aspergillus flavus* was also isolated from 50 % of patients diagnosed with AFRS in the Middle East [6].

Regional variation in the incidence of AFRS has been described worldwide. Recently a new staging system (Philpott-Javer Endoscopic staging system) was created for post-operative cases of AFRS. This was derived as a modification of the existing Kupferberg system; each sinus cavity is scored on its own rather than as a collective whole. Each of the Kupferberg stages of mucosal oedema, polypoid oedema and frank polyps were expanded to each have grades of mild, moderate or severe. This permitted nine stages of inflammatory changes to be assigned to each cavity. Additional consideration was then given to the presence of 'allergic' or reactive fungal mucin leading to a possible total score of 10 points for each cavity, 40 points for each side of the nose and 80 points for the total maximum bilateral score (figure 1). patients can be ranked as mild (1 - 20), moderate (21 - 40), severe (41 - 60) or extreme (61 - 80) based on the combined bilateral endoscopic staging, which may allow a useful context for planning future treatment [7].

The aim of work is to assess the presentation of allergic fungal rhinosinusitis in sinonasal polyposis.

PATIENTS AND METHODS

The present study was conducted on thirty six patients with sinonasal polyposis. All patients were diagnosed in the outpatient clinic of otorhinolaryngology department in Zagazig University Hospitals in the period from March 2018 to November 2018.

Written informed consent was obtained from all participants and the study was approved by the research ethical committee of Faculty of Medicine, Zagazig University. The work has been carried out in accordance with The Code of Ethics of the World Medical

Association (Declaration of Helsinki) for studies involving humans.

Table (1): Inclusion and exclusion criteria

Methods:

These patients were subjected to history taking including personal history, nasal symptoms, present and past history, general examination, nasal examination including anterior rhinoscopy, nasal decongestion and nasal endoscopy.

Investigations including diagnostic nasal endoscopy and Assessment of total serum immunoglobulin E (IgE) level were done.

Pre surgery treatment consisted of a topical steroid (2 puffs each side twice daily for at least 2 weeks) and short intermittent doses of oral steroids (40 mg prednisolone once daily for one week then tapered to 20 mg per day for one more week), antihistaminic and antibiotic if there is infection.

Patients have undergone functional endoscopic sinus surgery. The procedure was done under general anesthesia.

The surgical procedure of functional endoscopic sinus surgery was tailored to each patient according to the different sinus involvement revealed in the C.T scan.

The removed nasal polyps were sent for histopathological examination and fungal staining. Fungal elements are recognized for their unique ability to absorb silver. This property is the basis for various silver stains, such as Grocott's or Gomori's Metamine silver (GMS) stain. Figure (1).

Follow up after surgery:

- Endoscopic evaluation after 2,4&6 months Figure (2).

Statistical analysis:

Data were entered checked and analyzed using Epi-Info version 6 and SPP for Windows version 8.

RESULTS

Thirty six patients with sinonasal polyposis resistant to medical treatment for a period not less than six weeks were included in this study. The study work was done in Otorhinolaryngology Department in Zagazig University Hospitals over a duration from March 2018 to November 2018. Patient age

ranged from 12 to 65 years with a mean of 38.5 ± 10.6 . They were 9 males and 27 females.

Out of thirty six patients only five showed positive fungal stain. All the five cases diagnosed to have fungal sinus disease were female patients. Age varied from 12–65 years. four out of five cases were belonged to rural areas.

All the patients with positive fungal stain presented with headache and post nasal discharge while 80% of them presented with nasal obstruction and 60% of them presented with hyposmia. **Table (2)**

Preoperative nasal endoscopy revealed that 80% of the patients with positive fungal stain presented with polyps extending beyond the middle turbinate and mucopurulent thick discharge .while 20% of them showing polypi confined to the middle turbinate with clear thin discharge. **Table (3)**

Preoperative CT scan revealed that all the patients with positive fungal stain showed total opacification of the maxillary, anterior ethmoid, posterior ethmoid and sphenoid sinuses with obstructed osteomeatal complex. Assessment of total IgE is done in all the thirty six patients. IgE levels in the five patients diagnosed with AFS ranged between

572.10-623-10 IU/ml while those in patients with polyposis only ranged between 191.20-381 IU/ml. **Table (4).**

Histopathological examination(HPE) of the polyps and polypoidal mucosa was done in all thirty six patients. HPE of the biopsy material with special (Lactophenol cotton blue) stain was positive for pathogenic fungi in 5 patients.

Fungal Culture in all the five patients diagnosed with AFRS is positive revealing *Aspergillus fumigatus* in four patients and *Candida* in one patient.

Aspergillus positive patients were given itraconazole 200 mg single dose daily for one month. Postoperatively the patient with candidiasis was given local amphotericin-B (50 mg diluted in 20 ml of normal saline as nasal drops) for three months. Hepatic and renal functions were monitored in these patients.

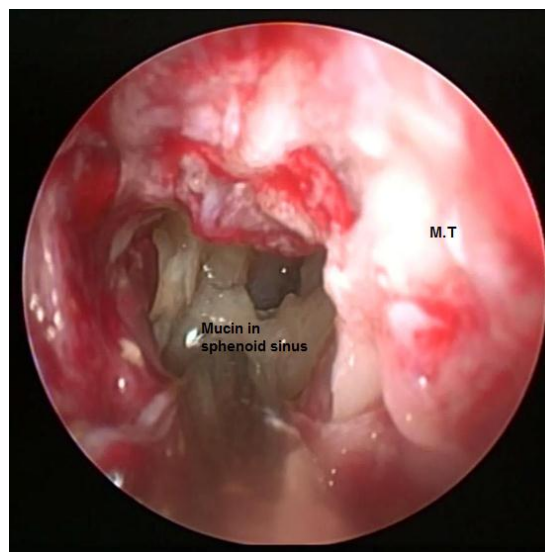
Postoperative follow up of patients with allergic fungal sinusitis according to Philpott-Javer staging system showed that 3 out of 5 patients diagnosed as allergic fungal sinusitis are ranked as mild while the remaining two ranked as moderate based on the combined bilateral endoscopic staging. (**Table 5**).

Table (1): Inclusion and exclusion criteria

| Inclusion Criteria | Exclusion Criteria |
|--|---|
| <ul style="list-style-type: none"> All patients proved to have intractable sinonasal polyposis for more than three months duration not responding to medical treatment in whom CT scan could be done and in need of Endoscopic Sinus Surgery Patients fit for surgery. | <ul style="list-style-type: none"> Patients with chronic sinusitis who responded to medical treatment. Patients who were not willing to undergo ESS. Patients with osteomyelitis and infiltrating tumors. Immunocompromised Patients Patients who are not fit for surgery. |

Table (2): Comparison between patients with and without fungal sinusitis according to presenting symptoms

| | Fungal stain | | X ² | P | Sig |
|-----------------------------|--------------|----------|----------------|--------|-----|
| | Negative | Positive | | | |
| | N (%) | N (%) | | | |
| Nasal obstruction: | | | | | |
| Yes | 30 (96.8) | 4 (80) | Fisher | <0.001 | HS |
| No | 1 (3.2) | 1 (20) | | | |
| Facial pain: | | | | | |
| No | 7 (22.6) | 0 (0) | Fisher | 0.559 | NS |
| Yes | 24 (77.4) | 5 (100) | | | |
| Rhinorrhea: | | | | | |
| No | 13 (41.9) | 1 (20) | Fisher | 0.628 | NS |
| Yes | 18 (58.1) | 4 (80) | | | |
| Hyposomia: | | | | | |
| No | 8 (25.8) | 2 (40) | Fisher | 0.603 | NS |
| Yes | 23 (74.2) | 3 (60) | | | |
| Postnasal discharge: | | | | | |
| No | 9 (29) | 0 (0) | Fisher | 0.302 | NS |
| Yes | 22 (71) | 5 (100) | | | |

**Figure (1):** Endoscopic view of thick tenacious allergic mucin in the right side of the nasal cavity .
M.T:Middle Turbinate

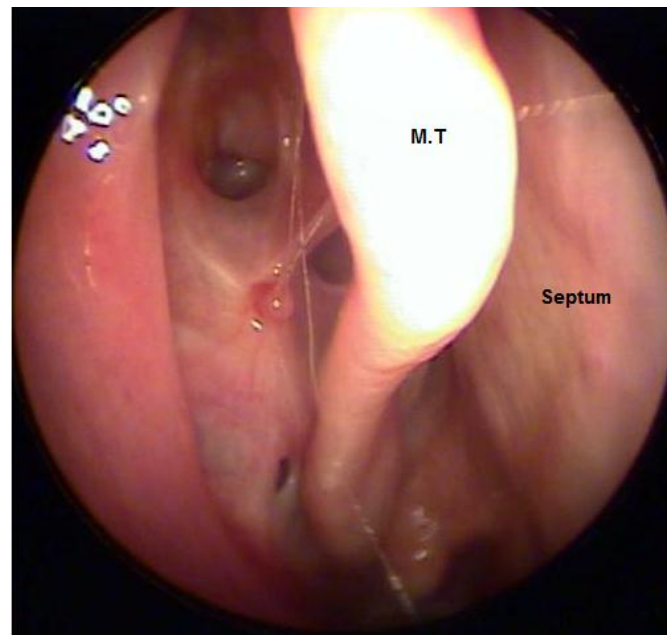


Figure (2): Endoscopic view of the right nasal cavity in a case of allergic fungal sinusitis 6 months postoperatively.

DISCUSSION

AFRS is a truly demarcated by the presence of allergic fungal mucin, which is a thick, tenacious and eosinophilic secretion with characteristic histologic findings [1].

The fungi causing AFRS have a great diversity. This variability in incidence may be due to different techniques in diagnosis and differences in geographical distribution.

Bakhshae et al. [8] found that 105 patients were non-asthmatic whereas 22 patients (20.95%) had a positive history for asthma. Only two patients with AFS had an associated asthma. The high incidence of associated asthma could be related to the combination of AFS and non-fungal eosinophilic mucin rhinosinusitis.

Ferguson et al. [9] stated that there is no significant association between asthma and nasal polyps.

Also, Telmesani [10] found that and asthma is not significantly associated with nasal polyps.

In **this** study, 88.9% of the studied patients had irrelevant history of asthma **and** 72.2% of the studied patients had allergy.

Ferguson et al. [9] noted that a geographical variability may be present in the incidence of AFS and fungal species associated with the

disease process. Dematiaceous fungi are most common in the United States whereas *Aspergillus* species are mostly reported in the Middle East.

Most American cases of AFRS occur within the southern and south eastern geographic regions, where the climate is warm and damp and mold counts are high. Some studies on the health effects associated with self-reported exposure to indoor humidity or mold have found an increase in sinusitis. The growth of fungi on buildings **was** mainly affected by moisture, nutrients, and temperature [11].

Chakrabati et al. [12] found in their study that the majority of AFRS patients were reported in young villagers of North India.

In **the** current study 80% of the patients diagnosed with allergic fungal sinusitis were from **the** rural areas.

Telmesani [10] reported a 12% prevalence of AFS among sinonasal polyposis in Saudi Arabia in which *Aspergillo*sis was found in 72% of the cases while the remaining cases had a negative culture.

. Bakhshae et al. [8] assessed the prevalence of AFS among rhinosinusitis patients in the North East of Iran in a prospective cross-sectional study, 127 patients with sinonasal polyposis were applicants for

surgery. Twelve (9.45%) met the AFS criteria while the remaining 115 patients showed histopathological features of chronic hyperplastic rhinosinusitis.

Goh et al. [13] reported that in adult patients with refractory rhinosinusitis, the incidence of AFS was 26.7%. The presence of allergic mucin was the diagnostic tool for AFS, by which they found fungi in the secretions of only 5 patients (16.7%) and in nasal secretions and surgical specimens of 11 (36.7%) patients.

Ferguson et al. [9] stated that the prevalence of AFS among patients with nasal polyps is 9.45%. In our study, 13.9% of the studied patients had positive fungal stain. In 4 out of 5 cases *Aspergillus Fumigates* was demonstrated in fungal cultures while *Candida Albicans* was detected in the fungal culture of one case.

AFRS is mediated by IgE in response to different fungi present in the sinonasal eosinophilic mucin. The theory is supported by the observation of specific IgE in cultures. Currently, the most widely accepted hypothesis excludes the allergic etiology and proposes the term "eosinophilic fungal sinusitis" [5].

Still, total IgE maybe of value in differentiating between eosinophilic mucin rhinosinusitis and AFS, where it is elevated in AFS cases [14]. Total IgE values are generally raised in AFS, often to more than 1000 U/mL (normal value = <100 IU/mL) [15].

Ferguson et al. [9] indicated that the IgE level in patients with AFS is higher than those with chronic hyperplastic rhinosinusitis.

Kuhn and Javer studied whether specific IgE to fungal species was superior to total IgE in expecting persistence or recurrence. They found that total IgE was generally most sensitive [16].

Telmesani [10] found that IgE level was higher in patients with AFS than those with chronic hyperplastic rhinosinusitis. Total IgE in patients diagnosed with AFS is frequently high with a mean of 668 IU/ml and the normal concentration being less than 125 IU/ml [9]. Bakhshae et al. [8] stated that the total IgE level was significantly higher in AFS patients as the total IgE level among patients with polyposis alone was 207.45,

while the same value was 520.14 in AFS cases. This difference was statistically significant.

In our study, IgE levels in AFS patients ranged between 572.10 – 623.10 IU/ml while those in patients with polyposis only ranged between 191.20 – 381 IU/ml.

It is our practice that after the endoscopic sinus surgery the *Aspergillus* positive patients were given itraconazole 200 mg once daily for one month. While the patient with candidiasis was given local amphotericin-B (50 mg diluted in 20 ml of normal saline as nasal drops) for three months. Hepatic and renal functions were monitored in these patients regularly. 3 out of the 5 patients diagnosed as allergic fungal sinusitis are ranked as mild while the remaining two are ranked as moderate based on Philpott-Javer Endoscopic staging system [7].

CONCLUSION

Proper diagnosis of AFRS is essential for planning treatment and follow up. The Bent and Kuhn criteria is generally the most widely accepted diagnostic criteria in use today. A confirmatory diagnosis is made from characteristics of the fungal mucin, the histological findings and CT scan findings. *Aspergillus* and *Candida* infections were observed in immunocompetent patients with more incidence of *Aspergillus* infections. AFRS is found to be more **common** in the rural than urban areas. Mainstay of treatment is surgical debridement using endoscopic sinus surgery. Comprehensive management with steroids and antifungals reduces the recurrence rate **with an emerging role for immunotherapy**.

Declaration of interest

The authors report no conflicts of interest. The authors alone are responsible for the content and writing of the paper.

Funding information None declared

REFERENCES

- 1- Glass D and AMedee RG (2011): Allergic fungal rhinosinusitis: A review. *Ochsner J*; 11(3): 271-275.
- 2- Bent JP 3rd and Kuhn FA (1994): Diagnosis of allergic fungal sinusitis. *Otolaryngol Head Neck Surg*; 111(5): 580-588.

- 3- **Libowitz, R.; Waltzman, M. , Jacob, J. , Pearlman, A. and Tierno, PM. (2002):** Isolation of fungi by standard laboratory methods in patients with chronic rhinosinusitis, *Laryngoscope*; 112: 2189-2191.
- 4- **Fokkens WJ, van Drunen C, Georgalas C and Ebbens F (2012):** Role of fungi in pathogenesis of chronic rhinosinusitis: The hypothesis rejected. *Curr Opin Otolaryngol Head Neck Surg*; 20(1): 19-23.
- 5- **Stammerger H (1999):** Examination and endoscopy of the nose and paranasal sinuses. In: Mygind N, Lildholt T (eds). *Nasal polyposis: An inflammatory disease and its treatment.* Munksgaard, Copenhagen; 120-36.
- 6- **Manning SC and Holman M (1998):** Further evidence for allergic pathophysiology in allergic fungal sinusitis. *Laryngoscope*; 108(10): 1485-1496.
- 7- **Carl, P.; Allan, C. and Amin, J. (2011):** Allergic fungal rhinosinusitis-a new staging system, *Rhinology* 49: 318-323.
- 8- **Backshae, M.; Fereidouni, M. , Mohajer, MN. , Majidi , MR. , Azad , FJ. , Moghiman , T. (2013):** The prevalence of allergic fungal rhinosinusitis in sinonasal polyposis. *Eur Arch Otorhinolaryngol*; 270: 3095-3098.
- 9- **Ferguson, B. (2000):** Definitions of fungal rhinosinusitis, *Otolaryngol. Clin. of North Am.*; 33(2): 227-235.
- 10- **Telmesani LM (2009):** Prevalence of allergic fungal sinusitis among patients with nasal polyps. *Ann Saudi Med*; 29(3): 212-214.
- 11- **Rajasekar, A. and Balasubramanian, R.(2011):** Assessment of airborne bacteria and fungi in food courts. *Building and Environment.* ;46(10):2081–2087.
- 12- **Chakrabarti A, Sharma SC (2000):** Paranasal sinus mycoses. *Indian J Chest Dis Allied Sci* 42: 293–304.
- 13- **Goh BS, Gendeh BS, Rose IM, Pit S, Samad SA (2005):** Prevalence of allergic fungal sinusitis in refractory chronic rhinosinusitis in adult Malaysians. *Otolaryngol Head Neck Surg* 133(1): 27-31.
- 14- **Ryan, MW. and Marple, BF. (2007):** Allergic fungal rhinosinusitis: Diagnosis and management. *Curr Opin Otolaryngol Head Neck Surg*; 15(1): 18-22.
- 15- **Ahn, CN.; Wise, SK. , Lathers, DM. , Mulligan , RM. , Harvey , RJ. , Schlosser , RJ. (2009):** *Otolaryngol Head Neck Surg.* 2009 Jul;141(1):97-103.
- 16- **Kuhn, FA. and Javer, A. (1999):** Utilizing fungal specific IgE levels as a serological marker for allergic fungal sinusitis activity. *Am Rhinologic Soc Spring Meet.*

To Cite This Article: El BahrawyAT, Abd El Fattah MM, Nasr WF, Beshara PBS. Presentation of Allergic Fungal Rhinosinusitis in Sinonasal polyposis. *Zumj* 2020; 27(2)255-261: doi :10.21608/zumj.2019.11491.1191.