

# Can Three-Dimensional Power Doppler Detect Placental Involvement in pregnant women with COVID-19? An observational study

Original  
Article

Nihal M. El-Demiry<sup>a</sup>, Sherif Elsirgany<sup>b</sup>, Manal Moussa<sup>a</sup>, Amr H. Wahba<sup>a</sup>

Department of <sup>a</sup>Obstetrics and Gynecology, Faculty of Medicine, Cairo University,  
<sup>b</sup>Reproductive Health Research Department, National Research Centre, Cairo, Egypt.

## ABSTRACT

**Objective:** Placental involvement in pregnant women with covid-19 has been proved by postnatal histopathological examination in many studies even in absence of fetal infection. Whether this placental involvement can be detected prenatally using ultrasonography has not been investigated.

**Materials and Methods:** This is a cross-sectional study including 40 women attending for second trimester scan divided into two groups; Group A (pregnant women with mild Covid-19 infection requiring home isolation), Group B (control group). Three-dimensional (3-D) power Doppler ultrasonography of the placenta using VOCAL technique, calculating the placental volume and placental vascular indices including Flow Index (FI), VI (Vascularity index), VFI (Vascularity flow index). The Pulsatility index (PI) of the uterine artery was also measured.

**Results:** Baseline characteristics were similar between both groups. Placental volume was significantly higher in Covid group than control group. Mean FI was significantly less while VI and VFI were higher in Covid group compared to control group. Uterine artery doppler did not show any differences between both groups.

**Conclusion:** Mild Covid-19 infection can have an impact on placental volume and placental vascularity and perfusion observed by three-dimensional ultrasonography. In mild cases, whether these changes are transient or permanent, and whether it can have an impact on pregnancy outcomes need to be investigated in future research.

**Key Words:** COVID-19, placental hypoperfusion, placental vascular indices, placental volume, three-dimensional ultrasound.

**Received:** 11 November 2022, **Accepted:** 19 November 2022

**Corresponding Author:** Nihal M. El-Demiry, MD, Department of Obstetrics & Gynecology, Faculty of Medicine, Cairo University, Cairo, Egypt. **Tel.:** 01006049052, **E-mail:** n.eldemiry@gmail.com

**ISSN:** 2090-7265, February 2024, Vol.14, No. 1

## INTRODUCTION

COVID-19 pandemic has a major global health concern. Owing a specific nature; pregnancy and pregnant women need special awareness for evaluation of possible effects and complications of Covid-19 infection during pregnancy. Even though the main population of pregnant covid infected patients are asymptomatic and most of symptomatic patients have mild symptoms. Symptomatic patients are more prone to have pregnancy complications as preterm birth with its neonatal morbidity and mortality, small for gestational-age (SGA) babies, and stillbirth<sup>[1]</sup>.

One of the major contributors of pregnancy is placental development including placental volume and vascularity. Most of the placenta-related complications such as fetal growth restriction (FGR) and pre-eclampsia (PE) originate during the first trimester, so proper evaluation of the placenta could help to predict adverse pregnancy outcome, by detection of placental insufficiency<sup>[2,3]</sup>.

Placental function can be evaluated using ultrasound (e.g., placental volume and vascularity) and/or by

measurement of placental hormones in maternal circulation<sup>[3]</sup>.

Advances in ultrasound imaging using 3D ultrasound and Doppler technology have enabled us of evaluating placental volume using VOCAL technique (Virtual Organ Computer-aided Analysis) and vascularity parameters e.g., Vascularization index (VI), the flow index (FI) and the vascularization flow index (VFI).

Plasencia *et al.*, 2011 claimed that improvement of the prediction rate of the birth of SGA or large for gestational age (LGA) neonates can be done by measurement of placental volume and serum PAPP-A<sup>[4]</sup>. Churchill *et al.*, 2017 found that placental volume is not affected by mode of pregnancy either spontaneous or induced as infertility patients<sup>[5]</sup>. Additionally, uterine artery parameters e.g., Pulsatility index measurement, can contribute to prediction of adverse outcomes when evaluated in pregnant women recovered from COVID-19<sup>[6]</sup>.

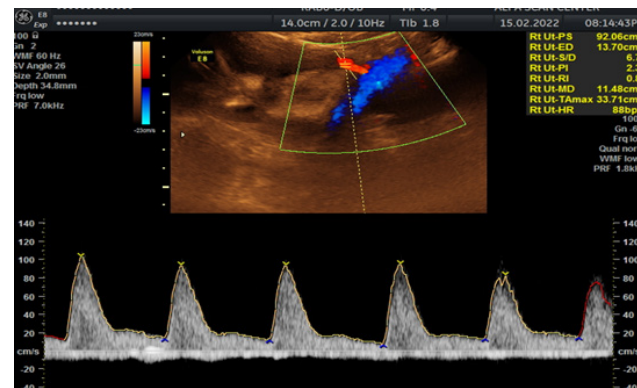
The aim of this study is to evaluate the impact of infection with Covid-19 on placental volume and placental perfusion in pregnant women with mild symptoms.

## PATIENTS AND METHODS

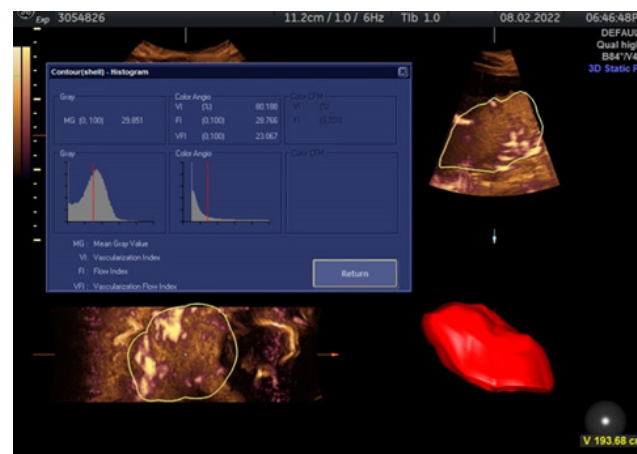
A consent was obtained from all the women after full explanation of the objectives of the study. Forty pregnant women included in this prospective cross-sectional study (pilot study) between June 2021 till June 2022. They came for second trimester anomaly scan in a private medical center in Cairo, Egypt. Pregnant women were divided into two groups; Group A, include women who had COVID 19 during the current pregnancy and only required home isolation. Group B included women who didn't have COVID-19 during current pregnancy (Control group). The ultrasound machine used was Voluson E8, with the use of Rab 6 convex probe 3.5 MHZ. Each fetus was examined for fetal anomaly scan second trimester by well-trained personnel specialized to do fetal anomaly scan. Ultrasound scans was performed by one operator (S. E.). We included women who have singleton pregnancy, 18-24 weeks of gestation, with known last menstrual period and who underwent a first trimester anomaly scan with history of regular menstruation. We excluded women with multiple pregnancy, medical disorders (e.g., diabetes, hypertension, anemia), uncertain dates (due to unknown last menstrual period or irregular period), fetal anomalies or anemia or hydrops, large or small fetuses. We also excluded cases with placenta previa, placental anomalies and those with poor visualization of the placenta. Uterine artery Doppler was measured abdominally (Transabdominal technique): where placed longitudinally in the lower lateral quadrant of the abdomen, angled medially in the parasagittal plane. Colour mapping is used to identify the uterine artery after crossing the external iliac artery. The sample volume is placed 1cm downstream from this crossover point and the same done on the other side (Figure 1).

The placenta was identified by 2D-ultrasound, the volume box was adjusted to scan the entire placenta. Then we selected Power Doppler and selected 3D. The angle of volume acquisition varied from 45° to 90°, and the duration of image acquisition lasted was 10 to 15 seconds and we selected trace maneuver rather than automated nor sphere. Four parameters were automatically calculated by the VOCAL software: (Figure 2).

- 1) Vascularization index (VI), i.e., which describes the overall perfusion.
- 2) Vascularization flow index (VFI), i.e., which assesses blood velocity in the same sample volume.
- 3) Flow index (FI), i.e., which evaluates the overall blood flow in the sample volume.
- 4) Placental Volume.



**Fig. 1:** shows the uterine artery where it crosses the external iliac artery and the sample gate placed 1 cm after crossing.



**Fig. 2:** shows a placenta with 3D power Doppler using A VOCAL software to evaluate placenta vascularity (FI, VI and VFI) and placental volume.

## Statistical analysis

Statistical analysis was performed using SPSS (Statistical package for the social sciences- IBM® SPSS® Statistics Version 20 for Windows, IBM Corp., Armonk, NY, USA). Data was represented as mean  $\pm$  standard deviation. Data was explored for normality using Kolmogorov-Smirnov and Shapiro-Wilk tests. For normally distributed data Student's t-test was used to compare variables between the two groups, while for non-normally distributed data Mann-Whitney U test was used. The results were considered statistically significant if the p value was less than 0.05.

## RESULTS

During the time period of the study, we approached 20 patients who had COVID-19 during the current pregnancy and only needed home isolation (Group A, study group) and 27 patients with no history of COVID infection (Group B, control group). We excluded 7 patients from the control group (2 had cardiac anomalies, 3 cases had placenta previa, 1 gestational DM and 1 overt diabetes).

The mean age was the same across both groups being 30.0+/-4.31 years in group A and was 30.8+/-4.53 years in group B ( $p=0.57$ ). Similarly, the gestational age at the time of the examination showed no statistically significant difference between both groups; group A 21.9+/-1.60 weeks and group B 22.1+/-1.57 weeks ( $p=0.69$ ). The mean

time of diagnosis of COVID 19 before the scan was 4.35+/-3.87 weeks and only 3 patients (15%) needed antibiotic therapy. Only one patient (5%) had a complication from the infection but was not admitted to a hospital. Demographic data are represented in (Table 1).

**Table 1:** Demographic data of our study and control groups

	Group A	Group B	<i>P value</i>
Age (mean and SD) yrs	30.0 +/- 4.31	30.8 +/- 4.53	0.57
GA (mean and SD) weeks	21.9 +/- 1.60	22.1 +/- 1.57	0.69
Number of weeks post Covid	4.35 +/- 3.87	-	-
Need for Antibiotics (no, %)	3 (15%)	-	-
Complications (no, %)	1 (5%)	-	-

As regards the VOCAL indices Group A, that included women who had COVID 19 showed a statistically significant increase in the placental volume 255.5+/-81.1 cc vs 155.1+/-46.3 cc ( $p=0.01$ ), mean VI 75.1+/-15.3 vs 40.1+/-13.4 ( $p=0.001$ ) and mean VFI 20.2+/-5.57 vs 15.0+/-3.27 ( $p=0.01$ ) as compared to Group B that included women who didn't have COVID-19 during

current pregnancy (Control group). However, the mean FI was statistically significant decreased in Group A, that included women with COVID 19 (26.9+/-6.32 vs 32.5+/-6.94 ( $p=0.01$ )). The Pulsatility index (PI) of the uterine artery did not show any significant difference between group A and Group B (PI 0.91+/-0.24 vs 0.85+/-0.29 ( $p=0.21$ )) (Table 2).

**Table 2:** Placental volume and vascular indices in both groups.

	Group A	Group B	<i>P value</i>
Placental volume (cc)	255.5 +/- 81.1	155.1 +/- 46.3 cc	$p=0.01$
Mean VI	75.1 +/- 15.3	40.1 +/- 13.4	$p=0.001$
Mean VFI	20.2 +/- 5.57	15.0 +/- 3.27	$p=0.01$
Mean FI	26.9 +/- 6.32	32.5 +/- 6.94	$p=0.01$
Mean uterine artery PI	0.91 +/- 0.24	0.85 +/- 0.29	$p=0.21$

## DISCUSSION

The effect of COVID-19 (SARS-CoV-2 virus) on pregnancy remains unclear. Covid-19 infection during pregnancy was found to increase risk for preterm birth as well as other adverse pregnancy complications such as pre-eclampsia, coagulopathy, and stillbirth, compared with those without COVID-19 infection<sup>[6,7,8,9]</sup>.

COVID-19 is considered a systematic disease that can affect many organs from different systems, including the placenta<sup>[10]</sup>. Few cases noted vertical transmission of SARS-CoV-2, but the recent data showed that vertical transmission is not to be common<sup>[11]</sup>. Placental involvement can occur in absence of fetal infection. The pathological changes and damage to the placenta is unlikely to be attributed to the direct effect of the virus but rather caused by the systemic effect of the virus<sup>[12,13,14]</sup>. In a study by Sherwani *et al.*, the affected placentas did not show gene expression of SARS-CoV-2 when confirmed by RT-PCR<sup>[15]</sup>.

Three-dimensional (3-D) ultrasound has enabled us to antenatal scanning with the use of VOCAL technique to assess the placental volume and the measurement of the placental vascular indices which can provide an insight into the placental vascularization.

Our results showed that the placental volume was significantly increased in infected women than in matched controls within same gestational age. This may reflect early phase of placental inflammation with villous edema and other pathological changes.

Increasing evidence suggests that COVID-19 infection leaves tell-tale signs of placental injuries (10). Histopathological examination of the placenta in infected women showed fetal vascular malperfusion, arteriopathy, inflammation, perivillous fibrin deposition<sup>[10,16]</sup>. In Covid-19 cases with stillbirth, examination of the placenta showed massive perivillous fibrin deposition, chronic histiocytic intervillitis and trophoblast necrosis. These three pathological findings, collectively defined as SARS-

CoV-2 placentitis. This result in destruction of the placenta parenchyma resulting in malperfusion and placental insufficiency<sup>[17]</sup>.

Sotiriou *et al.*, 2022 studied the morphological changes in the placenta in pregnant women infected with Covid-19 using two-dimensional ultrasound. They observed findings that may indicate malperfusion, chorangiosis, deciduitis and subchorionitis. The most prominent findings noted were the presence of the placenta lakes, fibrin deposits and subchorionic edema of at least 30% of the placental mass. These findings were observed in 85% of women who required hospital admission (severe cases), compared to 25% of women who remained at home<sup>[18]</sup>. The authors suggested that these findings can be used as a diagnostic tool for possible fetal vascular mal-perfusion, however, they did not correlate their findings with the pregnancy outcomes of the studied group of cases.

In the present study the placental vascular indices (VI and VFI which reflect the overall perfusion and blood velocity respectively in the same sample volume) were significantly increased in infected pregnant women compared to those without infection. While, FI (which measure the all blood flow within the sample volume) was less in infected women than in matched controls within same gestational age. The decrease in FI reflects decrease in placental flow compared to control which may result from the immunological and inflammatory response induced by the virus.

In case of evaluation of the maternal-fetal circulation, it may be that FI is more useful<sup>[19]</sup>.

There have been studies to evaluate the role of the placental vascular indices in prediction of SGA and pre-eclampsia. A study by Eastwood *et al.*, 2018 found that placental vascular indices in first and second trimester can predict pre-eclampsia where FI was found to be less in these patients than control<sup>[20]</sup>. Also, researches related to SGA/FGR pregnancies have shown a decrease in placental vascular indices after the second trimester<sup>[21]</sup>.

Histological examination of large number of placentas of infected pregnant women with Covid-19 showed picture suggesting of placental hypoperfusion and inflammation<sup>[22]</sup>.

In cases with severe Covid-19 infection, placental hypoperfusion can result from the compromised hemodynamic status of the mother. Another alternative hypothesis for placental hypoperfusion is that, the viral infection induce release of proinflammatory mediators in an event known as (Cytokine storm), with excessive inflammatory reaction leading to placental damage with histopathological abnormalities related to inflammation. The down-regulation of the renin-angiotensin system (RAS) which occurs secondary to binding of the virus to the

angiotensin-converting enzyme 2 (ACE 2) receptor may facilitate the release of cytokine storm. RAS has a crucial role to maintain the uteroplacental blood flow through regulation between vasodilator and vasoconstrictive pathways. Decrease the levels of angiotensin 1 and 7 vasoconstrictions and impairment of uteroplacental blood flow occurs due to Down-regulation of RAS<sup>[23]</sup>. The latter could provide an explanation to the reduced FI in infected women in our study.

In the present study The Pulsatility index (PI) of the uterine artery did not show any significant difference between group A and Group B.

In current practice, measurement of uterine artery Doppler during 11-13 weeks and 18-24 weeks of pregnancy can help for prediction of later pregnancy complications such as preeclampsia and IUGR. During third trimester uterine artery Doppler measurement may have role in pregnant women recovered from COVID-19<sup>[6]</sup>. Khalil *et al.* underwent a comparison between the incidence rates of stillbirth during the pandemic and pre-pandemic period and claimed that the incidence of stillbirth was significantly higher during the pandemic<sup>[24]</sup>.

To the best of our knowledge, this is the first study in the literature to evaluate the impact of mild Covid-19 infection on the placental volume and placental vascular indices. Our study is limited by the small sample size and the lack of the follow up of cases. This is required to evaluate whether the changes are transient and to correlate the findings with the pregnancy outcomes. However, our aim was to initially report whether there are differences in volume and vascularity between infected cases and non-infected cases. All the cases were done by single operator to avoid the intra-observer variability; however, previous researches have noted that FI, which represents blood flow intensity, is the most reliable vascular index due to lower intra-placental variability and higher intra- and inter-observer correlations<sup>[21,25]</sup>.

Our findings might encourage further research to evaluate the role of the measurement of placental volume and placental vascular indices in cases with covid-19 infection. The ability to detect early signs of placental involvement may facilitate the identification of pregnancies at increased risk of adverse outcomes.

---

## CONCLUSION

The current study showed that even mild infection with Covid-19 infection can have an impact on placental volume and placental vascularity and perfusion. In mild cases, whether these changes are transient or permanent, and whether it can have an impact on pregnancy outcomes need to be investigated in future research.



## CONFLICT OF INTEREST

There are no conflicts of interests.

## REFERENCES

1. RCOG, Coronavirus (COVID-19) Infection in Pregnancy version 15, 7 March 2022
2. Kroener L, Wang ET, Pisarska MD. Predisposing Factors to Abnormal First Trimester Placentation and the Impact on Fetal Outcomes. *Semin Reprod Med.* 2016 Jan;34(1):27-35.
3. Higgins LE, Myers JE, Sibley CP, Johnstone ED, Heazell AEP. Antenatal placental assessment in the prediction of adverse pregnancy outcome after reduced fetal movement. *PLoS One.* 2018 Nov 5;13(11):e0206533.
4. Plasencia W, Akolekar R, Dagklis T, Veduta A, Nicolaides KH. Placental volume at 11-13 weeks' gestation in the prediction of birth weight percentile. *Fetal Diagn Ther.* 2011;30(1):23-8.
5. Churchill SJ, Wang ET, Akhlaghpour M, Goldstein EH, Eschevarria D, Greene N, Macer M, Zore T, Williams J 3rd, Pisarska MD. Mode of conception does not appear to affect placental volume in the first trimester. *Fertil Steril.* 2017 Jun;107(6):1341-1347
6. Anuk AT, Tanacan A, Yetiskin FDY, Buyuk GN, Senel SA, Keskin HL, Moraloglu O, Uygur D. Doppler assessment of the fetus in pregnant women recovered from COVID-19. *J Obstet Gynaecol Res.* 2021 May;47(5):1757-1762. doi: 10.1111/jog.14726. Epub 2021 Mar 1. PMID: 33650296; PMCID: PMC8014281.
7. Villar J, Ariff S, Gunier RB, *et al.* Maternal and Neonatal Morbidity and Mortality Among Pregnant Women With and Without COVID-19 Infection: The INTERCOVID Multinational Cohort Study. *JAMA Pediatr.* 2021;175(8):817-826
8. Jering KS, Claggett BL, Cunningham JW, *et al.* Clinical Characteristics and Outcomes of Hospitalized Women Giving Birth With and Without COVID-19. *JAMA Intern Med.* 2021;181(5):714-717.
9. Conde-Agudelo A, Romero R. SARS-CoV-2 infection during pregnancy and risk of preeclampsia: a systematic review and meta-analysis. *Am J Obstet Gynecol.* 2021.
10. Wong YP, Khong TY, Tan GC. The effects of COVID-19 on placenta and pregnancy: what do we know so far? *Diagnostics (Basel)* 2021;11:94.
11. Dumitriu D, Emeruwa UN, Hanft E, *et al.* Outcomes of Neonates Born to Mothers With Severe Acute Respiratory Syndrome Coronavirus 2 Infection at a Large Medical Center in New York City. *JAMA Pediatr.* 2021;175(2):157-167
12. Shanes ED, Mithal LB, Otero S, Azad HA, Miller ES, Goldstein JA. Placental Pathology in COVID-19. *Am J Clin Pathol.* 2020 Jun 8;154(1):23-32
13. Singh N, Buckley T, Shertz W. Placental Pathology in COVID-19: Case Series in a Community Hospital Setting. *Cureus.* 2021 Jan 6;13(1):e12522.
14. Taglauer E, Benarroch Y, Rop K, Barnett E, Sabharwal V, Yarrington C, Wachman EM. Consistent localization of SARS-CoV-2 spike glycoprotein and ACE2 over TMPRSS2 predominance in placental villi of 15 COVID-19 positive maternal-fetal dyads. *Placenta.* 2020 Oct; 100:69-74.
15. Sherwani N, Singh N, Neral A, Jaiswal J, Nagaria T, Khandwal O. Placental Histopathology in COVID-19-Positive Mothers. *J. Microbiol. Biotechnol.* 2022;32:1098-1102
16. Resta L, Vimercati A, Cazzato G, *et al.* SARS-CoV-2 and placenta: new insights and perspectives. *Viruses.* 2021;13:723
17. Schwartz DA, Mulkey SB, Roberts DJ. SARS-CoV-2 Placentitis, Stillbirth and Maternal COVID-19 Vaccination: Clinical-Pathological Correlations. *Am J Obstet Gynecol.* 2022 Oct 10:S0002-9378(22)00800-6.
18. Sotiriou, S.; Samara, A.A.; Tsiamalou, I.-A.; Donoudis, C.; Seviloglou, E.; Skentou, C.; Garas, A.; Daponte, A. Placental Ultrasonographical Findings during SARS-CoV-2 Infection. *Diagnostics* 2022, 12, 974.
19. Alcázar JL. Three-dimensional power Doppler derived vascular indices: what are we measuring and how are we doing it? *Ultrasound Obstet Gynecol.* 2008 Sep;32(4):485-7.
20. Eastwood KA, Hunter AJ, Patterson CC, Mc Cance DR, Young IS, Holmes VA. Placental vascularization indices and prediction of pre-eclampsia in high-risk women. *Placenta.* 2018 Oct;70:53-59
21. Guiot, C.; Gaglioti, P.; Oberto, M.; Piccoli, E.; Rosato, R.; Todros, T. Is three-dimensional power Doppler ultrasound useful in the assessment of placental perfusion in normal and growth-restricted pregnancies? *Ultrasound Obstet. Gynecol.* 2008, 31, 171-176.

22. Di Girolamo, R.; Khalil, A.; Alameddine, S.; D'Angelo, E.; Galliani, C.; Matarrelli, B.; Buca, D.; Liberati, M.; Rizzo, G.; D'Antonio, F. Placental histopathology after SARS-CoV-2 infection in pregnancy: A systematic review and meta-analysis. *Am. J. Obstet. Gynecol.* 2021, 3, 100468
23. Seymen CM. Being pregnant in the COVID-19 pandemic: effects on the placenta in all aspects. *J Med Virol.* 2021; 93: 2769-2773,
24. Khalil A, von Dadelszen P, Draycott T, Ugwumadu A, O'Brien P, Magee L. Change in the incidence of stillbirth and preterm delivery during the COVID-19 pandemic. *JAMA.* 2020;324(7):705–6. [PMC free article] [PubMed] [Google Scholar] [Ref list]
25. Guimarães Filho, H.A.; Mattar, R.; Araujo Júnior, E.; da Costa, L.L.; de Mello Junior, C.F.; Nardoza, L.M.; Nowak, P.M.; Moron, A.F. Reproducibility of three-dimensional power Doppler placental vascular indices in pregnancies between 26 and 35 weeks. *Arch. Gynecol. Obstet.* 2011, 283, 213–217.