



Official Journal Issued by
Faculty of
Veterinary Medicine

Benha Veterinary Medical Journal

Journal homepage: <https://bvmj.journals.ekb.eg/>



Since 1990

Original Paper

Xylazine, ketamine, and propofol general anesthesia for laparoscopic intervention in goats

Abdelhaleem H. El-Kasapy

Surgery, Anesthesiology and Radiology Department, Faculty of Veterinary Medicine, Benha University.

ARTICLE INFO

Keywords

Goat,
Xyzazine,
Ketamine,
Propofol,
Laparoscopy

Received 24/09/2023

Accepted 04/10/2023

Available On-Line

31/12/2023

ABSTRACT

The use of the laparoscope technique witnessed a great acceleration during the last two decades in human medicine. It began to be used recently in small ruminants after it was used in medicine and surgery for pets. The reliance on the laparoscope technique instead of the classical surgical intervention is due to its advantages of minor ports and rapid healing. The use of goats as a model for training comes from the fact that they are docile and easily tractable, the ease and simplicity in raising, feeding, and living them, their strength to bear pain, and the speed healing of their wounds. Laparoscopy is a useful teaching aid for students and surgeons, facilitating a better understand of anatomy and the development of surgical skills. The use of an anesthetic protocol consists of xylazine Hcl at a dose of 0.05mg/kg bwt, ketamine Hcl at a dose of 3.5 mg/kg bwt and propofol by a dose rate 2.5 mg/kg bwt, fully satisfies the purpose of laparoscopic intervention in goats in terms of duration of anesthesia, the competence of entry into anesthesia as well as the quality of recovery. Therefore, this study aims to explain the best way to total intravenous anesthesia for the goats underwent laparoscope intervention.

1. INTRODUCTION

Due to their ease of use, compliance, and relatively low cost, goats have been used as animal models in various studies, mainly cardiovascular and regeneration, orthopedic, and reproductive studies. Anesthesia is usually important for further research studies with these animals. Using a mixture of premedication and general anesthesia is mentioned to be as multimodal anesthesia (Brown et al., 2018). The idea of multimodal anesthesia is that the mixed drugs may act synergistically to produce anxiolysis, smooth induction, and reduce dosage requirements of anesthetic, thus reducing unfavorable effects of each drug. Laparoscopic surgical techniques are better than traditional surgical approaches for goats (Devitt et al., 2005; Röcken et al., 2011; Daniel et al., 2019). The laparoscopic procedures admit many advantages include less operative trauma and postoperative pain, fast recovery, and excellent visibility of organs and structures in the abdomen (Baldassarre et al., 2007; Hunter et al., 2012).

Many surgical procedures can be performed by using laparoscope which including cholecystectomy, ovariohysterectomy, cryptorchidectomy, gastropexy, abdominal organ biopsy, splenectomy and others (Kassem et al., 2011; Butkovic et al., 2020).

Perfect anesthesia is necessary for successful laparoscopic procedures to produce relaxation, immobilization, and unconsciousness. Many anesthetic protocols were discussed for laparoscopic intervention such as local infiltration along the portal sites with sedation or tranquilization (Shin et al., 2008; Dovenski et al., 2012), lumbosacral epidural

analgesia (Fazili et al., 2015) and a combination of sedative and anesthetic agents which has been broadly used to achieve optimum analgesia, sedation and muscle relaxation particularly during the complex and prolonged surgical intervention that require whole control of movement and pain during surgery (Ragab et al., 2022).

The balanced anesthetic protocol comprises a combination of drugs that produces a general anesthetic effect with minimal adverse effects on cardiopulmonary function (Akter et al., 2020).

A suitable pre-anesthetic drug (xylazine) was a highly selective alpha-2 adrenoceptor agonist with potent analgesic and sedative properties and muscle relaxant effect for painful procedures (Asif et al., 2021)

Ketamine is a dissociative anesthetic agent that has profound analgesia and produces stable hemodynamic effects during anesthesia, which counteracts the depressant effects of other drugs used during anesthesia (Celestine et al., 2014).

Propofol is a phenolic compound unrelated to general anesthetic, non-barbiturates, non-dissociative, and noncumulative intravenous anesthetic agents (Prassinis et al., 2005; Celestine et al., 2014).

Propofol has good quality anesthesia, has short duration of action with rapid recovery, may be used alone or in combination with other drugs, and has a wide safety range (Steffey et al., 2009).

The study aimed to explain the best way to total intravenous anesthesia for the goats underwent laparoscope intervention.

2. MATERIAL AND METHODS

The study was conducted after receiving the approval from the institutional animal ethics committee, Faculty of Veterinary Medicine, Benha University (BUVFTM 43-06-23).

Animals:

Eighteen Egyptian goats aged from 3-4 years weighting 10-15 kg were used for laparoscopic ovariectomy and ovariohysterectomy training skills. The animals were admitted to the training center of the society 3 day before the operation. Physical examination was performed and food but not water was withheld for nearly 24 hours before induction of anesthesia.

Anesthetic protocol:

The goats were sedated with an intramuscular injection of xylazine HCl (Xylaject®, Adwia, Egypt) at a dose of 0.05mg/kg b.wt. After 5 minutes an intramuscular injection of Ketamine HCl (ketamax-50®, Troikaa pharmaceuticals Ltd, India) at a dose of 3.5 mg/kg b.wt. Ten minutes after beginning of the protocol, 20 gauge, and 2.5 cm cannula was placed in each goat in the jugular vein. Propofol (Diprivan® 1%, Fresenius Kabi USA) was administrated intravenously by a dose rate 2.5 mg/kg b.wt.

The calculated dose of propofol was diluted three times by normal saline. The total solution of diluted propofol was given through intravenous catheter by divided manner of 1 ml every 5 minutes to maintain anesthesia for a period of 50 minutes.

Assessment of anesthesia:

- 1- Clinical evaluation through numeric scoring system to estimate several reflexes table (1) and 5-point sedation scale table (2) (Ragab et al., 2022).

Table 1: Numeric scoring system applied to estimate several reflexes

Clinical parameters	Scores			
	0	1	2	3
Jaw relaxation	Not permitting jaw opening	The animal resists opening and closes its jaw rapidly	The animal has less resistance to opening its jaw and wraps it slowly	There is no resistance and the jaw still opens
Palpebral reflex	Rapid plink	Intact but weak (slow response)	Intact but very light (slow and occasionally response)	Abolished
Pedal reflex	Potent withdrawal	Intact but weak (slow response)	Intact but very light (slow and occasionally response)	Abolished completely

Table 2: Five-point sedation scale

Score	Description
1	No sedation (goat appears unchanged from initial attitude)
2	Low head carriage (droopy eyelid) and decreased reaction to external stimuli
3	Head lowers toward the ground and swaying of hind legs
4	Attempts to lie down but aroused with stimulation
5	Recumbency and unresponsive to external stimuli

- 2- Induction and recovery quality were judged according to (Abouelfetouh et al., 2022) and classified into good, fair and poor

- 3- Physiological parameters: The heart rate, respiratory rate and rectal temperature were assessed by vet vision monitor (Eckymeir, Germany) and statistically analyzed.

Surgical procedures:

Once the anesthesia was induced, the goat was Trendelenburg positioned (surgical position most often used during lower abdominal surgeries where the animal lies flat on their back, on the operating table with their hind legs raise higher than head) with 20-degree (special cradle was designed to facilitate the approach of this position) (Fig.1).

The ventral surface of the abdomen was prepared for aseptic surgical interference and the goats were draped.

Three portals were performed by scalpel 1.0-1.5 cm skin incision for each. The first portal was located at the trans-umbilical region with 10 mm diameter; this portal was used for insufflation of CO₂ to produce pneumoperitoneum with rate 12 L / min until maximum pressure of 10 mmHg was achieved. Through this portal inspection of the abdominal cavity was performed by a camera and light source (Karl Storz, Tuttlingen, Germany) (Kassem et al., 2011).

The other two instrument portals were performed 7-10 cm caudal to the first incision in the right and left para-inguinal regions with 5 mm diameter (Fig.2).

After completion the inspection, observation, surgical intervention (ovariectomy and ovariohysterectomy) and removal of the intrabdominal instrument the three portal were sutured by 2/0 Vicryl through simple interrupted pattern.

The animals received 50 mg /kg b. wt cefotaxime sodium (cefotax®, EPICO, Egypt) intramuscular per day and flunixin meglumine (Finadyne®, MSD Animal Health, Walton, United Kingdom, 2 mg/ kg I. v.) and daily dressing for 5 day.

3. RESULTS

The results of our study showed that, pre laparoscopic fasting for 24 hours was highly beneficial to decrease the size of the rumen and gastrointestinal tract and reducing the regurgitation of food.

Food fasting beside pneumoperitoneal insufflation with CO₂ increased the abdominal cavity and facilitates the exposure and the inspection of the abdominal viscera and /or organs. No penetration of the viscera was recorded in all animals.

Dorsal recumbency with Trendelenburg positioned with 20-degrees increased the visualization and manipulation of the abdominal content and was satisfactory to perform ovariectomy and ovariohysterectomy in goats, without any pressure on the thoracic organs.

The three portals for laparoscopic intervention allowed optimal visualization of the various pelvic viscera, ligament supporting urogenital organs, major blood vessels, internal inguinal ring and the muscle lining the pelvic cavity in goats (Fig 3).

The anesthetic regimen which formed from xylazine HCl as premedication, Ketamine as general

anesthetic and propofol for maintenance of the anesthesia showed that the induction was smooth, rapidly assumed recumbency and no signs of excitement.

The recorded clinical findings were extended to show the time of anesthesia of the previously mentioned dose was variable from 40 to 50 minutes. During this period the goats revealed complete muscle relaxation of jaw and abdominal wall and absence of palpebral, pedal and swallowing reflexes. No movement of any goat was recorded during the time of anesthesia.

The recovery of the animals displayed smooth, easy transition to awareness, recurred to sternal position, ability to stand within 5 minutes and ability to walk with slight ataxia. The animals talk their attitude of urination, defecation, drinking behavior, cud

chewing and their appetite within one hour after recovery.

The heart rate was significantly reduced from 15 to 30 minutes after induction of anesthesia and showed non-significant decrease from 45 minutes until recovery take place.

The respiratory rate decreased significantly at 30 minutes after induction, it showed non-significantly decreased at 45 minutes after induction. However, it significantly increases at the time of recovery and animal movement to change their position and make the behavioral attitude of different physiological functions. There was no significant difference in rectal temperature until evoking time (table 3).

Table (3) showing the heart rate, respiratory rate and rectal temperature^a before, during (along the time of anesthesia) and after anesthesia.

Time	0	15min	30 min	45 min	60 min	75 min	24 hour
Parameter							
Heart Rate	80± 12	50	48	58	61	75	79
Respiratory Rate	23± 023	17±06	13±05	18±04	20±03	21±05	23±08
Rectal Temperature	39 ±17 ⁰ C	38±3 ⁰ C	37±4 ⁰ C	38±23 ⁰ C	37±43 ⁰ C	38±34 ⁰ C	38±34 ⁰ C



Fig. 1. Special cradle was designed to facilitate the approach of Trendelenburg position



Fig 2: laparoscopic portal site on the goat abdomen. The first portal was located at the trans umbilical region with 10 mm diameter. The other portal was performed 7-10 cm caudal to the first incision in the left para-inguinal region with 5 mm diameter

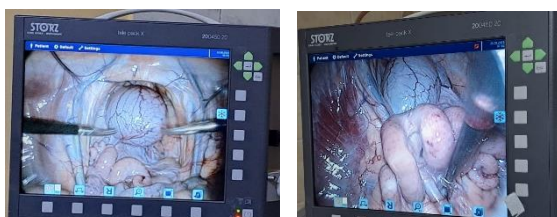


Fig 3 : showed the structure of the pelvic organs (urinary bladder, uterus) during laparoscopic intervention

4. DISCUSSION

The results of the present report coincide with that reported by (Devitt et al. 2005; Culp et al. 2009; Case et al. 2011). Who stated that the laparoscopic surgery was considered as minimally invasive surgery and have many advantages include the better visualization of the structures within the abdominal cavity, the reduced severity of pain in the postoperative period, and a faster patient recovery.

The results of our study during ovariectomy and ovariohystrectomy revealed that the laparoscopic technique is high academic value. These results come in contact with those reported by (Balsa and Culp, 2019) who mentioned that laparoscopic procedures were used for many surgical interference either in dogs or small ruminants and also used for artificial insemination, embryo transfer and ovum collection for in vitro fertilization they added that Laparoscopy has been used in academic training where the procedures is safe in experienced hands.

The results of this study revealed that pre-operative fasting for about 24 hours is satisfactory to decrease the ruminal content, motility of the gastrointestinal tract and prevent the possibility of accidental puncture of the internal viscera. This result gets in contact with (Fazili et al, 2015) who state that the preoperative fasting is mandatory before any laparoscopic procedure because it was found sufficient to decrease the content of the rumen and large intestine and reduce the intestinal peristaltic motility and reduce the risk of visceral penetration. Also they added that the preoperative fasting is essential during laparoscopic intervention because it improves observation of the abdominal and pelvic structure.

The result of the conducted study reveals that the anesthetic protocol composed of xylazine Hcl at a dose of 0.05mg/kg bwt, ketamine Hcl at a dose of 3.5 mg/kg bwt and propofol by a dose rate of 2.5 mg/kg bwt, was a suitable anesthetic method and had

satisfactory result that other anesthetic regimens. This result was differed entirely from that recorded by (Hall et al, 2001 and Khajuria et al, 2014). Who stated that the laparoscopic intervention can be performed under the effect of many anesthetic regimens such as local infiltration and lumbosacral epidural anesthesia.

The result of this study was documented by (Edmondson, 2014) who stated that local infiltration is easy to perform but had several disadvantages including, need for large volume of analgesic agent, non-homogenous and delayed wound healing.

Also, these results were supported by Ahmad and Shukla (2013) who discussed that lumbosacral epidural anesthesia in goats undergoing laparoscopy has no satisfactory relaxation of the abdominal musculature therefore make the manipulation harder during laparoscopy.

The results of our study revealed that the quality of induction, recovery was good and the time of anesthesia is satisfactory, sufficient to laparoscopic interference with the stated dose. Absence of palpebral, pedal and swallowing reflexes, complete muscle relaxation of jaw and abdominal wall. This results supported by Abouelfetouh et al, 2022 and Ragab et al, 2022 who mentioned the numeric scoring system applied to estimate several reflexes and 5 point sedation scales which revealing the good quality assumed with recumbency and unresponsive to external stimuli, no resistance and the jaw still opened, stopping the pedal and palpebral reflexes.

The good quality of our regimen is attributed to presence of alpha-2 adrenoceptor agonist (xylazine HCl) which admits an influence to muscle relaxation, reduce the required dose of ketamine, sedative, analgesic properties and decrease stress level during laparoscopic intervention. These results coincided with Afshar et al 2005 and Abouelfetouh et al 2021. The addition of ketamine to our protocol which considered as dissociative anesthetic agent that has profound analgesia and produces stable hemodynamic effect during anesthesia. This agrees with that mentioned by Celestine et al 2014.

The success goals of the used anesthetic combination depend on presence of propofol used in maintenance of anesthesia. Propofol characterized by good quality anesthesia, rapid onset, short duration of action with rapid recovery. This approved by Celestine et al 2014 and Ragab et al 2022. Who stated that, the smooth induction attributed to combination of more than anesthetic and sedative drugs like xylazine which acts as synergism to ketamine for production of better analgesic effect. They added that the rapid recovery after stopping of propofol administration resulting from no cumulative effect of propofol used for maintenance of anesthesia.

The significant bradycardia which observed at 5 minutes after anesthetic induction and extended to 20 minutes. While significant decrease in respiratory rate was recorded between 10-20 minutes after anesthetic induction. This come in contact with that reported by Aghamiri et al., 2022 Who mentioned that the balanced anesthetic regimen involved the combination of xylazine, ketamine and propofol anesthetic drugs to achieve total intravenous general anesthesia with minimal negative effect of individual drugs on the cardiopulmonary function. On the

contrary Kutter et al., 2006 stated that there is a significant reduction in respiratory rate between 5-30 minutes after administration, furthermore, these drugs has a significant decrease in heart rate up to 60 minutes after injection.

On the other hand the results of this work coincide with Kutter et al., 2006 Aghamiri et al., 2022 who stated that the animals restore ruminal motility, appetite and the attitude of urination and defecation within 120 minutes after administration of the anesthetic protocol.

The results of this article stated that the satisfactory visualization and manipulation of the internal viscera was achieved through pneumoperitoneum through insufflation of Co₂ as well as the dorsal recumbency with Trendelenburg position by 20 degree. This gets in contact with Daniel et al., 2019 who suggested that the optimum visualization of the internal viscera could be encouraged through abdominal insufflation beside Trendelenburg position with range 15-30 degree. They added that the Trendelenburg angle with 45 degree results in an increase in pressure on the diaphragm such that dynamic lung compliance and lung size are decreased, which lead to a reduce in cardiac venous return, cardiac output, and oxygen transfer to tissues.

In the present study, usage of 10mm laparoscope (primary portal) at the umbilical area and 5 mm of the other two portals in the pre-inguinal area provided optimum visualization of the abdominal viscera, ligaments supporting the internal organs, major blood vessels, internal inguinal ring and the muscle lining the pelvic cavity. These results agree with by Kawamoto et al., 2023 who mentioned that 10 mm initial laparoscopic portal with to sided 5 mm portal in the pre-inguinal provided good panoramic and close up view of the pelvic and abdominal cavity. They added that these portals allow satisfactory orientation and easier manipulation of the instrument.

5. CONCLUSIONS

Laparoscopy could be a useful teaching aid for students and surgeons, facilitating better understand of anatomy and developing of surgical skills. It is necessary to expand the use of laparoscope because of its many exploratory, diagnostic advantages and to perform many surgical interventions without the problems of standard surgical technique. The use of an anesthetic protocol consists of xylazine HCl at a dose of 0.05mg/kg b.wt, ketamine HCl at a dose of 3.5 mg/kg b.wt and propofol by a dose rate 2.5 mg/kg b.wt, fully satisfied the purpose of laparoscopic intervention in goats in terms of duration of anesthesia, the competence of entry into anesthesia as well as the quality of recovery.

ACKNOWLEDGMENT

The article was achieved by cooperation with Egyptian Society for Minimally Invasive Surgery. The target of this Society is practical personal training on laparoscopic skills.

6. REFERENCES

1. Abouelfetouh, M.M., Salah, E., Liu L., Khalil, A.H., Zhang, Q., Ding, M., Ding, Y. 2022. Immediate Postoperative Analgesia of Nalbuphine-Ketamine Combination Compared with Ketamine Alone in Xylazine-Sedated Goats Undergoing Left Flank Laparotomy. *Animals (Basel)* ;12 .4 :509. doi: 10.3390/ani12040509
2. Abouelfetouh, M.M.; Liu, L.; Salah, E.; Sun, R.; Nan, S.; Ding, M.; Ding, Y. 2021. The effect of xylazine premedication on the dose and quality of anesthesia induction with alfaxalone in goats *Animals (Basel)*;11,3:723. doi: 10.3390/ani11030723.
3. Afshar, F.S.; Baniadam, A.; Marashipour, S.P. 2005. Effect of xylazine-ketamine on arterial blood pressure, arterial blood pH, blood gases, rectal temperature, heart and respiratory rates in goats. *Bulletin of The Veterinary Institute in Pulawy*48, <https://api.semanticscholar.org/CorpusID:68763068>
4. Aghamiri, S.M., Samimi, A.S., Hajian, M., Samimi, A.M., Oroumieh, A. 2022. Effect of xylazine, detomidine, medetomidine and dexmedetomidine during laparoscopic SCNT embryo transfer on pregnancy rate and some physiological variables in goats. *BMC Vet Res* 18, 98 .
5. Ahmad, R., Shukla, B.P. 2013. Haematobiochemical changes following epidural analgesia by bupivacaine, ropivacaine and ropivacaine– xylazine combination in goats. *Indian J. Field Vet.* 8, 47-51.
6. Akter, M.A., Orchy, K.A.H., Khan, M.M.R., Hasan, M., Hasan, M., Alam, M.M. 2020. Clinical Evaluation of general Anaesthesia using ketamine hydrochloride with and without Diazepam in Sheep. *Arch Vet Sci Med* 3, 3:63–75 .
7. Asif, M., Khan, M.A., Akbar, H., Omer, M.O. 2021. Effects of detomidine and midazolam administered alone or combined, on induction dose and quality of propofol and ketamine anesthesia in goats. *The Journal of Animal & Plant Sciences*, 31(2): 2021, Page: 441-444
8. Baldassarre, H., Rao, K.M., Neveu, N., Brochu, E., Begin, I., Behboodi, E., Hockley, D.K. 2007. Laparoscopic ovum pick-up followed by in vitro embryo production for the reproductive rescue of aged goats of high genetic value. *Reprod Fertil Dev*; 19:612–616.
9. Balsa, I.M., Culp, W.T.N. 2019. Use of minimally invasive surgery in the diagnosis and treatment of cancer in dogs and cats. *Vet Sci.* 20; 6 1.:33 .doi: 10.3390/vetsci6010033
10. Brown, E.N., Pavone, K.J., Naranjo, M. 2018. Multimodal general anesthesia: Theory and practice. *Anesth Analg.* ;127:1246–1258 .
11. Butkovic, I., Vince, S., Marjanovic, K., Folnozic, I., Macesic, N., Spoljaric, B., et al. 2020. Laparoscopic ovariectomy in a pygmy goat. *Vet Med-Czech.* 65 9.:409-414 .
12. Case, J.B., Marvel, S.J., Boscan, P., Monnet, E.L. 2011. Surgical time and severity of postoperative pain in dogs undergoing laparoscopic ovariectomy with one, two, or three instrument cannulas. *J Am Vet Med Assoc.* 239, 2, 203-208.
13. Celestine, O. U., Chinedu, A.E, Anayo, J. O. 2014. Biochemical Effects of Xylazine, Propofol, and Ketamine in West African Dwarf Goats. *J Vet Med.* 758581 .doi: 10.1155/2014/758581
14. Celestine, O. U., Chinedu, A. E., Rita, I. U. 2014. Assessment of Common Anaesthetic and Clinical Indices of Multimodal Therapy of Propofol, Xylazine, and Ketamine in Total Intravenous Anaesthesia in West African Dwarf Goat. *J Vet Med.* DOI: 10.1155/2014/962560
15. Culp, W.T., Mayhew, P.D., Brown, D.C. 2009. The effect of laparoscopic versus open ovariectomy on postsurgical activity in small dogs. *Vet Surg.* 38 7.811-817.
16. Daniel, A. J., Easley, J. T., Holt, T. N., Griffenhagen, G. M., Hackett, E. S. 2019. Laparoscopic ovariohysterectomy in goats, *JAVMA*, 254 2., 275-281. Retrieved Jul 12, 2023 .
17. Devitt, C.M., Cox, R.E., Hailey, J.J. 2005. Duration, complications, stress, and pain of open ovariohysterectomy versus a simple method of laparoscopic-assisted ovariohysterectomy in dogs. *J Am Vet Med Assoc*; 227:921–927.
18. Dovenski, T., Trojancanec, P., Petkov, V., PopovskaPercinic, F., Kocoski, L.j. Grizelj, J. 2012. Laparoscopy-promising tool for improvement of reproductive efficiency of small ruminants. *Mac Vet Rev*; 35, 1, 5-11.
19. Edmondson, M.A. 2014. Local and regional anesthetic techniques in farm animal anesthesia. Lin, H and Walz, P Eds., first edition, Wiley Blackwell, Iowa, USA.
20. Fazili, M.R., Shah, R.A. Bhat, M.H. Khan, F.A. Khajuria, A., Yaqoob, S.H., Naykoo, N.A., Nazir Ahmad Ganai, N.A. 2015. Normal laparoscopic anatomy of the caprine pelvic cavity. *Veterinary Science Development*; 5:6012.
21. Hall, L.W., Clarke, K.W., Trim, C.M. 2001. *Veterinary anaesthesia*, fourth edition, W.B Saunders, Tottenham court road, London U.K..
22. Hunter, B.G., Huber, M.J., Riddick, T.L. 2012. Laparoscopic-assisted urinary bladder marsupialization in a goat that developed recurrent urethral obstruction following perineal urethrostomy. *J Am Vet Med Assoc*; 241:778–781.
23. Kassem, M.M., El-Gendy, S.A., Abdel-Wahed, R.E., El-Kammar, M. 2011. Laparoscopic anatomy of caprine abdomen and laparoscopic liver biopsy. *Res Vet Sci.* 90, 1, 9-15 .
24. Kawamoto, Y., Honda, G., Ome, Y., Matsunaga, Y., Uemura, S., Yoshida, N., Kotera, Y., Ariizumi, S. 2023. Laparoscopic left hepatectomy in a goat as a training model for laparoscopic anatomic liver resection: results of training courses with a total of 70 goats. *Surg Endosc.* 37, 5, 3634-3641 .
25. Khajuria, A., Fazili, M.U., Shah, R.A., Khan, F.A., Bhat, M.H., Yaqoob, S.H., Naykoo, N.A., Ganai, N.A. 2014. Comparison of Two Doses of Ropivacaine Hydrochloride for Lumbosacral Epidural Anaesthesia in Goats Undergoing Laparoscopy Assisted Embryo Transfer. *Int Sch Res Notices.* 937018 .
26. Kutter AP, Kästner SBR, Bettschart Wolfensberger R, Huhtinen M. 2006. Cardiopulmonary effects of dexmedetomidine in goats and sheep anaesthetised with sevofurane. *Vet Rec.* 159 19, 624-629.
27. Prassinis, N. N. Galatos, A. D. and Raptopoulos, D. 2005. A comparison of propofol, thiopental or ketamine as induction agents in goats. *Veterinary Anaesthesia and Analgesia*, 32, 5, 289–296.
28. Ragab, G., Hassan, S.E., Fathi, M.Z and Hagag, U. 2022. Clinicophysiological and hematobiochemical effect of dexmedetomidine or diazepam with ketamine and propofol in total intravenous anesthesia in goats. *Beni-Suef Univ J Basic Appl Sci* 11, 54 .
29. Röcken, M., Mosel, G., Seyrek-Intas, K., et al. 2011. Unilateral and bilateral laparoscopic ovariectomy in 157 mares: a retrospective multicenter study. *Vet Surg*; 40:1009–1014.
30. Shin, S.T., Jang, S.K., Yang, H.S., Lee, O.K., Shim, Y.H., Choi, W.I.L., Lee, D.S., Lee, G.S., Cho, J.K., Lee, Y.W. 2008. Laparoscopy vs. laparotomy for embryo transfer to produce transgenic goats *Capra hircus*.. *J. Vet. Sci.* 9, 103-107 .
31. Steffey, E. P., Brosnan, R. J., Galuppo L. D., Mama, K.R., Imai, A., Maxwell, L.K., Cole, C.A., Stanley, S.D. 2009. Use of propofol/xylazine and the anderson sling suspension system for recovery of horses from desflurane anesthesia, *Veterinary Surgery*, 38, 8, 927–933