




Official Journal Issued by  
Faculty of  
Veterinary Medicine

## Benha Veterinary Medical Journal

Journal homepage: <https://bvmj.journals.ekb.eg/>



Since 1990

### Original Paper

## Efficacy of administration of ampicillin and/or dimetridazole in the management of experimentally induced necrotic enteritis in broiler chickens.

Gehad Youssif, Nehal Mohsen, Eman Salah\*, Ashraf A. Elkomy

Department of Pharmacology, Faculty of Veterinary Medicine, Benha University, Toukh 13736, Egypt

### ARTICLE INFO

#### Keywords

*Clostridium perfringens*  
Ampicillin  
Broiler chickens  
Dimetridazole

Received 21/08/2023

Accepted 03/10/2023

Available On-Line

31/12/2023

### ABSTRACT

This study aimed to investigate the efficacy of oral administration of ampicillin and dimetridazole (DMZ) either alone or in combination for the treatment of necrotic enteritis (NE) caused by *Clostridium perfringens* (CP) infection in broiler chickens. One hundred Hubbard chicks were allocated into five groups (A, B, C, D, and E, 20 birds each). Birds in all groups (except those in group A) were orally inoculated at the age of 15 days with 0.5 mL of CP broth culture ( $10^9$  CFU/mL). Two days later, medications were orally given once daily for five days as follows; Group A and B were left untreated. Group C and D were treated with a therapeutic dose of ampicillin (20 mg/ kg b.wt) and DMZ (20 mg/ kg b.wt) respectively, while group E was treated with both ampicillin and DMZ. Clinical symptoms, weight gain, feed conversion rate (FCR), and the score of intestinal lesions were used to estimate the effectiveness of the investigated drugs. The results showed that administration of ampicillin and DMZ combination was followed by noticeable increases in body weight, weight gain, FCR, red blood cell count (RBCs), and hemoglobin concentration associated with a significant decrease in leukocyte. In addition, intestinal lesions in the ampicillin and DMZ groups showed nearly normal intestinal villi and enterocytes indicating recovery. The efficiency of ampicillin or DMZ was varied, but the combination of both drugs was greater. In conclusion, using ampicillin and DMZ together rather than separately was significantly more effective in controlling NE in broiler chickens.

## 1. INTRODUCTION

Necrotic enteritis (NE) is a critical bacterial disease that affects broiler chickens, causing inflammation and necrosis of the intestinal tissue. Necrotic enteritis has a global impact on the poultry industry. In broiler chickens, the disease results in lower weight gain, higher mortality, and decreased feed efficiency. Due to these clinical indications, the poultry industry suffers huge economic losses, making NE a key worry for producers. The economic impact of NE is both complex and different. Increased mortality rates, decreased weight gain, and poor feed efficiency are examples of direct losses that can drastically impact revenues for poultry producers. Furthermore, NE might have indirect costs such as increased veterinarian bills, additional labor costs connected with treating sick birds, and the requirement for increased biosecurity measures to avoid disease spread. The total economic loss due to NE in the poultry industry is estimated to be between \$2 and 6 billion USD worldwide annually (Timbermont *et al.*, 2011; Wade and Keyburn, 2015; Moore, 2016).

*Clostridium perfringens* (CP) is a Gram-positive, non-motile, spore-forming anaerobic bacteria that is a component of natural flora in the gastrointestinal tracts of animals and humans (Miller *et al.*, 2010). *Clostridium perfringens* is the most common cause of NE which produces strong toxins that harm the intestinal mucosa and encourage the development of additional harmful microbes in the gut of

chicken (Prescott *et al.*, 2016). *Clostridium perfringens* strains are divided into five toxin types (A–E) based on their ability to produce four primary toxins: Alpha ( $\alpha$ ), beta ( $\beta$ ), epsilon ( $\epsilon$ ), and iota ( $\iota$ ). Necrotic enteritis B-like (NetB), a spore-forming toxin generated by (A and C) strains of CP, has been found to have a significant role in the pathogenesis of NE (Prescott *et al.*, 2016; Mwangi *et al.*, 2019). Recent research has shown that the majority of CP strains isolated from NE outbreaks were resistant to some commonly used antibiotics, like gentamicin and streptomycin. As a result, it is necessary to study the use of other antibiotic types to control NE (Park *et al.*, 2015).

Ampicillin is a broad-spectrum, semi-synthetic penicillin that is a member of the  $\beta$ -lactam antibiotic family. Chemically, it resembles penicillin but has an additional amino group, which facilitates greater penetration through bacterial membranes. When bacteria are actively growing, its bactericidal or bacteriolytic action is most pronounced. It kills bacteria by preventing the biosynthesis of the mucopeptide that makes up the cell wall while they are growing. It is acid-stable and well absorbed from the gastrointestinal tract, and it is utilized as an oral antibiotic against systemic infections (El-Sheikh *et al.*, 2018; Gawrońska *et al.*, 2022).

Dimetridazole (DMZ) is a nitroimidazole antibiotic that has long been used in the chicken industry to treat and prevent bacterial and protozoal infection, such as *Eimeria* spp., *Salmonella* spp., and *Campylobacter* spp. Dimetridazole has

\* Correspondence to: eman.salah@fvtm.bu.edu.eg

also been proven to have high antibacterial activity against anaerobic microorganisms such as *CP* (Gray *et al.*, 2021). According to our knowledge, no published scientific papers discuss the use of ampicillin and DMZ together to treat *CP* infection in broiler chickens. The current study aimed to determine whether ampicillin and DMZ, used separately or together, are effective against experimentally induced NE in broiler chickens.

## 2. MATERIAL AND METHODS

### 2.1. Drugs

#### 2.1.1. Ampicillin

Ampicillin was purchased from ATCO Pharma for Pharmaceutical Industries, Cairo, Egypt with the commercial name of ATCO- AMPICINE 13%®. It is a water-soluble powder, and each 7.5 gm contains 1.155 ampicillin trihydrate (Eq. to 1gm ampicillin base) for veterinary use only. Ampicillin was given orally once daily for five consecutive days at a therapeutic dose of 20 mg ampicillin/kg b.wt. (Gross, 1991).

#### 2.1.2. Dimetridazole

Dimetridazole was purchased from ATCO Pharma for Pharmaceutical Industries, Cairo, Egypt with the commercial name of ATCO-DIAZOLE 40%®. Dimetridazole is a water-soluble powder, and each 1 kg contains 400 gm dimetridazole for veterinary use only. A therapeutic dose of DMZ was administered orally once daily for five consecutive days at a rate of 20 mg/kg body weight (Inghelbrecht *et al.*, 1996).

### 2.2. Experimental infection

We gratefully received a toxic strain of *CP* type (A) from the Animal Health Research Institute's, Microbiology Department, Giza, Dokki, Egypt. This strain was isolated from a flock of broiler chickens that kept in a local poultry farm, El-Saf, Giza, Egypt and had NE. The organism was cultured anaerobically for 24 hours at 37 °C in a Gaspack anaerobic jar using 10% sheep blood agar media with 200 µmL neomycin sulfate. The bacterium was then cultured in a medium containing cooked beef and incubated anaerobically at 37 °C for 12 hours. The acquired culture was centrifuged at 1000 rpm for 10 min and the *CP* concentration was adjusted to 10 colony-forming units (CFU)/ mL in an opaque tube (McFarland, 1907). Chickens were infected at the age of 15 days in all groups that received oral inoculations of 0.5 mL of *CP* broth culture except group A (Dahiya *et al.*, 2005).

### 2.3. Experimental chicks

One hundred mixed Hubbard broiler chicks of one day old were purchased from a poultry company (Qalyubia, Egypt). The birds were housed in wire-floor batteries in a highly sanitary environment. Chickens were vaccinated against the Newcastle at 7 days (Hitchner B1, Intervet International BV Company, Boxmeer, Holland) and at 18 days (Lasota, Intervet International BV Company, Boxmeer, Holland) and the birds were grown in temperature and humidity conditions appropriate for their ages, with unlimited access to feed and water. All birds received a non-medicated ration.

The experimental protocols followed the rules established by the Ethical Committee of the Faculty of Veterinary Medicine at Benha University in Egypt (Approval number: BUFVTM 12-04-23).

### 2.4. Experimental design

When clinical signs of NE were established and confirmed on the 17<sup>th</sup> day of life (two days after inoculation), oral administration of antibiotics was adopted in drinking water once per day for five days. The chickens were allocated into five equal-sized groups (twenty chickens each). Group A was maintained uninfected and untreated, while group B was infected with *CP* but did not receive treatment. Chickens in group C were infected and received ampicillin (20 mg/ kg b.wt.); those in group D were infected and received DMZ at a dose of 20 mg/ kg b.wt.; and chickens in-group E were infected with *CP* and received treatment with a combination of ampicillin and DMZ at a dose of 20 mg/ kg b.wt. each.

### 2.5. Blood sampling

Two ml of blood samples were taken from the wing vein of each bird on the 1<sup>st</sup> and 10<sup>th</sup> days after drug administration. Samples were collected in tubes with EDTA as an anticoagulant to estimate hematological parameters such as red blood cells (RBCs), hemoglobin, packed cell volume (PCV %), and white blood cells (WBCs). Red blood cell (RBCs) and WBCs counts were counted in a Neubauer hemocytometer using a 1:200 dilution with Natt and Herrick solution. Hemoglobin content was measured spectrophotometrically (JENWAY 6051 Colorimeter U.K Device) by manual method and PCV% was obtained by centrifuging a microhematocrit tube full of blood 12,000 G for five minutes (Campbell, 1995).

### 2.6. Efficacy of the drugs

#### 2.6.1. Clinical symptoms

The clinical symptoms that appeared in chickens post clostridia infection were recorded (Sojka and Carnaghan, 1961).

#### 2.6.2. Body weight and body weight gain

Prior to infection and on the first- and tenth day following drug administration, each group's chick was marked and weighed individually. The disparity in body weight between two subsequent weights was subtracted to determine the gain in body weight for each group.

#### 2.6.3. Feed consumption and feed conversion rate (FCR)

For all groups, weekly feed consumption and feed conversion calculations were recorded. The feed conversion was calculated using the following formula: grams of consumed feed per grams of body gain (Wagner *et al.*, 1983).

#### 2.6.4. Scoring of the intestinal microscopic lesions

The intestinal lesions were scored as follows: necrosis of enterocytes, necrosis of intestinal glands, villar fusion, hyperplasia of goblet cells, infiltration of mucosa and submucosa with inflammatory cells in mucosa and submucosa (Brennan *et al.*, 2003).

2.6.5. Histopathological examination

Five infected chickens from each group were sacrificed with sterile knives and a strict aseptic technique, and then small tissue specimens from the intestines in all groups were collected in vials containing 10% formalin. Histopathology sections were prepared using the formalin sample and hematoxylin and eosin (H&E) were used to stain all histological sections (Rapp and Wurster, 1978).

2.7. Statistical analysis

Statistical analysis was done using Graph Pad Prism software version 8.0. The body performance and hematological data were expressed as mean ± standard error. Two-way ANOVA was used with Dunnett's post-hoc test to compare variables between each group with control on the same day and the Tukey test to compare differences between groups on the different days post-treatment. The differences were considered significant at P < 0.05.

3. RESULTS

3.1. The impact of oral administration of ampicillin and DMZ at a dose of 20 mg/ kg b.wt each given alone or in conjunction on body performance of chickens experimentally infected with CP at 1<sup>st</sup>, and 10<sup>th</sup> days post-treatment.

In this study, CP-infected broiler chickens showed clinical symptoms including decreased appetite, depression, ruffled feathers, weight loss, diarrhea, dehydration, a reduction in weight gain, and an elevated feed conversion rate. Ampicillin and/or DMZ either alone or combined together resulted in the disappearance of the aforementioned clinical signs. The influence of oral administration of ampicillin (20 mg/ kg b.wt) alone or in combination with DMZ (20 mg/ kg b.wt) for 5 successive days on body weight, weight gain, and feed conversion rate in healthy and experimentally infected broiler chicks with CP was illustrated in Table (1). Following infection with CP, ampicillin administration alone produced a significant reduction in weight gain (p ≤ 0.05) on 1<sup>st</sup> day post-treatment and restored to normal level on 10<sup>th</sup> day post-treatment, compared with birds of the control group. Meanwhile, treatment of infected birds with DMZ either alone or combined with ampicillin returned weight gain and FCR to normal value at 1<sup>st</sup> and 10<sup>th</sup> days post-treatment, compared with birds of the control group (Table 1).

Table 1 Effect of ampicillin and/or DMZ either alone or combined on body performance in chickens infected with CP at 1<sup>st</sup>, and 10<sup>th</sup> days post-treatment.

Parameter	Group	13 <sup>th</sup> day of age (before infection)	1 <sup>st</sup> day post-treatment	10 <sup>th</sup> day post-treatment
Body weight (g)	Control	300.2 ± 11.3	984.6 ± 14.1	1881 ± 15.0††
	Infected non-treated	292.2 ± 10.6	738.4 ± 13.7***	1554 ±
	Infected A treated.	294.8 ± 11.9	883.6 ± 17.9**	19.9***†††
	Infected D treated.	296.2 ± 19.5	898.4 ± 16.2 *	1730 ± 19.2***††
	Infected A-D treated	300.8 ± 13.4	921.8 ± 15.1 *	1792.6 ± 16.4***†††
Weight gain (g)	Control	262.6 ± 11.3	684.4 ± 22.5	896.4 ± 6.4†††
	Infected non-treated	254.4 ± 10.4	446.2 ± 14.5***	815.6 ± 15.4***††
	Infected A treated.	257 ± 11.7	588.8 ± 9.5*	846.4 ± 15.9†††
	Infected D treated.	258.2 ± 19.2	602.2 ± 7.6	883.4 ± 15.4†††
	Infected A-D treated	263 ± 13.2	621.2 ± 3.8	893.2 ± 6.2†††
FCR (%)	Control	1.23	1.17	1.56
	Infected non-treated	1.26	1.46	1.72
	Infected A treated.	1.25	1.31	1.65
	Infected D treated.	1.24	1.30	1.58
	Infected A-D treated	1.22	1.29	1.57

FCR: feed conversion rate, A: ampicillin, D: DMZ, A-D: ampicillin and DMZ. Values are presented as mean ± SE (n=5). \* Significant difference compared to the control group at the same day. †Significant difference between groups at the different days post-treatment. \*Significant at p < 0.05, \*\* Significant at p < 0.01, \*\*\* Significant at p < 0.001

3.2. The impact of oral administration of ampicillin (20 mg/ kg b.wt) alone or in combination with DMZ (20 mg/ kg b.wt) on erythrogram and leukocytic count in CP experimentally infected chicks at 1<sup>st</sup>, and 10<sup>th</sup> days post-treatment.

The results of the current study showed that broilers infected with CP displayed significant reductions in total RBCs count, hemoglobin concentration, and PCV % accompanied by significant increases in WBCs count during the entire experimental period post-infection (p ≤ 0.001), (Table 2). In addition, administrating ampicillin alone in drinking water for 5 consecutive days resulted in a significant reduction (p < 0.01) in the RBCs count, hemoglobin concentration, and PCV% accompanied by a substantial elevation in WBC (p < 0.01) when compared with the control group, at 1<sup>st</sup> day post-treatment. Also, administrating DMZ alone in drinking water for 5 consecutive days resulted in a significant decrease (p < 0.05) in the RBCs count, hemoglobin concentration, PCV%, and a significant increase in WBC count (p < 0.05) when compared with the control group, at 1<sup>st</sup> day post-treatment. However, the RBCs count, hemoglobin concentration, PCV%, and total WBCs count restored toward normal levels in ampicillin and DMZ combination at 10<sup>th</sup> day post-treatment, when compared with the control group (Table 2).

Table 2 Effect of ampicillin and/or DMZ either alone or combined on erythrogram and leukocytic count in chickens infected with CP at 1<sup>st</sup>, and 10<sup>th</sup> days post-treatment.

Parameter	Group	1 <sup>st</sup> day post-treatment	10 <sup>th</sup> day post-treatment
RBCs (10 <sup>12</sup> /L)	Control	3.8 ± 0.10	3.8 ± 0.12
	Infected non-treated	2.7 ± 0.10***	3 ± 0.16***
	Infected A treated.	3.2 ± 0.11**	3.3 ± 0.08*
	Infected D treated.	3.3 ± 0.12*	3.4 ± 0.10*
	Infected A-D treated	3.3 ± 0.14*	3.7 ± 0.16
HB (g/dL)	Control	10.7 ± 0.35	10.5 ± 0.38
	Infected non-treated	7.9 ± 0.26***	8.1 ± 0.15***
	Infected A treated.	9.3 ± 0.31**	9.2 ± 0.14*
	Infected D treated.	9.3 ± 0.28*	9.2 ± 0.19*
	Infected A-D treated	9.5 ± 0.22*	10.6 ± 0.47
PCV (%)	Control	31.2 ± 1.1	31.2 ± 1
	Infected non-treated	23.1 ± 0.70***	24.5 ± 1***
	Infected A treated.	26.5 ± 1.2**	27 ± 1.2*
	Infected D treated.	26.9 ± 0.98*	27.3 ± 0.97*
	Infected A-D treated	27.4 ± 1*	31.2 ± 0.88†††
TLC (10 <sup>9</sup> /L)	Control	0.88 ± 0.1	1 ± 0.1
	Infected non-treated	2.5 ± 0.21***	2.3 ± 0.38***
	Infected A treated.	1.8 ± 0.30**	1.8 ± 0.19*
	Infected D treated.	1.8 ± 0.17**	1.8 ± 0.16*
	Infected A-D treated	1.7 ± 0.10*	1.3 ± 0.15

RBC: red blood cell count, HB: hemoglobin concentration, PCV: packed cell volume, TLC: total leukocytic count, A: ampicillin, D: DMZ, A-D: ampicillin and DMZ. Values are presented as mean ± SE (n = 5). \* Significant difference compared to the control group at the same day post-treatment. †Significant difference between groups at the different days post-treatment. \* Significant at p < 0.05, \*\* Significant at p < 0.01, \*\*\* Significant at p < 0.001

3.3. Histopathological lesion score

Table (3) displayed the severity scores for the recorded intestinal microscopic lesions among chickens in experimental groups.

Table 3 Scoring of histopathological alterations in the intestine of all treated groups

Lesions	G1	G2	G3	G4	G5
Necrosis of enterocytes	0	3	3	2	1
Necrosis of intestinal glands	0	3	1	1	1
Villar fusion	0	3	1	0	0
hyperplasia of goblet cells	0	3	3	2	1
Infiltration of inflammatory cells in mucosa and submucosa	0	3	2	1	0

The scoring system was as follows: score 0 = absence of the lesion in all rats of the group (n=5), score 1= (< 30%), score 2= (< 30% – 50%), score 3 = (>50%).

3.4. Histopathological findings of intestine:

The control untreated group exhibited normal histological architecture of intestinal villi and lining enterocytes (Fig. 1a). The infected group showed diffuse necrotic enteritis in the form of coagulative necrosis of enterocytes and intestinal glands with fusion of intestinal villi (Figs.1b&c). There was also hyperplasia in the intestinal goblet cells (Fig. 1d). The

intestinal mucosa and submucosa were heavily infiltrated with mononuclear inflammatory cells (Fig.1 e). The ampicillin treated group showed moderate coagulative necrosis of enterocytes and hyperplasia of goblet cells (Fig. 1f). The Dimetridazole treated group showed mild coagulative necrosis of enterocytes lining intestinal villi Fig. g) with few goblet cells (Fig. h). The ampicillin+ DMZ treated group showed nearly normal intestinal villi and lining enterocytes (Fig. i) and few goblet cells (Fig.1 j).

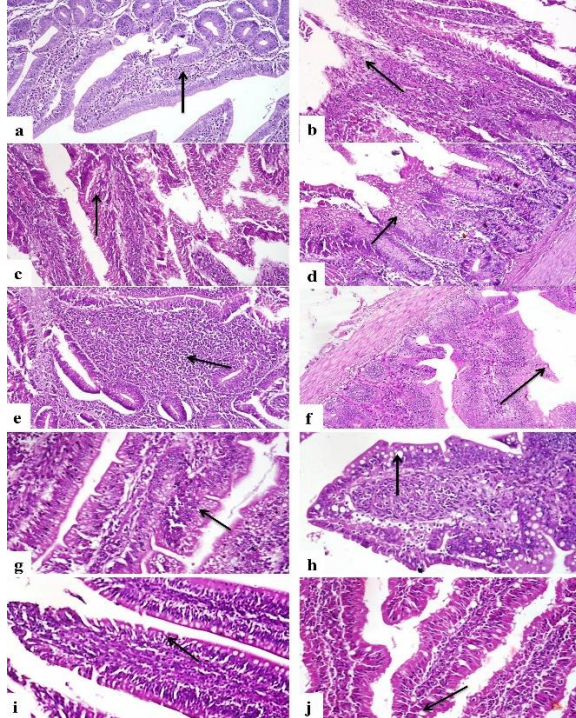


Figure 1 Photomicrograph of intestine. (a) Control untreated group showing normal histological structure of intestinal villi (arrow) indicating normal lining enterocytes H&E, X200. (b) Infected group showing diffuse necrotic enteritis with villar fusion (arrow) H&E, X200. (c) Infected group showing diffuse coagulative necrosis of enterocytes (arrow) H&E, X200. (d) Infected group demonstrating hyperplasia of goblet cells (arrow) H&E, X200. (e) The infected group showed heavy infiltration of the intestinal mucosa with mononuclear inflammatory cells (arrow) H&E, X200. (f) Ampicillin-treated group showing moderate necrosis of enterocytes with hyperplasia of goblet cells (arrow) H&E, X100. (g) Dimetridazole treated group showing necrosis of few enterocytes (arrow) H&E, X200. (h) DMZ treated group showing few goblet cells (arrow) H&E, X200. (i) Ampicillin+ DMZ treated group showing nearly normal intestinal villi and enterocytes (arrow) H&E, X200. (j) Ampicillin+ DMZ treated group showing few goblet cells (arrow) H&E, X200.

#### 4. DISCUSSION

Even though there have been an increasing number of reported clinical incidents of NE in the poultry business, including broilers produced on the floor (Dhillon *et al.*, 2004; Timbermont *et al.*, 2011), the therapeutic effectiveness of antibiotics for the prevention of NE in broiler chicken is not well documented in the literature (Abreu *et al.*, 2023).

This study was conducted to give a clear pattern of the effectiveness of orally administered ampicillin and/or DMZ either alone or in conjunction with controlling of NE in broiler chickens. The *in-vivo* experiment was performed on 100 chickens, all were the same age and size and allocated into five groups. Four groups were infected with *CP* and NE clinical symptoms were recorded on day 17 as previously reported (Immerseel *et al.*, 2004; Gholamiandekhordi *et al.*, 2006; Cooper and Songer, 2010; Hafez, 2011; Dar *et al.*, 2017).

According to the results of the current study, broilers experimentally infected with *CP* showed a significant reduction in body weight, weight gain, and increase in FCR all over the experimental period post-infection. Similar

decreases in body weight gain and increases in feed conversion rate were observed by Skinner *et al.* (2010). The reduction in body weight in broiler chickens with *CP* infections was explained by Lovland and Kaldhusdal (1999). They discovered that clostridial toxins had caused damage to intestinal tissue and the liver leading to a decrease in nutrient uptake and metabolism, which led to poorer growth performance in the birds.

Ampicillin administration alone in infected birds with *CP* produced a significant reduction in weight gain ( $p \leq 0.05$ ) at 1<sup>st</sup> day post-treatment and was restored to normal level on the 10<sup>th</sup> day post-treatment, compared with birds of the control group.

These findings were supported by findings that ampicillin inhibited the progress of NE, lessened mortality, and controlled bacterial multiplication linked with NE in broilers (Abd El-Hack *et al.*, 2022). Treatment of infected birds with DMZ either alone or combined with ampicillin returned weight gain and FCR to normal value at 1<sup>st</sup> and 10<sup>th</sup> days post-treatment, compared with birds of the control group. This increase in weight gain, and feed conversion rate may be due to the antimicrobial effect of used antibiotics in the suppression of *CP* and decreased its intestinal colonization leading to the prevention of NE (Watkins *et al.*, 1997)

Dimetridazole was reported to have excellent antimicrobial properties against various bacterial and parasite infections. Dimetridazole was reported to be safe to use in poultry. After being administered to turkey for three days, DMZ was highly effective for treating histaminases and was quickly metabolized and eliminated with no measurable tissue residual (<0.02 ppm) (Law *et al.*, 1963). Several studies were conducted to evaluate the accumulation of DMZ in poultry and eggs using different methods such as Liquid Chromatography, Mass Spectrometry, and Gas Chromatography (Cannavan and Kennedy, 1997; Ho *et al.*, 2005). In Australia, DMZ maximum residue limit (MRL) was stipulated at 5 µg/kg in poultry meat (Ho *et al.* 2005). For the first time, we evaluated the efficacy of DMZ as a potential therapy for NE and compared it to ampicillin. Dimetridazole showed promising results on live poultry because it not only eliminates the NE but also high up FCR from 1.23 to 1.24 %. Interestingly, when we use a combination therapy between ampicillin and DMZ, we get better results not only in terms of the elimination of the pathogen but also in weight gain, FCR, and the general status of the chickens. Previous research has demonstrated that nitroimidazole class drugs are effective as metronidazole against *CP* (Aslam *et al.*, 2016). Metronidazole has been used in combination with amoxicillin to prevent *CP* infection in broiler chickens. A combination of amoxicillin (10 mg/kg b.wt) and metronidazole (20 mg/kg b. wt) is better than using amoxicillin (20 mg/kg b.wt) or metronidazole (40 mg/kg b.wt) separately for treatment of NE in broiler chickens (Aboubakr and Elbadawy, 2016). Earlier research has shown that the metronidazole accumulation rate in chickens was high, which causes neurotoxicity in birds and humans (Cybulski *et al.*, 1996 ; Abdulrazzaq and Amin, 2021). Dimetridazole, on the other hand, is safer than metronidazole and more capable of eliminating *CP*, the cause of NE (Beer *et al.*, 2022).

Throughout the entire experimental period post-infection, the broilers infected with NE displayed a remarkable drop in the total RBC count, hemoglobin concentration, and PCV % together with a large rise in the WBC count. Comparable blood image changes in broiler chickens with NE have also been noted in prior studies (Mawell, 1993). Moreover, *CP* infection demonstrated a reduction in total RBC count, hemoglobin content, and PCV % in young turkeys (Dorra *et*

al., 2016). In the present study, broiler chickens treated with ampicillin and DMZ improved RBC count, hemoglobin concentration, PCV% and WBC count. In a previous study, amoxicillin administration in broiler chickens revealed beneficial efficacy against clostridial infections and enhanced the hematological variables (Khodary *et al.*, 2019).

## 5. CONCLUSIONS

As a result of the current study, it was determined that A novel treatment regimen of ampicillin and DMZ each at a dose of 20 mg/ kg b.wt is a very effective combination than using ampicillin (20 mg/ kg b.wt) or DMZ (20 mg/ kg b.wt) separately for treatment of NE in broiler chickens.

## 6. REFERENCES

1. Abd El-Hack, Mohamed E., Mohamed T. El-Saadony, Ahmed R. Elbestawy, Nahed A. El-Shall, Ahmed M. Saad, Heba M. Salem, Amira M. El-Tahan, Asmaa F. Khafaga, Ayman E. Taha, Synan F. AbuQamar, and Khaled A. El-Tarabily. 2022. 'Necrotic enteritis in broiler chickens: disease characteristics and prevention using organic antibiotic alternatives – a comprehensive review', *Poultry Science*, 101: doi.org/10.1016/j.psj.2021.101590
2. Abdulrazzaq, DH, and SM Amin. 2021. 'Acute toxicity of metronidazole and its interaction with chlorpyrifos in chicks', *Iraqi J Vet Sci*, 35: 13-18.
3. Aboubakr, Mohamed, and Mohamed Elbadawy. 2016. 'Efficacy of flagymox®(amoxicillin and metronidazole combination) in controlling *Clostridium perfringens* infection in broiler chickens', *World Journal of Pharmacy and Pharmaceutical Sci*, 6: 80-95.
4. Abreu, Raquel, Teresa Semedo-Lemsaddek, Eva Cunha, Luís Tavares, and Manuela Oliveira. 2023. 'Antimicrobial Drug Resistance in Poultry Production: Current Status and Innovative Strategies for Bacterial Control', *Microorganisms*, 11: 953-988. doi: 10.3390/microorganisms11040953.
5. Cannavan, A and Kennedy, D. 1997. 'Determination of dimetridazole in poultry tissues and eggs using liquid chromatography–thermospray mass spectrometry', *Analyst*, 122: 963-966.
6. Aslam, S, AZ Durrani, M Rizwan, and M Kashif. 2016. 'Comparative Efficacy of metronidazole in combination colistin sulphate and probiotics against *Clostridium perfringens* and their effects on histopathological features of visceral organs in broiler', *Veterinaria*, 4: 11-17.
7. Beer, L.C., Petrone-Garcia, V.M., Graham, B.D., Hargis, B.M., Tellez-Isaias, G. and Vuong, C.N. 2022. 'Histomonosis in poultry: a comprehensive review', *Frontiers in Veterinary Science*, 9: 880738.
8. Brennan, J, J Skinner, DA Barnum, and J Wilson. 2003. 'The efficacy of bacitracin methylene disalicylate when fed in combination with narasin in the management of necrotic enteritis in broiler chickens', *Poultry Science*, 82: 360-363.
9. Campbell, TW. 1995. 'Avian hematology and cytology', University press Ames.
10. Cooper, Kerry K, and J Glenn Songer. 2010. 'Virulence of *Clostridium perfringens* in an experimental model of poultry necrotic enteritis', *Veterinary microbiology*, 142: 323-328.
11. Cybulski, W, P Larsson, H Tjälve, H Kowalska-Pylka, M Sylla, and S Semeniuk. 1996. 'Disposition of metronidazole in hens (*Gallus gallus*) and quails (*Coturnix coturnix japonica*): pharmacokinetics and whole-body autoradiography', *Journal of veterinary pharmacology and therapeutics*, 19: 352-358.
12. Dahiya, JP, D Hoehler, DC Wilkie, AG Van Kessel, and MD Drew. 2005. 'Dietary glycine concentration affects intestinal *Clostridium perfringens* and lactobacilli populations in broiler chickens', *Poultry Science*, 84: 1875-1885.
13. Dar, Parvaiz S, Shakil A Wani, Aasim H Wani, I Hussain, Rafia Maqbool, Muhammad Y Ganaie, Zahid A Kashoo, and S Qureshi. 2017. 'Isolation, identification and molecular characterization of *Clostridium perfringens* from poultry in Kashmir valley, India', *J Entomol Zool Stud*, 5: 409-414.
14. Dhillon, AS, Parimal Roy, Lloyd Lauerman, Dennis Schaberg, Sylvia Weber, Daina Bandli, and Fonda Wier. 2004. 'High mortality in egg layers as a result of necrotic enteritis', *Avian Diseases*, 48: 675-680.
15. Dorra, Tork I, ZM Kalaba, MY Mostafa, and Sh M Zayed. 2016. 'Growt performance and hematological parameters of turkey poults as affected by effective microorganisms', *Journal of Animal and Poultry Production*, 7: 15-22.
16. El-Sheikh, Sawsan M, Mohamed H Khairy, Naglaa Z Eleiwa, Osama E Abdalla, and Asmaa G Abd El-Monsef. 2018. 'Effect of Sanguinarine phytobiotic, Sodium butyrate compared to ampicillin on controlling necrotic enteritis in broiler chickens', *Slovenian Veterinary Research*, 55:405-414.
17. Gawrońska, M., M. Kowalik and M. Makowski 2022. 'Recent advances in medicinal chemistry' of ampicillin: Derivatives, metal complexes, and sensing approaches', *Trac trends in analytical chemistry*, 155: 116691-116712.
18. Gholamiandekhordi, Ahmad R, Richard Ducatelle, Marc Heyndrickx, Freddy Haesebrouck, and Filip Van Immerseel. 2006. 'Molecular and phenotypical characterization of *Clostridium perfringens* isolates from poultry flocks with different disease status', *Veterinary microbiology*, 113: 143-152.
19. Gray, P., R. Jenner, J. Norris, S. Page, and G. Browning. 2021. 'Antimicrobial prescribing guidelines for poultry', *Aust Vet J*, 99: 181-235.
20. Gross, W. B. 1991. 'Use of corticosterone and ampicillin for treatment of *Streptococcus faecalis* infection in chickens', *American journal of veterinary research*, 52: 1288-1291.
21. Hafez, Hafez Mohamed. 2011. 'Enteric diseases of poultry with special attention to *Clostridium perfringens*'.
22. Ho, Clare, Della WM Sin, KM Wong, and Hubert PO Tang. 2005. 'Determination of dimetridazole and metronidazole in poultry and porcine tissues by gas chromatography–electron capture negative ionization mass spectrometry', *Analytica chimica acta*, 530: 23-31.
23. Immerseel, Filip Van, Jeroen De Buck, Frank Pasmans, Gerard Huyghebaert, Freddy Haesebrouck, and Richard Ducatelle. 2004. '*Clostridium perfringens* in poultry: an emerging threat for animal and public health', *Avian Pathology*, 33: 537-549.
24. Inghelbrecht, Sabine, Hubert Vermeersch, S. Ronsmans, Jean Paul Remon, Patrick Debacker, and Jozef Vercruyse. 1996. 'Pharmacokinetics and anti-trichomonal efficacy of a dimetridazole tablet and water-soluble powder in homing pigeons (*Columba livia*)', *Journal of veterinary pharmacology and therapeutics*, 19: 62-67.
25. Khodary, Marwa, Nasr El-Deen, and Ibtisam Gamal El-Deen. 2019. 'Effect of experimental *Clostridium perfringens* infection on some immunological, hematological and biochemical values in broiler chickens', *Zagazig Veterinary Journal*, 47: 222-233.
26. Law, G.L., Mansfield, G.P., Muggleton, D.F. and Pamell, E.W. 1963. 'Dimetridazole: absorption, excretion and metabolism in turkeys', *Nature*, 197: 1024-1025.
27. Lovland, A. and Kaldhusdal, M. 1999: Liver lesions seen at slaughter as an indicator of necrotic enteritis in broiler flocks. *Immun. Med. Microb.*, 24: 45-51.
28. McFarland, Joseph. 1907. 'The nephelometer: an instrument for estimating the number of bacteria in suspensions used for calculating the opsonic index and for vaccines', *Journal of the American Medical Association*, 49: 1176-1178.
29. Maxwell, M. 1993. "Avian blood leucocyte responses to stress," *World's Poultry Science Journal*, 49: 34-43.
30. Miller, Ross W., James Skinner, Alexander Sulakvelidze, Greg F. Mathis, and Charles L. Hofacre. 2010. 'Bacteriophage therapy for control of necrotic enteritis of broiler chickens experimentally infected with *Clostridium perfringens*', *Avian Diseases*, 54: 33-40.
31. Moore, Robert J. 2016. 'Necrotic enteritis predisposing factors in broiler chickens', *Avian Pathology*, 45: 275-281.

32. Mwangi, S, J Timmons, S Fitz-Coy, and S Parveen. 2019. 'Characterization of *Clostridium perfringens* recovered from broiler chicken affected by necrotic enteritis', Poultry Science, 98: 128-135.
33. Park, Ji Young, Sara Kim, Jae Young Oh, Hye Ryoung Kim, Il Jang, Hee Soo Lee, and Yong Kuk Kwon. 2015. 'Characterization of *Clostridium perfringens* isolates obtained from 2010 to 2012 from chickens with necrotic enteritis in Korea', Poultry Science, 94: 1158-1164.
34. Prescott, John F, Valeria R Parreira, Iman Mehdizadeh Gohari, Dion Lepp, and Joshua Gong. 2016. 'The pathogenesis of necrotic enteritis in chickens: what we know and what we need to know: a review', Avian Pathology, 45: 288-294.
35. Rapp, W., and K. Wurster. 1978. Alcian blue staining intestinal goblet cell antigen (GOA): A marker for gastric signet ring cell and colonic colloidal carcinoma, Klin Wochenschr, 56: 1185–1187.
36. Skinner, J.; Bauer, S. and Wilson, J. 2010. 'An economic analysis of the impact of subclinical (mild) necrotic enteritis in broiler chickens', Avian Disease, 54: 1237–1240.
37. Sojka, WJ, and RBA Carnaghan. 1961. 'Escherichia coli infection in poultry', Research in Veterinary Science, 2: 340-352.
38. Timbermont, L., F. Haesebrouck, R. Ducatelle and F. Van Immerseel. 2011. 'Necrotic enteritis in broilers: an updated review on the pathogenesis', Avian Pathology, 40: 341-347.
39. Wade, Ben, and Anthony Keyburn. 2015. 'The true cost of necrotic enteritis', World Poult, 31: 16-17.
40. Wagner, DD, RD Furrow, and BD Bradley. 1983. 'Subchronic toxicity of monensin in broiler chickens', Veterinary pathology, 20: 353-359.
41. Watkins, K.L., Shryock, R., Dearth, N and Saif, Y. 1997. 'In-vitro antimicrobial susceptibility of *Clostridium perfringens* from commercial turkey and broiler chicken origin', Veterinary Microbiology, 54: 195-200..