

## SURGICAL EXTRACTION OF IMPACTED LOWER THIRD MOLAR, EVALUATION OF A NEW SCALE OF DIFFICULTY

Aya Aly Mohammed <sup>1\*</sup>, Tamer Abd Elbari Hamed <sup>2</sup>, Mohammed Hassan Eid <sup>3</sup>

DOI: 10.21608/dsu.2024.188601.1158

Manuscript ID: DSU-2301-1158

### KEYWORDS

Lower Third Molar;  
Surgical Extraction;  
New Scale of Difficulty

- E-mail address:  
ayaalybraveheart1990@gmail.com
- 1. Postgraduate student at the Department of Oral and Maxillofacial Surgery, Faculty of Dentistry, Suez Canal University, Egypt.
- 2. Professor of Oral and Maxillofacial Surgery, College of Dentistry, University of Science and Technology of Fujairah, United Arab Emirates.
- 3. Lecturer of Oral and Maxillofacial Surgery, Faculty of Dentistry, Suez Canal University, Egypt.

### ABSTRACT

**Introduction:** Assessment of the surgical complexity of lower third molar extraction is a crucial step to formulate an optimal treatment plan, balancing the advantages and disadvantages of the surgical extraction procedure to manage intraoperative complications and postoperative pain. **Aim:** This study aimed to evaluate the accuracy of a new scale of surgical difficulty for the extraction of the impacted lower third molar. **Patients and methods:** Fifty-four patients were attended for lower third molar extraction. All patients undergoing the same surgical approach including anesthesia, incision, and elevation of the mucoperiosteal flap, ostectomy, and tooth sectioning, elevation, and avulsion according to the root axis, socket debridement, and suturing. The period of this study extended for 2 years. **Results:** The mesio angular impaction was the most common type of impaction, followed by horizontal impaction. There was agreement between the preoperative and the postoperative assessment of a simple operation. 26 third molars (48.15%) were considered preoperatively medium difficulty group, and 80.77% was agreement between the preoperative and the postoperative assessments of moderately simple ( $p < 0.001$ ). **Conclusion:** Our scale is effective since the mandibular third molars with the highest scores were significantly correlated to longer ostectomy time and total surgical time.

### INTRODUCTION

Third molars, or “wisdom teeth”, are extremely polymorphic in modern humans. Approximately one-fourth of people worldwide are born missing one or more of these teeth, and one-fourth of people have one or more of these teeth impacted <sup>(1)</sup>.

The most frequently impacted teeth in the mouth are the mandibular third molars, or wisdom teeth, which can affect up to 70% of people. Due to the high prevalence of impacted third molars, their surgical extraction under local anesthetic is regularly performed in dental practices and countries, with practically all oral and maxillofacial surgeons <sup>(2)</sup>.

The average age at which lower wisdom teeth erupt in men is roughly three to six months earlier than in women, and most authors assert that the incidence of mandibular wisdom tooth impaction is higher in women. Mandibular third molars may erupt as early as

14 years of age in Nigerians and as late as 26 years in Europeans<sup>(3-5)</sup>. Third molars differ from other teeth in several important ways. They are also seen as functionally unnecessary in dental treatment and are thought to represent the pathological, developmental, and medical abnormalities that characterize contemporary society<sup>(6,7)</sup>.

The accident or complication rates associated with wisdom tooth removal may range from 2.6 to 30.9%; these outcomes depend on several variables, including patient age, gender, health status, degree of tooth impaction, surgeon experience, level of oral hygiene, smoking, use of contraceptives, and surgical technique. The majority of third molar procedures go off without a hitch. However, the patient may experience major consequences as a result of the treatment. Odontectomy, a procedure that involves elevating the gingival flap and sectioning the tooth to remove it from the bone piece by piece, is frequently required to remove IMTM. As a result, it is common to experience postoperative inflammatory symptoms like trismus, swelling, infection, persistent pain, dry socket (alveolar osteitis), hemorrhage, mandibular fracture, dentoalveolar fracture, and even paresthesia<sup>(7)</sup>.

It is crucial for both general dentists and oral and maxillofacial surgeons to be aware of all the potential problems and/or accidents that could arise during or after the surgical removal of impacted wisdom teeth. This enhances patient education and raises awareness of the need to handle any unforeseen circumstances in the best way possible<sup>(8)</sup>. So, before any type of surgery in order to anticipate any potential issues that may arise throughout the entire treatment, the preoperative difficulty index for removal of impacted mandibular third molars should be taken into consideration<sup>(9)</sup>.

Therefore, this study aimed to describe a radiographic surgical difficulty grade based on a

number of factors, including the angulation, depth, bone density, relationship with the mandibular canal, buccolingual location, and dental morphology of impacted teeth, and comparing it with the overall surgical time.

## PATIENTS AND METHODS

This study included 54 healthy patients classified as ASA (American Society of Anesthesiology classified patients according to their physical state 2014), Class I patients (normal healthy middle-aged patients) from the outpatient clinic of Oral and Maxillofacial Surgery Department, Faculty of Dentistry, Suez Canal University who required surgical extraction of impacted mandibular third molar. A preoperative panoramic radiograph was obtained for all patients. All patients were informed about all details of the surgical procedures, the expected complications, the whole study schedules, and the photos to be shared in that scientific research. Then they signed an informed consent. Approval of the Research Ethical Committee of the Faculty of Dentistry, Suez Canal University (35/2018) was obtained before starting the study.

### Inclusion criteria:

The patients have impacted lower third molars as shown from their panoramic radiograph that need surgical extraction. Patients of both sexes (20 males and 34 females), aged (18-45) years were included in the study. All patients were physically healthy with no medical history of any systemic diseases that would contraindicate the surgery or might complicate the healing process. The patients were cooperative, motivated, nonsmokers, and had good oral hygiene.

### **Exclusion criteria:**

Patients with conditions including liver cirrhosis, renal failure, and osseous illnesses that influence the healing process will confound the study's results. Any pathology, such as cysts, benign or malignant tumors, acute infections, or cysts, around the impacted tooth. Patients undergoing radiotherapy or chemotherapy, those with any type of physical or mental impairment, those with dysplastic molar problems (germinal or follicular test), pregnant women, and those with a lower second molar that is missing due to surgery are also at risk.

### **Preoperative preparation**

All patients are subjected to full dental history and clinical examination. Third molar examination showed dental caries, pericoronitis, periodontal disease, resorption of adjacent tooth, and crowding of anterior dentition.

The management of third molars consists of radiographic evaluation of dentofacial structures and the third molars in particular because it provides very important information to program and correctly plan the surgical removal of impacted teeth. This information includes the type and position of impaction, size, and shape of impacted tooth, the relationship of impacted tooth to adjacent teeth density of bone surrounding impacted tooth, the depth of impaction in bone, and the relationship of impacted tooth to various anatomic structures, such as the mandibular canal.

### **Preoperative instructions:**

Each patient was given the oral antibiotic Augmentin (produced by Medical Union Pharmaceuticals, Abu Sultan, Ismailia under license from the GlaxoSmithKline group of companies) twice daily one day prior to surgery. All patients were instructed to maintain periodontal health in the form of tooth brushing and oral rinses mouthwash with

Hexitol (produced by The Arab Drug Company, Cairo, A.R.E.) three times per day. Radiographic assessment was performed as screening panoramic, and cone beam computed tomography (CBCT) for included cases with limited field of view of the impaction site.

### **Surgical difficulty assessment:**

The surgical difficulty was evaluated preoperatively using **Sammartion et al.**<sup>(10)</sup> difficulty index which proposed and validated a new scale of surgical difficulty based on variables not previously considered (relating to morphological abnormalities, the type of undercut and the transverse position of the tooth) as the following:

- 1. Angulation:** Winter's classification was based on the relationship of the impacted tooth to the long axis of the second molar tooth<sup>(11)</sup>. **Quek et al.**<sup>(12)</sup> proposed a classification approach that uses an orthodontic protractor to minimize mistakes caused by a single visual impression. The angle produced when the second and third molars' long axes intersected was used by this study to assess angulation. Lower third molar impaction was divided into the following categories: vertical (0 to 10), mesioangular (11 to 79), horizontal (80 to 100), distoangular (-11 to -79), and others (-111 to -80).
- 2. Available space:** According to **Pell and Gregory's**<sup>(13)</sup> classification according to the distance between the ramus of the mandible and the distal side of the second molar, there are three categories of impacted third molars in the horizontal plane.
- 3. Depth:** According to **Pell and Gregory**<sup>(13)</sup> The depth is measured in places A, B, and C corresponding to the highest part of the third molar in relation to the occlusal plane and cervical line of the second molar.

Relation with mandibular canal: **Abu-El Naaj et al.** <sup>(14)</sup> revealed that TMC I, TMCII(a,b), and TMC III are the three classifications for third molars based on their relationship to the mandibular canal.

Bone density: according to Misch's classification<sup>(15)</sup>, Bone density can be broken down into five groups: D1-1250 Hounsfield units (HU); D2-850 HU; D3-350 HU; D4-150 HU; and D5-150 HU. Another crucial aspect to take into account when determining the degree of surgical difficulty is the buccolingual position of the majority of the impacted teeth with respect to the mandibular buccal and lingual walls. When the third molar in the mandible is extracted near the lingual nerve, iatrogenic damage to the nerve may result. It is located in the cortical plate and occasionally lies outside of it due to the periosteum<sup>(9)</sup>. Dental morphology can be categorized into two difficulty levels: low and high. Hour-glass undercuts, taurodontism, numerous, curved or convergent roots (or both), or fusion of the apices are characteristics of low difficulty.

### Operative procedure:

Before the procedure, betadine solution and standard draping were provided. All patients washed with 5-10 ml of Chlorhexidine for 2 min preoperatively. All patients received a standardized mandibular nerve block injection with additional

infiltration of the buccal nerve. The effective local anesthesia was injected using Articaine 4% with Epinephrine 1:100,000 as a vasoconstrictor presented in carpule 1.8 ml with a trade name Artinibsa (Articaine 4% Inibsa® Inibsa, Barcelona, Spain).

The surgical approach for removing impacted mandibular third molar involves anesthesia, incision, and elevation of the mucoperiosteal flap, osteotomy, and tooth sectioning, elevation, and avulsion according to the root axis, socket debridement, and suturing (Fig.1). The surgery classified as simple (less than 20 minutes); moderately simple (20-40 minutes); difficult (40-60 minutes) and extremely difficult (More than 60 minutes).

### Postoperative care:

All patients were subjected to the following drugs after the surgery Augmentin (1 gm) tablets every 12h for 7 days. Flagyl (Sanofi-Aventis Egypt, under license of Sanofi-Aventis France) is available in 500 mg tablets every 12 h for 7 days. Brufen (Kahira Pharma & Chemical Ind. Co. under license of Abbott Laboratories), 400 mg tablets as required. Hexitol (The Arab Drug Company, Cairo, A.R.E) for 7 days postoperatively. All patients were informed of the expected occurrence of facial swelling, pain, and trismus. A sterile gauze pack was kept on the

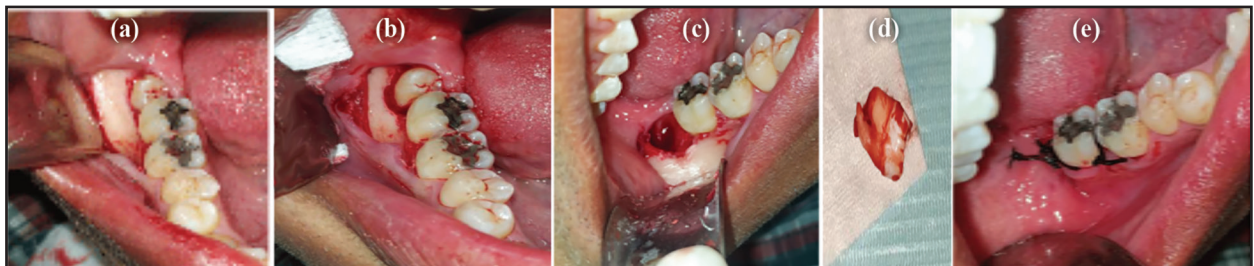

Fig. (1) Surgical procedures; (a) clinical photograph showing reflection of flap to expose impacted tooth and bone around it, (b) clinical photograph after osteotomy, (c) showing socket after extraction of impacted third molar, (d) extracted impacted tooth, and primary wound closure by using interrupted sutures.

wound and the patients were advised to bite for one hour. Avoid rinsing or spitting for 24 hours after surgery.

The patient was instructed to apply cold packs over the surgical area extra-orally 20 minutes/hour, five times for the day of the operation only in order to reduce the swelling caused by the surgical procedure this also has some sedative effect. Avoid hot drinks, hot foods, hard foods, and eating on the operating side.

### Statistical analysis

Analysis of data was performed with SPSS statistical software version 28.0 for Mac OS. Demographic data, gender and type of impaction as a nonparametric data were described in terms of frequency count and percentages (n, %). Continuous variables such as age were expressed as mean  $\pm$  standard error (SE). Two-way repeated measures analysis of variance (ANOVA) followed by paired sample t-test was used for testing relation between related samples. To verify normal distribution of data the Kolmogorov-Smirnov and Shapiro-Wilk normality test was used. The level of agreement using the Kappa statistic test and a Kendal-tau-b tests were used. All statistical tests were performed at 0.05 levels. A p-value less than 0.05 was considered statistically significant and a confidence interval was estimated at 95%.

## RESULTS

According to age groups, the distribution of patients according to age groups was 2 (3.7%), 30 (55.6%), 18(33.3%), and 4(7.4%) from 18-20 years was 2 with 3.7 percent, in age groups 18-20, 21-30, 31-40, and 41-45 years; respectively. The difference between age groups was highly significant at 0.05

level (**Table 1**). Male patients were represented by 20 (37%) and females with 34 (63%), and the difference was non-significant (**Table 2**).

**Table (1)** Distribution of patients according to Age groups

Age group	Frequency n (%)		Chi-square	
	n	%	Chi-	Sign.
18-20 years	2	3.7		
21-30 years	30	55.6		
31-40 years	18	33.3	38.148	<0.001***
41-45 years	4	7.4		
Mean $\pm$ SD	29.85 $\pm$ 6.17 years			

\*, \*\*, \*\*\*, significant at  $p < 0.05$ ,  $< 0.01$ ,  $< 0.001$ ;  
NS, non-significant at  $p > 0.05$

**Table (2)** Gender distribution among studied patients.

Gender	Frequency n (%)		Chi-square	
	n	%	Chi-	Sign.
Male	20	37		
Female	34	63	3.63	0.057 ns

\*, \*\*, \*\*\*, significant at  $p < 0.05$ ,  $< 0.01$ ,  $< 0.001$ ;  
NS, non-significant at  $p > 0.05$

The mesio angular impaction was seen in 28 patients (51.9%) and was the most common type of impaction, followed by horizontal impaction in 18 (33.3%), then vertical impaction in 6(11.1%) and the least recorded was distal impaction 2 patients 3.7%. The differences between impaction on the right side was significant ( $p=0.002^{**}$ ), and left side ( $p=0.032^{*}$ ), and highly significant in the total of right and left sides ( $p < 0.001^{***}$ ) (Table 3).



**Table (3)** Mandibular their molar impaction on the right and left sides

	Right		Left		Total		Wilcoxon signed rank
	n	%	n	%	n	%	Sign.
Mesioangular	16	29.6	12	22.2	28	51.9	>0.05ns
Horizontal	10	18.5	8	14.8	18	33.3	>0.05ns
Vertical	4	7.4	2	3.7	6	11.1	>0.05ns
Distal	2	3.7	0	0.0	2	3.7	>0.05ns
Total	32	59.3	22	40.7	54	100.0	>0.05ns
Chi-square sign.	0.002**		0.032*		<0.001***		
Chi-square sign.							<0.001***

\*, \*\*, \*\*\*, significant at  $p < 0.05$ ,  $< 0.01$ ,  $< 0.001$ ; NS, non-significant at  $p > 0.05$

According to pre-operative difficulty index. The distribution of pre-operative difficulty index was 20 (37.04%) low, 26 (48.15%) Medium, and 8 (14.8%) high. The difference between low, medium and high was highly significant (Chi=9.33; sign.=0.009) (Fig.2).

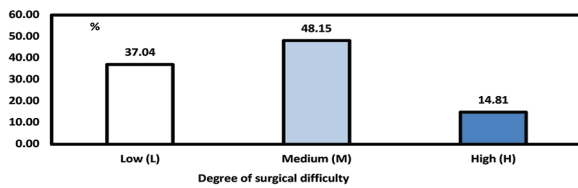


Fig. (2) Degree of surgical difficulty according to pre-operative difficulty index.

The pre-operative evaluation placed 20 third molars (37.04%) in the low-difficulty group, and in 18 of these (90%), there was agreement between the preoperative and the postoperative assessment of a simple operation. 26 third molars (48.15%) were considered preoperatively as being in the medium difficulty group, and in 21 out of 26 (80.77%) there was agreement between the preoperative and the postoperative assessments of moderately simple ( $p < 0.001$ \*\*\*). Eight third molars (14.8%) were considered preoperatively as highly difficult, and out of these 7 third molars were postoperatively difficult to extremely difficult comprising 87.5% ( $p = 0.044$ \*) (Table 4).

**Table (4).** Frequency of agreement between preoperative and post-operative degree of difficulty.

Postoperative assessment of degree of difficulty	Pre-operative assessment of degree of difficulty						Chi-square sign.
	Low		Medium		High		
	n	%	n	%	n	%	
Simple	18	33.3	2	3.7	0	0.0	0.003**
Moderately simple	2	3.7	21	38.9	1	1.9	<0.001***
Difficult	0	0.0	2	3.7	6	11.1	0.146 ns
Extremely difficult	0	0.0	1	1.9	1	1.9	0.317 ns
Total	20	37.0	26	48.1	8	14.8	0.009**
Chi-square	<0.001***		0.006**		0.044*		
Chi-square							Chi=38.72; Sign. <0.001***

\*, \*\*, \*\*\*, significant at  $p < 0.05$ ,  $< 0.01$ ,  $< 0.001$ , NS, nonsignificant at  $p > 0.05$

The ordination analysis values based on Eigenvalues presented about 6 PC axes, with PC-1 and PC-2 representing more than 86% of the total variance. Variables studied were effective in classifying studied cases and were significantly effective (Fig. 3).

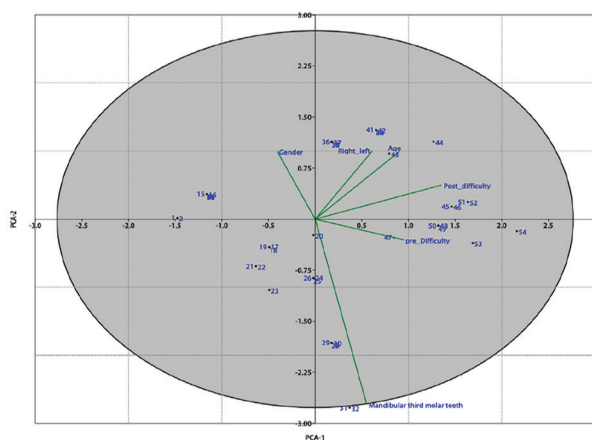


Fig. (3) PCA-Ordination presenting the interaction between variables of the study and studied cases.

## DISCUSSION

The present study aimed to evaluate the accuracy of the preoperative difficulty index for removal of impacted mandibular third molar using difficulty index which based on variables not previously considered relating to morphological abnormalities, type of undercut, and transverse position of the tooth<sup>(10)</sup>.

We give patients preoperative medications for a long time in surgical extraction, Surgical trauma is associated with post-operative pain, edema and swelling according to Newton's law for every action there's a reaction.

In order to improve the prediction of surgical difficulty, various variations of these scales have been put forward over time. Each factor's influence

on extraction difficulty was given a score between 0 and 4, and the sum of these scores produced a final score that predicted extraction difficulty: 3-4 (not difficult), 5-7 (moderately difficult), and 7-9 (great difficulty). This scale has been frequently utilized in oral and maxillofacial surgical literature as a quick approach to gauge how difficult an impacted mandibular third molar surgery will be to perform<sup>(16)</sup>.

**Diniz-Freitas et al.**<sup>(17)</sup> showed that due to the lack of information regarding bone density, check flexibility, buccal opening, and operation time, the Pederson difficulty index scale is insufficient to adequately represent the grade of surgical difficulty.

In our study, panoramic radiography is primarily used for preoperative planning, but in case of diagnostic doubts about the risk of the surgical procedure. Similar to **Trybek et al.**<sup>(5)</sup> used CBCT in their study and stated that comparing three-dimensional (3D) images to traditional (2D plain) radiographs, the former offers superior and more detailed information. Additionally, CBCT determines the type of impaction, the size of the follicle, the inclination of the tooth's long axis, the relative locations of the buccal and palatal surfaces, the amount of bone covering the tooth, and its approximate location with respect to nearby teeth and anatomical features<sup>(18)</sup>.

It's a reliable prediction of the duration of the procedure (time) is an important factor to optimize the daily schedule for both the operator and the patient.

Cost is different in severe, moderate, and simple cases regarding time of the procedure because of the tools used and the effort, and exhaustion of the operator.

In our study the selected patients were free from any systemic diseases and the mean age of the selected patients was found to be  $29.8 \pm 6.17$  years.

This is accordant to **Kugelberg et al.**<sup>(19)</sup> agreed that older individuals tend to respond less positively to the removal of teeth, especially impacted third molars, surgical removal of impacted mandibular third molars should be performed when the patient is young. Also, **Chiapasco et al.**<sup>(20)</sup> believed that age-related postoperative problems may be correlated with increased bone density, which could necessitate more surgical manipulation.

In this study we found that impaction of lower third molar occur in female than in male, this is in accordance with research conducted by **Braimah et al.**<sup>(21)</sup>; **Barunawaty et al.**<sup>(22)</sup>; **Albyati et al.**<sup>(23)</sup>; and **Bede**<sup>(24)</sup>. This is consistent with the assumption that physical growth in woman will stop earlier compared to men and this leads to a smaller jaw size in women compared to men.

In our study, mesio-angular impaction constitutes the majority of the impacted mandibular third molars, followed by horizontal impaction, vertical then distoangular. This study similar to **Muhmmad et al.**<sup>(25)</sup> stated that a 50% incidence, mesio-angular impactions were the most frequent kind seen, followed by horizontal impactions (16.5%), vertical inclinations (16.2%), distal inclinations (15.9%), transverse inclinations (1.2%), and inverted impactions (0.3%).

The studies of **Al-Dajani et al.**<sup>(26)</sup> and **Yilmaz et al.**<sup>(27)</sup> showed the most frequent impaction was discovered to be vertical impaction; the first team found that this impaction occurred in 40.7% of patients while mesio-angular impaction occurred in only 7.1% of patients, but the second team discovered that vertical impaction occurred in 53% of patients while mesio-angular impaction occurred in 29% of patients. The differences in results may be due to the adoption of an incorrect modification of Winter's index in the studies of **Al-Dajani et al.**<sup>(26)</sup> and **Yilmaz et al.**<sup>(27)</sup>.

In our study, 54 cases of impacted third molar were 32 (59.3%) right side and 22 (40.7%) left side. Similar to **Albyati et al.**<sup>(23)</sup> stated that prevalence of impacted mandibular third molar on right side is more than left side. Also, **Jae-Young et al.**<sup>(28)</sup> found of the 204 impacted mandibular third molar, 89 were impacted on the left side and 115 were impacted on the right side.

The results conducted by **Muhmmad et al.**<sup>(25)</sup> stated that the distribution of the lower left and right third molar has no significant difference. Likewise, distribution of the lower third molar impaction between males and females has no significant difference.

According to the relation between ages, this study showed that most cases of impaction were found in the 21-30 years old. **Muhmmad et al.**<sup>(25)</sup> found in young adults, impacted lower third molars are typical. Patients between the ages of 21 and 30 had the highest prevalence of impactions (103%) and patients between the ages of 31 and 40 had the lowest prevalence (52%) of impactions. This study clearly shows that the number of impacted wisdom teeth decreases as individuals get older.

The difficult value was in male than females in the present study. This finding coincides with those of **Bachmann et al.**<sup>(29)</sup> and **Anjum et al.**<sup>(30)</sup>. One of the possible reasons that supports this presumption was based on the gender-related bone composition differences<sup>(31)</sup>. On the other hand, **Roy et al.**<sup>(32)</sup> stated that gender was not a determinant of surgical difficulty<sup>(33)</sup>.

## CONCLUSION AND RECOMMENDATIONS

Our scale is effective since the mandibular third molars with the highest scores were significantly correlated to longer ostectomy time and total surgical time.



In our opinion, this new index is an accurate and valuable tool for the prediction of the surgical difficulty in the removal of mandibular wisdom teeth. This index is easy to calculate and can be used by general dental practitioners, residents, and experienced oral and maxillofacial surgeons alike.

## REFERENCES

1. Goyal S, Verma P, Radiographic evaluation of the status of third molars in Sriganganagar population – A digital panoramic study. *Malays J Med Sci* 2016;23 (6):103-112.
2. Salwan Y Bede. Factors Affecting the Duration of Surgical Extraction of Impacted Mandibular Third Molars. *World J Dent* 2018;9 (1):8-12.
3. Juoodzbalys G, Daugela P. Mandibular Third Molar Impaction: Review of Literature and a Proposal of a Classification. *J Oral Maxillofac Res* 2013, 4(2): e1.
4. Zeynep G, Emre B, Mert K. Is there a relationship between third-molar impaction types and the dimensional/angular measurement values of posterior mandible according to Pell & Gregory/Winter Classification? *J Oral Radiol* 2021;37(1):29-35.
5. Trybek G, Jaroń A, Grzywacz A. Association of polymorphic and Haplotype Variants of the MSX1 Gene and the Impacted Teeth Phenomenon. *Genes* 2021;12(4), 577.
6. Kumar VR, Yadav P, Kahsu E, Girkar F, Chakraborty R. Prevalence and Pattern of Mandibular Third Molar Impaction in Eritrean Population: A Retrospective Study. *J Contemp Dent Pract* 2017;18 (2):100-106.
7. Khanal P, Dixit S, Singh R, Dixit P. Difficulty index in extraction of impacted mandibular third molars and their postoperative complication. *J Kathmandu Med Coll* 2014; 3:14-20.
8. Shital Patel, Saloni Mansuri, Faizan Shaikh, Taksh Shah. Impacted Mandibular Third Molars: A Retrospective Study of 1189 Cases to Assess Indications for Surgical Removal, and Correlation with Age, Sex and Type of Impaction- A Single Institutional Experience. *J Maxillofac Oral Surg* 2017; 16:79-84.
9. Elitsa G, Deliverska, Milena P. Complications after Extraction of Impacted Third Molars. *J IMAB* 2016; 22(3):1202-1211.
10. Sammartion G, Gasparro R, Marenzi G, et al. Extraction of mandibular third molars: proposal of a new scale of difficulty. *Br J Oral Maxillofac surg* 2017; 55:952-957.
11. Andreasen JO, Petersen JK, Laskin DM. Text book and colour atlas of tooth impactions. 1st ed. *Impactions-Diagnosis, Treatment and Prevention* (1997).
12. Quek SL, Tay CK, Tay KH, Toh SL, Lim KC. Pattern of third molar impaction in a Singapore Chinese population: a retrospective radiographic survey. *Int J Oral Maxillofac Surg* 2003; 32(5) 548-552.
13. Pell GJ, Gregory GT. Impacted third molars: classification and modified techniques for removal. *Dental Digest* 1933; 39:330-338.
14. Abu-El Naaj I. Surgical Approach to Impacted Mandibular Third Molars- Operative Classification. *J Oral Maxillofac Surg* 2010; 68:628-633.
15. Misch CE. *Contemporary implant dentistry*. 2nd ed. St Louis: Mosby: 1990.
16. Ribes Lainez N, Sanchis González JC, et al. Importance of a preoperative radiographic scale for evaluating surgical difficulty of impacted mandibular third molar extraction. *J Oral Sci Rehab* 2017; 3(1):52-59.
17. Diniz- Freitas M, Lago-Méndez L, Gude-Sampedro F, et al. Pederson scale fails to predict how difficult it will be to extract lower third molars. *Br J Oral Maxillofac Surg* 2007; 45:23-26.
18. Badawy I N, El Prince NH, EL Ashwah A A. Evaluation of Panoramic X-ray Versus Cone Beam Computed Tomography In Surgical Removal Of Horizontally Impacted Mandibular Third Molar. *Alex Dent J* 2016; 41:277-282.
19. Kugelberg CF, Ahlström U, Ericson S, Hugoson A. Periodontal healing after impacted lower third molar surgery. A retrospective study. *Int J Oral Surg* 1985; 14(1): 29-40.
20. Chiapasco M, De Cicco L, Marroneh K. Side effects and complications associated with third molar surgery. *Oral Surg Oral Med Oral Pathol* 1993; 76:412-420.

21. Braimah RO, Ali-Alsuliman D, Taiwo AO, Ibikunle A A, Makarami RM, Al-Sagoor ST. Surgical difficulty assessment in patients undergoing impacted mandibular third molar extraction. A single center evaluation in Najran, Kingdom of Saudi Arabia. *J Dent Res Rev* 2021; 8:163-167.
22. Yunus B, Wulansari DP, Tunnizha BM. Lower Third Molar Impaction Based on Pell and Gregory Classification: A Panoramic Study. *Sys Rev Pharm* 2020;11(11):19-23.
23. Albyati MT, Salwan YB. The Effect of the Difficulty of Surgical Extraction of Impacted Mandibular Third Molars on the Postoperative Inflammatory Response. *J Res Med Den Sci* 2020; 8(1):107-111.
24. Bede SY. Factors affecting the Duration of Surgical Extraction of Impacted Mandibular Third Molars. *World J Dent* 2018; 9(1):8-12.
25. Muhamad A, Nezar W, Azzaldeen A. Prevalence of impacted third molars in population of Arab Israeli: a retrospective study. *I J Dent and med Sci* 2016;15 (1):80-89.
26. Al-Dajani M, Abouonq AO. Cohort Study of the patterns of Third Molar Impaction in Panoramic Radiograph in Saudi Population. *Open Dent J* 2017; 11:648-660.
27. Yilmaz S, Adisen MZ. Assessment of Third Molar Impaction Pattern and Associated Clinical Symptoms in a central Anatolian Turkish Population. *Med Princ Pract* 2016; 25: 169-175.
28. Jae-Young K, Hae-Sung Y. Modified difficult index adding extremely difficult for fully impacted mandibular third molar extraction. *J Korean Assoc Oral Maxillofac Surg* 2019; 45:309-315.
29. Bachmann H, Cáceres R, Munoz C, Uribe S. Complications en cirugias de terceros molars entre los años y 2010, en un hospital urbano, Chile. *Int J Odontostomat* 2014; 8(1): 107-112.
30. Anjum R, Naseem N, Nagi AH. Age, gender and pattern distribution of impacted third molar among patients attending teaching hospital of Lahor. *PJMHS*. 2014; 8(3):562-565.
31. Ishwarkumar S, Pillay P, Degama BZ, Satyapal KS. An osteometric evaluation of the mandibular condyle in a black KwaZulu-Natal population. *Int J Morphol* 2016; 34 (3):848-853.
32. Roy I, Baliga SD, Louis A, Rao S. Importance of clinical and radiological parameters in assessment of surgical difficulty in removal of impacted mandibular 3rd molars: a new index. *J Maxillofac Oral Surg* 2015;14 (3):745-749.
33. Yunus D, Wulansari DP, Tunnizha BM. Lower Third Molar Impaction Based on Pell and Gregory Classification: A Panoramic Study. *J Sys Rev Pharm* 2020; 11(11):19-23.