

COMPARATIVE STUDY BETWEEN SMART BURS II AND CONVENTIONAL CARBIDE BURS IN EVALUATION OF PAIN ANXIETY IN CHILDREN

Walaa Mohamed Hussein Ghalwash^{1*}, Ghada Abdel Hamid El Baz², Yousra Samir Mohamed Helmy³

DOI: 10.21608/dsu.2024.216890.1186

Manuscript ID: DSU-2306-1186

KEYWORDS

Carbide burs,
Caries removal time,
SmartBurs II, Pain

• E-mail address:
walaaghalwash@gmail.com

1. Post Graduate Student in Pediatric, Preventive Dentistry and Dental Public Health Department, Faculty of Dentistry Suez Canal University, Ismailia, Egypt.
2. Professor, Pediatric and Preventive Dentistry and Dental Public Health, Faculty of Dentistry, Suez Canal University, Ismailia, Egypt.
3. Lecturer, Pediatric and Preventive Dentistry and Dental Public Health, Faculty of Dentistry, Suez Canal University, Ismailia, Egypt.

ABSTRACT

Introduction: The anticipation of pain experienced through dental treatment is usually because of local anesthetic injections and a high-speed handpiece, especially in children. Smart Burs II does not require local anesthesia; therefore, it can mitigate the discomfort encountered during dental interventions and circumvent dental anxiety. **Aim:** We aimed to evaluate the duration required for caries removal by Smart Burs II in contrast to carbide burs, as well as the level of pain reported by pediatric patients during the application of each method. **Methods:** Thirty permanent first molars that met our criteria were included in the study. These molars were present in children aged between 8 and 11 years and exhibited class I occlusal caries. Participants were categorized into two groups on the basis of random allocation. In Group I, which consisted of 15 participants, caries removal was performed using SmartBurs II. In Group II, which comprised 15 participants, a conventional carbide bur was used for caries removal. The duration of the caries removal procedure was recorded in seconds for both groups. Patient perceptions of treatment were determined using the facial image scale (FIS). **Results:** According to the statistical analysis, SmartBurs II resulted in a longer duration and lower recorded pain scores than carbide bur. **Conclusions:** The employment of SmartBurs II necessitated an extended duration for caries removal and resulted in a significant reduction in pain sensation during the extraction of infected dentin compared to using traditional carbide burs.

INTRODUCTION

It is commonly understood that dental procedures are often accompanied by expectations of pain, particularly in children. The pain associated with dental treatment plays a significant role in developing dental anxiety. This anxiety amplifies the perception ⁽¹⁾.

Dental anxiety has severe health implications for both children and adolescents. This can result in decreased comfort during dental care situations, postponement, or avoidance of necessary routine dental care and follow-up appointments, leading to unmet dental treatment needs. A major source of dental anxiety arises from local anesthetic injections or high-speed handpieces. Sound, vibration, and even the sight of a handpiece can disturb the patient ^(2,3).

The traditional technique of removing caries is often perceived as traumatic, primarily because of the fear and anxiety, it elicits in

children and their parents. In addition, mechanical preparation often induces pain; therefore, local anesthesia is administered to control pain. The conventional method of caries removal involves the extraction of both infected and affected dentin. This can result in unnecessary weakening of the tooth structure, which often leads to over-extended cavities. Additionally, it can have harmful thermal impacts on the pulp, reducing the regenerative potential of the pulp-dentin complex ⁽⁴⁻⁶⁾.

In 2003, a potential alternative to traditional dentin caries removal methods was introduced as a polymer prototype bur. This self-limiting polymer bur, known as SmartBurs™ (SS White, Lakewood, NJ, USA), is a single-use instrument resembling a bur and is constructed from medical-grade polymers with a hardness lower than that of healthy dentin. Different sizes are available for right-angle latch handpieces: #4, #6, and #8 ^(7,8).

Minimally invasive excavation techniques reduce the cutting of the dentinal tubules, resulting in less pain than traditional burs. Polymer bur instruments, made from a specialized polymer material rather than metal, have a unique design with straight, shovel-like cutting edges. The polymer material has a Knoop Hardness of 50 kg/mm² and was specifically improved to be harder than carious dentin (Knoop Hardness 0-30) but softer than healthy dentin (Knoop Hardness 70-90) ^(9,10).

SmartBurs II ensures the selective removal of caries-infected dentin, thus minimizing the pain experienced during dental procedures and avoiding dental anxiety. Thus, this work aimed to assess and compare the extent of pain perception and caries removal time using SmartBurs II and conventional carbide burs during caries removal procedures.

MATERIALS AND METHODS

Sample size calculation

Two way analysis of variance (ANOVA) was proposed. A total calculated sample size of 30 samples was sufficient to detect the effect size of 0.5, a power ($1-\beta=0.80$) of 80% at a significance probability level of $p < 0.05$ partial eta squared of 0.21. According to sample size calculation, the minimum required sample size will be 15 molars in each group. Thus a total of thirty permanent first molars will be divided into two groups for the purpose of this study. The sample size was calculated according to G*Power software version 3.1.9.3.

Ethical approval

This study was performed at the Department of Pediatric Dentistry Clinic of the Faculty of Dentistry, Suez Canal University. The study was accepted by the Research Ethics Committee (REC) of the Faculty of Dentistry at Suez Canal University (approval no. 69/2018), and all clinical procedures were performed according to its guidelines and regulations.

Study design

Before the study, a preoperative evaluation was performed to ensure the appropriate selection of cases. This involved obtaining a medical history, performing clinical evaluations, capturing digital images, and conducting radiographic assessments. This study involved selecting children between 8 and 11 years of age, encompassing both sexes. The selection criteria were based on the ratings of definitely positive or positive on the Frankl behavior rating scale. The participants were chosen from the outpatient clinic of the Pedodontic Department affiliated with the Faculty of Dentistry at Suez Canal University.

Ultimately, 30 permanent first molars were chosen depending on the inclusion criteria. Class I (occlusal) active caries involved dentin with a cavity opening diameter of at least 2 mm, estimated using a periodontal probe, teeth with carious lesions extending up to 2/3 of the dentin thickness, and without periapical or interradicular radiolucency. Teeth with developmental abnormalities that could affect treatment and carious teeth exhibiting clinical or radiographic indications of pulpal involvement were excluded from the study. Cases in which the parents declined to sign an informed consent form were also excluded. Detailed information about the study objectives and clinical procedures was provided to the parents or legal guardians.

Clinical procedures and grouping

At the beginning of the dental visit, the “tell-show-do” method was used, in which the child was introduced to all instruments and equipment involved in the treatment session. Periapical radiographs were obtained for each carious tooth. Proper isolation was performed on the selected teeth using cotton rolls and suction. The study did not use local anesthesia; however, the patients were informed that they could choose anesthesia for discomfort or pain. Carious lesions were removed from all selected carious teeth and then divided into two groups based on the kind of bur utilized for caries removal.

Carbide bur group (Group A)

The caries was removed using round carbide burs #12, #14, and #16, as per the lesion size, on a slow-speed handpiece. Dentin excavation ceased upon the detection of hard dentin via a dental probe. Hard dentin is characterized by its resistance to probe penetration when subjected to firm pressure.

Smart polymer bur group (Group B)

The removal of carious tissue was accomplished using smart polymer burs of sizes #4, #6, and #8, which were selected based on the cavity size. The burs were operated slowly without water coolant according to the manufacturer’s guidelines. The circular motion was employed, beginning at the center of the lesion, and moving outward to the periphery, as suggested by the manufacturer. The excavation process was terminated when the instrument exhibited macroscopic signs of abrasion and blunting, rendering it incapable of removing the dental tissue.

Evaluation of caries removal time

The duration of the carious dentin removal was measured using a KADIO digital stopwatch. The measurement started at the onset of caries removal, utilizing either polymer or carbide burs, and concluded upon complete caries removal^(11, 12).

Patient evaluation of the procedures

Children’s anxiety levels were evaluated using the facial image scale (FIS), as shown in Figure 1. This scale comprised a series of five faces that depicted emotions ranging from extreme happiness to extreme unhappiness. Scale scoring was performed by assigning a value of one to the face with the most positive effect and five to the face with the most negative effect. The FIS was used because of its evidence of validity and proven to be suitable for the age group selected in this study. Also, it was easy and quick (less than 1 min) to administer, and the score was simply a reflection of the chosen face⁽¹³⁾.

After the treatment session, the FIS was presented to the children, and they were asked, “Which face would you be if you were this face right now?” The child then indicated the face that best represented their level of pain or discomfort during the treatment. Scores were recorded based on faces selected by the child⁽¹⁴⁾.

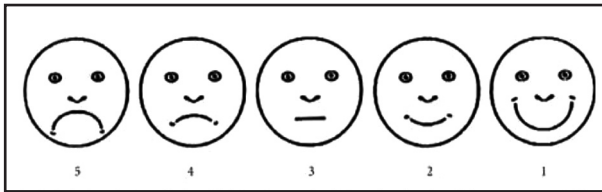


Fig. (1) Facial Image Scale (The scoring pattern for facial image scale was according to five different faces: 1 = no distress to 5 = severe distress)

Statistical analysis

The collected data were recorded, organized into tables, checked for normal distribution, and statistically analyzed by IBM SPSS version 20.0 software for Windows (SPSS, Chicago, IL, USA).

RESULTS

Concerning caries removal time, the study outcomes demonstrated a statistically significant difference in caries removal time, where the polymer bur was more time-consuming than the carbide bur, as shown in Table 1.

The two groups measured patient satisfaction with the procedures using the FIS. The FIS reported that the polymer bur group had a lower average score than the carbide bur group, with values of 1.4 ± 0.5 and 3.67 ± 0.89 , respectively. The difference between the two groups was statistically significant ($p \leq 0.05$) (Table 2).

Table (1) Comparison between both groups for caries removal time (seconds).

Groups	N	Min.	Max.	Mean \pm SD	T-test	P-value
Carbide bur group	15	310	410	363.20 ± 32.91	-7.9	0.001**
Polymer bur group	15	442	516	473.27 ± 28.41		

**; means significant difference between groups at P value <0.05

Table (2) Patient satisfaction with clinical procedures in both groups.

FIS	Groups				T-test	P-value
	Carbide bur (n = 15)		Polymer bur (n = 15)			
	n	%	n	%		
Very happy	0	0.0	9	60		
Happy	2	13.3	6	40		
Indifferent	3	20	0	0	-8.5	0.002**
Sad	8	53.4	0	0		
Very sad	2	13.3	0	0		
Mean \pm SD	3.67 ± 0.89		1.4 ± 0.3			

** P is statistically significant at level of < 0.05

DISCUSSION

The removal of dental caries and the duration of dental procedures have a strong effect on children's behavior and can produce high levels of anxiety and dental fear, especially among children⁽¹⁵⁾. Caries removal using a self-limiting and painless technique has garnered significant interest, particularly in pediatric dentistry. Therefore, the polymer bur has been introduced as a new tool in the dental market, claiming it is the optimal choice for selective caries removal and reducing patient discomfort^(4,10,16). The objective of this work is to evaluate the duration of caries removal and the level of pain experienced by patients during the excavation process using two distinct methods.

In this study, the children recruited ranged in age from 8 to 11 years old and could interact with and understand the FIS. A minimum age of 8 years was chosen for this study because the first permanent molars typically erupt or fully erupt by six years. Caries often develops and becomes clinically detectable within 1-2 years following their eruption⁽¹⁷⁻¹⁹⁾. Only children who received a rating of definitely positive or positive on the Frankl behavior rating scale were selected to participate in the study. This was performed to ensure that the children could accept the treatment and follow the dentist's instructions cooperatively⁽²⁰⁾. In this study, local anesthesia was not administered unless specifically requested by the patient. This approach aligns with the findings of Maarouf et al.⁽⁴⁾, who noted that injections are a major source of stress and anxiety in young children and can trigger pain. Additionally, avoiding anesthesia allows for a more objective assessment of pain perception.

Concerning the time required for complete caries removal, a digital stopwatch was used in this study as it represents simplicity, accuracy, and precision^(10,21). This study found that using a smart

polymer bur for caries removal took longer than using a conventional carbide bur. The difference in time was statistically significant. These results could be attributed to the recommended speed for carbide burs running at approximately 20,000 rpm, whereas it is 5,000–10,000 rpm for smart polymer burs⁽²²⁾. In addition, in most cases, more than one polymer bur was required to complete caries excavation; thus, more time was required⁽²³⁾.

These outcomes agree with those of Shakaya et al.⁽²⁴⁾ and Wahba et al.⁽¹⁰⁾, who attributed the long excavation time of the polymer bur to the instrument's path during the removal of infected dentin^(10, 24). The polymer bur works from the center and top of the lesion, progressively moving outward and downward and removing the layers of the lesion. Additionally, SmartBurs II is less hard than healthy dentin, causing it to become self-limiting and dull when in contact with healthy tooth structures. This necessitates the replacement of the bur with a new one to complete the removal of caries^(10, 11). A study proposed that the longer time required by SmartBurs II to remove caries may be due to the higher hardness (7,000 KHN) and greater cutting efficiency of the carbide bur when compared to the polymer bur, which has a hardness of only 50 KHN⁽²¹⁾.

Pain is a subjective experience that can be difficult to quantify; therefore, the FIS determined the patients' perception of the treatment procedure. This scale was chosen because it is easily understood and is appropriate for the age group chosen for this work. The findings of the current study regarding patient satisfaction revealed that patients treated with SmartBurs II experienced significantly less pain than those treated with a conventional carbide bur. This may be due to the cutting mode of SmartBurs II, which performs a minimally invasive excavation that is limited to the superficial layer of the affected

dentin. These findings are supported by similar results from previous studies^(25,26). There were some limitations of this study; difficulty of using polymer bur in small cavities as its easily touched enamel and the bur went blunt, also, many cases required using more than one polymer bur which increased the caries removal time, as well as the cost of the procedure.

CONCLUSION

The utilization of smart polymer burs requires an extended duration for the comprehensive removal of caries relative to conventional carbide burs. The smart polymer bur showed greater patient acceptance, as there was no need for local anesthesia, and the pain sensation was reduced during caries removal.

REFERENCES

- Matar MA, Samir R. Pain assessment during the removal of infected carious dentin using ceramic burs without local anesthesia in children. *Egy Dent J*. 2017; 63(3): 2131-2136.
- Murthy AK, Pramila M, Ranganath S. Prevalence of clinical consequences of untreated dental caries and its relation to dental fear among 12-15-year-old schoolchildren in Bangalore city, India. *EAPD*. 2014;15(1):45-49.
- Wide Boman U, Carlsson V, Westin M, Hakeberg M. Psychological treatment of dental anxiety among adults: a systematic review. *Eur J Oral Sci*. 2013;121(3):225-234.
- Maarouf R, Badr S, Ragab H. Clinical efficiency of polymer burs in caries removal in primary molars and relevant pain perception: A randomized controlled trial. *Int Arab J Dent*. 2018; 9, 9-14
- Anwar AS, Kumar RK, Prasad Rao VA, Reddy NV, Reshma VJ. Evaluation of microhardness of residual dentin in primary molars following caries removal with conventional and chemomechanical techniques: An In vitro Study. *J Pharm Bioallied Sci*. 2017;9:166-172.
- Kathuria V, Ankola AV, Hebbal M, Mocherla M. Carisolv- an innovative method of caries removal. *J Clin Diagn Res*. 2013;7(12):3111-3115.
- Meller C, Welk A, Zeligowski T, Splieth C. Comparison of dentin caries excavation with polymer and conventional tungsten carbide burs. *Quintessence Int*. 2007;38(7):565-569.
- Corrêa FN, Rocha Rde O, Rodrigues Filho LE, Muench A, Rodrigues CR. Chemical versus conventional caries removal techniques in primary teeth: a microhardness study. *J Clin Pediatr Dent*. 2007;31(3):187-192.
- Allen KL, Salgado TL, Janal MN, Thompson VP. Removing carious dentin using a polymer instrument without anesthesia versus a carbide bur with anesthesia. *JADA*. 2005;136(5):643-651.
- Wahba W, Sharaf A, Bakery N, Nagui D. Evaluation of polymer burs for carious dentin removal in primary teeth. *Azhar Dent J*. 2015;40(1):107-112.
- Frencken JE, Peters MC, Manton DJ, Leal SC, Gordan VV, Eden E. Minimal intervention dentistry for managing dental caries - a review: report of a FDI task group. *Int Dent J*. 2012;62(5):223-243.
- Shivasharan PR, Farhin AK, Wakpanjar MM, Shetty A. Clinical evaluation of caries removal in primary teeth using carie-care and SmartPrep burs: An in vivo study. *Indian J Dent Res*. 2016;2(1):27.
- Shetty RM, Khandelwal M, Rath S. RMS Pictorial Scale (RMS-PS): an innovative scale for the assessment of child's dental anxiety. *J Indian Soc Pedod Prev Dent*. 2015;33(1):48-52.
- Fathima F, Jeevanandan G. Validation of a facial image scale to assess child dental anxiety. *Drug Invent Today*. 2018;10:2825-2828.
- Jamali Z, Najafpour E, Ebrahim Adhami Z, Sighari Deljavan A, Aminabadi NA, Shirazi S. Does the length of dental procedure influence children's behavior during and after treatment? A systematic review and critical appraisal. *J Dent Res Dent Clin Dent Prospects*. 2018;12(1):68-76.
- Koruyucu M, Bayram M, Tuna EB, Gencay K, Seymen F. Clinical findings and long-term managements of patients with amelogenesis imperfecta. *Eur J Dent*. 2014;8(4): 546-552.

17. Lakhani B, Indushekar K, Garg S, Singh N, Tomer E. Behavior assessment using frankl rating scale and identification of personality in pediatric dental operator. *J Child Adolesc Psychopharmacol.* 2017;5(5):1-5.
18. Al-Samadani KH, Ahmad MS. Prevalence of first permanent molar caries in and its relationship to the dental knowledge of 9-12-year olds from jeddah, kingdom of saudi arabia. *ISRN Dent.* 2012;2012:1-6.
19. Alshiha SA, Alwayli HM, Hattan MA, Alfraih YK, Alamri AA, Aldossary M S. Prevalence of dental caries and fissure sealants in the first permanent molars among male children in Riyadh, kingdom of Saudi Arabia. *Int J Clin Pediatr Dent.* 2018;11(5):365-370.
20. Inamdar MS, Chole DG, Bakle SS, Gandhi NP, Hattte NR, Rao MP. Comparative evaluation of BRIX3000, CARIE CARE, and SMART BURS in caries excavation: An in vivo study. *J Conserv Dent.* 2020;23(2):163-168.
21. Somani R, Chaudhary R, Jaidka S, Singh DJ. Comparative Microbiological Evaluation after Caries Removal by Various Burs. *Int J Clin Pediatr Dent.* 2019;12(6):524-527.
22. Medioni E, Rocca JP, Fornaini C, Merigo E. Histological evaluation of three techniques for caries removal. *J Oral Sci.* 2016;58(4):583-589.
23. Hassan AF, Yadav G, Tripathi AM, Mehrotra M, Saha S, Garg N. A Comparative Evaluation of the Efficacy of Different Caries Excavation Techniques in reducing the Cariogenic Flora: An in vivo Study. *Int J Clin Pediatr Dent.* 2016;9(3):214-217.
24. Shakyia VK, Chandra A, Tikku AP, Verma P, Yadav RK. A comparative evaluation of dentin caries removal with polymer bur and conventional burs-An in vitro study. *Open J Stomatol.* 2012;2(01):12-15.
25. Kumar K, Prasad MG, Sandeep RV, Reddy SP, Divya D, Pratyusha K. Chemomechanical caries removal method versus mechanical caries removal methods in clinical and community-based setting: A comparative in vivo study. *Eur J Dent.* 2016;10(3):386-391.
26. Soni HK, Sharma A, Sood PB. A comparative clinical study of various methods of caries removal in children. *Eur Arch Paediatr Dent.* 2015;16(1):19-26.