



Clinical Effect of Mesenchymal Stem cell-Derived Microvesicles as Adjunctive Treatment to Surgery on Healing of Distal Limb Chronic Wounds in Arabian Horses

Marwa H. Hassan^{1,2}, Ahmed N. Abdallah³, Ashraf A. Shamaa² and Ashraf M. Abu-Seida^{4,2*}

¹ Department of Veterinary Clinical Sciences, Faculty of Veterinary Medicine, Jordan University of Science and Technology, Irbid, PO: 22110, Jordan.

² Department of Surgery, Anesthesiology and Radiology, Faculty of Veterinary Medicine, Cairo University, Giza PO: 12211, Egypt.

³ Hormones Department, Medical Research and Clinical Studies Institute, National Research Centre, Giza, Egypt

⁴ Galala University, Suez, Egypt.

Abstract

DISTAL limb wounds in horses account for more than 60% of all wounds. This study described the clinical effect of mesenchymal stem cell-derived microvesicles (MVs) on healing of equine distal limb chronic wounds. Twelve Arabian horses with distal limb granulating wounds (Group I, n=6) or ulcerated wounds (Group II, n=6) were treated surgically either by excision of the granulating masses or debridement of ulcers. In group I, the horses were divided randomly into two subgroups (3 horses each); subgroup 1 was given two doses of topical and subcutaneous injection of MVs after surgery. Subgroup 2 (control) was treated only by surgery. Group II was divided randomly into two equal subgroups; subgroup 1 was given one dose of topical and subcutaneous injection of MVs after surgery and subgroup 2 was treated by debridement (control). Healing progression was documented using digimizer image analysis software and data were statistically analyzed. The mean areas of the granulating and ulcerating wounds were 81.71±3.25 cm² and 18.91±1.78 cm², respectively. In group I, complete wound healing was achieved on days 70±3.5 and 100±4.32 in subgroups 1 and 2, respectively. However, complete wound healing was achieved in group II on days 27±2.3 and 41±3.1 in subgroups 1 and 2, respectively. There were statistically significant differences in wound area reduction between the two subgroups in both groups (P<.05). In conclusion, this preliminary study indicated that topical and subcutaneous injection of MVs after surgical interferences may enhance healing of the chronic wounds in distal limbs of horses.

Keywords: Chronic wound, Equine, Mesenchymal stem cell, Microvesicles, Regenerative medicine.

Introduction

The skin has thermoregulatory, protective, metabolic, sensory and many other important functions. Therefore, healthy skin is necessary for good health and treatment of skin wounds has a high priority to avoid several complications [1].

In equine practice, distal limb wounds are common and account for more than 60% of all wounds [2, 3]. These types of wounds are often more challenging to manage since the skin around the distal limb wound is more difficult to suture [2]. Moreover, owing to extensive tissue loss and

contamination, vascular supply and motion, healing of these wounds is usually delayed in comparison with that of proximal limb wounds [4, 5]. Therefore, open wounds at the distal extremities heal by secondary intention in most cases. In this type of wound healing, granulation tissue accumulates to fill the wound bed, followed by re-epithelialization and wound contraction [6, 7]. However, if the open wounds become infected, several complications like delayed healing, bone sequestration, over granulating

*Corresponding author: Ashraf M. Abu-Seida, E-mail: ashrafseida@cu.edu.eg Tel.: +201001997359

(Received 05/01/2024, accepted 04/03/2024)

DOI: 10.21608/EJVS.2024.260906.1767

©2024 National Information and Documentation Center (NIDOC)

tissue formation, scar tissue formation, and surrounding tissue infection may occur [8].

Several studies have been carried out to develop novel therapeutic alternatives for both horses and humans with non-healing skin wounds [3, 9-11]. Most of these studies focused on the promising clinical therapeutic using of stem cells for treatment of non-healing and recurrent immune-mediated skin diseases which have not responded to the conventional therapy [6, 12, 13].

Microvesicles (MVs) or exosomes are membrane vesicles that are released by many types of cells from the endosomal compartment or as shedding vesicles from the cell surface. MVs act as important mediators of cell-to-cell communication, promote self-repair and play crucial role in stem and injured tissue cells communication [14, 15]. Therefore, mesenchymal stem cell (MSC)-derived MVs significantly enhanced skin wound healing, collagen synthesis, and wound area revascularization in a dog model with full-thickness skin defects and exhibited rapid wound closure [16].

Considering the benefits of MSC-derived MVs in wound healing in experimental studies, MSC-derived MVs were applied in this preliminary study for the treatment of Arabian horses with distal limb chronic wounds. This prospective randomized controlled study evaluated the clinical effect of topical and subcutaneous infiltration of MSC-derived MVs on healing of distal limb chronic wounds in equine.

Material and methods

Ethical approval

This study was approved by the Animal Care and Use Committee at the Faculty of Veterinary Medicine, Cairo University (Vet-CU/12/10/2023/29), Egypt. All institutional and national guidelines regarding the care and use of animals were applied.

Animals

Twelve Arabian horses with chronic distal limb wounds were admitted to the surgery clinic at Faculty of Veterinary Medicine, Cairo University, Egypt. The age of the affected animals ranged between 3 and 5 years (mean 4.2 ± 0.3 year). The animals included 7 horses and 5 mares. Their body weight ranged between 350-380 kg (mean 365 ± 3.7 kg). All owners attempted conventional treatment with a systemic antibiotic (Procaine penicillin) for a week and daily dressing with Povidone iodine solution for 1.5- 2 months with unsatisfactory results.

A complete case history and thorough clinical examination were performed. A written consent was obtained from all owners before treatment. These horses were divided into two main groups (6 animals each) according to the nature of distal limb wounds.

Group I included horses with granulating wounds and group II included horses with ulcerative wounds

Surgical procedures

Food was withheld for 12 h before surgery. Animals were premedicated with intravenous Xylazine HCl (1.3 mg/kg) and anesthesia was induced with intravenous Thiopental sodium (6 mg/kg). Anesthesia was maintained with triple drip of one liter of 5% Guaiphenesin solution with Xylazine HCl (1 mg/mL) and Ketamine HCl (2 mg/mL) administered at 2 mL/kg/h [17]. All animals were prepared for aseptic excision of the granulating masses (group I) or debridement of the ulcerative lesions (group II). The excised masses were fixed in 10% formalin solution. Then, histopathology sections were prepared, stained with hematoxylin and eosin (H&E) stain as well as examined under a light microscope.

Postoperative treatment and follow up

Postoperatively, topical Fusidic acid cream (Fucidin cream 2%[®], Leo Laboratories Limited, USA) was applied in all animals, followed by pressure bandage application for 7 days. Antitetanic serum (3,000 IU) was subcutaneously administered in all animals. Penicillin–streptomycin combination (Penstrep[®], Kepro B.V., Netherlands) was injected intramuscularly once daily at doses of 10,000 IU penicillin/kg and 10mg streptomycin/kg, for 5 days. Intravenous Phenylbutazone (Phenylbutazone 20% injection, Aspen co., Durban, South Africa) was administered as initial dose of 8 mg/kg at the first day, and then continued at a dose of 4 mg/kg once daily for 3 successive days as an anti-inflammatory drug.

After 7 days of surgery, the animals in each group were further subdivided randomly into two subgroups (3 animals each) according to the treatment after surgery. Subgroup 1 (Surgery + MVs) in both groups received topical and subcutaneous infiltration of MVs around periphery of the wounds after one week of surgery. However, the wounds in subgroup 2 (control) in both groups were dressed with a thin layer of inert hydrogel (Polyethylene glycol) and given 4 mL subcutaneous infiltration of sterile distilled water around periphery of the wounds. The wounds were covered by Mepore sterile dermal patches (Molnlycke[®] Health Care, Sweden) and protective bandage. The bandage was changed in 5-day intervals and the wounds were dressed with Povidone iodine solution only until complete wound healing.

In group I, an amount of 3gm of powdered heterogenic lyophilized MSC-derived exosomal solution (Bioluga[®], Canada) was applied to the clean wound surface at day 7 after surgery in subgroup 1. The exosomal solution was prepared following the protocol developed before [16]. The lyophilized

product was reconstituted in 8 mL sterile water for injection and mixed well until a homogenous gel solution was obtained. Half the dose (4 mL) was infiltrated subcutaneously in 8 points using a 14 gauges needle (16 mm length) at 0.5 cm from the periphery of the wound, and the other half was applied as a topical dressing. The wounds were covered by Mepore sterile dermal patches and protective bandage. A second dose of MVs solution was repeated by the same protocol after four weeks of the first dose. The bandage was changed after one week of the first exosomal treatment and in 5-day intervals thereafter. Dressing with Povidone iodine solution was performed until complete wound healing was achieved.

In group II, the ulcerated wounds in subgroup 1 received a single dose of topical and subcutaneous infiltration of MVs as mentioned before on day 7 after the surgery. The wounds were covered by Mepore sterile dermal patches and bandage. The bandage was changed after one week of the exosomal treatment and in 5-day intervals thereafter. Dressing with Povidone iodine solution was performed until complete wound healing was achieved.

Healing progression in all animals was documented using digimizer image analysis software (Belgium) through wound measurement by two examiners who were blinded to the study design.

Statistical analysis

All data were reported as mean and standard deviation (SD). Independent sample t-test was used for comparison of reduction in wound area between the two subgroups in each group. A repeated measure ANOVA with a Greenhouse-Geisser correction was performed to compare the effect of MVs on the wound area reduction through different time points. Data were analyzed using PASW statistics, version 18.0 software (SPSS Inc., Chicago, IL, USA). Statistical significant was considered at $P \leq 0.05$

Results

All wounds were present at the fetlock and pastern regions. The etiology of all wounds was trauma since 2 to 3 months. Horses with granulating wounds suffered from pain, slight lameness, restlessness and anorexia. These horses had multiple lobulated granulating masses mainly at the caudal aspects of the fetlock and pastern regions (Fig. 1). The wounds' areas (cm^2) after surgery in both groups and subgroups are shown in Table (1).

Histopathological examination of the excised masses revealed overgranulating tissue. The granulation tissue had well-organized condensed fibrous tissue with newly formed blood vessels and inflammatory cell infiltration (Fig. 2a). Hyperplasia

and migration of epidermal cells were also observed (Fig. 2b).

In group I (Granulating wounds), the mean area of the granulating wounds in the examined horses after the surgery was $81.71 \pm 3.25 \text{ cm}^2$ (Fig. 3a). After 7 days the wounds became clean and ready for treatment with MVs in subgroup 1 (Fig. 3b). Stages of wounds' healing following surgical excision of the granulating tissues and using of double doses of exosomal solution of MVs are shown in Figures 3c-e and table (1). Finally, the wounds healed completely with scar tissue formation on day 70 ± 3.5 (Fig. 3f). Marked reduction in the wound area was observed in the affected horses and complete wound healing with scar tissue formation was achieved in group I on days 70 ± 3.5 and 100 ± 4.32 in subgroups 1 and 2, respectively. In subgroup 2 (control subgroup), there was marked delayed healing in the wounds of all horses (Fig. 4). There was statistically significant difference in wound healing between both subgroups 1 and 2 ($P < .05$). Also, there were statistically significant differences in wound area reduction along different time points in both subgroups of group I ($P < .05$).

In group II (Ulcerating wounds), the wounds were circular, necrotized, and ulcerated. The mean area of ulcerative wounds in the examined horses was $18.91 \pm 1.78 \text{ cm}^2$ (Fig. 5a). The stages of wound healing in horses with ulcerative wounds treated by surgical debridement and MVs applications are illustrated in Figure 5 and table (1). Complete wound healing following a single dose of MVs treatment was achieved with scar tissue formation on day 27 ± 2.3 (Fig. 5d). Complete wound healing in the affected horses was achieved on days 27 ± 2.3 and 41 ± 3.1 in subgroups 1 and 2, respectively. In subgroup 2 (control subgroup), there was marked delayed healing in the wounds of all horses (Fig. 6). There was statistically significant difference in wound healing between subgroups 1 and 2 ($P < .05$). Also, there were statistically significant differences in wounds' area reduction along different time points for the horses with ulcerating wounds in both subgroups ($P < .05$).

Discussion

Distal limb wounds in horses are often more problematic than wounds located elsewhere owing to their proximity to the ground, making them more likely to become contaminated and infected. Moreover, the skin in the distal portion of the limb is poorly vascularized compared with that located elsewhere on the horse's body [18]. This preliminary study indicated that topical and subcutaneous injection of MVs after surgical interferences may enhance healing of the chronic wounds in distal limbs of horses.

Surgical debridement of the wounds facilitates fast neovascularization and fibroblast growth, which are the basis for the production of collagen and other components of the extracellular matrix and tissue regeneration [18, 19]. Therefore, all horses in the present study were treated with either surgical excision of the overgranulating tissue or debridement of the ulcerative wounds

Granulation tissues formation is an essential process in successful chronic skin wound healing that is created by fibroblasts, which are composed of type III collagen. Granulation tissue has a significant role in filling the wound space, forming a barrier between the body and external contaminants, and serving as support for cells that contribute to wound repair [19-21]. New blood capillaries are formed by endothelial cells in the granulation tissue. In case of chronic low-grade inflammation and fibroproliferative disorders, excessive granulation tissue deposition occurs and it is called proud flesh or exuberant granulation tissue (EGT). It is characterized by visually irregular with a pebbled, moist surface protruding beyond the wound margins, making it susceptible to abrasions, secondary infections, and reinjures and may delay or inhibit the migration of epidermal and epithelial cells and keratinocytes; furthermore, it may lead to the lack of wound closure [12], which was observed in the present study.

In the current study, horses with granulating wounds suffered from pain and loss of mobility due to the presence of wounds. These findings are consistent with the results of earlier workers [22].

The distal limb wounds reported here did not show complete healing despite several therapies were tried for 1.5 to 2 months; the horses were associated with extremely high rates of recurrence as these wounds have no effective treatment regimen. Similar findings were recorded before [23]. For this reason, treatment alternative by using MVs or exosomes was tried for the treatment of non-healing chronic wounds in the presented horses. In the first step of the treatment protocol, surgical excision of EGT was performed to rapidly improve granulation tissue formation and promote wound contraction.

Exosomes are one of the many secretory factors released by MSCs and have been described as the most important and effective components [16, 24, 25]. Therefore, exosomes are considered important mediators of cell-to-cell communication [14, 15]. Exosomes may act as paracrine or endocrine mediators that interact with neighboring cells, modulate immune responses, promote self-repair from cells that survive injury, and play an important role in stem and injured tissue cell communication [14, 15].

The wound area was calculated by using a digimizer considering that the wound has irregular wound edges, with no accurate length and width. The

mean wound area in the examined horses with granulating wounds started from 81.71cm² to complete disappearance with scar tissue formation when the wound area was 0 due to MSC-derived exosomal treatment that significantly enhanced wound reduction. Due to the large wounds' area, two doses of MVs with four weeks in between were given to enhance complete healing. The gross evaluation of wounds revealed early and better wound contraction as well as closure. Early crustation and deposition of healthy granulation tissues resulted in complete wound healing and skin regeneration. Thus, this study showed better and faster healing of the MVs-treated wounds throughout the 70-day treatment period. In contrast, these wounds have not healed before the MVs treatment or with traditional methods.

Moreover, MVs did not only enhance wound reduction but also compensated tissue loss. After the second dose of MVs treatment, the wounded area became 0 after 70±3.5 days, and scar tissue formation covered the entire gap. Conversely, the ulcerative wound in the examined horses did not require a second dose of MVs treatment because the healing completely occurred with scar tissue formation on day 27±32.3.

Based on the available literature, exosomes are proven to exert an important mechanisms for cutaneous wound healing, including proangiogenic effects (promote angiogenesis and enhance tubular formation), activating wound healing pathways, and promoting growth factor secretion and collagen synthesis [16, 26, 27]. Moreover, exosomes compensate for the tissue loss in the wound area.

The main limitation of this study is the small population of the horses and future studies on large numbers of horses are recommended. Moreover, Histopathology studies on wound healing after application of mesenchymal stem cell – derived MVs are suggested in the future.

Conclusion

The topical application with subcutaneous infiltration of MVs enhances the chronic wound healing in distal limbs of Arabian horses after surgical interference.

Author contribution

AAS and AMA planned and designed the research as well as carried out the surgeries. MHH followed the clinical process and collected the data. ANA analyzed the histology of the samples. All authors discussed the results, wrote the manuscript and approved the final version of manuscript.

Funding statement

The authors declare that no funds, grants, or other support were received during the preparation of this manuscript

Data availability statement

All data generated or analyzed during this study were included in this published article.

Declarations**Ethics approval**

All institutional and national guidelines regarding the care and use of patients were followed.

Conflict of interest

The authors declare no competing interests.

Publication consent

Informed consent was obtained from the horses' owners included in the study.

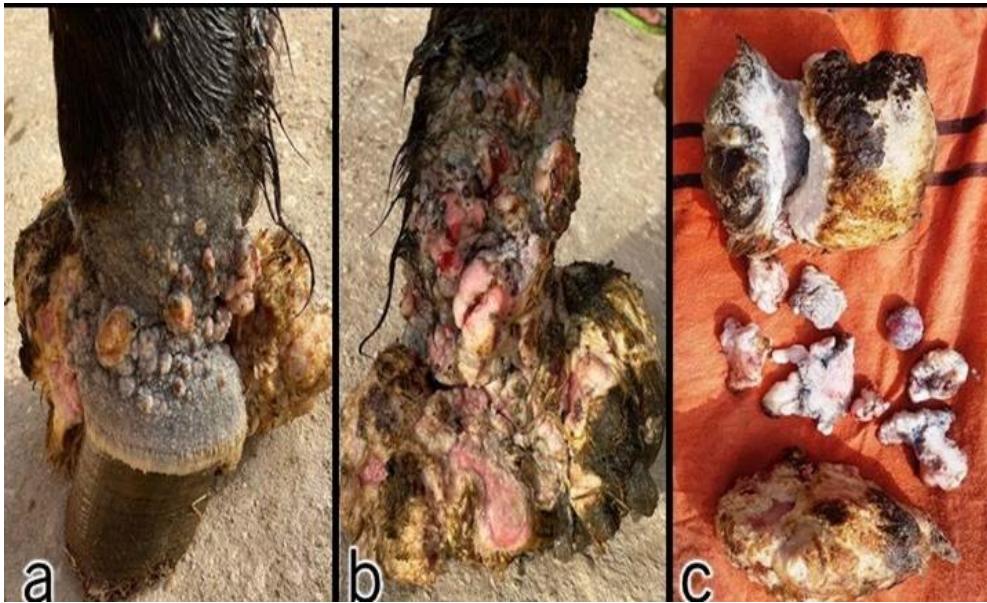


Fig. 1. (a, b) Granulating wounds at the fetlock and pastern regions in two Arabian horses. (c) The excised granulating masses after the surgery.

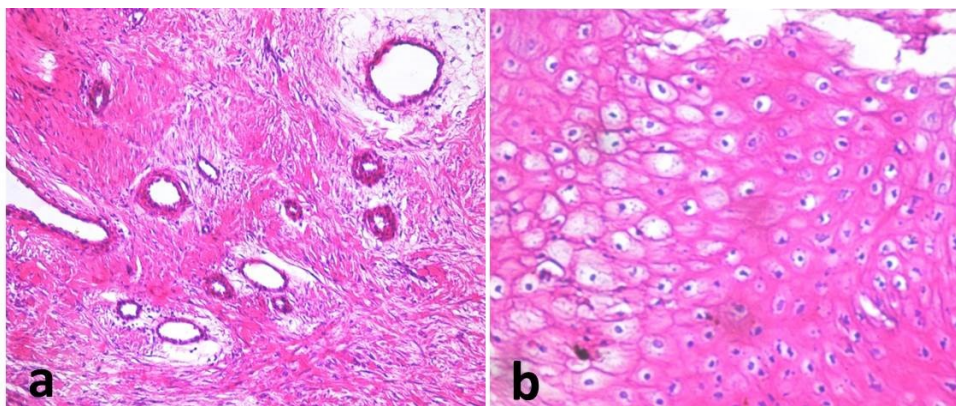


Fig. 2. (a) Photomicrograph of the excised granulation tissue showing well-organized condensed fibrous tissue, newly formed blood vessels and inflammatory cell infiltration (20X, H&E). (b) Photomicrograph of the excised granulation tissue showing hyperplasia and migration of epidermal cells (40X, H&E).

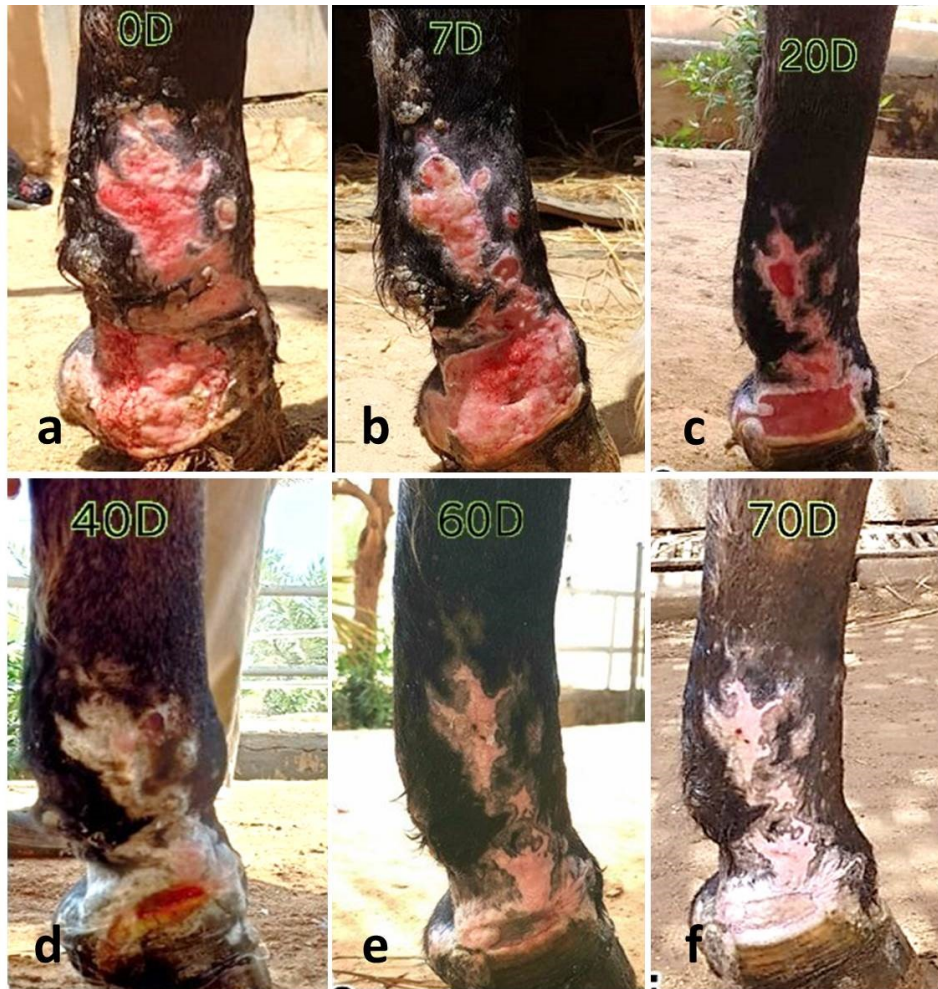

Fig. 3. (a) Granulating wound after surgical excision of the over granulating masses on day 0 in a 5-year-old Arabian stallion. (b) Clean wound ready for the first dose exosomal solution of MVs treatment on day 7. (c-e) Showing different stages of wound healing following exosomal solution of MVs treatment on days 20, 40 and 60. (f) Showing complete wound healing with scar tissue formation on day 70.

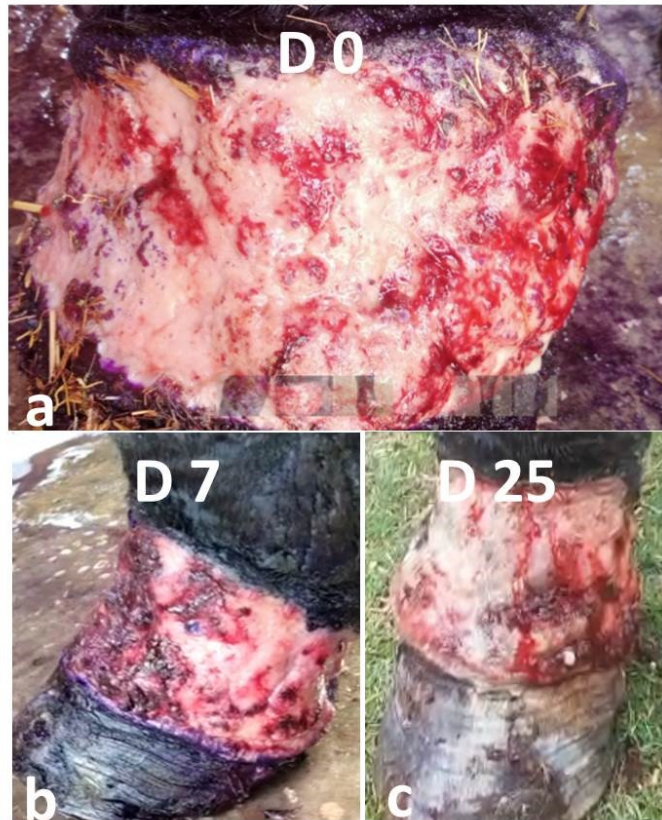


Fig. 4. (a) Granulating wound at the pastern region of a 4-year-old mare in subgroup 2. The same wound after 7 days (b) and 25 days of surgical excision of the overgranulating masses showing delayed wound healing (c).

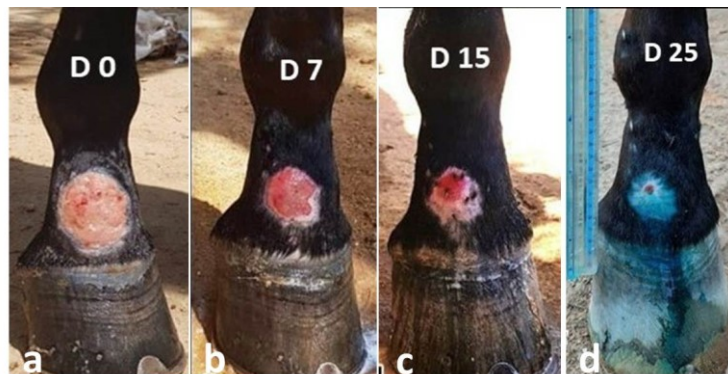


Fig. 5. (a) Ulcerated wound in a 6-year-old Arabian mare before surgical debridement. (b) Clean wound ready for treatment with MVs on day 7. (c) Showing the wound healing on day 15 following MVs treatment. (d) Nearly complete wound healing with scar tissue formation on day 25.

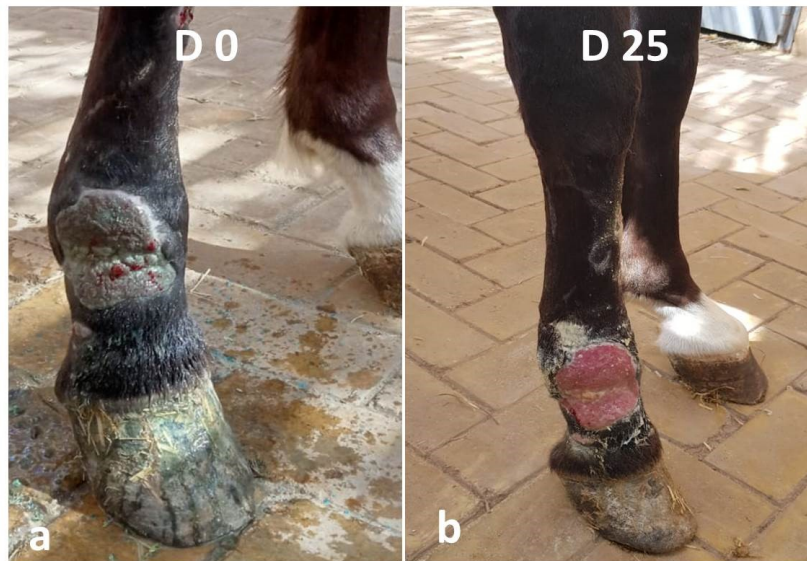

Fig. 6. (a) Ulcerated wound at the fetlock and pastern regions of a 3-year-old stallion in subgroup 2. The same wound after 25 days of surgical debridement showing delayed wound healing (b).

References

- Proksch, E., Brandner, J.M. and Jensen, J.M. The skin: an indispensable barrier. *Exp. Dermatol.*, **17**, 1063-1072(2008). <http://pubmed.ncbi.nlm.nih.gov/19049850/>
- Harman, R.M., Theoret, C.L. and Van de Walle, G.R. The horse as a model for the study of cutaneous wound healing. *Adv. Wound Care.*, **10**(7), 381-399 (2019). <https://doi.org/10.1089/wound.2018.0883>
- Sparks, H.D., Sigaeva, T., Tarraf, S., Mandla, S., Pope, H. and Hee, O. Biomechanics of wound healing in an equine limb model: Effect of location and treatment with a peptide-modified collagen-chitosan hydrogel. *ACS Biomater. Sci. Eng.*, **7**, 265-278 (2021). doi.org/10.1021/acsbiomaterials.0c01431
- Caston, S.S. Wound care in horses. *Vet. Clin. North Amer. Equine Pract.*, **28** (1), 83-100 (2012). <http://doi:10.1016/j.cveq.2012.01.001>.
- Heyer, K., Herberger, K., Protz, K., Glaeske, G. and Augustin, M. Epidemiology of chronic wounds in Germany: analysis of statutory health insurance data. *Wound Repair Regen.*, **24**, 434-442 (2016). <http://doi:10.1111/wrr.12387>.
- Theoret, C. Tissue engineering in wound repair: the three "R"s repair, replace, regenerate. *Vet. Surg.*, **38**, 905-913 (2009). [http:// DOI: 10.1111/j.1532-950X.2009.00585.x](http://DOI:10.1111/j.1532-950X.2009.00585.x)
- Helal, I.E., Al-Abadi, H.A., El-Daharawy, M.H. and Ahmed, M.F. Enhancement of chronic wound healing with maltodextrin/ascorbic acid gel: A clinical evaluation of distal limb wounds in horses. *J. Anim. Sci. Technol.*, **64**(5), 997-1007 (2022). [doi: 10.5187/jast.2022.e52](https://doi.org/10.5187/jast.2022.e52)
- Provost, P.J. Wound Healing. In: Auer JA, Stick JA (ed). *Equine Surgery* (4th ed.), Saint Louis: W.B. Saunders, pp, 47-61 (2012).
- Solea, A., Bolwellb, C., Darta, A., Riley, C. and Theoret, C. Descriptive survey of wounds in horsparkses presented to Australian veterinarians. *Aust. Equine Vet.*, **34**, 68-74 (2015).
- Theoret, C.L., Bolwell, C.F., Riley, C.B. A cross sectional survey on wounds in horses in New Zealand. *New Zealand Vet. J.*, **64**, 90-94 (2016). [http://DOI: 10.1080/00480169.2015.1091396](http://DOI:10.1080/00480169.2015.1091396)
- Hassan, M.H., Abd El-Rahman, S.S., Amer, M.S., Fahmy, H.M. and Shamaa, A.A. Effect of lyophilized growth factors (LGF) derived from equine platelets on experimentally induced skin wound healing in mongrel dogs. *Int. J. Vet. Sci.*, **10**(2), 75-82 (2021). <https://doi.org/10.47278/journal.ijvs/2020.012>
- Theoret, C. Innovative adjunctive approaches to wound management. In: Theoret C, Schumacher J, (ed). *Equine wound management*. 3rd edition. Ames (IA): Wiley; pp, 508-539 (2017).
- Mizuno, H. Adipose-derived stem cells for tissue repair and regeneration: ten years of research and a literature review. *J. Nippon Med. Sch.*, **76**(2), 56-66 (2009). [http:// DOI: 10.1272/jnms.76.56](http://DOI:10.1272/jnms.76.56)

14. Camussi, G., Deregibus, M.C. and Cantaluppi, V. Role of stem-cell-derived microvesicles in the paracrine action of stem cells. *Biochem. Soc. Trans.*, **41**, 283-287 (2013). [http:// DOI: 10.1042/BST20120192](http://doi.org/10.1042/BST20120192)
15. Yu, B. and Zhang, X., Li, X. Exosomes derived from mesenchymal stem cells. *Int. J. Mol. Sci.*, **15**, 4142-4157 (2014). <https://doi.org/10.3390/ijms15034142>
16. El-Tookhy, O.S., Shamaa, A.A., Shehab, G.G., Abdallah, A.N. and Azzam, O.M. Histological evaluation of experimentally induced critical size defect skin wounds using exosomal solution of mesenchymal stem cells derived microvesicles. *Int. J. Stem Cells*, **10** (2), 144-153 (2017). [http://doi: 10.15283/ijsc17043](http://doi:10.15283/ijsc17043)
17. Vullo, C., Carluccio, A., Robbe, D., Meligrana, M., Petrucci, L. and Catone, G. Guaiphenesin-ketamine-xylazine infusion to maintain anesthesia in mules undergoing field castration. *Acta Vet. Scand.*, **59**, 67 (2017). doi: 10.1186/s13028-017-0335-7
18. Schumacher, J. and Stashak, T.S. Management of wounds of the distal extremities. In: Theoret C, Schumacher J (ed). *Equine wound management*, 3rd edition. Wiley –Blackwell, 312-351 (2016).
19. Rodeheaver, G. Wound cleansing, wound irrigation, wound disinfection. In: Krasner D, Rodeheaver G, Sibbald G (ed). *Chronic Wound Care*, 3rd edn. HMP Communications: Wayne, pp, 371 (2001).
20. Gurtner, G.C., Werner, S., Barrandon, Y. and Longaker, M.T. Wound repair and regeneration. *Nature*, **453**, 314-321 (2008). [http:// doi 10.1038/nature07039.20](http://doi10.1038/nature07039.20).
21. Gonzalez, A.C. de O., Costa, T.F., Andrade, Z. de A. and Medrado, A.R.A.P. Wound healing: A literature review. *An. Bras. Dermatol.*, **91**, 614-620 (2016). [http:// doi: 10.1590/abd1806-4841.2016474121](http://doi10.1590/abd1806-4841.2016474121).
22. Bock, O., Schmid-Ott, G., Malewski, P. and Mrowietz, U. Quality of life of patients with keloid and hypertrophic scarring. *Arch. Dermatol. Res.*, **297**, 433-438 (2006). <https://doi.org/10.1007/s00403-006-0651-7>.
23. Gauglitz, G.G., Korting, H.C., Pavicic, T., Ruzicka, T. and Jeschke, M.G. Hypertrophic scarring and keloids: pathomechanisms and current and emerging treatment strategies. *Mol. Med.*, **17**, 113-125 (2011). [http://doi: 10.2119/molmed.2009.00153](http://doi:10.2119/molmed.2009.00153).
24. Tögel, F., Weiss, K., Yang, Y., Hu, Z., Zhang, P. and Westenfelder, C. Vasculotropic, paracrine actions of infused mesenchymal stem cells are important to the recovery from acute kidney injury. *Am. J. Physiol. Renal Physiol.*, **292**, F1626-F1635 (2007). [http://doi: 10.1152/ajprenal.00339.2006](http://doi:10.1152/ajprenal.00339.2006)
25. Rani, S., Ryan, A.E., Griffin, M.D. and Ritter, T. Mesenchymal stem cell-derived extracellular vesicles: toward cell-free therapeutic applications. *Mol. Ther.*, **23**, 812-823 (2015). [http:// doi: 10.1038/mt.2015.44](http://doi10.1038/mt.2015.44).
26. Shabbir, A., Cox, A., Rodriguez-Menocal, L., Salgado, M. and Badiavas, E. Mesenchymal stem cell exosomes induce proliferation and migration of normal and chronic wound fibroblasts, and enhance angiogenesis in vitro. *Stem Cells Dev.*, **24**, 1635-1647 (2015). [http://doi: 10.1089/scd.2014.0316](http://doi10.1089/scd.2014.0316)
27. Zhang, J., Guan, J., Niu, X., Hu, G., Guo, S., Li, Q., Xie, Z., Zhang, C. and Wang, Y. Exosomes released from human induced pluripotent stem cells-derived MSCs facilitate cutaneous wound healing by promoting collagen synthesis and angiogenesis. *J. Transl. Med.*, **13**, 49 (2015). [http://doi: 10.1186/s12967-015-0417-0](http://doi10.1186/s12967-015-0417-0).

التأثير السريري للحويصلات الدقيقة كعلاج مساعد للجراحة في شفاء الجروح المزمنة في الأطراف السفلي في الخيول العربية

مروة حمدي حسن^{1,2}، أحمد نور عبد الله³، أشرف على الدسوقي شمعة² وأشرف محمد عبد الرحمن أبو سعده^{2,4}

1 كلية الطب البيطري - جامعة العلوم والتكنولوجيا الأردنية - اربيد - الاردن.

2 قسم بالجراحة و التخدير و الأشعة - كلية الطب البيطري - جامعة القاهرة- الجيزة - مصر.

3 قسم الهرمونات - معهد البحوث الطبية والدراسات السريرية - المركز القومي للبحوث - الجيزة - مصر.

4 جامعة الجلالة - السويس - مصر.

تمثل الجروح السفلية في أطراف الخيول أكثر من 60% من جميع الجروح. عادة ما يتأخر شفاء هذه الجروح مقارنة بشفاء الجروح العلوية في الأطراف. تصف هذه الدراسة العشوائية المعماة التأثير السريري للإستخدام الموضعي و تحت الجلد للحويصلات الدقيقة المشتقة من الخلايا الجذعية الوسيطة (MVs) على شفاء الجروح المزمنة في الأطراف السفلية في الخيول. تم علاج اثني عشر حصاناً عربياً مصاباً بجروح مزمنة في الأطراف السفلية جراحياً إما عن طريق استئصال الكتل الحبيبية أو التنضير. تم تقسيم الخيول ذات الجروح الحبيبية (عددها = 6 حيوانات) بشكل عشوائي إلى مجموعتين (3 خيول لكل منهما)؛ أعطيت المجموعة 1 جرعتين من الإستخدام الموضعي و تحت الجلد من MVs حول الجرح بعد أسبوع و 5 أسابيع من الجراحة. تم تقديم المجموعة 2 كعنصر تحكم. بينما تم تقسيم الخيول المصابة بالجروح القرحة (عددها = 6 حيوانات) عشوائياً إلى مجموعتين متساويتين؛ أعطيت المجموعة 1 جرعة واحدة من الإستخدام الموضعي و تحت الجلد من MVs بعد أسبوع واحد من الجراحة و تم تقديم المجموعة 2 كمجموعة تحكم. تم توثيق تطور الأفة في جميع الحيوانات باستخدام برنامج تحليل الصور الرقمي وتم تحليل البيانات إحصائياً. بلغ متوسط مساحات الجروح الحبيبية و القرحة في الخيول المفحوصة 3.25 ± 81.71 سم² و 1.78 ± 18.91 سم² على التوالي. لوحظ انخفاض ملحوظ في الجروح الحبيبية ومساحتها و تم تحقيق التئام كامل للجروح مع تكوين أنسجة ندبية في الأيام 70 ± 3.5 و 100 ± 4.32 في المجموعتين 1 و 2 على التوالي. ومع ذلك، تم تحقيق التئام كامل للجروح في الخيول المصابة بجروح متقرحة في الأيام 27 ± 2.3 و 41 ± 3.1 في المجموعتين 1 و 2 على التوالي. كانت هناك فروق ذات دلالة إحصائية في تقليل مساحة الجرح بين المجموعتين في كلا النوعين من الجروح ($P < 0.05$). في الختام، أشارت هذه الدراسة الأولية إلى أن إستخدام الحويصلات الدقيقة المشتقة من الخلايا الجذعية الوسيطة (MVs) بعد التدخلات الجراحية قد تعزز شفاء الجروح السفلية المزمنة في أطراف الخيول.

الكلمات الدالة: الخيول، الحويصلات الدقيقة، الطب التجديدي، الخلايا الجذعية، الجروح المزمنة.