

# A report on how we managed a displaced bur in the maxillary sinus.

Case  
Report

*Reda FADEL , Mohamed AFELLAH , Mohamed Nouredine ELAMINE  
ELALAMI , Dounia KAMAL.*

*Oral and maxillofacial surgery departement, CHU HASSAN II, USMBA, FEZ*

## ABSTRACT

In the field of oral surgery, complications are common, however the displacement of a bur in the maxillary sinus is a rare entity. The occurrence of such a displacement and how to manage it is a real challenge to the oral surgeon that may lead to anxiety and loss of trust in the practitioner. We report a rare case of a bur displacement in the maxillary sinus that was referred to us by a private practice dentist. We describe the surgical technique we used to extract it. Existing literature outlines cases involving the displacement of teeth, dental implants, and dental materials into the maxillary sinus, with treatment options including endoscopic, Caldwell-Luc or alveolar surgical approach . In this case the extraction of the displaced bur was through an alveolar approach and was performed after the bur was precisely located on a CT scan . The follow up examinations were uneventful, and the patient was happy about the outcome .

**Key Words:** bur, displaced, maxillary sinus, foreign body, extraction

**Received:** 25 January 2024, **Accepted:** 2 February 2024.

**Corresponding Author:** Reda FADEL , Oral and maxillofacial surgery departement, CHU HASSAN II, USMBA, FEZ,

**Mobile:** 00212 667158326, **E-mail:** reda.fadel@usmba.ac.ma

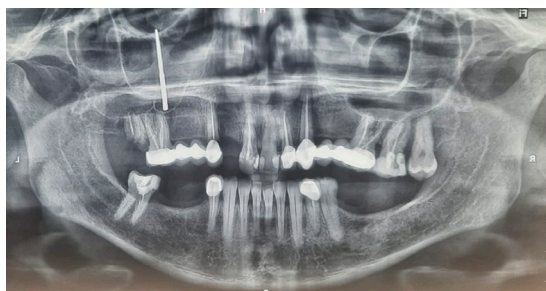
**ISSN:** 2090-097X, January 2024, Vol. 15, No. 1

## INTRODUCTION

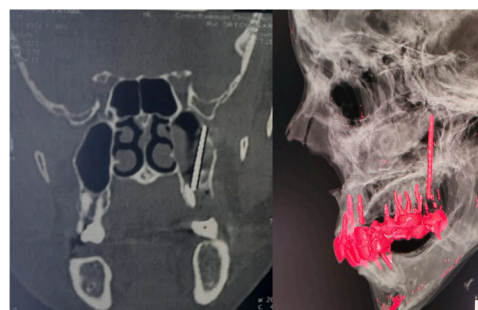
In the realm of oral surgery, precision and meticulous care are paramount. However, even with the most skilled hands and advanced techniques, unexpected complications can arise, adding a layer of complexity to the delicate art of surgical procedures. One such intricate challenge that surgeons may encounter is the displacement of surgical burs into the maxillary sinus. <sup>[1,4]</sup>

## CASE REPORT

We report the case of a 42 year old female, that was referred to our department by a private practice dentist. The patient is a non smoker, with no history of osteoporotic disease nor cocaine use. She presented to her dentist with a chief complain of pain on her left maxillary second molar (27). Once the dentist started drilling to try and separate the remaining roots, the poorly attached bur slipped in the maxillary sinus. After several attempts to retrieve the bur only resulting in displacing it deeper, he carried out an orthopantomogram (**Figure 1**).

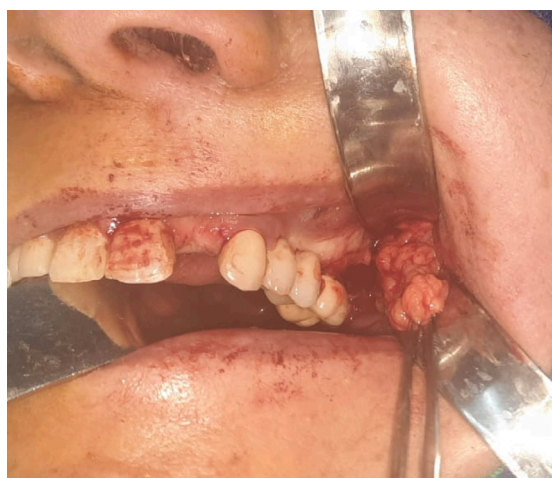

One day after the displacement we received a very concerned patient. Upon initial examination no functional disability was discovered, sight, and sensory innervation were preserved, and no infectious complication was detected. We could not visually locate the bur while the roots were still in place. After the initial assessment, we put the patient on antibiotics to prevent sinusitis and cellulitis, we reassured her about her functional abilities integrity, and performed a CT scan so we can precisely locate the displaced bur (**Figure 2**).



The following day we proceeded to retrieve the bur under general anesthesia. First we started by an alveolar approach, a crestal incision prolonged by a sulcular syndesmotomy and flap elevation. We then separated the roots and proceeded to their avulsion. A centimetric tear in the sinus mucosa was discovered, and the proximal end of the bur was located. We retrieved the bur by

cautious traction, making sure not to push it forward. (Figure 3) We then elevated a BICHAT fat pad flap and transposed it to fix the oroantral communication. Finally the mucosa was closed using 30- VICRYL. (Figure 4). Follow up after one week, one month, and 6 months was uneventful. The patient healed well, with no functional complication and with a perfectly airtight closed mucosa.



#### DISCUSSION:

The maxillary sinus, situated in the upper jawbone, plays a crucial role in maintaining the structural integrity of the facial skeleton.

While the inadvertent displacement of foreign bodies into the maxillary sinus is a common complication in dental practice, the occurrence of surgical bur displacement is relatively rare. The ramifications can lead to unique complications, such as sinusitis and foreign body reactions, necessitating prompt removal. Reports have highlighted instances of foreign bodies entering the maxillary sinus through an oroantral fistula, as well as delayed retrieval of a displaced maxillary third molar from infratemporal spaces. Existing literature outlines cases involving the displacement of teeth, dental implants, and dental materials into the maxillary sinus, with treatment options including endoscopic, Caldwell-Luc or alveolar surgical approach, though the specifics of the Caldwell-Luc procedure for surgical bur removal are often not detailed.

In our case the extraction of the displaced bur was through an alveolar approach and was performed after the bur was precisely located on a CT scan. The approach to retrieve the bur must be well thought and the least invasive possible. If an alveolar approach is possible it is the preferred one, otherwise an endoscopic approach with the help of an ENT colleague is chosen. The classical CALDWELL-LUC approach is performed if for size or anatomical considerations the endoscopic retrieval is difficult or impossible. [2-6]

#### CONCLUSION

The occurrence of displaced burs in the maxillary sinus is a rare complication in oral and dental surgery, it is surpassed by implants and dental filling displacement. However a meticulous examination and precise location of the bur must be carried out before retrieval is attempted. Communication with the patient is key, we must accompany him through out the process explaining every step, technique, possible outcome, and complication. An educated and compliant patient is the first step to a good treatment and in fine for the best outcome possible.

#### CONFLICTS OF INTEREST

The authors declare that there are no conflicts of interest.

#### REFERENCES:

1. Gómez-Oliveira G, Arribas-García I, Alvarez-Flores M, Gregoire-Ferriol J, Martínez-Gimeno C. Delayed removal of a maxillary third molar from the infratemporal fossa. *Med Oral Patol Oral Cir Bucal*. 2010;5(3):e50911.
2. Guo Y, Xu DD, Lv K, Wan QL, Li ZB, Li Z. Use of Computer-Assisted Navigation in the Retrieval of Accidentally Displaced Third Molars. *J Oral Maxillofac Surg*. 2016;74(5):889-94.
3. Nogami S, Yamauchi K, Tanuma Y, Odashima K, Matsui A, Tanaka K, et al. Removal of dental implant displaced into maxillary sinus by combination of endoscopically assisted and bone repositioning techniques: a case report. *J Med Case Rep*. 2016; doi: 10.1186/s13256-015-0787-1.
4. Kim, Y. J., da Silva, A. M. B., Perez, M. D. A., Marão, H. F., & Pallos, D. (2018). Removal of dental surgical bur from maxillary sinus: a case report. *Brazilian Journal of Oral Sciences*, 17, e18224-e18224.
5. R. Aduri, R. E. Reddy, and K. Kiran, "Foreign objects in teeth: retrieval and management," *Journal of Indian Society of Pedodontics and Preventive Dentistry*, vol. 27, no. 3, pp. 179–183, 2009.
6. Plascencia, H., Cruz, A., Solís, R., Díaz, M., & Vázquez, J. (2014). Iatrogenic displacement of a foreign body into the periapical tissues. *Case Reports in Dentistry*, 2014.