

Primary Cutaneous Ewing Sarcoma of the Scalp – A Case report

MOHAMMED YOUSSEF NAJI , ANOUAR TITOU , MOHAMMED NOUREDDINE EL ALAMI , KAMAL, DOUNIA

**Case
Report**

Hassan II University Hospital Center of Fez

ABSTRACT

1.Introduction. - Ewing sarcoma is a tumour in children and young adults that usually starts in the bone. Extraskelatal Ewing sarcoma is rare, and its cutaneous localization is exceptional. We report a new case of primary cutaneous Ewing sarcoma.
2.Observation. - A 22-year-old man was presented for a skin tumor on the scalp that had been evolving for six months. MRI showed a tumor process of the left occipital region of the scalp without bony involvement of the cranial vault or endocranial extension. The patient underwent a biopsy. Histopathological examination showed round mesenchymal cells expressing CD99. The treatment was extended surgical excision, chemotherapy and radiotherapy.
3.Discussion. – Cutaneous Ewing sarcoma is a rare pathology, difficult to diagnose even from an anatomopathological point of view. Confirmation of the diagnosis by molecular biology methods is therefore essential. Due to its rarity, there is little data on specific treatment recommendations. Currently, cutaneous Ewing sarcomas are treated like bone Ewing sarcomas. The prognosis, according to the data in the literature, is much more favorable than bone Ewing sarcomas.

Key Words: Primary cutaneous sarcoma, Ewing sarcoma , Scalp

Received: 19 December 2023, **Accepted:** 2 February 2024.

Corresponding Author: MOHAMMED YOUSSEF NAJI , Hassan II University Hospital Center of Fez,

Mobile: +212608838219, **E-mail:** mohammedyoussef.naji@usmba.ac.ma

ISSN: 2090-097X, January 2024, Vol. 15, No. 1

INTRODUCTION

Ewing's sarcoma (ES/PNET) is usually a bone-localized tumour. The occurrence of extraosseous (or extraskelatal) Ewing sarcoma (EES) has been well described, but cases in which this tumor occurs in a primary cutaneous site remain exceptional. We report a case of primary cutaneous Ewing sarcoma (PCES) of the scalp.

Observation

Our patient is 22 years old, a smoker, who had been suffering from a swelling of the scalp for six months following a trauma to this area. He had no history of other diseases and he was not receiving any medical treatment at that time. Upon examination, the mass is subcutaneous, roughly oval in shape with regular contours, sitting next to healthy skin at the left occipitoparietal level, having a non-infiltrated mobile base, a clean surface traversed by telangiectatic vessels. The mass was of soft consistency, warm on palpation, not beating, and without any pain, pruritus or bleeding, measuring about 6cm along its largest axis. The examination of the lymph node areas did not reveal lymphadenopathy, the osteoarticular examination revealed no pain or bone deformity or palpable mass either in the long bones or along the spine, and there was no hepatosplenomegaly.

A brain MRI was performed, revealing the existence of a necrotic tumor-related lesion on the scalp of the

left occipital region with high-signal T2 and low-signal T1, weakly enhanced after injection of contrast medium, measuring 40 mm x 21mm and 28 mm thick, located at the level of the subcutaneous fatty tissue and making contact with the external table of the cranial vault without signs of invasion of the latter.

Additionally, a biopsy of the tumor was conducted and forwarded for pathological analysis., the results of which spoke of malignant tumor proliferation arranged in layers, small clumps and spans, of high cell density, composed of round cells with rounded nuclei, fine chromatin and amphophilic cytoplasm. Several figures of mitosis have also been noted. The immunohistochemistry was in favor of an Ewing/PNET tumor and showed positive and diffuse anti-CD99 and anti-cytokeratin antibody membrane labeling in tumor proliferation and negativity of antibodies to ERG, PS100, NSE, Desmine, CD34, chromogranin A, synaptophysin, CK7 and CK20.

Fluorescent in situ hybridization (FISH) analysis was conducted, revealing a 100% occurrence of EWSR1 gene rearrangement in 100% of the examined nuclei. Considering these clinical findings, along with the results from the histopathological examination and immunohistochemical profiling, the conclusive diagnosis of Ewing sarcoma was established.

The full-body CT scan did not reveal any suspicious anomalies on various levels, except for the scalp lesion. No bone lesions were detected either. Bone scintigraphy demonstrated the absence of scanno-scintigraphic evidence supporting secondary bone localization, confirming the primary cutaneous nature of the Ewing's tumor.

The patient received 5 cycles of neoadjuvant chemotherapy type VDC, followed by excision of the tumor with margins of 1.5cm and was referred to the radiotherapy department after coverage with a total skin graft

DISCUSSION:

First described by James Ewing in 1921, Ewing's sarcoma primarily manifests as a bone tumor, impacting children and young adult males [1]. Extrasosseous occurrences of Ewing sarcoma are uncommon, and primary skin localization is particularly rare, leading to challenges in both diagnosis and treatment.

The tumor also has the ability to grow within various soft tissues, but it demonstrates a particular inclination for areas such as the paravertebral region, chest wall, lower extremities, and pelvis [2-4]

The nose, eye socket, larynx, nasopharynx, scalp, face, neck and parotid gland remain very rare locations [2]

The swift and painless advancement observed in our patient aligns with existing literature findings. Pain, typically of mild intensity, is reported in only approximately one-third of cases, often attributed to peripheral nerve or spinal cord involvement, or intra-tumoral bleeding. [5]

Identifying this tumor poses difficulties because of its infrequent occurrence in the skin and the diverse range of clinical presentations it may exhibit. Consequently, it is rarely taken into consideration in a clinical context.

Histologically, cutaneous ES/PNETs display features consistent with an undifferentiated "small round cell tumor," presenting a broad spectrum of potential differential diagnoses, encompassing both primary tumors and skin metastases [6]. This diversity complicates the diagnostic process for pathologists. Moreover, CD99, while 86% specific with a positive predictive value of 69% [7], underscores the importance of employing molecular biology methods to ascertain the rearrangement of the EWSR1 gene for definitive diagnosis confirmation.

In our case, the widespread positivity of CD99, along with the absence of reactivity in other markers (such as ERG, PS100, NSE, DESMIN, CD34, CK7, CK20, etc.), and the identification of the EWSR1 gene rearrangement through FISH, collectively supported the diagnostic conclusion.

Diagnostic and extent evaluation of tumors benefit significantly from imaging modalities, such as high-resolution CT and MRI. While the features may lack specificity for EES, these techniques remain valuable. Despite the rapid local growth characteristic of EES, the tumor typically presents with a pseudo-capsule, imparting a distinct and well-defined appearance on both CT and MRI images. In MRI scans, these tumors exhibit low signal intensity in T1, high signal intensity in T2, and demonstrate uneven enhancement following contrast medium injection [2], which is consistent with our results.

In the absence of explicit therapeutic guidelines for primary cutaneous Ewing sarcomas, conventional treatment approaches align with those used for bone Ewing sarcomas. This typically involves extensive surgical intervention, adjuvant radiotherapy, and chemotherapy [8] In our patient's case, the treatment plan involved initiating neoadjuvant chemotherapy with VDC (5 cycles), followed by a comprehensive surgical procedure encompassing a wide excision with lateral margins of 1.5 cm and extending down to the bone. Spongiolization prepared the groundwork for a full-thickness skin graft. This choice of reconstruction method was based on the absence of consent for alternative approaches. The skin graft, harvested from the supraclavicular hollow, underwent degreasing and was secured in place using a tie-over bolster dressing. The outcome proved highly satisfactory, and the patient was subsequently referred for complementary radiotherapy.

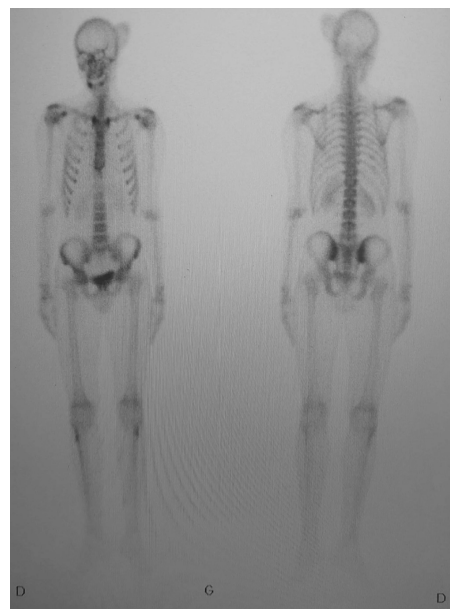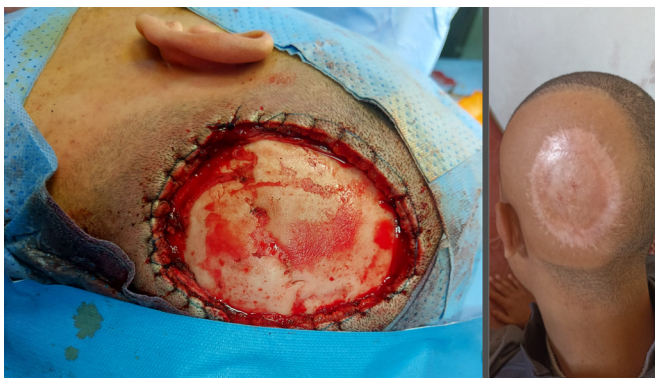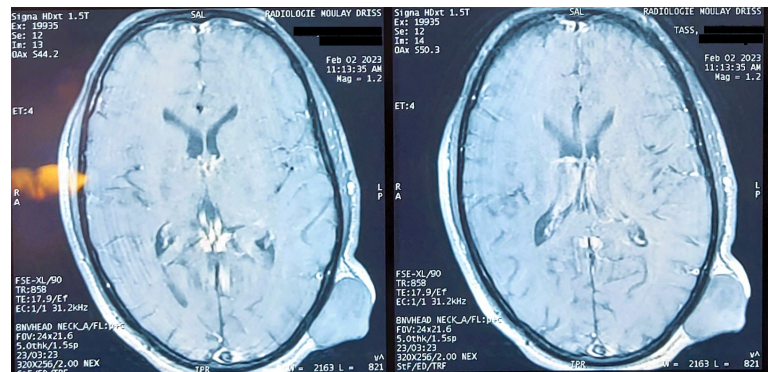
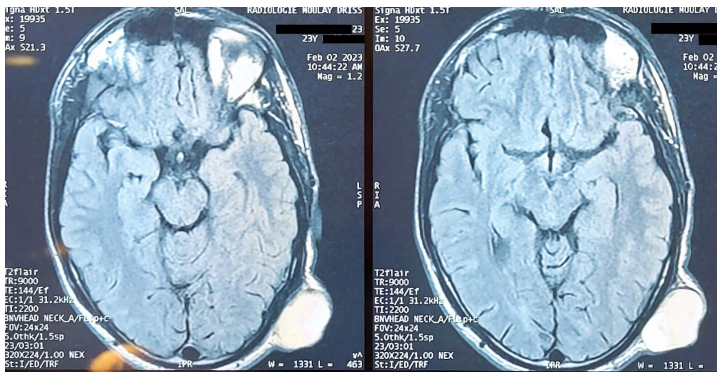
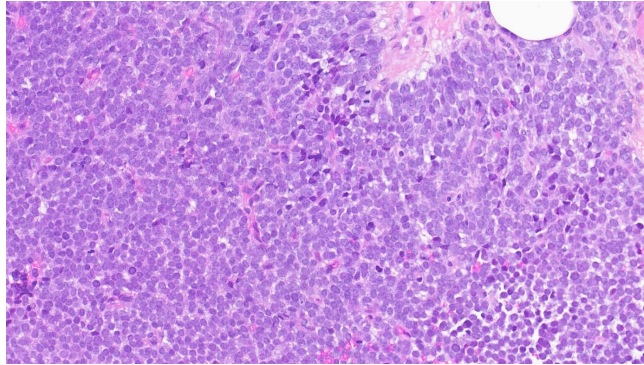
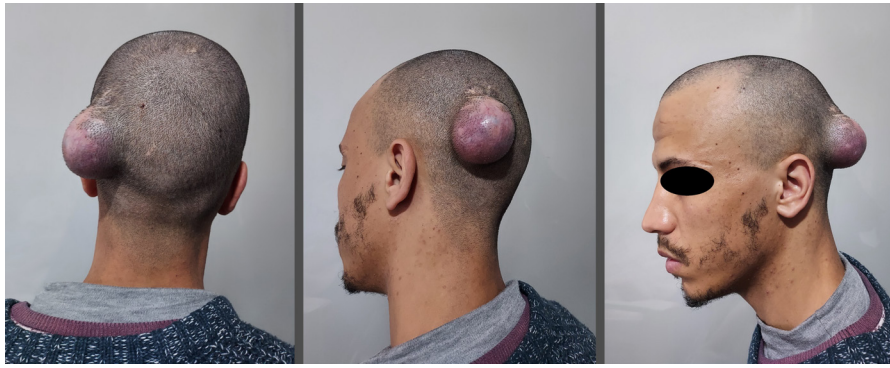The trajectory of extrasosseous Ewing sarcomas tends to be less severe in comparison to their osseous counterparts [6,9,10]. The more favorable prognosis for primary PCES may be attributed to the visible and tangible nature of the lesion, enabling early detection and diagnosis with a smaller tumor volume. This characteristic, in turn, facilitates the execution of a carcinologic excision, presenting an advantage over the challenges posed by bone tumors.

CONCLUSION

Extraskelatal Ewing sarcoma remains an infrequent occurrence, and the primary cutaneous localization, although described, remains exceedingly rare. Diagnosis poses multiple challenges and is currently based on histological evidence. The treatment strategy involves surgery, radiation and chemotherapy, and the prognosis appears to be relatively better than bone Ewing sarcoma.

CONFLICTS OF INTEREST

The authors declare that there are no conflicts of interest.



REFERENCES:

- [1] - Ewing J. Diffuse endothelioma of bone. Proc New York Pathol Soc 1921;21:17–24.
- [2] - Agir H, Brasch HD, Tan ST. Extra-skeletal Ewing's sarcoma of the submandibular gland. Journal of Plastic, Reconstructive & Aesthetic Surgery. 2007;60(12):1345-1348.
- [3] Rose JS, Hermann G, Mendelson DS, Ambinder EP. Extraskelatal Ewing sarcoma with computed tomography correlation. Skeletal Radiol. 1983;9(4):2347-.
- [4] El Weshi A, Allam A, Ajarim D, Al Dayel F, Pant R, Bazarbashi S et al. Extraskelatal Ewing's sarcoma family of tumours in adults: analysis of 57 patients from a single institution. Clinical Oncology. 2010;22(5):374381-.
- [5] Allam K, Sze G. MR primary extraosseous Ewing sarcoma. AJNR. 1994 Feb;15(2):3057-.
- [6] Shingde MV, Buckland M, Busam KJ, McCarthy SW, Wilmott J, Thompson JF, Scolyer RA. Primary cutaneous Ewing sarcoma/primitive neuroectodermal tumour: a clinicopathological analysis of seven cases highlighting diagnostic pitfalls and the role of FISH testing in diagnosis. J Clin Pathol. 2009 Oct;62(10):9159-.
- [7] Ramani P, Rampling D, Link M. Immunohistochemical study of 12E7 in small round-cell tumours of childhood: an assessment of its sensitivity and specificity. Histopathology 1993;23: 557—61.
- [8] M. Delaplace, P. Mélard, A. Perrinaud, C. Goré, B. Vergier, L. Machet, Sarcome d'Ewing cutané primitif : difficultés diagnostiques et thérapeutiques, Annales de Dermatologie et de Vénérologie, Volume 138, Issue 5, 2011, Pages 395398-.
- [9] Terrier-Lacombe MJ, Guillou L, Chibon F, Gallagher G, Benhattar J, Terrier P, et al. Superficial primitive Ewing's sarcoma: a clinicopathologic and molecular cytogenetic analysis of 14 cases. Mod Pathol 2009;22:87—94.
- [10] Ehrig T, Billings S, Fanburg-Smith J. Superficial primitive neuroectodermal tumor/Ewing sarcoma (PN/ES): same tumor as deep PN/ES or new entity? Ann Diagn Pathol 2007;11: 153—9.