



Assessment of Lavender, Frankincense and Peppermint Oils Transdermal Nano Spray Formulation Effect on Wound Healing Activity in Rat Model



Gehan Safwat¹, Zeinab A. El-Gendy², Lamiaa M. Ramadan³, Hager N. Fathy⁴, Omaima H. Ezzo⁵, Merit Rostom⁶ and Fayez K. Fouda⁷

¹Faculty of Biotechnology, October University for Modern Science and Arts (MSA), Giza, Egypt

²Department of Pharmacology, Medical Research and Clinical Studies Institute, National Research Centre, Dokki, Giza, Egypt. za.el-gendy@nrc.sci.eg

³Department of Biochemistry, Biotechnology Research Institute, National Research Centre, Dokki, Giza, Egypt. lmr1@yahoo.com

⁴Faculty of Pharmacy Zagazig University, Zagazig, Egypt. hagernf2002@gmail.com

⁵Department of Animal Reproduction and Artificial Insemination, Veterinary Research Institute, National Research Centre, Dokki, Giza, Egypt.

⁶Academy of Scientific Research and Technology, ASRT, Cairo, Box 11562, Egypt.

⁷Medical Research and Clinical Studies Institute, National Research Centre, Dokki, Giza, Egypt.

BURNS are one of the leading causes of mortality and high morbidity, particularly when combined with bacterial infection that prevents wound closure and delays the healing process. Consequently, there is a huge demand for pharmaceutical techniques to assist in resolving this problem. Essential oils are becoming more popular as organic substitutes for synthetic medications. However, the usage of essential oils is limited due to their poor qualities but they can be utilized by encapsulating them in Nano emulsions. The aim of this study is to investigate the Nano spray formulation containing a combination of lavender, frankincense and peppermint oils for burn healing potential using rat-burn induced model. The effect of Nano emulsions of 2% lavender, 10% peppermint, 5% frankincense, the combination of the three oils in half of their concentrations and the combination in the same concentrations on the fibrotic marker, oxidative stress markers, and histopathological was examined. Our results support the use of essential oils in the development of pharmaceuticals for wounds management and/or inflammatory-related diseases. A trans-dermal Nano spray formulation containing a combination of lavender, frankincense and peppermint oils exhibit considerable wound healing activity.

Keywords: Nano Emulsion oils, Burn healing, Lavender oil, Peppermint oil, Frankincense oil, Spray formulation.

Introduction

Burns are skin wounds that are typically caused by contact with heat, radiation, electricity, friction, or chemicals [1]. Burns are one of the most severe injuries and one of the leading

causes of death and morbidity worldwide due to the physical, emotional, and mental effects [2]. Managing burns and their effects is difficult and prohibitively expensive, even in modern, well-equipped burn units of advanced, wealthy nations

*Corresponding author: Omaima H.Ezzo, E-mail: omimaezzo0@gmail.com, Tel.: 01000917638

(Received 08/01/2024, accepted 05/03/2024)

DOI: 10.21608/EJVS.2024.259455.1765

©2024 National Information and Documentation Center (NIDOC)

[3]. Burns are considered to be the cause of 180000 annual deaths, according to the World Health Organisation (WHO); the bulk of these fatalities occur in low- and middle-income countries, with over two thirds of them taking place in the WHO areas of Africa and South-East Asia [4]. A burn is categorized as a first, second, third, or fourth-degree burn depending on how badly and deeply it penetrates the skin's surface [5].

Wound healing is the body's response to wounds which is a highly specialized and complicated process that replaces harmed or damaged tissues with healthier one for the quick recovery and normal function [6]. Hemostasis, inflammation, proliferation, and remodeling are its four phases which are cross over and linked. Each one differs from the others in terms of the bio physiological processes and predominate cells. These phases must be followed in the proper sequence and at the appropriate time if wounds are to completely heal [7]. The body's natural healing process is seriously hampered by burn wounds, which calls for specialized biomedical urgent care because of their complicated pathophysiology and the possibility of secondary consequences including burn shock, intense pain, hypovolemia, immunosuppression, and severe microbial infections [5]. If burns not treated in the appropriate way it will leave behind physical and psychological scarring that lasts a lifetime, harming mental health, lowering quality of life, making it difficult to find employment, and increasing the risk of death [8]. Nowadays, there is an increasing attention towards plant essential oil extracted from edible and medicinal parts to be used in developing novel topical formulations for treating or manage skin wounds [9].

lavender essential oil consisting of many components such as linalool and linalyl acetate which has analgesic, anti-inflammatory, antibacterial, antifungal, antioxidant, sedative, and antidepressant effects and can successfully heal burns and insect bites [10]. Essential oils are unique heterogeneous classes of secondary metabolites extracted from variety of plant parts including leaves, stems, petals, roots, and seeds [11,12]. Plant-derived oils are broadly classified into two types: (a) volatile or essential oils, and (b) fixed or carrier oils [12, 13]. Lavender oil promotes wound contraction by supporting number of growth factors leading to early wound closure and epithelial layer regeneration. It enhances the healing process through the

granulation tissue formation, tissue remodeling, and wound contraction [14].

Since ancient times, frankincense has been used as an alternative natural medicine to cure a variety of diseases, including cancer, arthritis, asthma, chronic pain syndrome, and brain memory problems [15]. It has also tranquilizing analgesic and antibacterial effects. Its anti-inflammatory effect is mainly attributed to the presence of boswellic acids which inhibit 5-lipoxygenase and hence, prevent leukotrienes formation [15]. Furthermore, it was previously proven that frankincense resins extract can reduce both irritation and redness in the skin and can produce uniform skin pigmentation due to the presence of boswellic acids compounds [16].

In the medical field, peppermint oil is one of the most widely used essential oils which have a good therapeutic effect on migraine, dizziness and insomnia [17]. It has antioxidant and enzyme inhibitory activities, explained its advantages as antibacterial one [18].

Despite their excellent medicinal qualities, essential oils have limited applications as candidates for pharmacotherapy treatments because of their poor water solubility, high volatility, and the risk of an allergic reaction when applied directly to the skin [19]. Therefore, it is crucial to create a suitable medicine delivery system to fully use essential oils in order to assure their overall effectiveness and enhance the stability of volatile components [20]. Using the contemporary medication delivery mechanism known as Nano-encapsulation technology is one way to get around these limitations [21]. The creation of a Nano emulsion is one of the encapsulation techniques. Nano emulsions are colloidal dispersions that are isotropic and thermodynamically unstable [22].

Nano emulsions are employed extensively in the food and pharmaceutical industries due to their small size, great transparency, and low viscosity [23]. In terms of medication absorption, Nano emulsions are superior to conventional emulsions because they increase both the bioavailability of pharmaceuticals as well as their solubility in water for drugs that are water insoluble [24]. Nanoparticles, Nano-cargoes, and bio-compatible materials derived from chemical conjugation and organic reactions have been used to enhance drug-ability, drug availability, and bio-active drug. The purpose of this study is to investigate the role of

lavender, frankincense and peppermint oils Nano emulsions every one alone and in combination on burn wound healing in a rat model, using gross morphological, histopathological and biochemical, analyses. With the goal of expanding the current repertoire of cost-effective wound healing options available to physicians.

Material and Methods

Nano emulsion oil preparation

To create the composite emulsifier used in the production of oil in water O/W Nano emulsions, it is reported that 2 v/v% Tween 80 and Carpool were dissolved in double-distilled water at room temperature. Lavender essential oils were mixed in a 1:1 ratio. IKA[®]C-MAG MS magnetic stirrer (Sigma-Aldrich, Missouri, United States) was used to agitate the mixture for ten minutes in order to obtain a homogeneous solution. Drop by drop, at various water addition rates, distilled water was then added. The final crude emulsion was created by shearing the material for three minutes at 7100 rpm on a high-speed shearing machine from Sigma-Aldrich in Missouri, the United States. To create a frankincense Nano emulsion oil repeat the previous process. Both oils emulsion was then homogenized using an HG-15D high pressure homogenizer (Daihan Scientific, Wonju, South Korea). This was done before the mixture was cooled for 0.5 hours in an ice water bath. For the lavender Nano emulsion oil and frankincense oil used as divided groups, the pH of the Nano-emulsion was finally lowered to 7 using either 0.5 mol/L of citric acid or 0.5 mol/L of sodium hydroxide solution. Samples were kept in the securely closed vials for further examination.

Preparation of spray formula

The TS-800 Trigger Spray from Calmar Dispensing Systems is the trigger spray device used to package the oil (Watchung, N.J., U.S.A.). When set to the spray setting and sprayed from an 8-inch distance, it is intended to spray a pattern with an 8-inch diameter. When set to the stream setting and sprayed from an 8-inch distance, the same sprayer produced a 2-inch diameter pattern.

TEM measurements of the Nano emulsion's droplet size

Transmission electron microscopy (TEM) was used to examine the surface morphology of the NE droplets of juniper/eucalyptus essential oil (TEM, Akishima, Tokyo, Japan). The samples were adsorbed for 1 minute onto 200-mesh form-var-coated copper sample holders after

being negatively stained for 10 minutes at room temperature with 50 micro-liters of 1.5% (w/v) phosphotungstic acid. After draining the extra liquid, the holders were looked at with a TEM with a 20 m aperture. A 200 KV TEM was used to photograph the samples after sufficient air drying.

Evaluation of Nano emulsion oil's antimicrobial activity

Utilizing a nutritive agar medium and the agar disk diffusion plate technique was created to evaluate the antibacterial activity of the formulated mixture. *Escherichia coli*, a gram-negative bacteria, and *Staphylococcus aureus* were used in this investigation (gram positive). Nutrient agar (NA) (25 ml) was poured into the sterilized Petri dishes and allowed to solidify before being inoculated with the two pathogenic strains of bacteria (Mueller-Hinton Agar plates, Merck Co., Germany) in three wells with the appropriate microbial suspension (0.1 mL) containing 105 CFU/ml (colony forming unit per milliliter), which had been diluted beforehand with distilled water. To ensure pathogen saturation, the agar plate was then incubated for another two hours at 37° C.

The patch discs or (oils at varying concentrations of 6.25, 12.5, 25, 50, 100, and 200 g/ml) were then placed directly on the agar medium plate surface and cultured under the conditions mentioned above for each of the bacteria (24 hours at 37° C). Finally, the antibacterial activity of lavender, peppermint and frankincense was evaluated on bacteria.

Animals

Adult male Wister rats weighing between 180 and 200 g and 6 weeks of age were purchased from the National Research Centre (NRC) animal colony. All rats were housed under standard circumstances (12 h day/night cycle, 22–25 °C), with unlimited access to food and water. The experimental procedure was approved by the Research Ethics Committee for Experimental and Clinical Studies, following the recommendations of National Research Centre. Following a week of acclimation, an electric shaver was used to uncover the cutaneous surface on the back of the animal. The remaining hair was removed using a hair removal cream. The rats were given a 24-hour period of rest to allow their skin to heal from any injuries sustained during hair removal. After the experiment's 14 day period had passed, the rats were sacrificed by cervical dislocation and the sample were collected for histopathological and biochemical analysis.

Development of burn model and topical treatment

Rats were anesthetized using phenobarbital (120 mg/kg) intraperitoneally, and a second-degree burn was induced on the back of the animal by 10 seconds exposure to 5 × 2 cm size metal block weighing 200 g heated to 100 °C [25]. Rats were divided into seven groups (n = 20 each group) as follows:

Normal (shaving was done and skin was left), Control (burn); the skin was exposed to the burn injury and left untreated, 2% lavender [19], 10% peppermint [17], 5% frankincense [26], 0.5 Mix (half the concentration of three oils), and Mix (the same concentration of three oils) groups.

Assessment of the wound healing area

The wound healing area was assessed on 3rd, 7th, and 14th d after starting the treatment (Fig.1). Before making the wounds, we anaesthetized the rats with pentobarbital. Each rat had a wound that was excised on its anterior-dorsal side, with an estimated maximum thickness of 500 mm² and a specified area of 500 mm². The test formulations were applied topically once daily for 15 days to each group of rats. The percentage of wound contractions and healing time proved to be the most useful indicators of wound healing. Every third day, we drew a rough outline of the wound area on butter paper to determine its location. To calculate the percentage area of wound contractions, Image software was used. Calculations were made for the total wound healing area and the closure area.

The following variables were used to determine how quickly burn wounds healed

$$\text{Wound size - reduction (\%)} = \frac{A_0 - A_x}{A_0} \times 100$$

Where A = wound area at day 0, A_x = wound area at day 15 of the experiment.

Determination of oxidative stress and anti-oxidant activity in skin homogenate

1- Malondialdehyde (MDA) determination.

This test was conducted using kits of Bio Diagnostic Company for the enzymatic colorimetric measurement of MDA at wave length 534 nm according to the method of Abd-Rabou and Edris [27].

2-Reduced glutathione (GSH) measurement.

Using kits from Bio Diagnostic Company, this test was carried out in accordance with Ohkawa et al. [28] for the enzymatic colorimetric measurement of GSH at wave length 405 nm.

Determination of fibrosis markers

Transform growth factor β (TGF-β) was quantified using ELISA kit (Cell science, Canton, MA, USA) according to the manufacturer's procedure.

Determination of Interleukin-1β (IL-1B)

IL-1B was quantified using rat ELISA kit (Catalog number 27193) of Immuno-Biological Laboratories, USA for the enzymatic colorimetric measurement of IL-1B at wave length 450 nm according to the manufacturer's procedure.

Evaluation of tissues' histomorphology

The skin specimens on the 3th, 7th and 14th d after starting the treatment were obtained from rat and fixed in 10% buffered formalin solution for 24 hours, dehydrated in ascending grades of ethanol concentration, cleaned in xylol and embedded in paraffin the tissue slices were deparaffinized. A Minux® S700 Rotary microtome (Minux® S700, RWD Life science, China), H&E (Hematoxylin and Eosin) (Sigma-Aldrich, Missouri, United States), and Olympus CX23 light microscope (Olympus, Tokyo, Japan) cut skin sections of 5 μm thickness and then mounted on glass slides of Paraffin sections were stained with H&E. In the healed areas, inflammation could be seen without a visual examination, whereas infiltration's or their inflammatory cell field were counted. To measure the degree to which the tissues were healed, markers for inflammation included epithelization, neovascularization, fibroblast proliferation, and collagen deposition. We used a modified version of a published scale to describe the area where the wound was healing (0.0-5.0).

Statistical analysis

A one-way ANOVA and Tukey's multiple comparison tests were employed for the statistical study of anti-oxidant activity and oxidative stress. The data were given as mean ± SEM. P values less than 5% (p < 0.05) indicated statistical significance for differences.

Results

TEM measurements

By transmission electron microscopy, it was possible to determine the size of the surface morphology of the Nano emulsion droplets made from juniper and eucalyptus essential oils. The results showed that the essential oils in Nano emulsions were evenly dispersed as spherical particles between 27.78 and 56.96 nm in size. The size range of accepted Nano emulsion particle sizes is occupied by all of the produced droplet sizes, where sizes of the control group ranged from 20.63 to 144.45 nm (Fig. 2).

Examination of Nano emulsion oil's antimicrobial activity

The agar disk diffusion plate technique was created to assess the antibacterial efficacy of lavender essential oil and combination of lavender essential oil, frankincense oil and peppermint essential oil Nano emulsion loaded in the formulated spray using a nutritive agar medium that permits the growth of *Escherichia coli* (Gram negative) and *Staphylococcus aureus* (Gram positive) bacteria. The combination of Lavender essential oil; Frankincense oil and peppermint essential oil Nano emulsion oil is effective against two strains of bacteria and lavender positive effect with *E. coli* in figure (3).

Effect of Nano emulsions of 2% lavender, 10% peppermint, 5% frankincense, the combination of the three oils in half of their concentrations and the combination in the same concentrations on IL-1B

The skin burn significantly increased content of IL-1B by 11.1 fold in day three as compared to the normal group ($P < 0.05$). Whereas treatment with Nano emulsions of 2% lavender, 10% peppermint and 5% frankincense resulted in decrease in the content of IL-1B by 46.6%, 62.9% and 63.6% respectively, as compared to the control group. Moreover, the combination of the three oils in half of their concentrations and in the same concentrations resulted in further boosting of the aforementioned marker by 66.8 % and 70.8 %, respectively. While in day seven content of IL-1B increased by 9.7 fold as compared to the normal group ($P < 0.05$). Whereas treatment with Nano emulsions of 2% lavender, 10% peppermint and 5% frankincense resulted in decrease in the content of IL-1B by 53.1%, 71.7% and 72.5% respectively, as compared to the control group. Moreover, the combination of the three oils in half of their concentrations and in the same concentration resulted in further boosting of the aforementioned marker by 75.9 % and 80.1 %, respectively. While in day fourteen content of IL-1B increased by 8.8 fold as compared to the normal group ($P < 0.05$). Whereas treatment with Nano emulsions of 2% lavender, 10% peppermint and 5% frankincense resulted in decrease in the content of IL-1B by 58.6%, 79.1% and 79.9% respectively, as compared to the control group. Moreover, the combination of the three oils in half of their concentrations and in the same concentration resulted in further boosting of the aforementioned marker by 86.1 % and 91.2 %, respectively (Figure, 4).

Effect of Nano emulsions of 2% lavender, 10% peppermint, 5% frankincense, the combination of the three oils in half of their concentrations and the combination in the same concentrations on TGF- β 1.

The skin burn significantly increased content of TGF- β 1 by 6.4 fold in day three as compared to the normal group ($P < 0.05$). Whereas treatment with Nano emulsions of 2% lavender, 10% peppermint and 5% frankincense resulted in decrease in the content of TGF- β 1 by 7.7%, 3.6% and 11.7% respectively, as compared to the control group. Moreover, the combination of the three oils in half of their concentrations and in the same concentrations resulted in further boosting of the aforementioned marker by 15.5 % and 18.6 %, respectively. While in day seven content of TGF- β 1 increased by 4.1 fold as compared to the normal group ($P < 0.05$). Whereas treatment with Nano emulsions of 2% lavender, 10% peppermint and 5% frankincense resulted in decrease in the content of TGF- β 1 by 12.4%, 5.5% and 14.6% respectively, as compared to the control group. Moreover, the combination of the three oils in half of their concentrations and in the same concentration resulted in further boosting of the aforementioned marker by 17.8 % and 20 %, respectively. While in day fourteen content of TGF- β 1 increased by 1.9 fold as compared to the normal group ($P < 0.05$). Whereas treatment with Nano emulsions of 2% lavender, 10% peppermint and 5% frankincense resulted in decrease in the content of TGF- β 1 by 30.7%, 25.2% and 33.9% respectively, as compared to the control group. Moreover, the combination of the three oils in half of their concentrations and in the same concentration resulted in further boosting of the aforementioned marker by 38.6 % and 42.3 %, respectively (Figure, 5).

Effect of Nano emulsions of 2% lavender, 10% peppermint, 5% frankincense, the combination of the three oils in half of their concentrations and the combination in the same concentrations on MDA.

The skin burn significantly increased content of MDA by 2.6 fold in day three as compared to the normal group ($P < 0.05$). Whereas treatment with Nano emulsions of 2% lavender, 10% peppermint and 5% frankincense resulted in decrease in the content of MDA by 39.9%, 32.6% and 44.5% respectively, as compared to the control group. Moreover, the combination of the three oils in half of their concentrations and in the same concentrations resulted in further boosting

of the aforementioned marker by 46 % and 57.5 %, respectively. While in day seven content of MDA still increased by 2.5 fold as compared to the normal group ($P < 0.05$). Whereas treatment with Nano emulsions of 2% lavender, 10% peppermint and 5% frankincense resulted in decrease in the content of MDA by 40.8%, 34% and 44.3% respectively, as compared to the control group. Moreover, the combination of the three oils in half of their concentrations and in the same concentration resulted in further boosting of the aforementioned marker by 45 % and 56.5 %, respectively. While in day fourteen content of MDA still increased by 2.3 fold as compared to the normal group ($P < 0.05$). Whereas treatment with Nano emulsions of 2% lavender, 10% peppermint and 5% frankincense resulted in decrease in the content of MDA by 45.8%, 37.9% and 43% respectively, as compared to the control group. Moreover, the combination of the three oils in half of their concentrations and in the same concentration resulted in further boosting of the aforementioned marker by 38.4 % and 54.8 %, respectively (Figure, 6).

Effect of Nano emulsions of 2% lavender, 10% peppermint, 5% frankincense, the combination of the three oils in half of their concentrations and the combination in the same concentrations on GSH.

The skin burn significantly decreased content of GSH by 2.4 fold in day three as compared to the normal group ($P < 0.05$). Whereas treatment with Nano emulsions of 2% lavender, 10% peppermint and 5% frankincense resulted in increase in the content of GSH by 48.3%, 56.7% and 40.8% respectively, as compared to the control group. Moreover, the combination of the three oils in half of their concentrations and in the same concentrations resulted in further boosting of the aforementioned marker by 87.8 % and 88.9 %, respectively. While in day seven content of GSH increased by 1.8 fold as compared to the normal group ($P < 0.05$). Whereas treatment with Nano emulsions of 2% lavender, 10% peppermint and 5% frankincense resulted in decrease in the content of GSH by 46.2%, 42.5% and 30.6% respectively, as compared to the control group. Moreover, the combination of the three oils in half of their concentrations and in the same concentration resulted in further boosting of the aforementioned marker by 65.6 % and 66.2 %, respectively. While in day fourteen content of GSH increased by 1.5 fold as compared to the normal group ($P < 0.05$). Whereas treatment with Nano emulsions of 2%

lavender, 10% peppermint and 5% frankincense resulted in decrease in the content of GSH by 29%, 30% and 24.5% respectively, as compared to the control group. Moreover, the combination of the three oils in half of their concentrations and in the same concentration resulted in further boosting of the aforementioned marker by 52.5 % and 53.4 %, respectively (Figure, 7).

Effect of Nano emulsions of 2% lavender, 10% peppermint, 5% frankincense, the combination of the three oils in half of their concentrations and the combination in the same concentrations on tissues' histomorphology (figures 8-9).

Examination of H&E-stained sections of skin of rats of control group revealed that the normal histological structure for skin was formed of epidermis; dermis and many hair follicles and associated sebaceous glands were evident in dermis (Fig. 8.1.A). Histological examination of skin samples in burn group revealed epithelium of ununiformed thickness, coagulative necrosis involving the whole thickness of the epidermis, with degenerated hair follicles and sebaceous glands, inflammatory cell infiltration of the epidermis, dermis and oedema (Fig. 8.2. A).

At 3 days of treatment: In the burn group treated with lavender showed moderate improvement structure of epidermis, dermis reduced thickness of the epidermis, mild increase sebaceous glands and hair follicles with mild inflammatory cell infiltration (Fig. 8.3. A). In the burn group treated with peppermint showed almost nearly normal structure epidermis and dermis, sebaceous glands and hair follicles and some filed appeared slight degeneration of epidermis and dermis were also present (Fig. 8.4 A). In the burn group treated with frankincense showed more or less normal epidermis and dermis, sebaceous glands and hair follicles were also present with oedema (Fig. 8.5. A). In the burn group treated with Mix showed more or less normal epidermis and dermis, sebaceous glands and hair follicles were also present with minimal inflammatory cellular infiltration (Fig. 8.6. A). In the burn group treated with 5% Mix showed more or less normal epidermis and dermis, sebaceous glands and hair follicles and odema (Fig. 8.7. B).

At 7 days of treatment: Section in burn rat skin from group reveals epithelium of unregular thickness, coagulative necrosis in the epidermis, with degenerated hair follicles and sebaceous glands, inflammatory cell infiltration of the epidermis, dermis and odema (Fig. 8.8. B). In

the burn group treated with 2% lavender showed moderate improvement structure of epidermis, dermis reduced thickness of the epidermis, mild increase sebaceous glands and hair follicles and odema (Fig. 8.9. B). In the burn group treated with peppermint showed nearly normal structure epidermis (Ep) and dermis (Der), sebaceous glands (Sg) and hair follicles (HF) were also present with minimal inflammatory cellular infiltration (Fig. 8.10. B).

In the burn group treated with frankincense showed more or less normal epidermis (Ep) and dermis (Der), sebaceous glands (Sg) and hair follicles (HF) were also present with minimal inflammatory cellular infiltration (Fig. 8.11. B).

In the burn group treated with Mix 3 % showed more or less normal epidermis (Ep) and dermis (Der), sebaceous glands (Sg) and hair follicles (HF) were also present with minimal inflammatory cellular infiltration (Fig. 8.12. C).

In the burn group treated with Mix 5 % showed more or less normal epidermis (Ep) and dermis (Der), sebaceous glands (Sg) and hair follicles (HF) were also present with minimal inflammatory cellular infiltration (Fig. 8.13. C).

At 14 days of treatment: Examined skin of rats from burn group revealed epithelium of un-uniformed thickness, marked necrosis involving the almost thickness of the epidermis, with hair follicles degeneration and sebaceous glands, severe degenerated cell (Fig. 8.14. C). Examined skin of rats from burn group treated with lavender showed moderate improvement structure of epidermis, dermis with reduced thickness of the epidermis. Mild increased sebaceous glands and hair follicles were also present with mild cell degeneration (Fig. 8.15. C). In the burn group treated with burn group treated with peppermint showed nearly normal structure epidermis and dermis, sebaceous glands and hair follicles were also present with minimal inflammatory cellular infiltration and oedema (Fig. 8.16. C). In the burn group treated with burn group treated with frankincense showing more or less normal epidermis and dermis, sebaceous glands and hair follicles were also present with minimal inflammatory cellular infiltration and oedema (Fig. 8.17. C). In the burn group treated with burn group treated with Mix 3% showed more or less normal epidermis and dermis, sebaceous glands and hair follicles were also present with minimal inflammatory cellular infiltration and oedema (Fig. 8.18. C). In the

burn group treated with burn group treated with Mix 5% showed moderate improvement structure of epidermis, dermis reduced thickness of the epidermis, mild increase sebaceous glands and hair follicles (Fig. 8.19. C).

Discussion

Burn injuries are a trauma that may happen to anyone, anytime and anywhere. Burn injuries are accompanied by immunological and inflammatory response, metabolic alterations and distributive shock that can be challenging to manage and can lead to multiple organ failure. Burn care is, therefore, faced with several difficulties including acute and critical care management, long-term care and rehabilitation [29].

In order to prevent the incidence of burn circumstances, novel treatment approaches are needed, and Nano medicine is one field that may be extensively explored [28]. As the application of nanotechnology in medical care, Nano medicine is a promising field since it lowers therapeutic costs while simultaneously improving healthcare [30].

This study attempted to investigate how lavender, frankincense and peppermint oils Nano emulsions can help in the healing process of burn wounds. Our results revealed that lavender; frankincense and peppermint oils Nano emulsions combined significantly accelerated repair and regeneration of burn wounds by lowering inflammatory response, stimulating fibroblast proliferation and differentiation, and improving angiogenesis and re-epithelialization. Such beneficial effects may improve cosmetic appearance of wound and prevent excessive scar tissue formation in the wound bed. These findings were supported by the current results obtained from histopathology and biochemical analyses.

In this study, treatment with lavender, frankincense and peppermint oils Nano emulsions resulted in significant increase in the antioxidant activity, reflected by the significantly lower MDA and increase in GSH contents ($P < 0.05$) as come with Souto et al. [31] for lavender, Ahmed et al. [32] for frankincense and Hosny et al. [33] for peppermint. The combination 0.5 mix and mix Nano emulsions was superior to the individual ones at different time intervals which proves its anti-oxidant effect when combined together during burn healing, suggesting that they can help in preventing the production and scavenging of ROS.

Prolonged inflammatory response is a serious issue in patient with severe burn injuries and can lead to systemic complications [34]. It has been shown that lavender [35], frankincense [36] and peppermint [37] oils are significantly able to reduce inflammation. Accordingly, it is hypothesized that incorporation of them combined into Nano emulsion spray may protect against inappropriate conditions. The ability of lavender, frankincense and peppermint oils Nano emulsions to reduce the inflammatory response in the wound site was demonstrated by low contents of IL-1 β and TGF- β 1, on day 7 and 14 post-burning. Although lavender, frankincense and peppermint oils Nano emulsions every one alone reduced the inflammatory reactions. Advanced smart Nano-technology platforms, Nano-encapsulation, Nano emulsions, liposomes, and cyclodextrins with chemical conjugation, structure modification to improve the biological activity, stability, bioavailability, effective drug delivery, and drug ability of crude EOs and individual EO-constituents [38] a decrease in IL-1 β and TGF- β 1 contents was observed in the wounds treated with the combination of them. In 0.5 mix and mix groups at 7 and 14 days post-burning. Hence, the anti-inflammatory activity of their combination, in the current experiment, seems to be related to a direct influence of them on expression of IL-1 β and TGF- β 1. In addition, significant reduction in mononuclear cells in the 0.5 mix and mix groups in histopathology sections treated wounds could be another explanation for the anti-inflammatory activity of them in the wound environment as come with Woranuch *et al.* [39] for lavender, Faridzadeh *et al.* [40] for frankincense and AL-dahmash *et al.* [41] for peppermint.

Lavender, frankincense and peppermint oils Nano emulsions in combination significantly improved burn healing in comparison to every one of them alone, after 14 day of treatment. TGF- β 1 is a strong activator of myofibroblast differentiation, and high levels of TGF- β 1, which is frequently associated with a prolonged acute inflammatory response, can cause over-contraction, formation of tight collagen bundles, excessive matrix deposition, and increased scar formation [42]. Treatment by lavender, frankincense and peppermint oils Nano emulsions in combination resulted in significant reduction in scar formation in the wound bed. This finding was also supported histopathological results that demonstrated low concentration of hydroxyproline in the wounds treated with their combination. Actually, during the remodelling phase of healing, lavender, frankincense and peppermint

oils Nano emulsions in combination improved tissue alignment and organization which resulted in decrease wound size and cosmetic appearance of the burn wounds that were reasons for accelerated maturation of the wounds of this treatment regimen.

A trans-dermal Nano spray formulation containing a combination of lavender, frankincense and peppermint oils exhibit considerable wound healing activity. Amirzade-Iranaq *et al.* [43] concluded that the application of *M. piperita* essence has led to an increase in expression of TGF- β gene in the wound region and has provided wound healing essentials. The essence has antibacterial properties because of having thymol, menthol, phenol and flavonoid combinations, and oxidants such terpenes. In addition, due to the antioxidant effects of the aforementioned chemicals, it has been able to promote angiogenesis, fibroblast proliferation epithelialization as well as regulation of skin infections and acceleration of wound healing.

In particular, lavender oil has traditionally been used to treat wounds. Lavender essential oils have a wide range of pharmacological effects that could be beneficial in the healing process of wounds. Our treatment with this lavender oil cream formulation led to remodeling, re-epithelization, improved tissue perfusion and regeneration and decreased inflammation. There were fewer macrophage and more collagen fibers, with less scar formation. In this respect, the biological effects of EOs (frankincense, lavender, myrrh, sandalwood, rose and *Helichrysum*) on human dermal fibroblast cells subjected to simulated chronic inflammation were investigated [44]. They found that all of the examined EOs had anti-proliferation impact on fibroblast cells. Furthermore, lavender essential oil was among the few oils that inhibited collagen III, plasminogen activator inhibitor.

Conclusions

Collectively, the use of lavender, frankincense and peppermint oils Nano emulsions in combination could improve burn healing during the wound healing process.

Acknowledgment

We thank the National Research Centre for introducing the facilities of this research.

Conflicts of interest

There are no conflicts to declare

Funding statement

Self funding

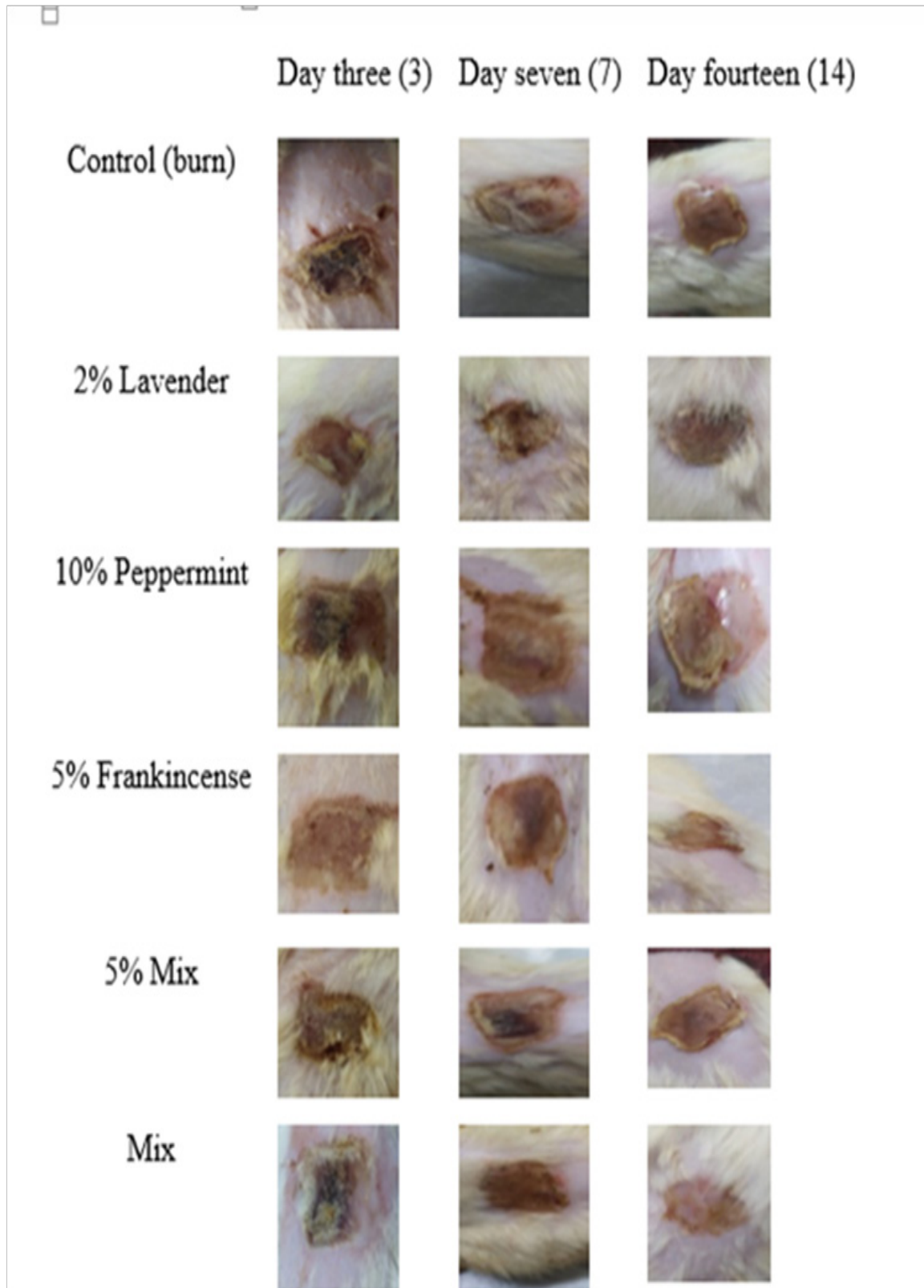


Fig. 1. Various phases of wound healing area in the rats.

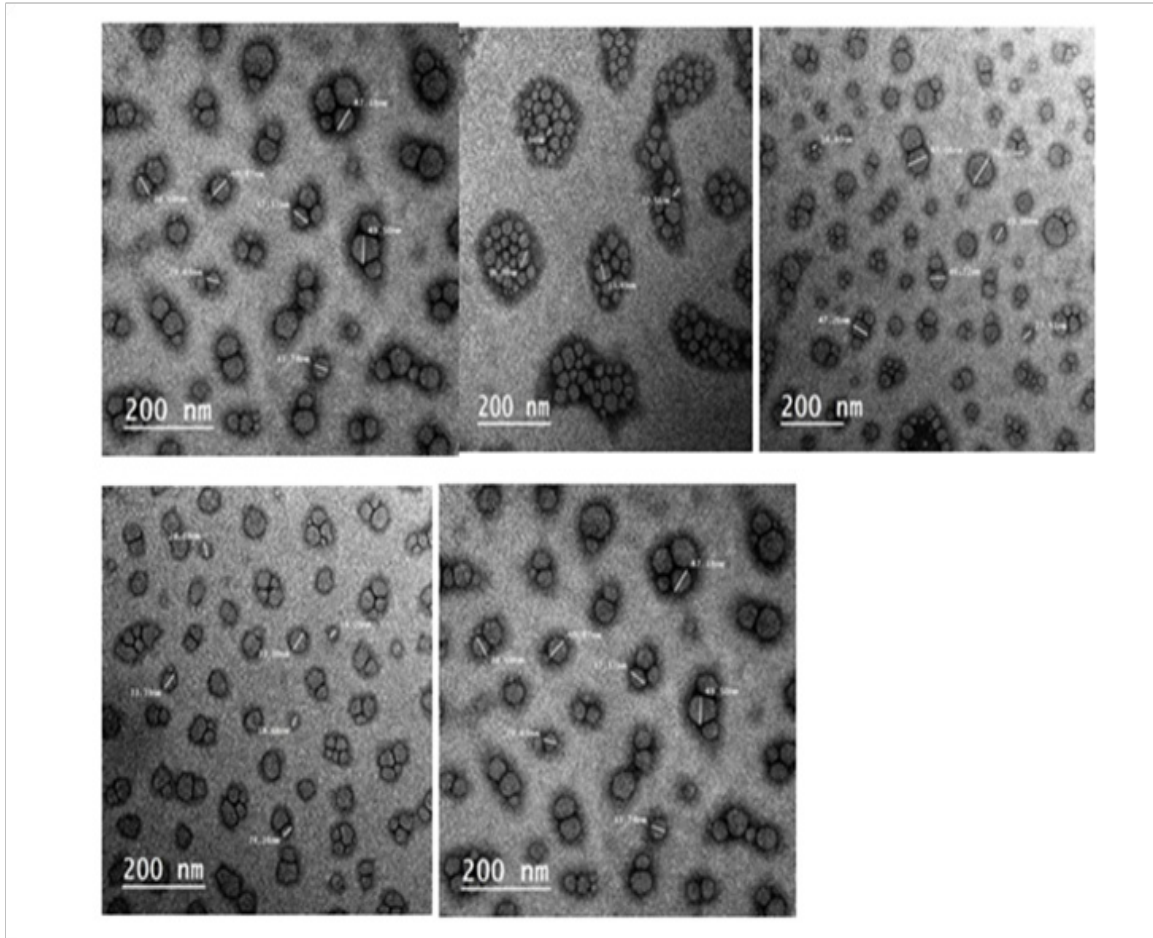


Fig. 2. TEM images of (A) lavender, (B) peppermint essential oil and (C) frankincense essential oil (D) 0.5 Mix (E) Mix.




Fig. 3. Agar plates containing zones of inhibition among the bacteria (*Escherichia coli*), of Lavender essential oil; Frankincense oil and peppermint essential oil Nano emulsion oil.

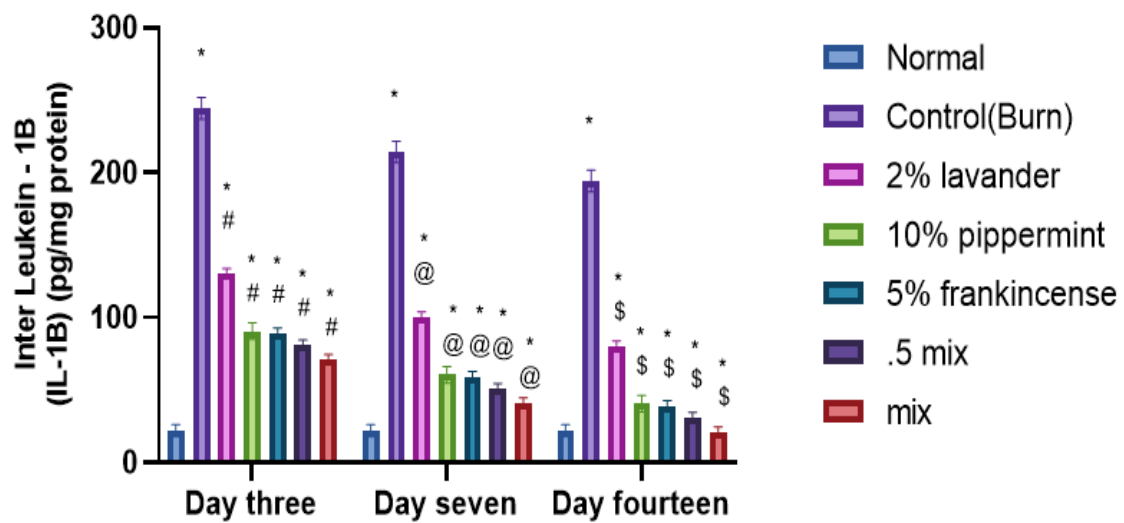


Fig. 4. Effect of Nano emulsions of 2% lavender, 10% peppermint, 5% frankincense, the combination of the tree oils in half of their concentrations and the combination in the same concentrations on IL-1B. Each bar represents the mean of 8 rats. Significant difference from normal group expressed by * at $p < 0.05$. Significant difference from control (Burn) group at day three was expressed by # at $p < 0.05$, at day seven was expressed by @ at $p < 0.05$ and at day fourteen was expressed by \$ at $p < 0.05$.

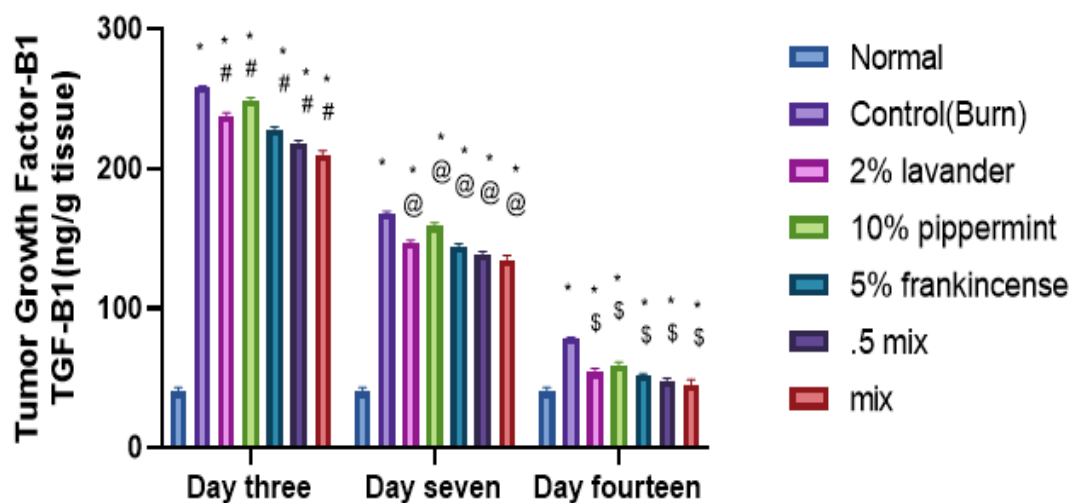


Fig. 5. Effect of Nano emulsions of 2% lavender, 10% peppermint, 5% frankincense, the combination of the tree oils in half of their concentrations and the combination in the same concentrations on TGF- β 1. Each bar represents the mean of 8 rats. Significant difference from normal group expressed by * at $p < 0.05$. Significant difference from control (Burn) group at day three was expressed by # at $p < 0.05$, at day seven was expressed by @ at $p < 0.05$ and at day fourteen was expressed by \$ at $p < 0.05$.

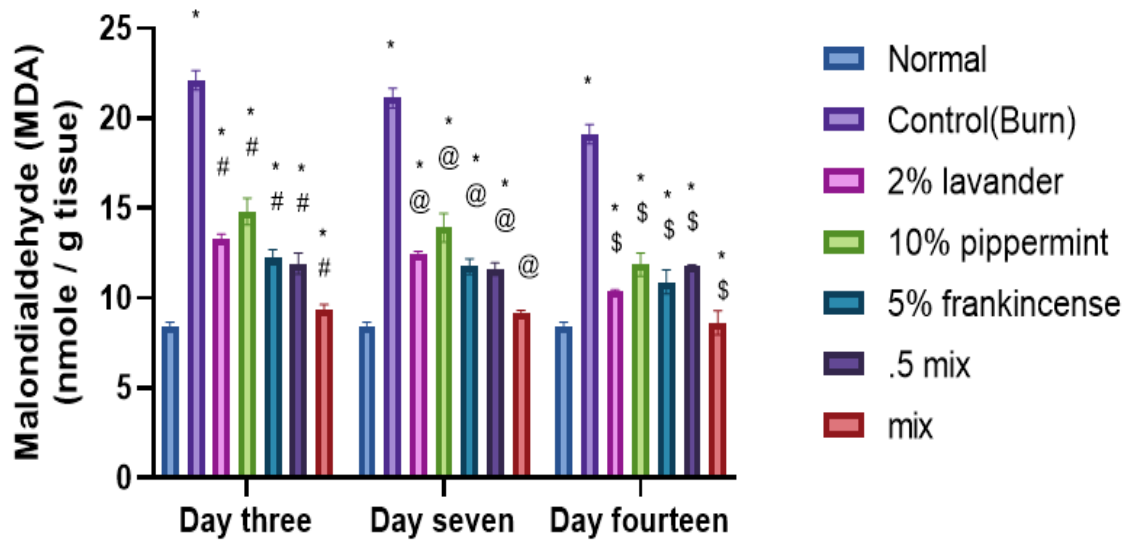


Fig. 6. Effect of Nano emulsions of 2% lavender, 10% peppermint, 5% frankincense, the combination of the three oils in half of their concentrations and the combination in the same concentrations on MDA. Each bar represents the mean of 8 rats. Significant difference from normal group expressed by * at $p < 0.05$. Significant difference from control (Burn) group at day three was expressed by # at $p < 0.05$, at day seven was expressed by @ at $p < 0.05$ and at day fourteen was expressed by \$ at $p < 0.05$.

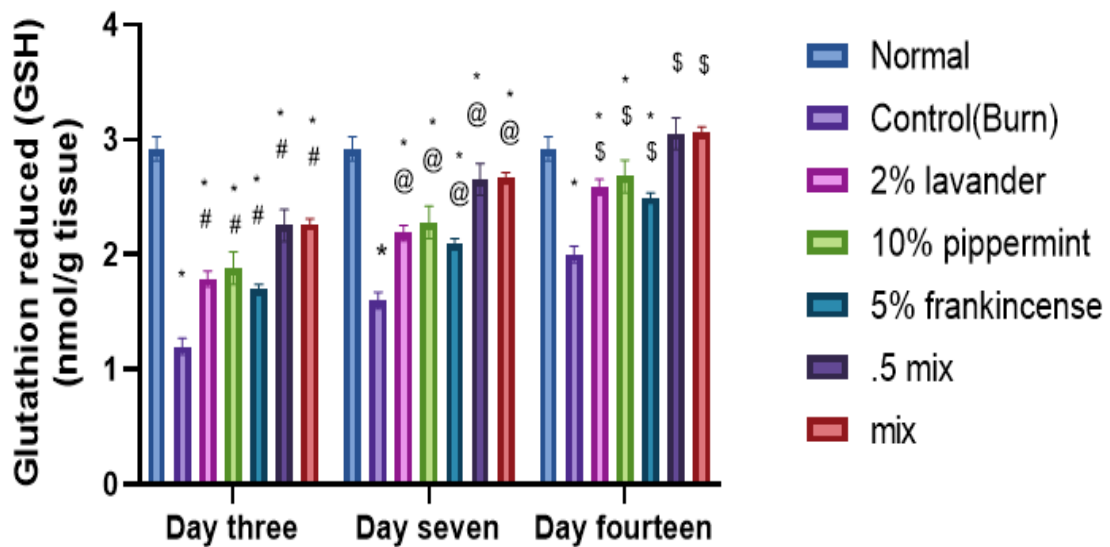


Fig. 7. Effect of Nano emulsions of 2% lavender, 10% peppermint, 5% frankincense, the combination of the three oils in half of their concentrations and the combination in the same concentrations on GSH. Each bar represents the mean of 8 rats. Significant difference from normal group expressed by * at $p < 0.05$. Significant difference from control (Burn) group at day three was expressed by # at $p < 0.05$, at day seven was expressed by @ at $p < 0.05$ and at day fourteen was expressed by \$ at $p < 0.05$.

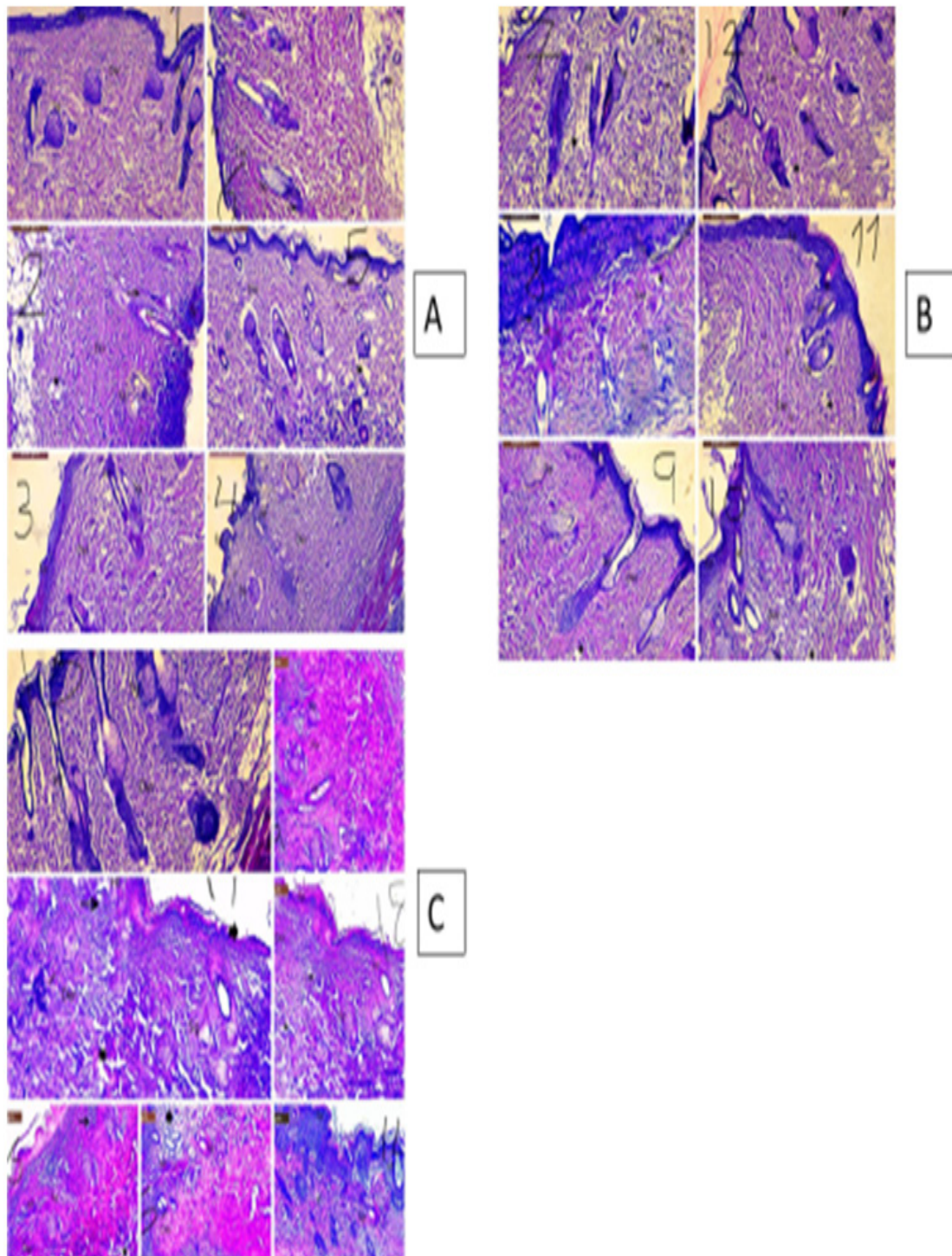


Fig. (8: A, B, C). Photomicrographs of sections of skin from rats stained with H&E. from control and treated groups at 3, 7 and 14 days of treatment. The sections showed epidermis (Ep), Dermis (D) many hair follicles (HF) and sebaceous glands (Sg), in addition to pathological skin changes.

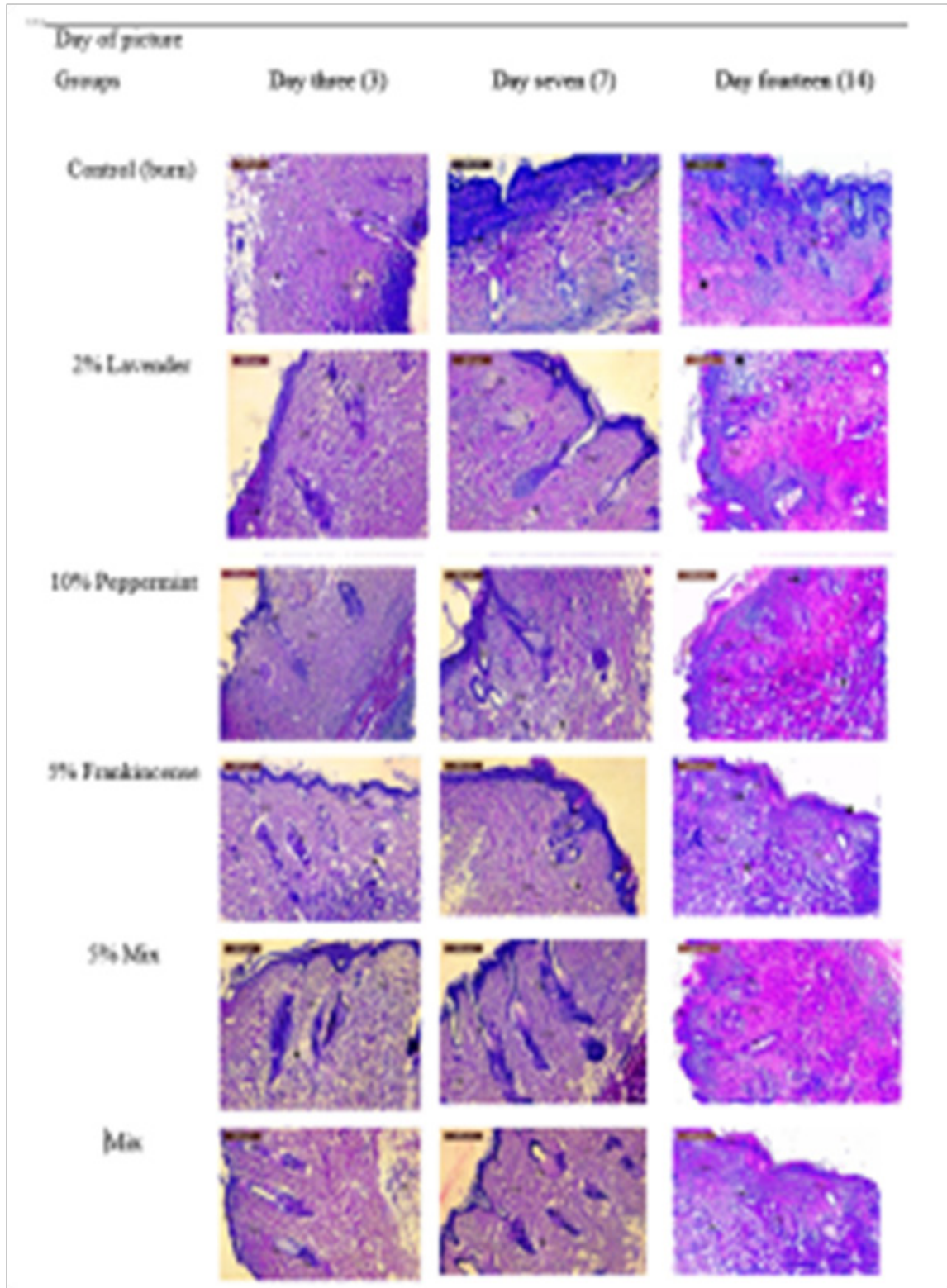


Fig. 9. Microscopic view of open cutaneous wounds.

References

1. Rossella, E., Giulio, M. and Michele, M. Burns: classification and treatment. Textbook of Plastic and Reconstructive Surgery: Basic Principles and New Perspectives, 285-301(2022).
2. Rice, P.L. and Orgill, D. Assessment and classification of burn injury. *UpToDate, [Internet]*, **8**, 129-132 (2021).
3. Kars, A.A., Erasmus, G.J. and Van der Westhuizen, J. Variance component and heritability estimates for growth traits in the Nguni cattle stud at Bartlow Combine. *South African Journal of Animal Science*, **24** (1), 129-132 (1994).
4. Courtwright, J. Prairie fire: a Great Plains history, University Press of Kansas. (2023).
5. Markiewicz-gospodarek, A., Koziół, M., Tobiasz, M., Baj, J., Radzikowska-Büchner, E. and Przekora, A. Burn wound healing: clinical complications, medical care, treatment, and dressing types: the current state of knowledge for clinical practice. *International Journal of Environmental Research and Public Health*, **19**, 1338. (2022).
6. Hussain, Z., Thu, H. E., Rawas-qalaji, M., Naseem, M., Khan, S. and Sohail, M. Recent developments and advanced strategies for promoting burn wound healing. *Journal of Drug Delivery Science and Technology*, 92-103(2022).
7. Desjardins-park, H. E., Gurtner, G. C., Wan, D. C. and Longaker, M. T. From chronic wounds to scarring: The growing health care burden of under-and over-healing wounds. *Advances in Wound Care*, **11**, 496-510 (2022).
8. Liu, J., Qu, M., Wang, C., Xue, Y., Huang, H., Chen, Q., Sun, W., Zhou, X., Xu, G. and Jiang, X. A Dual-Cross-Linked Hydrogel Patch for Promoting Diabetic Wound Healing. *Small*, **18** (2), 160-172(2022).
9. Conti, P. Trauma: The invisible epidemic: How trauma works and how we can heal from it, Random House. (2022).
10. Pandey, V. K., Islam, R. U., Shams, R. and Dar, A. H. A comprehensive review on the application of essential oils as bioactive compounds in Nano-emulsion based edible coatings of fruits and vegetables. *Applied Food Research*, **10**, 32-42 (2022).
11. Antonelli, M. and Donelli, D. Efficacy, safety and tolerability of aroma massage with lavender essential oil: an overview. *International Journal of Therapeutic Massage and Bodywork*, **13**, 32(2020).
12. Bilia, A.R., Guccione, C., Isacchi, B.; Righeschi, C., Firenzuoli, F. and Bergonzi, M.C. Essential oils loaded in nanosystems: A developing strategy for a successful therapeutic approach. *Evid. Based Complement. Altern. Med.*, **2014**, 651593(2014).
13. Ferhat, M.A., Meklati, B.Y. and Chemat, F. Comparison of different isolation methods of essential oil from Citrus fruits: Cold pressing, hydrodistillation and microwave 'dry' distillation. *Flavour. Fragr. J.*, **22**, 494–504 (2007).
14. Masango, P. Cleaner production of essential oils by steam distillation. *J. Clean. Prod.*, **13**, 833–839. (2005).
15. Samuelson, R., Lobl, M., Higgins, S., Clarey, D. and Wysong, A. The effects of lavender essential oil on wound healing: A review of the current evidence. *The Journal of Alternative and Complementary Medicine*, **26**, 680-690 (2020).
16. Buch, R. M., Carlson, R. E. and Von fraunhofer, J. A. Frankincense: an ancient oil in the modern world. *Journal of Essential Oil Research*, **34**, 303-312 (2022).
17. Agwa, M. M., Sabra, S., Atwa, N. A., Dahdooh, H. A., Lithy, R. M. and Elmotasem, H. Potential of frankincense essential oil-loaded whey protein nanoparticles embedded in frankincense resin as a wound healing film based on green technology. *Journal of Drug Delivery Science and Technology*, **71**, 103-291(2022).
18. Liu, Q., Gao, Y., Fu, X., Chen, W., Yang, J., Chen, Z., Wang, Z., Zhuansun, X., Feng, J. and Chen, Y. Preparation of peppermint oil nanoemulsions: Investigation of stability, antibacterial mechanism and apoptosis effects. *Colloids and Surfaces B: Biointerfaces*, **201** (11), 16-26(2021).
19. Agarwal, P., Sebghatollahi, Z., Kamal, M., Dhyani, A., Shrivastava, A., Singh, K. K., Sinha, M., Mahato, N., Mishra, A. K. and Baek, K.-H. Citrus Essential Oils in Aromatherapy: Therapeutic Effects and Mechanisms. *Antioxidants*, **11**, (23)74 (2022).

20. Kazemi, M., Mohammadifar, M., Aghadavoud, E., Vakili, Z., Aarabi, M. H. and Talaei, S. A. Deep skin wound healing potential of lavender essential oil and licorice extract in a nanoemulsion form: Biochemical, histopathological and gene expression evidences. *Journal of Tissue Viability*, **29**, 116-124(2020).
21. Granata, G., Stracquadiano, S., Leonardi, M., Napoli, E., Malandrino, G., Cafiso, V., Stefani, S. and Geraci, C. Oregano and thyme essential oils encapsulated in chitosan nanoparticles as effective antimicrobial agents against foodborne pathogens. *Molecules*, **26**, 4055. (2021).
22. Wagle, S. R., Kovacevic, B., Walker, D., Ionescu, C. M., Shah, U., Stojanovic, G., Kojic, S., Mooranian, A. and AL-salami, H. Alginate-based drug oral targeting using bio-micro/nanoencapsulation technologies. *Expert Opinion on Drug Delivery*, **17**, 1361-1376(2020).
- 23- Souto, E. B., Cano, A., Martins-gomes, C., Coutinho, T. E., Zielińska, A. and Silva, A. M. Microemulsions and nanoemulsions in skin drug delivery. *Bioengineering*, **9**, 158(2022).
- 24- Malode, M. G. P., Chauhan, S. A., Bartare, S. A., Malode, L. M., Manwar, J. V. and Bakal, R. L.. A critical review on nanoemulsion: Advantages, techniques and characterization. *Journal of Applied Pharmaceutical Sciences and Research*, **4**, 6-12(2021).
- 25- Amiri-rigi, A., Abbasi, S. and Emmambux, M. N. Background, limitations, and future perspectives in food grade microemulsions and nanoemulsions. *Food Reviews International*, **1**, 39(2022).
- 26- Alyoussef, A., EL-gogary, R. I., Ahmed, R. F., Farid, O. A. A., Bakeer, R. M. and Nasr, M. The beneficial activity of curcumin and resveratrol loaded in nanoemulgel for healing of burn-induced wounds. *Journal of Drug Delivery Science and Technology*, **62**, 102360 (2021).
- 27- Abd-Rabou, A. A. and Edris, A. E. Frankincense essential oil nanoemulsion specifically induces lung cancer apoptosis and inhibits survival pathways. *Cancer Nanotechnology*, **13**, 22 (2022).
- 28- Ohkawa, H., Ohishi, N. and Yagi, K. Assay for lipid peroxides in animal tissues by thiobarbituric acid reaction. *Analytical biochemistry*, **95**, 351-358(1979).
- 29- Tietze, F. Enzymic method for quantitative determination of nanogram amounts of total and oxidized glutathione: applications to mammalian blood and other tissues. *Analytical biochemistry*, **27**, 502-522 (1969).
- 30- Jeschke, M. G., Van baar, M. E., Choudhry, M. A., Chung, K. K., Gibran, N. S. and Logsetty, S. Burn injury. *Nature Reviews Disease Primers*, **6**, 11(2020).
- 31- Souto, E. B., Ribeiro, A. F., Ferreira, M. I., Teixeira, M. C., Shimojo, A. A., Soriano, J. L., Naveros, B. C., Durazzo, A., Lucarini, M. and Souto, S. B. New nanotechnologies for the treatment and repair of skin burns infections. *International Journal of Molecular Sciences*, **21**, 393(2020).
- 32- Ahmed, S. A., Altaei, T. and Ahmed, T. Comparative study of the antioxidant effects of lavender and flax oils in recurrent aphthous ulceration treatment. *Journal of Baghdad College of Dentistry*, **32**, 42-50 (2020).
- 33- Hosny, E. N., Elhadidy, M. E., Sawie, H. G., Kilany, A. and Khadrawy, Y. A. Effect of frankincense oil on the neurochemical changes induced in rat model of status epilepticus. *Clinical Phytoscience*, **6**, 1-11 (2020).
- 34- Zhang, W., Shi, R., Gao, T., Hu, Y., Zhou, J., LI, C., Wang, P., Yang, H., Xing, W. and Dong, L. Repeated Inhalation of Peppermint Essential Oil Improves Exercise Performance in Endurance-Trained Rats. *Nutrients*, **15**, 2480 (2023).
- 35- Korkmaz, H. I., Flokstra, G., Waasdorp, M., Pijpe, A., Papendorp, S. G., DE Jong, E., Rustemeyer, T., Gibbs, S. and Van zuijlen, P. P. The Complexity of the Post-Burn Immune Response: An Overview of the Associated Local and Systemic Complications. *Cells*, **12**, 345 (2023).
- 36- Boukhatem, M. N., Sudha, T., Darwish, N. H., Chader, H., Belkadi, A., Rajabi, M., Houche, A., Benkebailli, F., Oudjida, F. and Mousa, S. A. A. New eucalyptol-rich lavender (*Lavandula stoechas* L.) essential oil: Emerging potential for therapy against inflammation and cancer. *Molecules*, **25**, 3671(2020).
- 37- Khajehdehi, M., Khalaj-kondori, M. and Baradaran, B. Molecular evidences on anti-inflammatory, anticancer, and memory-boosting effects of frankincense. *Phytotherapy Research*, **36**, 1194-1215 (2022).

-
- 38- Nayak, P., Kumar, T., Gupta, A. and Joshi, N. Peppermint a medicinal herb and treasure of health: A review. *Journal of Pharmacognosy and Phytochemistry*, **9**, 1519-1528 (2020).
- 39- Woranuch, S. and Yoksan, R. Eugenol-loaded chitosan nanoparticles: I. Thermal stability improvement of eugenol through encapsulation. *Carbohydr Polym.*, **96**(2),578-585(2013).
- 40- Faridzadeh, A., Salimi, Y., Ghasemirad, H., Kargar, M., Rashtchian, A., Mahmoudvand, G., Karimi, M. A., Zerangian, N., Jahani, N. and Masoudi, A. Neuroprotective potential of aromatic herbs: rosemary, sage, and lavender. *Frontiers in Neuroscience*, **16**, 967 (2022).
- 41- AL-dahmash, N. D., AL-ansari, M. M., AL-otibi, F. O. and Singh, A. R. Frankincense, an aromatic medicinal exudate of *Boswellia carterii* used to mediate silver nanoparticle synthesis: Evaluation of bacterial molecular inhibition and its pathway. *Journal of Drug Delivery Science and Technology*, **61**, 102337 (2021).
- 42- Mohammadifar, M., Aarabi, M. H., Aghighi, F., Kazemi, M., Vakili, Z., Memarzadeh, M. R. and Talaei, S. A. Anti-osteoarthritis potential of peppermint and rosemary essential oils in a nanoemulsion form: behavioral, biochemical, and histopathological evidence. *BMC Complementary Medicine and Therapies*, **21**, 1-12 (2021).
- 43- Amirzade-Iranaq, M.H., Tajik, M., Takzaree, A., Amirmohammadi, M., Rezaei Yazdi, F. and Takzaree, N. Topical *Mentha piperita* effects on cutaneous wound healing: A Study on TGF- β Expression and Clinical Outcomes. *World J. Plast. Surg.*, **11**(1),86, 86-96 (2022).
- 44- Han, X., Beaumont, C. and Stevens, N. Chemical composition analysis and in vitro biological activities of ten essential oils in human skin cells. *Biochim. Open*, **5**, 1-7 (2017).

تقييم تأثير تركيبة نانو زيوت اللافندر واللبان والنعناع عبر الجلد على نشاط التئام الجروح في نموذج الفئران

جيهان صفوت^١، زينب الجندي^٢، لمياء رمضان^٣، هاجر نبيل فتحي^٤، أميمة حامد عزو^٥، ميريت رستم^٦ و فايز فودة^٧
^١ كلية التكنولوجيا الحيوية - جامعة أكتوبر للعلوم الحديثة والآداب - الجيزة - مصر.
^٢ قسم الصيدلة - معهد البحوث الطبية والدراسات الإكلينيكية - المركز القومي للبحوث - الدقي - الجيزة - مصر.
^٣ قسم الكيمياء الحيوية - معهد بحوث التكنولوجيا الحيوية - المركز القومي للبحوث - الدقي - الجيزة - مصر.
^٤ كلية الصيدلة - جامعة الزقازيق - الزقازيق - مصر.
^٥ قسم التناسل الحيواني والتلقيح الصناعي - معهد البحوث البيطرية - المركز القومي للبحوث - الدقي - الجيزة - مصر.
^٦ أكاديمية البحث العلمي والتكنولوجيا - القاهرة - ص.ب ١١٥٦٢.
^٧ معهد البحوث الطبية والدراسات الإكلينيكية - المركز القومي للبحوث - الدقي - الجيزة - مصر.

الحروق هي أحد الأسباب الرئيسية للوفيات وارتفاع معدلات الإصابة بالأمراض، خاصة عندما تقترن بالعدوى البكتيرية التي تمنع التئام الجرح وتؤخر عملية الشفاء. وبالتالي، هناك طلب كبير على التقنيات الصيدلانية للمساعدة في حل هذه المشكلة. أصبحت الزيوت الأساسية أكثر شعبية كبديل عضوية للأدوية الاصطناعية. ومع ذلك، فإن استخدام الزيوت العطرية محدود نظرًا لضعف جودتها ولكن يمكن الاستفادة منها بتغليفها في مستحلبات النانو. الهدف من هذه الدراسة هو دراسة تركيبة رذاذ النانو التي تحتوي على مزيج من زيوت اللافندر واللبان والنعناع لإمكانية شفاء الحروق باستخدام نموذج حرق الفئران. تم فحص تأثير مستحلبات النانو المكونة من ٢٪ لافندر، ١٠٪ نعناع، ٥٪ لبان، مزيج الزيوت الثلاثة بنصف تراكيزها والمزيج بنفس التراكيز على الدلالات الليفية ودلالات الإجهاد التأكسدي والهستوباثولوجي. تدعم نتائجنا استخدام الزيوت العطرية في تطوير المستحضرات الصيدلانية لإدارة الجروح و/أو الأمراض المرتبطة بالالتهابات. تركيبة رذاذ نانو عبر الجلد تحتوي على مزيج من زيوت اللافندر واللبان والنعناع أظهرت نشاطًا كبيرًا في التئام الجروح.

الكلمات المفتاحية: زيوت مستحلب النانو، التئام الحروق، زيت اللافندر، زيت النعناع، زيت اللبان، تركيبة رذاذ.