



Histopathological Effects of Anabolic Androgenic Steroids (Nandrolone Decanoate) on Heart, Liver and Kidney of Male Local Rabbits



Taghreed Hazem Saber Alfakje* and Faehaa Azhar Al-Mashhadane

Department of Dental Basic Sciences, College of Dentistry, University of Mosul, Mosul, Iraq

Abstract

NANDROLONE decanoate consider as one of the group of anabolic steroids used by athletic with high dose to enhance athletic ability and build muscles. It was found that the use of high dose of these compounds affects the heart, liver and kidneys. Therefore, this study aims to research the histopathological outcome of the drug Nandrolone on the heart, liver and kidneys in adult rabbits. Six adult rabbits were used in this research, and these animals distributed into 2 groups as 3 rabbits in each. The group one considered a control, the second group was given a dose of (10 mg/kg) of nandrolone decanoate\ IM injection for (15 consecutive days). After (24) hours of giving the last dose, the rabbits were slaughtered and samples were taken from the heart, liver and kidney, and they were prepared for histological study by light microscopy. This study showed clear alteration in the structure of the heart muscle, represented in the infiltration of inflammatory cells, vacuolar degeneration, Zenker's necrosis and vascular congestion. In the liver also observed inflammatory cells infiltration, vacuolar degeneration, hyperplasia of lining of bile duct, fibrosis and sinus congestion. In the kidneys, vacuolar degeneration, atrophy and congestion of the glomeruli, expansion of the urinary space and cysts formation were noted. We conclude from the current study that the drug nandrolone has a harmful effect on the histological composition of the heart muscle, liver, kidney in adult rabbits, so the current study recommends limiting the excessive use of this drug.

Keywords: Androgenic anabolic steroid, Liver, Heart, Kidney, Rabbits.

Introduction

Anabolic androgenic steroids (AASS) are a kind of synthetic compounds which is resemble testosterone produced naturally by the body [1]. Young people frequently use AASS to increase muscular tone or growth for cosmetic reasons and sports performance [2, 3]. Research have examined the potential negative effects of using or abusing AASS in children [4, 5]. Although anabolic steroids can be utilized for a variety of medical conditions, the use is typically linked by a number of negative side effects. Curative, dose seem to have less side effect, however supraphysiological doses are linked to significant and severe side effect, hence these side effects are typically dose – related [6]. AAS use for a long period of time may cause aberrant endogenous hormone release, leading to either reversible irreparable harm.

Increased oil secretion from sebaceous glands which results in dermatological conditions such as

the acne vulgaris, cases of androgenic alopecia, and the hypertrichosis, is the most frequent adverse effect of AAS [7]. AAS can also cause several sex issues, including male infertility, importance a zoospermia, and testicular atrophy [8, 9]. Abuse of AAS in women can lead to changes in voice, amenorrhea, uterine atrophy, and cortical hypertrophy [9]. AAS abusers are substantially more likely to suffer tendon ruptures, which can be fatal to an athlete's career [10]. AAS dependence syndrome, headache, irritability, and depression are among the psychobehavioral disorders that long term use of AAS is likely to experiment [11]. In some situations, resulting in violence and suicide [12]. An excessive oral AAS burden can result in damage of the liver or the kidney, as coagulation malfunction, the liver fibrosis, the renal hypertrophy and failure.

A too much oral AAS load is processed via the hepatorenal damage [12,13]. Abuse of AAS also raises cardiovascular risk and poses a major threat to user's safety (7, 14). Nandrolone decanoate is class II

*Corresponding author: Taghreed H.S. Alfakje,, E-mail: taghreedhazem@uomosul.edu.iq , Tel.: +964 770 063 9080

(Received 24/01/2024, accepted 08/03/2024)

DOI: 10.21608/EJVS.2024.265138.1805

©2024 National Information and Documentation Center (NIDOC)

androgenic steroids that rapidly spread in the world and clinically used and illicitly composed of 19 – nortestosterone – derivatives [15].

The enzyme 5 α - reductase mostly breaks down nandrolone decanoate into 5 α -dihydroandrolone, 19– nortestocholanolone. Urine tests can find these metabolites [16]. Despite therapeutic benefits, nandrolone usage that is uncontrolled and prolonged leads to negative effects such as liver toxicity, thyroid function changes, and cardiovascular toxicities [17].

The objective of current study is to find out the impact of nandrolone decanoate management on heart, the liver and the kidney in male local rabbits.

Material and Methods

Ethical Approval

The present research was carried out in the animal house and the scientific research laboratory after approving by the study ethics committee and scientific committee / Dental Basic science / Dentistry College / University of Mosul. No. UOM. Dent.23/30 in 31/5/2023.

Experimental Design

Six male rabbits weighing (1.5–2 kg) and (10–12 months) old made up the sample. Veterinarian will examine them both before and after the operation to assess their condition and overall health. They were given the standard rodent and kept in separate cages with tap water. Animals distributed into two categories at random, with three rabbits in each group.

Group 1: Control group, animals treated by D.W intramuscular injection and served as control.

Group 2: (ND) treated group. The rabbits give nandrolone decanoate (10 mg / kg), IM injection once per day for (15 days).

Tissue harvesting procedures

Animals were sacrificed at the end of the experiment, their organs the heart, the liver and the kidney removed, samples measuring (0.5cm³) were taken, fixed in 10% neutral formalin for 24 hours, washed, dehydrated increasing alcohol concentrations, cleared in xylene, and then embedded in paraffin.

After that, specimen sectioned at a thickness of 5 μ m. The tissues section stained by HandE stain, using the light microscope for histopathological analysis.

Results

After 15 days of the experiment, the histological alterations of the heart, the liver and kidney examined in all groups of rabbits employed in the current investigation.

Control Group

The Heart

The findings of microscopic analysis of cardiac tissue sections from control group rabbits, as well as the typical histological structure of myocardial fibers. The myocardial cytoplasm, a central oval nucleus, and intracellular space with capillaries as shown in Fig. (1).

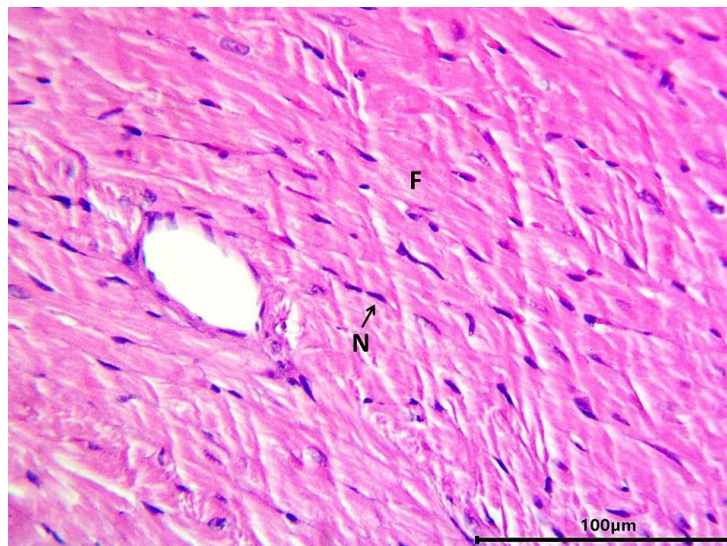


Fig. 1. Microphotograph showing a section of heart tissue of rabbits in control – note elongated cardiac muscle fibers (F) and a central oval nucleus (N) : HandE 400X.

The Kidney

Microscopic analysis of kidney tissue sections from rabbits in the control group revealed that their kidneys had a normal histological structure. The included blood arteries, tubules, interstitial tissue, and renal corpuscles

(glomerulus, Bowman capsule, and Bowman an space). Large pyramidal cells with an acidic cytoplasm and a big, rounded nucleus line the proximal renal tubules. Microvilli called brush boundary emerge into the tubule lumen from the cells surfaces. The distal tubules in contrast , have a broader lumen , shorter cells , and less acidic cytoplasm as shown in Fig. (2).

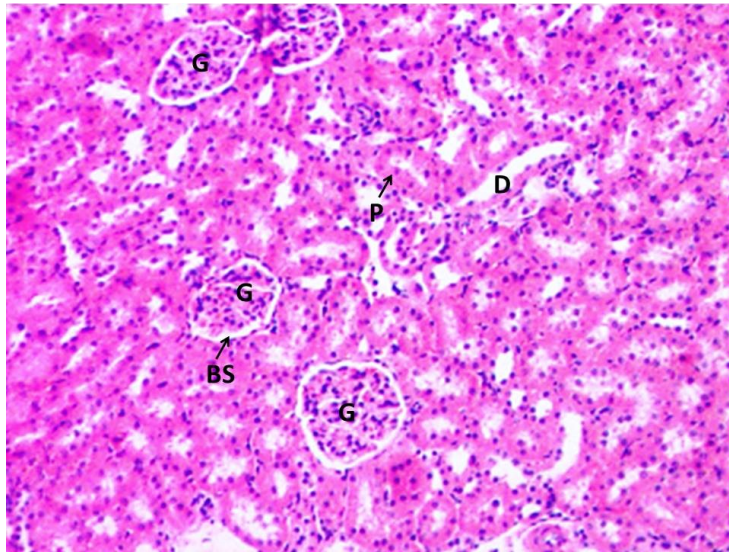


Fig. 2. Microphotograph showing a section in kidney tissue of the control rabbits , note renal glomerulus (G), Bowman's space (BS), Proximal convoluted tubules (P), distal convoluted tubule (D). HandE 100X.

The Liver

Microscopic analysis of liver tissue slices from rabbits in the control group revealed that the liver had a normal histological structure. Hepatic cords or plates radiate from the central vein and are made up of relatively large cells with polyhedral shaped (ribs) arrangements. Contain spherical nuclei and cytoplasm that is acidic. Blood sinusoids that run into the central vein and are bordered with rows of epithelial and kupffer cells separate the hepatic cords as shown in Fig. (3).

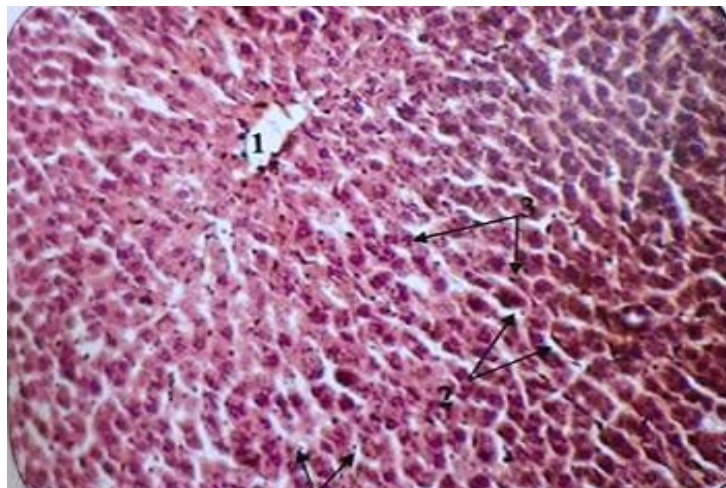


Fig. 3. Microphotograph showing a section of liver tissue of control rabbits, shows central vein, with Sinusoids, the hepatic cords, kupffer cells, Hand E 100X.

Anabolic androgenic Steroids (Nandrolone Decanoate)

The Heart

Microscopic analysis of cardiac tissue sections from rabbits treated with anabolic steroids from revealed the development of inflammatory cell infiltration, vacuolar degeneration, and zinker necrosis, as shown in the Fig. (4). As shown in the Fig. (5). further signs of damage include the infiltration of inflammatory cells. Vacuolar degeneration, clogged blood vessels, and Zinker necrosis in the other location. Vacuolar degeneration and blood

vessels congestion were also seen in another location, as shown in the Fig. (6). Infiltration of inflammatory cells, vacuolar degeneration, blood vessel congestion, and Zinker necrosis were also seen in some area as shown in figures (7, 8).

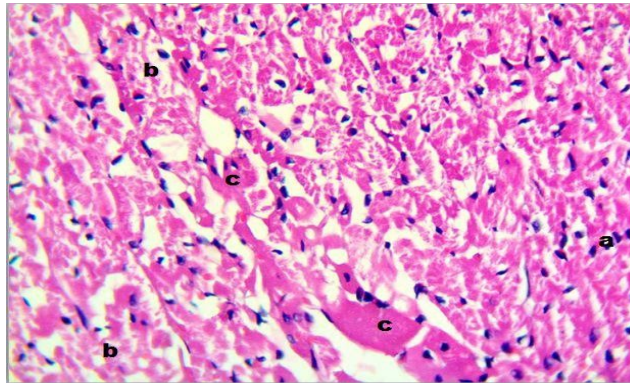


Fig. 4. Microphotograph showing a section of the heart tissue of the Nandrolone decanoate group rabbits, note : mild infiltration of inflammatory cells (a), vacuolar degeneration (b), and zinker necrosis (c), HandE, 400X.

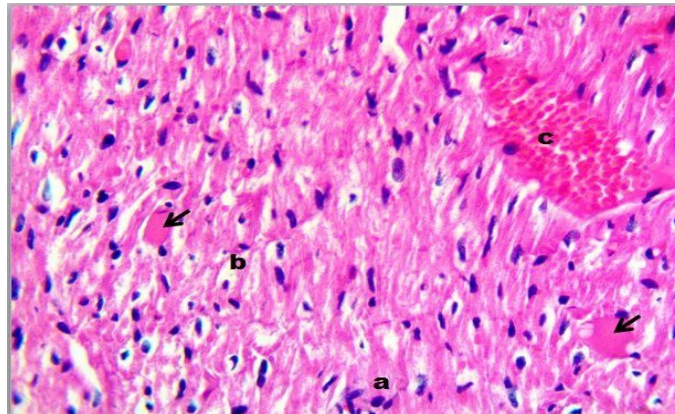


Fig. 5. Microphotograph showing a section of the heart tissue of the Nandrolone decanoate group rabbits, note : mild infiltration of inflammatory cells (a), vacuolar degeneration (b), blood vessels congestion (c) and zinker necrosis (arrow). HandE, 400X.

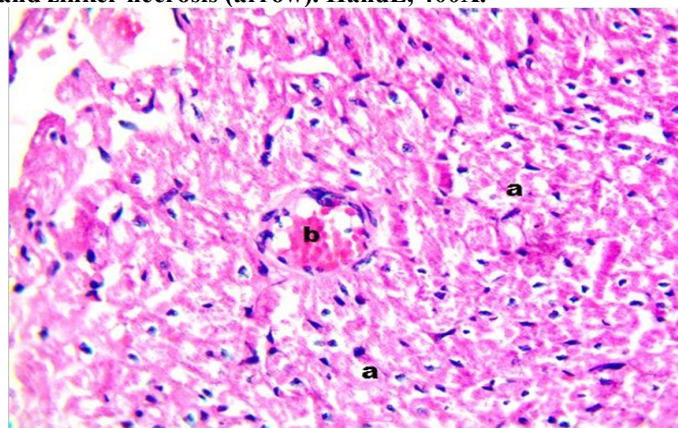


Fig. 6. Microphotograph showing a section of the heart tissue of the Nandrolone decanoate group rabbits, note :vacuolar degeneration(a), blood vessels Congestion (b). HandE stain, 400X.

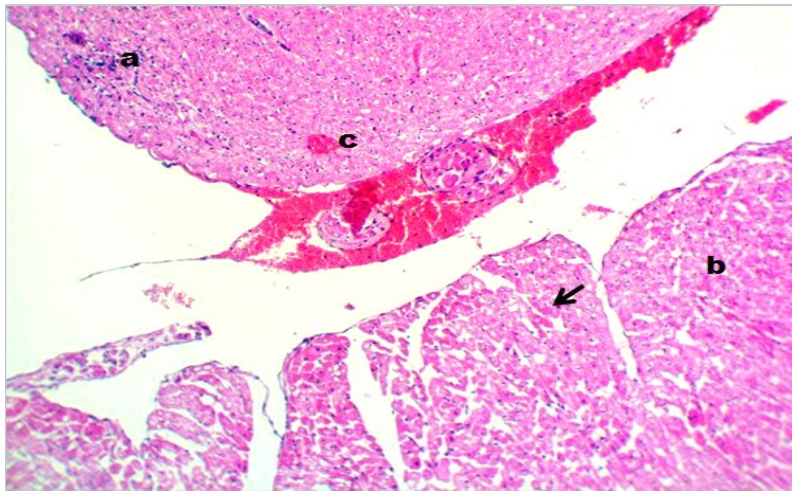


Fig. 7. Microphotograph showing a section of the heart tissue of the Nandrolone decanoate group rabbits, note: mild infiltration of inflammatory cells (a), vacuolar degeneration (b), blood vessels congestion (c) and zinker necrosis (arrow). HandE stain, 400X.

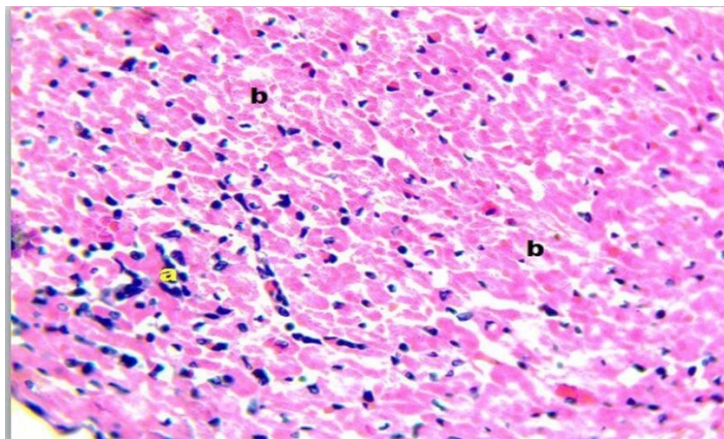


Fig. 8. Microphotograph showing a section of the heart tissue of the Nandrolone decanoate group rabbits, note: mild infiltration of inflammatory cells (a), vacuolar degeneration (b). HandEstain, 400X.

The Kidney

As can be seen in the figures (9, 10, 11) Microscopic analysis of kidney tissue sections from anabolic steroid. exposed rabbits revealed numerous histological alterations, such as vacuolar degeneration, glomerular atrophy, enlarged urinary spaces, and kidney cysts. Mild atrophy, glomeruli congestion, and cyst formation were also seen in another location, as shown in Fig. (12).

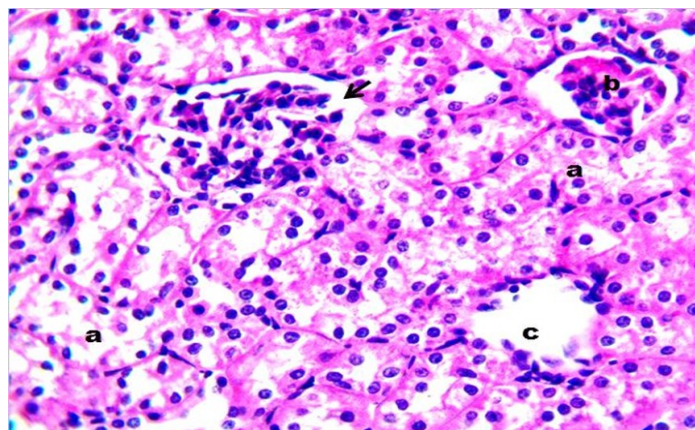


Fig. 9. Microphotograph showing a section of the kidney tissue of the Nandrolone decanoate group rabbits, note : mild vacuolar degeneration(a), atrophy of glomeruli (b) urinary space dilatation (arrow) and cyst kidney (c), HandE stain, 400X.

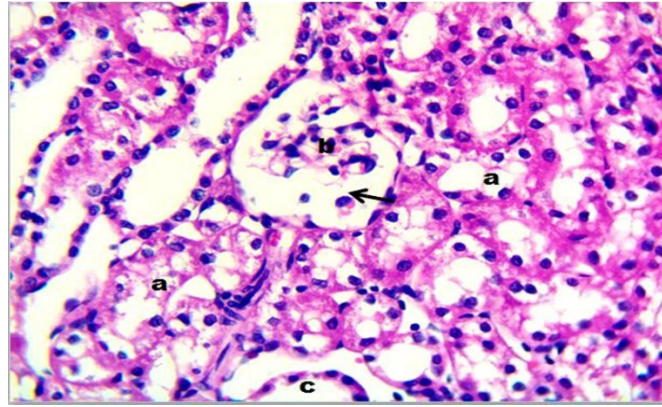


Fig. 10: Microphotograph showing a section of the kidney tissue of the Nandrolone decanoate group rabbits, note :vacuolar degeneration (a), atrophy of glomeruli (b), urinary space dilatation (arrow) and cyst kidney (c). HandE stain, 400X.

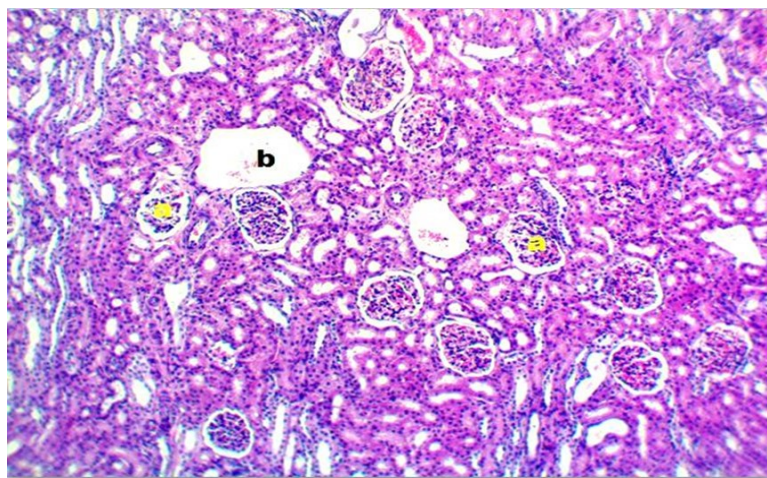


Fig. 11. Microphotograph showing a section of the kidney tissue of the Nandrolone decanoate group rabbits, note: atrophy of glomeruli (a), urinary space dilatation (arrow) and cyst kidney (b). HandE stain, 400X.

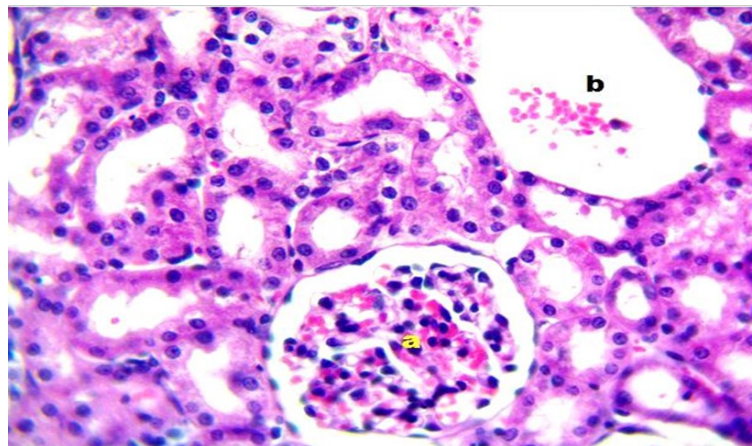


Fig. 12. Microphotograph showing a section of the kidney tissue of the Nandrolone decanoate group rabbits, note: mild atrophy and congestion of glomeruli and cyst formation (b). HandE stain, 400X.

The Liver

Microscopic analysis of liver tissue sections from rabbits given anabolic steroids revealed hyperplasia, sever vacuolar degeneration, necrosis, and infiltration of inflammatory cells, as shown in Fig. (13).

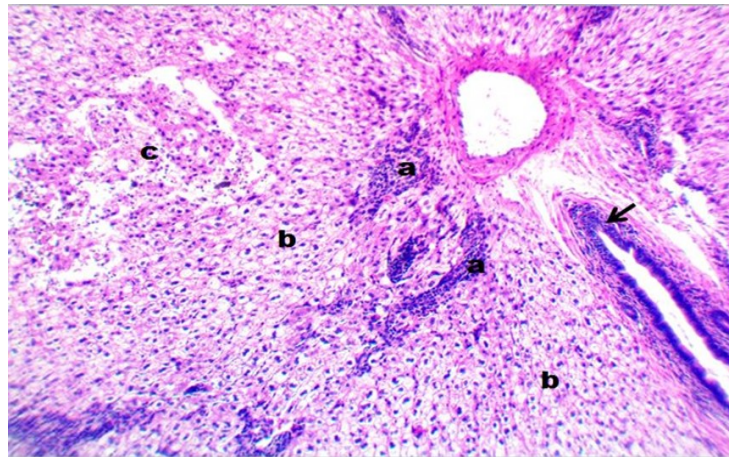


Fig. 13. Microphotograph showing a section of the liver tissue of the Nandrolone decanoate group rabbits, note :infiltration of inflammatory cells (a) , sever vacuolar degeneration (b) , necrosis (c) , and hyperplasia of bile ductule (arrow). HandE stain, 100X.

As seen in the figures (14). There was also fibrosis present in that location, along with sever vacuolar degeneration , hyperplasia of the bile ducts , and infiltration of inflammatory cells. There was also modest infiltration of inflammatory cells in the portal area, diffuse vacuolar degeneration, and hyperplasia of the bile duct in some area of the liver tissue, as shown in figures (15). Also as shown in the figures (16). There was sinusoidal congestion.

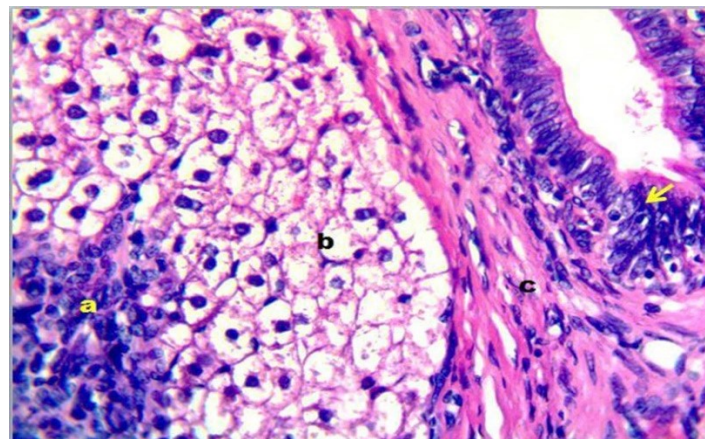


Fig. 14. Microphotograph showing a section of liver tissue of Nandrolone decanoate group rabbits, note : infiltration of inflammatory cells (a) , sever vacuolar degeneration (b), fibrosis (c) and hyperplasia of bile ductule cells. HandE stain, 400X.

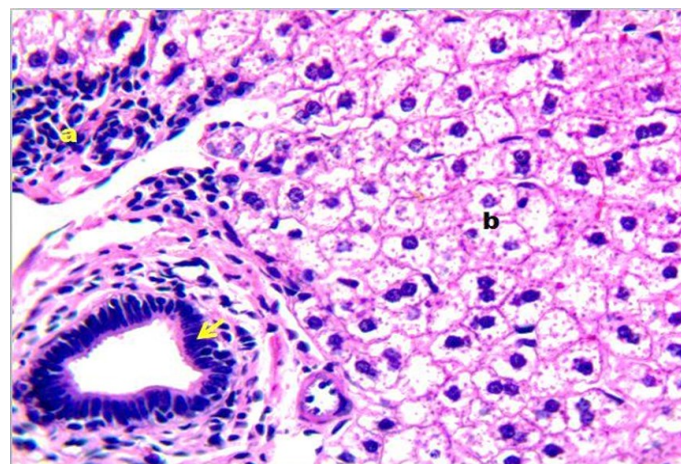


Fig. 15. Microphotograph showing a section of liver tissue of Nandrolone decanoate group rabbits, note : infiltration of inflammatory cells in portal area (a), diffuse vacuolar degeneration (b), and hyperplasia of bile ductule (arrow). HandE stain, 400X.

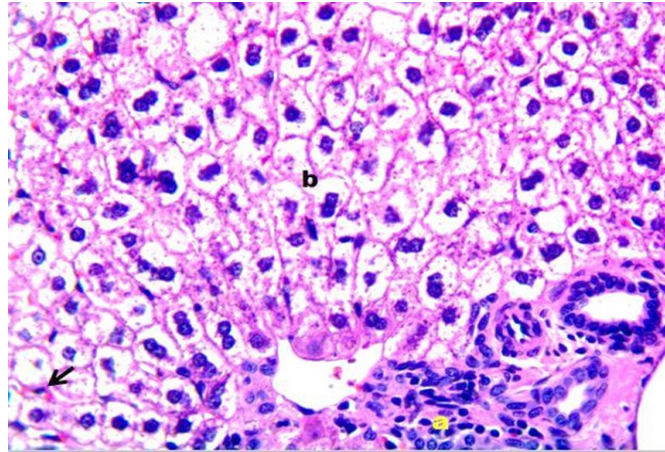


Fig. 16. Microphotograph showing a section of liver tissue of Nandrolone decanoate group rabbits, note : mild infiltration of inflammatory cells in portal area (a), diffuse vacuolar degeneration (b), and sinusoidal congestion (arrow). HandE stain, 400X.

Discussion

Although anabolic steroids can be utilized for a variety of medical conditions, using is typically combined with a number of negative side effects. While therapeutic levels seem to have few side effects, but supraphysiological doses are linked to significant and severe side effects, these adverse effects are typically does – relates [6].

A cording to National Institute on medicine abuse [18]. Nandrolone Decanote (ND) is one of most popular testosterone anabolic derivatives since it has a moderate androgenic potential and the best anabolic qualities [19]. The heart muscle fibers in this investigation had sever ischemia degradation together with obvious inflammatory infiltration. This may be the reason athletes who use AAS experience deadly arrhythmias. ASS nandrolone in malarate impacted left ventricular remodeling in (2000), according to Woodimiss and others [20], Without causing heart muscle injury. This might be related to the lower dose they utilized.

Androgens operate by receptor – dependent, means receptors are current in cardiovascular system, in human vascular endothelium, smooth muscle tissue, macrophage, cardiac myocytes, could be linked to the mechanisms of AAS promotes cardiac muscle injury. Moreover, testosterone directly affects transcription translation, and enzyme function in the myocardium as it is the preferable binding of the androgen receptor (21). In the physiological dose range, AAS has a protecting impact on the cardiovascular system. Nevertheless, supraphysiological AAS doses result in cardiovascular system toxicity, which sharply raises the risk of cardiovascular disease. The exact cause of AAS toxicity is still unclear. A cording to studies, there are two main mechanisms. One of them is AAS gene regulation, in which AAS or their metabolites bind to

AAS and cause these receptors to change conformation [20,21].

The study recorded sever ischemic damage of heart muscle fiber with inflammatory signs. this may be cause of fatal case of arrhythmias in the athletes use AAS [22]. Several research have revealed and suggested that the toxicity of AAS is connected to oxidative damaging and tissue damage [22], by modification of the mitochondrial respiratory chain complexes activity (23). Causing reactive oxygen species ROS, and causing harmful effective on cell. Many reactive oxygen species (ROS) produced can cause oxidative damage, which can injury the cells and eventually lead to cell death and a variety of degenerative diseases [24]. Cytochrom p-450 mono–oxygenases metabolize high dosages of nandrolone decanote. Reactive oxygen species are produced as a result, which increases the activity of antioxidant enzyme until they are exhausted [25].

Moreover, anabolic steroids boost the lipase enzyme's action, which increase the availability of long chain fatty acids for mitochondrial oxidation and ATP productions resulting in the developing of lipid peroxidation and the formation of ROS [26]. mechanism for AAS produce cardiac muscle injury by receptor dependent and receptors – independent mechanisms. the Androgen receptor in cardiovascular system, include the human vascular endothelium and smooth muscle fibers, also the cell of macrophages and cardiac myocyte cells. Testosterone is ligand preferred of human androgen receptor in the myocardium and directly modulates transcription, translation, and enzyme function. AAS cause damaging associated with the apoptosis [27, 28, 29]. AAS has a protective impact on cardio – vascular system in physiological doses. Suprophysiological AAS dose cause toxicity in cardio vascular system, which substantial increase cardiovascular injury. The mechanisms of toxicity of AAS not fully detected.

Others found two main mechanisms, the first one was the regulation of AAS genes it means AAS or its metabolite link to ARS, that cause a case of conformational alteration of the receptor. AR dimers then will transport from cytoplasm into nucleus where dimers combined by androgen reacting element in DNA, then regulate the gene transcription in cooperative by active (or in activation) of coregulations, which result in toxic effects [30]. Other non-gene regulation mechanisms (in the skeletal muscle cell and the prostate cancer cells) is the AR dimers combined by the cytoplasmic protein by a different of signaling pathway which is mainly produce the toxicity no gene transcription pathway[30]. toxicity of AAS is connected to a range of aspect like doses, cycle and individual difference.

In (2005), Du Toit *et al.* [31]; recorded that the suprphysiological dose of AAS, which is taken throughout the exercise training or according to inactive condition elevated myocardial susceptibility to the ischemia or reperfusion damage. The increasing sensitivity linked to steroid – induce increasing in pre-ischemic myocardial CAMP concentration and increasing in both of pre-ischemic and reperfusion of the tumor necrosis factor TNF- α concentration. Kahal and Allem, [31], recorded in this study enlargement, sever degenerate ion and the heart muscle damage. The findings support Hassan *et al.* [32]. Study, which found that " As sustaining produces significant ischemia necrosis and degeneration the heart muscle fibers in male albino rats ". Moreover, Elgend *et al.* [33], informed on hypertrophy and degenerate of both of cardiac muscle and skeletal muscle, explain by citing its effect on extensively distribute androgen receptor in many type of muscles.

Al most anabolic steroids experience many side effects as the liver toxicity [34]. Because of the secrecy around the use of large doses of androgens, limited data on the relationship of adverse effects to doses or substances used are available. While some symptoms are caused by androgenic or estrogenic actions, others may be caused by the toxic (non-hormonal) consequences of the androgen or its metabolites, particularly when the dose is very high [35]. More hepatocytes were harmed by vascular degeneration, particularly those near the central venules, since these cells were more exposed to hypoxia than those near the portal area [36]. Vacuolar degeneration affected nearly all hepatocytes, and areas of localized necrosis were frequently infiltrated with monoclear inflammatory cells. This is consistent with the findings of Boada, who discovered centrilobular degeneration and lipidic vacuolization in male rats given large doses of anabolic androgenic steroids. Vieira *et al.* [37], discovered that subchronic treatment with nandrolone decanoate, primarily at higher doses, is potentially toxic to the liver and causes fibrosis. [38].

A cause of spontaneous hepatic rupture with life-threatening bleeding has been linked to a history of anabolic steroid usage. In (2011), Tousson *et al.*, [39,40] showed that sinusoid and centrolobular necrosis occurs as a result of anabolic androgenic steroids' ability to cause hepatocyte injury via their effect on mitochondria, specifically the mitochondrial membrane, and inhibit mitochondrial respiration, resulting in mitochondrial swelling and ALT and AST leakage. This study found fibrosis in the portal area, which means that the liver goes to healing the damaged cells caused by fibrosis in the portal area rather than regeneration of other hepatocytes because the damage is powerful and strong, and regeneration may take more than 15 days because anabolic steroids remain in the tissue after administration is stopped [41]. Proposed mechanisms of liver injury include anabolic steroid-induced infiltration of inflammatory cells in the hepatic tissue and activation of kupffer cells, which results in the production of inflammatory cytokines and collagen deposition; increased oxidative stress and reactive oxygen species, which leads to mitochondrial degeneration in liver cells; and stimulation of intracellular androgenic steroid receptors, which leads to uncontrolled growth of hepatocytes [30].

An in vitro study published in 2021 found that mitochondrial respiratory chain processes are disrupted early in the pathophysiology of liver injury caused by suprphysiologic dosages of nandrolone, an asynthetic AAS extensively used for performance enhancement. It particularly inhibits respiratory chain complexes I and III, causing reactive oxygen species buildup and oxidative damage [42]. Animal investigations revealed a decrease in glutathione and enzymes that act as free radical scavengers (superoxide dismutase and catalase), as well as an increase in thiobarbituric acid - a reactive compound indicating poor redox equilibrium [34, 44].

Oxidative stress disrupted mitochondrial membrane potential dynamics, resulting in decreased cell energy supply, hepatocyte dysfunction, and necrosis [45]. Chronic AAS use was known to produce a number of changes. Renal illnesses have received less attention among these conditions, most likely because they are less common and hepatotoxicity has been thoroughly studied [46, 47].

Nephrotoxic side effects have been documented, such as renal failure or wilms tumours [48, 49]. AAS illicitly used by athletes for decades to increase muscle mass and decrease body fat [50], are emerging as podocyte toxins in long term abusers [48]. Until now, the effects of AAS on kidney structure have often included the following: glomerular and tubular atrophy, vacular degeneration, congestion, necrosis, interstitial fibrosis, inflammatory interstitial nephritis, and segmental glomerulosclerosis [51, 49].

The current investigation found significant histological damage to the rabbit renal cortex after 2 weeks of AAS treatment. Congestion in both glomerular capillaries and interstitial blood vessels has been practically universal in this group. Similarly, Kahal and Allem, 2018 reported congestion of renal blood vessels and interstitial hemorrhage following AAS a base in adult male mice and added that it persisted and even worsened after stopping treatment [50]. The observed congestion could also be attributed to the AAS- that induced PCT which increase in width and luminal deprivation [51,52], congest ion was accompanied by a rise in PCT diameter and obstruction of their Lumina by swelling cells and ischemia-associated cell debris.

A recent study found a relationship between glomerular damage and tubular interstitial injury, with podocyte damage causing substantial plasma protein leakage into the tubules. These proteins were reabsorbed by the PCT, resulting in the release of mediators such as monocyte chemoattractant protein type 1, platelet-derived growth factor, and endothelin into the interstitium. These mediators cause an inflammatory response that results in interstitial fibrosis and tubular degeneration [53]. Similarly, Hasso, [45], observed vacuolar degeneration of the PCT lining epithelium with sloughing and necrosis of the epithelial cells and engorgement of numerous interstitial blood vessels in male rabbits following ND treatment. According to Sood *et al.* [55], necrotic nuclei and brush border separation indicate functional impairment of urine reabsorption.

This necrosis could be linked to mitochondrial injury and subsequent cellular ATP depletion [55]. Furthermore, mitochondrial damage can result in intracellular oxidative stress and higher ROS levels due to disruption of the mitochondrial electron transport chain [56]. Brenu *et al.*, [57]. Suprophysiological dosages of ND increase the production of inflammatory cytokines, interleukin-1 beta (IL-1 β), and tumor necrosis factor- β (TNF- β) in human peripheral blood lymphocyte cultures in vitro [57].

TNF - has been identified as a cytotoxic that produces apoptosis in numerous cells, including renal tubular cells, either through association with its membrane - bound receptor or by triggering mitochondrial membrane disruption and cytochrome C release [58]. Long-term administration of ND. resulted in a decrease in antioxidant enzyme activity, which resulted in oxidative renal cell injury due to its decreased ability to scavenge harmful hydrogen peroxide and lipid peroxides [59].

Anabolic androgenic steroids may contribute to the development of CKD by generating reactive oxygen species and causing oxidative stress [60] Testosterone can increase endothelin synthesis directly or indirectly (via RAAS). As a result,

testosterone may have a role in both kidney fibrosis and ischemia-reperfusion injury via both local and systemic endothelin effects [61]. Other laboratories have shown that renal tissues are more sensitive to oxidative tissue injury due to the high content of long-chain polyunsaturated fatty acids [62]. Furthermore, extremely high metabolic rates result in excessive free radical production [63]. Renal tissue damage is caused by reactive oxygen species produced by kidney cells or toxic substances introduced to the kidney, both of which contribute to a number of nephron-degeneration disorders [64]. Androgen receptors (ARS) are expressed in many human tissues, including the kidney. AAS operates by binding to these receptors to boost endogenous testosterone synthesis. The increased testosterone production has an effect on the glucocorticoid receptors, which decrease glucose synthesis and protein catabolism. As a result, renal tissue expands and distorts [65- 67]. Memudu and Dongo, recently reported that the pathophysiology of nephron toxicity caused by a hazardous chemical is characterized by increased lipid peroxidation and decreased SOD level in the presence of AAS-induced oxidative tissue damage, which resulted in the loss of renal tissue cell membrane integrity [68].

More research is needed to overcome this study's limitations and examine the impact of anabolic steroids on overall health.

Conclusion

In rabbits, nandrolone discount at a dose of 10 mg/kg for 15 days had a notable effect on the heart, liver, and kidney. It can cause significant disruption in tissue architecture.

Acknowledgments

The authors are appreciative to the University of Mosul /College of Dentistry for providing facilities that helped to increase the quality of this work.

Conflicted interest: None

References

1. Raman, R.M., Roman, D.L. and Ostafe,V. Computational assessment of pharmacokinetics and biological effects of some anabolic and androgen steroids. *Pharma Res.*, **35**(2),41. (2018).
2. Esposito, M., Licciardello, G. and Privitera, F. Forensic post-mortem investigation in AAS abusers: investigative diagnostic protocol. A systematic review. *Diagnostics (Basel)*, **11**(8),1307(2021).
3. Mullen, C., Whalley, B.J. and Schifano, F. Anabolic androgenic steroid abuse in the United Kingdom: an update. *BMJ Form.*, **177**, 2180-2198(2020).
4. Albano, G.D., Amico, F. and Gocimano, G. Adverse effects of anabolic androgenic steroids: a literature review. *Healthcare (Basel)*, **9**, 97(2021).

5. Ajorenbekk, A., Westlye, L.T. and Walhoved, K.B. Cognitive performance and structural brain correlates in long-term anabolic androgenic steroid-exposed and unexposed weightlifters. *Neuropsychology*, **33**, 547 (2019).
6. Reyes-Vallejo, L. Current use and abuse of anabolic steroids. *Actas Urol. Esp. (Engl Ed.)*, **44**(5),309-313 (2020).
7. Pope, H.G., Jr, Wood R.I. and Rogol, A.D. Adverse health consequences of performance-enhancing drugs: an Endocrine Society scientific statement. *Endocr. Rev.*, **35**, 341-375(2014).
8. Armstrong, J.M., Avanta, R.A. and Charchenko, C.M. Impact of anabolic and androgenic steroids on sexual function. *Translational Andrology and Urology*, **7**, 483-489(2018).
9. Neischlag, E., Vorona, E. and Meehan, W.R. Medical consequences of doping with anabolic androgenic steroids: effects on reproductive functions. *European Journal of Endocrinology*, **173**(Suppl 1), R47-R58 (2015).
10. Kanayama, G., Deluca, J. and Meehan, W.P. Ruptured tendons in anabolic-androgenic steroid users: a cross-sectional cohort study. *American Journal of Sports Medicine*, **43**, 2638-2644(2015).
11. Medras, M., Brona, A. and Jozkow, P. The central effects of androgenic-anabolic steroid use. *Journal of Addictive Medicine*, **12**, 184-192(2018).
12. Dodge, T. and Hoagland, M.F. The use of anabolic androgenic steroids and polypharmacy: review of the literature. *Drug and Alcohol Dependence*, **114**, 100-109(2011).
13. Bond, P., Llewellyn, W. and Van Mol, P. Anabolic androgenic steroids induced hepatotoxicity. *Medical Hypotheses*, **93**, 150-153(2016).
14. D'Andrea, A., Limongelli, G. and Morello, A. Anabolic-androgenic steroids and athlete's heart: when big is not beautiful. *International Journal of Cardiology*, **203**, 486-488(2016).
15. Patane, F.G., Liberto, A. and Maria Maglito, A.N. Nandrolone abuse: use, abuse and side effects. *Medicine (Baltimore)*, **99**(39), e2198(2020).
16. Monda, V., Salerno, M. and Fiorenzo, M. Role of sex hormones in the control of vegetative and metabolic functions of middle-aged women. *European Review for Medical and Pharmacological Sciences*, **21**(Suppl 1), 00773(2017).
17. Fortunato, R.S., Marassi, M.P. and Chaves, E.A. Chronic administration of anabolic androgenic steroid alters murine thyroid function. *Medicine and Science in Sports and Exercise*, **38**, 256-261(2006).
18. National Institute on Drug Abuse (NIDA). Research Report: steroid abuse and addiction. NIH Publication No. 00-37-P-21(2000).
19. Shahidi, N.T. A review of the chemistry, biological action, and clinical applications of anabolic-androgenic steroids. *Clinical Therapeutics*, **23**, 1355-1390(2001).
20. Woodiwiss, A.J., Trifunovic, B., Philippi, M. and Norton, G.R. The effects of an androgenic steroid on exercise-induced cardiac remodeling in rats. *Journal of Applied Physiology*, **88**, 409-415 (1985).
21. Marsh, J.D., Lehmann, M.H. and Ritchie, R.H. Androgen receptors mediate hypertrophy in cardiac myocytes. *Circulation*, **98**, 256-261(2000).
22. Barany, Q.L., Sofi, A. and Al-Barwary, M.K. Neurosteroid, Natural and Anabolic Steroids: Physiological, Immunological and Histopathological Study on Diabetic Albino Rats. *Egyptian Journal of Veterinary Sciences*, **54**(5), 863-881(2023).
23. Cerretani, D., Neri, M. and Cantatore, S. Looking for organ damages due to anabolic-androgenic steroids (AAS): is oxidative stress the culprit? . *Mini Reviews in Medicinal Chemistry*, **10**, 393-399(2013).
24. Arazi, H., Mohammadjafari, H. and Asadi, A. Use of anabolic androgenic steroids produces greater oxidative stress responses to resistance exercise in strength-trained men. *Toxicology Reports*, **4**, 282-288 (2017).
25. Poljsak, B., Supic, S. and Milisavljevic, N. Achieving the balance between ROS and antioxidants: when to use the synthetic antioxidants. *Oxidative Medicine and Cellular Longevity*, **2013**, 956792(2013).
26. Pey, A., Saborido, A. and Blazquez, I. Effects of prolonged stanozolol treatment on antioxidant enzyme activity, oxidative stress markers, and heat shock protein Hsp70 levels in rat liver. *Journal of Steroid Biochemistry and Molecular Biology*, **87**(4-5), 269-277(2003).
27. Niki, E., Yoshida, Y., Saito, Y. and Noguchi, N. Lipid peroxidation: mechanisms, inhibition, and biological effects. *Biochemical and Biophysical Research Communications*, **338**(1), 668-676(2005).
28. Basile, J.R., Binmadi, N.O. and Zhou, H. Supraphysiological doses of performance enhancing anabolic-androgenic steroids exert direct toxic effects on neuron-like cells. *Frontiers in Cellular Neuroscience*, **7**, 69 (2013).
29. Turillazzi, E., Neri, M. and Cantatore, S. Lipid peroxidation and apoptotic response in rat brain areas induced by long-term administration of nandrolone: the mutual cross talk between ROS and NF-kB. *Journal of Cellular and Molecular Medicine*, **20**, 601-612(2016).
30. Joukar, S., Vahidi, R. and Farsinejad, A. Ameliorative effects of endurance exercise with two different intensities on neurodegeneration in rats: involving redox and apoptotic systems. *Neurotoxicity Research*, **32**, 41-49(2017).
31. Alabdaly, Y.Z. Neurobehavioral evaluation of quail treated with omega-3 and chlorpyrifos. *Iraqi Journal of Veterinary Sciences*, **37**(Supplement I-IV), 245-250(2023).
32. Kahal, A. and Allem, R. Reversible effects of anabolic steroid abuse on cytoarchitectures of the heart, kidneys and testis in adult male mice. *Biomedicine and Pharmacotherapy*, **106**, 917-922(2018).
33. Hassan, N.A., Salem, M.F. and Sayed, M.A.E.L. Doping and effects of anabolic androgenic steroids on

- the heart: histological, ultra-structural, and echocardiographic assessment in strength athletes. *Human and Experimental Toxicology*, **28**(5), 273-283(2009).
34. Elgend, H.A.E., Alhawary, A.A.E., El-Shahat, M.A.E. and Ali, A.T. Effect of anabolic steroids on the cardiac and skeletal muscles of adult male rats. *International Journal of Clinical and Developmental Anatomy*, **4**(1), 1(2018).
 35. Sánchez- Osorio, M., Duarte- Rojo, A., Martínez- Benítez, B., Torre, A. and Uribe, M. Anabolic-androgenic steroids and liver injury. *Liver International*, **28**(2), 278-282(2008).
 36. Bagtell, C.J. and Bremner, W.J. Androgens in men: uses and abuses. *New England Journal of Medicine*, **334** (1), 707-715(1996).
 37. Strugill, G. and Lambert, H. Xenobiotic C-induced hepatotoxicity: mechanisms of liver injury and methods of monitoring hepatic function. *American Association for Clinical Chemistry*, **34**, 1512-1526(1997).
 38. Boada, L.D., Zumbado, M. and Torres. Evaluation of acute and chronic hepatotoxic effects exerted by anabolic androgenic steroid stanozolol in adult male rats. *Archives of Toxicology*, **73**, 465-472(1999).
 39. Vieira, P.R., Franca, R.F. and Damaceno-Rodrigues, N.R. Dose-dependent hepatic response to subchronic administration of nandrolone decanoate. *Medicine and Science in Sports and Exercise*, **11**, 33-34(2008).
 40. Patil, J.J., O'Donohoe, B., Loyden, C.F. and Shanahan, D. Near-fatal spontaneous hepatic rupture associated with anabolic androgenic steroid use: a case report. *British Journal of Sports Medicine*, **41**(7), 462-46(2007).
 41. Tousson, E., Allu-Eldeen, A. and El-Moghazy, M. P53 and Bcl-2 expression in response to boldenone induced liver cells injury. *Toxicology and Industrial Health*, **27**, 711-718(2011).
 42. Diab, A.E.A.A., Al-Mathal, E.M., Zahra, M.H., Dowidar, M.F., El-Sherbeny, S.A. and Abu El-Magd, M. Ameliorative Effect of *Costus speciosus* Extracts on Toxic Effects of Lead Acetate on Liver and Kidney of Male Rats. *Egyptian Journal of Veterinary Sciences*, **55**(4), 895-901(2024).
 43. Sadowska-Krepa, E., Klapinska, B. and Nowara, A. High-dose testosterone supplementation disturbs liver pro-oxidant/antioxidant balance and function in adolescent male Wistar rats undergoing moderate-intensity endurance training. *Peer J.*, **8**, e10228(2020).
 44. Lima, E.M., Cassaro, K.O.D.S. and Silva, C.L.D. Eight weeks of treatment with nandrolone decanoate in female rats promotes disruption in the redox homeostasis and impaired renal function. *Life Sciences*, **242**, 117227(2020).
 45. Carteri, R.B., Kopezynski, A. and Rodolphi, M.S. Anabolic-androgenic steroids impair mitochondrial function and redox status in the heart and liver of mice. *Steroids*, **172**, 108861(2021).
 46. Bonetti, A., Tirelli, F. and Catapano, A. Side effects of anabolic androgenic steroids abuse. *International Journal of Sports Medicine*, **29**, 679-687(2008).
 47. Modlinski, R. and Fields, K.B. The effect of anabolic steroids on the gastrointestinal system, kidneys, and adrenal glands. *Current Sports Medicine Reports*, **5**, 104-109(2006).
 48. Albogami, B., Hassan, N.A., Mansour, A.M. and Hussien, N.A. Prevalence of Intestinal Parasites Infesting Domestic Pigeons with Histopathological Changes at Taif Governorate, KSA. *Egyptian Journal of Veterinary Sciences*, **54**(3), 433-443(2023).
 49. Al-Mukhtar, S.E., Abbas, A.A., Muhealdeen, D.N. and Michael, D.H. Acute kidney injury associated with androgenic steroids and nutritional supplements in bodybuilders (dagger). *Clinical Kidney Journal*, **8**, 415-419 (2015).
 50. Sjoqvist, F., Garle, M. and Rane, A. Use of doping agents, particularly anabolic steroids, in sports and society. *The Lancet*, **371**, 1872-1882(2008).
 51. Hemmi, S., Matsumoto, N. and Jike, T. Proximal tubule morphology in rats with renal congestion: a study involving the in vivo cryotechnique. *Medical Molecular Morphology*, **48**(2), 92-103(2015).
 52. Kriz, W. and Lemley, K.V. The role of the podocyte in glomerulosclerosis. *Current Opinion in Nephrology and Hypertension*, **8**(4), 489-497(1999).
 53. Hasso, R.A. Histological Toxic effects of Nandrolone Decanoate on the kidney of Male rabbits. *Medical Journal of Babylon*, **27**(1), 19-22(2009).
 54. Sood, P.K., Nahar, U. and Nahru, B. Curcumin attenuates aluminum-induced oxidative stress and mitochondrial dysfunction in rat brain. *Neurotoxicity Research*, **20**, 351-361(2011).
 55. Indo, H.P., Davidson, M. and Yen, H.C. Evidence of ROS generation by mitochondria in cells with impaired electron transport chain and mitochondrial DNA damage. *Mitochondrion*, **7**, 106-118(2007).
 56. Brenu, E.W., Nanghton, L. and Marshall-Gradisnik, S.M. Is there a potential immune dysfunction with anabolic androgenic steroid use?: A review. *Expert Opinion on Drug Safety*, **10**(2), 207-215(2011).
 57. Misseri, R., Meldrum, D.R. and Dinarello, C.A. TNF-alpha mediates abstraction-induced renal tubular cell apoptosis and proapoptotic signaling. *American Journal of Physiology - Renal Physiology*, **288**, F406-F411(2005).
 58. Riezzo, I., Turillazzi, E. and Bello, S. Chronic nandrolone administration promotes oxidative stress, induction of pro-inflammatory cytokines, and TNF-mediated apoptosis in the kidneys of CDI-treated mice. *Toxicology and Applied Pharmacology*, **280**(1), 97-106(2014).
 59. Abdel-Daim, M.M., Dessouki, A.A. and Abdel-Rahman, H.G. Hepatorenal protective effects of taurine and N-acetylcysteine against fipronil-induced injuries: The antioxidant status and apoptotic markers expression in rats. *Science of the Total Environment*, **650**(Pt 2), 2063-2073(2019).

60. Ousdampains, P., Trigka, K. and Fourtounas Bargman, J.M. Role of testosterone in the pathogenesis, progression, prognosis, and comorbidity of men with chronic kidney disease. *Therapeutic Apheresis and Dialysis*, **18**, 220–230(2014).
61. Ozbek, E. Induction of oxidative stress in kidney. *International Journal of Nephrology*, **9**, 465897 (2012).
62. Daenen, K., Andries, A., and Mekahli, D. Oxidative stress in chronic kidney disease. *Pediatric Nephrology*, **34**(6), 975–991(2019).
63. Sharifi–Rad, M., Anil Kumar, N.V. and Zucca, P. Lifestyle, oxidative stress, and antioxidants back and forth in the pathophysiology of chronic disease. *Frontiers in Physiology*, **11**, 694(2020).
64. Aparicio, V.A., Camiletti–Moiron, D. and Tassi, M. Effects of anabolic genic steroids on renal morphology in rats. *Archives of Renal Diseases Management*, **3**(2), 034–037(2017).
65. Albano, G.D., Amico, F. and Cocimano, G. Adverse effects of anabolic–androgenic steroids: a literature review. *Healthcare*, **9**, 97(2021).
66. Aly, M.A., El–Sayed, E.S. and Soliman, M. Protective effect of nanoencapsulated curcumin against boldenone-induced testicular toxicity and oxidative stress in male albino rats. *Egyptian Pharmaceutical Journal*, **20**, 72–81(2012).
67. Frankenfeld, S.P., Oliveira, L.P. and Ortenzi, V.H. The anabolic androgenic steroid nandrolone decanoate disrupts redox homeostasis in the liver, heart, and kidney of male Wistar rats. *PLoS One*, **9**(9), e106699 (2014).

التأثيرات المرضية النسيجية للستيرويدات الاندروجينية البنائية (ناندرولون ديكانويت) على القلب، الكبد والكلية في ذكور الارانب المحلية

تغريد حازم صابر الفججي و فيحاء ازهر المشهداني

فرع علوم طب الأسنان الأساسية - كلية طب الأسنان - جامعة الموصل - الموصل - العراق.

الخلاصة

يعتبر ديكانوات الأندروولون واحداً من مجموعة الستيرويدات الابتنائية التي يستخدمها الرياضيون بجرعات عالية لتعزيز القدرة الرياضية وبناء العضلات. وقد وجد أن تناول جرعات عالية من هذه المركبات يؤثر على القلب والكبد والكلية. تهدف هذه الدراسة إلى بحث النتائج النسيجية المرضية لعقار الناندرولون على القلب والكبد والكلية في الأرانب البالغة. تم استخدام ستة أرانب بالغة في هذا البحث، وتم توزيع هذه الحيوانات على مجموعتين بواقع 3 أرانب في كل مجموعة. اعتبرت المجموعة الأولى مجموعة سيطرة، بينما أعطيت المجموعة الثانية جرعة مقدارها (10 ملغم/كغم) من الناندرولون ديكانوات/ حقناً في العضل لمدة (15 يوماً متتالية). وبعد (24) ساعة من إعطاء الجرعة الأخيرة تم ذبح الأرانب وأخذ عينات من القلب والكبد والكلية وتم تحضيرها للدراسة النسيجية بالمجهر الضوئي. أظهرت هذه الدراسة تغيراً واضحاً في بنية عضلة القلب، يتمثل في ارتشاح الخلايا الالتهابية، والتنكس الفراغي، ونخر زنكر، واحتقان الأوعية الدموية. وفي الكبد لوحظ أيضاً تسلل الخلايا الالتهابية، وتنكس الفجوات، وتضخم بطانة القناة الصفراوية، والتليف، واحتقان الجيوب الأنفية. في الكلية، لوحظ انحطاط الفجوات، وضمور واحتقان الكبيبات، وتوسيع الفضاء البولي وتشكيل الخراجات. نستنتج من الدراسة الحالية أن عقار الناندرولون له تأثير ضار على التركيب النسيجي لعضلة القلب والكبد والكلية في الأرانب البالغة، لذا توصي الدراسة الحالية بالحد من الاستخدام المفرط لهذا الدواء.

الكلمات المفتاحية: الستيرويد المنشطة منشط الذكورة، الكبد، القلب، الكلية، الأرانب.