

*Case Report***AVULSED POSTERIOR COLUMN OF THE ACETABULUM AS A PART OF BOTH COLUMN ACETABULAR FRACTURE: CASE REPORT**Wael Salama<sup>(\*)</sup>, Mohamed Abdellah, & Hassan Noaman*Orthopedic dept., Faculty of Medicine, Sohag Univ. Hospital, Sohag, Egypt*E-mail: [Waeladel582@gmail.com](mailto:Waeladel582@gmail.com)

Received 1/12/2023

Accepted 17/12/2023

**1. Introduction**

Both column acetabular fractures are commonly associated with high energy trauma [1,2]. Judet and Letournel classified the acetabular fractures into two main types, simple type and associated type [3]. Associated both column acetabular fractures occur when the fracture line involve the anterior and the posterior column of the acetabulum in which no portion of the articular surface of the hip is communicated with the sacroiliac joint [3]. In this report we describe a very rare case of associated both column acetabular fracture in which the whole posterior column is avulsed from the sacroiliac joint down to the ischial tuberosity in one piece.

**2. Case Presentation**

Due to a motor car accident a 35-year-old male was presented to our hospital. The patient was managed according to the advanced trauma life support protocol. He was fully conscious and hemodynamically stable. Clinically, there was pain at the left hip and inguinal regions with inability to mobilize the left lower limb. The neurovascular examination was normal. On radiological examinations, there was associated both column acetabular

fracture in which the posterior column was completely avulsed in one piece from the sacroiliac joint above down to the ischial tuberosity and the fragment displaced anteriorly and medially, figs. (1 & 2)

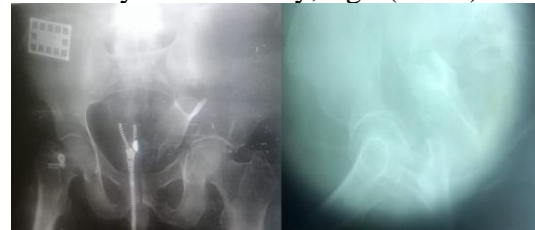


Figure (1) Preoperative plain X-ray antero-posterior and iliac view showing avulsion of the posterior column.

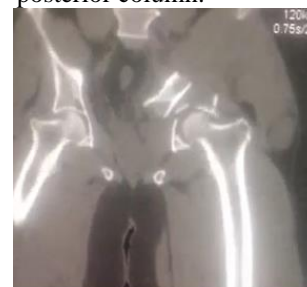


Figure (2) Preoperative computed tomography scan showing the avulsed posterior column displaced medially and anteriorly.

After stabilization of the general condition of the patient, the patient prepared for operative intervention. Depending on Computed Tomography scan finding, under general anaesthesia initially through Kocher Langenbeck approach, the posterior col-

umn forming the greater sciatic notch was completely avulsed from the sacroiliac joint down to the ischial tuberosity and was displaced medially and anteriorly, located medial to the quadrilateral surface, fig. (3).

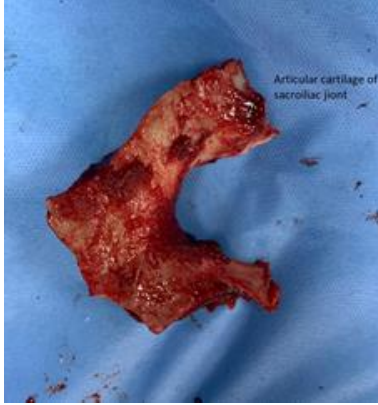


Figure (3) Intraoperative view showing the posterior column fragment before reduction and fixation.

We reduced and fixed the posterior column by 3.5 mm reconstruction plate, and in the same setting the patient was turned in supine position and through modified Stoppa approach we reduced and fixed the anterior column by 4.5 mm reconstruction plate, fig. (4). The postoperative radiograph showed concentric reduction of the hip joint with adequate reduction of the anterior column and the posterior column.

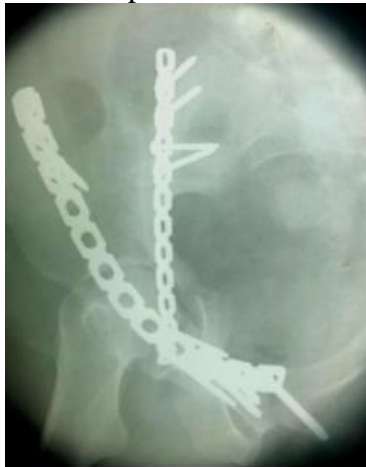

Figure (4) Post-operative X ray showing adequate reduction of the posterior column.

Regular follow up visits were scheduled at 6 weeks, 3, 6 months and one year postoperatively, complete fracture healing was achieved at 6 months and the patient Harris Hip Score (HHS) was 98 at the end of the first year postoperatively [4],

fig. (5). Informed consent was obtained from the patient for publication.

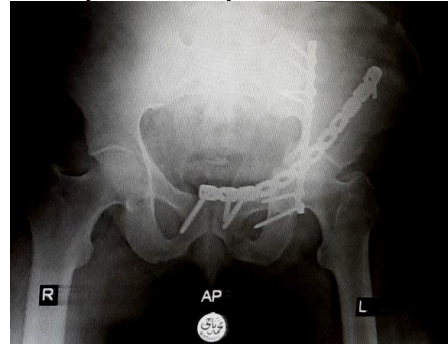


Figure (5) One year follow up

### 3. Discussion

Acetabular fractures are classified according to Letournel into elemental fractures and associated fractures [3]. The both-column associated fracture type is common injury and mostly associated with high energy trauma, in such injury there is complete discontinuity of the articular surface of the acetabulum from the axial skeleton [5,6]. In most cases it results from laterally directed force through the femoral head to the acetabulum resulting into fracture and separation of the anterior and posterior column of the acetabulum [5]. So, the end result is disruption of the acetabulum into two main fragments representing the anterior and posterior column taking T or Y shaped fracture morphology in association with other secondary fractures that may be present as posterior wall fracture and acetabular roof fracture [5]. In this article, we describe a very rare fracture pattern in which the posterior column forming the greater sciatic notch is completely avulsed in one intact piece from the sacroiliac joint down to the ischial tuberosity. This case was not reported previously in the literature. There are a very rare reports regarding acetabular fracture in the literature. Chen et al reported a poly trauma patient with posterior hip dislocation associated with posterior wall fracture and anterior wall fracture [7]. Tusirin et al reported a case with anterior hip dislocation with small fragment post wall fracture which had been treated conservatively [8]. Sinha et al

reported a case with posterior hip dislocation and anterior column fracture [9]. Chadha et al reported a case with anterior hip dislocation and posterior wall fracture [10].

#### 4. Conclusion

*High energy trauma may result into unusual fracture pattern as regard acetabular fracture and the surgeon must be aware about the presence of such rare combinations to avoid missing any injury pattern.*

#### References

- [1] Salama, W., Mousa, S., Khalefa, A., et al. (2017). Simultaneous open reduction and internal fixation and total hip arthroplasty for the treatment of osteoporotic acetabular fractures. *International Orthopaedics*. 41 (1): 181-189
- [2] Salama, W., Hosny, H., Mohamed, M., et al. (2021). Modified stoppa approach for the treatment of complex acetabular fractures. *Orthopedics*. 44 (3): e353-e358
- [3] Judet, R., Judet, J. & Letournel, E. (1964). Fractures of the acetabulum: Classification and surgical approaches for open reduction: Preliminary report. *JBJS*. 46 (8): 1615-1675.
- [4] Harris, W. (1969). Traumatic arthritis of the hip after dislocation and acetabular fractures: Treatment by mold arthroplasty: An end-result study using a new method of result evaluation. *JBJS*. 51 (4): 737-755.
- [5] Giordano, V., Acharya, M., Pires, R., et al. (2020). Associated both-column acetabular fracture: An overview of operative steps and surgical technique. *J. Clin Orthop Trauma*. 11 (6): 1031-1038.
- [6] Mauffrey, C., Hao, J., Cuellar, D., et al. (2014). The epidemiology and injury patterns of acetabular fractures: Are the USA and China comparable? *Clinical Orthopaedics and Related Research*®. 472 (11): 3332-3337.
- [7] Chen, W., Su, Y., Zhang, Y., et al. (2010). Unusual combination of posterior femoral head dislocation with anterior and posterior wall fractures in the ipsilateral acetabulum. *Orthopedics*. 33 (6): 440.
- [8] Tusirin, M., Borhanuddin, M. & Bahaudin, N. (2019). Traumatic anterior dislocation of right hip with associated posterior acetabular wall fracture: A rare case report. *MOA Scientific Meeting Abstract supplement* May, Vol. 13, (Suppl. A)
- [9] Sinha, S., Naik, A., Arya, R., et al. (2013). Ipsilateral traumatic posterior hip dislocation, posterior wall and transverse acetabular fracture with trochanteric fracture in an adult: Report of first case. *J. of Orthopaedic Case Reports*. 3 (4): 31.
- [10] Chadha, M., Agarwal, A. & Singh, A. (2005). Traumatic anterior dislocation of the hip joint with posterior acetabular wall fracture. *Acta Orthop Belg*. 71(1):111-4.