

Glutathione's Antioxidant Effects and Its Ability to Shield Mice's Hepatocytes From Damage Caused by Furan

*Ibrahim, M. Ibrahim, Hend, M. Saleh & Alshaimaa, M. Hamouda

Special Food and Nutrition Department, Food Technology Research Institute, Agricultural Research Center, Egypt

Original Article

ABSTRACT

Furan is commonly found in several kinds of heat-treated foods, the existence of furan in food causes public health issues. The current research examines the preventive impact of glutathione on liver, kidney function, and tumor markers against furan-induced injury in mice. Male albino mice were divided into seven groups: a control (G1), G2 (0.5mg furan/kg b.w./day), G3 (1 mg furan/kg b.w./day), G4 (2 mg furan/kg b.w./day), G5 (4 mg furan/kg b.w./day), G6 (2 mg furan/kg b.w./day +500 mg glutathione/kg/day), and G7 (4 mg furan/kg b.w./day +500 mg glutathione/kg/day). At the end of the study, after 8 weeks, the anesthetized and sacrificed were done, and then the different tests were conducted. Results: Furan significantly increased hepatocyte damage in mice, as evidenced by increased activities of aminotransferase (AST) and alanine aminotransferase (ALT) after a 2mg/kg/day dose. Furan promoted oxidative stress due to elevated malondialdehyde levels, occurring at various furan dosages (0.5, 1, 2, and 4mg/kg/day). The study found that pre-treatment with glutathione at 500 mg/kg/day reduced AST, ALT, and MDA activities in mice, while furan levels did not negatively impact kidney functions. It should be noted that all levels of furan increased tumor markers [Alpha Fetoprotein (AFP)] compared to the control (3.1 ng/ml), whereas glutathione reduced the level of AFP in groups taking furan at (2 and 4 mg/kg) to range (3.5–3.6 mg/ml) compared to (4.6–4.8 mg/ml) for the same groups taking furan at (2 and 4 mg/kg) without glutathione. Glutathione's protective effects against furan-induced hepatocyte damage may be due to its exceptional capacity to scavenge free radicals. Glutathione, with its strong antioxidant properties, has the potential to be a promising therapeutic and preventive agent for diseases induced by furan compounds.

Article information

Received 21/2/2024

Revised 29/2/2024

Accepted 01/3/2024

Published 20/3/2024

Available online
20/03/2024

Keywords

Furan, Glutathione, Mice, Liver, Kidney, Tumor Markers, Alpha Fetoprotein

1. Introduction

Furan is typically created during the thermal processing of a variety of foods, especially baked, fried, and roasted foods like cereals, coffee, canned and jarred prepared meals, and infant foods. Furan is a poisonous and carcinogenic substance for humans that may pose a serious risk to newborns and babies. Furan can be generated in meals as a result of heat carbohydrate breakdown, amino acid dissociation, and polyunsaturated fatty acid oxidation. Furan is difficult to detect in food because of its high volatility and low molecular weight (Javed et al., 2021). The heating temperature has an impact on the initial rate of furan formation

(Akilloğlu et al., 2015). (Mogol and Gokmen 2013) found that an increase in heat load has a substantial impact on the growth of furans. Honey-coated breakfast contains 57.4 mg/kg of furan (Fromberg et al., 2014); breakfast cereals contain 27–27.5 mg/kg of furan; crackers, biscuits, crispbread, and other similar foods contain 32.4 mg/kg; vegetables and savory baby foods (meat, fish, or pasta) contain 33.3–289 mg/kg (Kettlitz et al., 2019); however, 74–99 and 47–53 mg/kg were found in fully automated coffee machines and filter coffee, respectively (Rahn and Yeretizian, 2019). The The (EFSA 2004) discovered that this dangerous was present in a wide range of

foods, with levels above 100 ppb in coffee, infant food, and canned meat. According to (EFSA's 2017) report, which was requested by the European Commission, the largest source of dietary exposure to furan in adults, the elderly, and the very old is coffee. The liver has the largest concentration of furan, which is absorbed through the digestive system. DNA, proteins, and amino acids may all bind covalently to furan. Rats and mice exposed to furan exhibit hepatotoxicity, such as cholangiofibrosis and hepatocellular adenomas and carcinomas. Oxidative stress, altered gene expression, altered epigenetic modifications, inflammation, and enhanced cell proliferation are examples of convincing evidence for indirect pathways implicated in carcinogenesis. Furan and several of its constituents are extremely toxic and linked to a number of major health problems, such as growth rate and behavioral issues, cancer, hormone imbalances, abnormalities in the immune system, problems in the embryo, and detrimental postnatal consequences on human health (Hamadeh et al., 2004). (IARC 1995) categorized furan as probably carcinogenic for humans (Group 2B). In 2-year carcinogenicity research in 344 Fischer rats, furan administration causes neoplastic lesions that are largely localized in the liver (NTP, 1993). The dosages at which this occurs are 2, 4, and 8 mg per kg BW per day. Thus, research on furan toxicity to humans is necessary to mitigate or minimize negative consequences. (Yuan et al., 2013) demonstrated that furan significantly increased hepatocyte damage as indicated by raised levels of aspartate aminotransferase (AST), alanine aminotransferase (ALT), and direct bilirubin (DBIL). Increased formation of reactive oxygen species (ROS) and malondialdehyde (MDA) levels in the livers of mice were indicative of oxidative stress brought on by furan. According to (Kaya et al., 2019), rats given high doses of furan experienced increased MDA levels, which resulted in oxidative stress and hepatotoxicity. Moreover, increase the activities of alanine transaminase and aspartate transaminase. Histopathological examination of the liver tissues of the furan-treated groups revealed many lesions,

particularly in the higher-dose group. Furan was discovered by (Aydin et al., 2023) to lower the activity of antioxidant enzymes while raising the rates of apoptotic cells, reactive oxygen species, and lipid peroxidation. It also negatively impacts the skin, liver, kidneys, immunological system, neurological system, and fat tissue. These consequences might result from reducing the antioxidant system's effectiveness, which could lead to cytotoxicity, oxidative stress, and apoptosis. An antioxidant called glutathione is created when glutamine, glycine, and cysteine are combined. In addition to acting as an electron donor for GPx and providing protection against nonspecific oxidative damage and hydrogen peroxide, which is known to be a major cause of sickness in a variety of illnesses (Parsons and Gates 2013), It prevents the oxidative denaturation of proteins under stress by protecting thiol groups (Zhang et al., 2019). Protein, bilirubin, and enzyme levels in the blood are all improved in patients with deep-seated fatty liver diseases by glutathione (Kotsos and Tziomalos 2023). Additionally, it helps organisms detoxify and gets rid of different kinds of free radicals, or ROS, in cells (Lee et al., 2015). By interacting with toxins and carcinogens, it reduces liver damage by enhancing the solubility of foreign compounds that are easily excreted by the kidneys, helps repair DNA through the production of prostaglandins and proteins, and aids in the detoxification of harmful minerals through the mercapturic acid pathway (Niu et al., 2021 and Yilmaz & Omakli 2023). It is also a significant reducing agent with strong antioxidant action. Glutathione is involved in the elimination of poisons such as mercury from cells and the brain, in addition to eliminating a variety of oxidants such as superoxide, hydroxyl radical, carbon radical, nitric oxide, detoxified hydroperoxides, lipid peroxides, and peroxy nitrates (Mary et al., 2015). It also acts as an antioxidant, preserves the thiol status of proteins, and alters DNA and the structure of the immune system (Halliwell and Gutteridge 2015). Better physical health and fewer diseases have been associated with higher glutathione levels (Halliwell 2013).

Nevertheless, no research has used a mice model to assess the preventive benefits of glutathione administration against hepatocyte damage caused by furans. The impact of glutathione supplementation on furan-induced damage in the liver and kidney of mice was examined in this work.

2. Materials and Methods

Materials

The purification level of furan (CAS: 110-00-9, >98.0%) was obtained from Sigma-Aldrich (St. Louis, Mo., USA). Commercial kits for ALT, AST, and total bilirubin were purchased from Diamond Co. in Hannover, Germany. Sigma-Aldrich's ELISA Kit was used to evaluate the quantity of AFP. We bought glutathione, dimethyl sulfoxide, and diammonium salt (DMSO) from Sigma-Aldrich. All the different reagents and chemicals were of the highest grade possible. Furan (0.5, 1, 2, and 4 mg furan/kg b.w. of mice/day) was diluted in DMSO to a final volume of 0.5 ml of solution. The experimental mice were given solutions daily with the aid of a stomach tube. Glutathione (500 mg/kg b.w. of mice/day) was dissolved in 0.5 ml of normal saline and given orally daily by stomach tube to mice.

Experimental design

For this study, 42 male albino mice weighing 20 ± 5 g each were obtained from the Food Technology Research Institute and were in good health. Mice were fed a standard mouse pellet diet, and tap water was provided *ad libitum*. As advised by (Tebib et al., 1997), the basal diet, also known as the control group, consists of 15% sugar, 21.7% casein, 53.3% corn starch, 5% corn oil, 1% vitamin mixture, 4% mineral mix, and 0.2% choline chloride. The experiment was carried out in the Agriculture Research Center's experiment animal house at the Food Technology Research Institute. The living quarters were designed to resemble a typical laboratory, with $24 \pm 3^\circ\text{C}$ temperature control, 60% relative humidity, and 12-hour light and dark cycles. For ten days, the mice were fed a control diet, or basal diet, to help them adapt. After adaptation, 42 mice were split into seven groups of equal mean body weight. All groups fed on a basal diet during

the experiment period and submitted to seven different treatments: G1 (control), G2 (0.5 mg furan/kg b.w./day), G3 (1 mg furan/kg b.w./day), G4 (2 mg furan/kg b.w./day), G5 (4 mg furan/kg b.w./day), G6 (2 mg furan/kg b.w./day +500 mg glutathione/kg/day), and G7 (4 mg furan/kg b.w./day +500 mg glutathione/kg/day). Each mouse was given 0.5 ml of solution containing the required concentration of furan or glutathione according to body weight via a stomach tube. There was no treatment given to the mice in the control group.

Biochemical analysis

After eight weeks of study, the mice were slaughtered, and their livers were removed after they had fasted for the whole night. Before analyzing the liver samples, they were thoroughly washed with a physiological saline solution. Then, one part of the liver tissues was homogenized with 10 parts of distilled water using a Potter-Elvehjem homogenizer (CAT R50D model, Germany). To measure MDA, the homogenate was centrifuged for 15 minutes at 3,000 g at 4°C . (Placer et al., 1966) approach was followed while testing the MDA level. This particular approach relied on the interaction between thiobarbituric acid and MDA, which is one of the aldehydes that arise from the process of lipid peroxidation. After blood collection, it permitted clotting, and serum was extracted using a 15-minute centrifugation run at 3000 rpm. The kit's instructions for colorimetric techniques were followed to quantify the amounts of serum AST, ALT, and bilirubin (Diamond Co., Hannover, Germany). The test samples' absorption was measured at 578 nm for total bilirubin and 505 nm for AST and ALT. The kinetic approach was used to determine kidney functions, such as serum urea (Sampson et al., 1980). The colorimetric technique reported by (Heinegard and Tinderstrom 1973) was used to measure creatinine. Uric acid was measured using a uricase enzyme method (Fossati et al., 1980).

Histopathological examination

After the liver tissues were embedded in paraffin blocks, they were soaked in 10% neutral

buffered formalin, sliced into 5 μm slices, and stained with hematoxylin and eosin (HE). A light microscope was then used to analyze the samples (Bhadoria and Nirala, 2009). Ten microscopic areas that were chosen at random were evaluated for the histological assessment.

Alpha-Feta protein

The Alpha-Fetoprotein (AFP) ELISA Kit is intended for the quantitative measurement of AFP in serum or plasma, according to (Adinolfi and Adinolfi 1975).

Statistical analysis

The SPSS 11.5 program (SPSS Inc., Chicago, IL) was used to conduct the statistical analysis. The Duncan test was used to assess mean differences at $p < 0.05$.

3. Results and discussions

Effects of glutathione on the AST and ALT activities in the serum of furan-treated mice

The impact of oral glutathione and furan administration on mice's liver function is displayed in Figure 1. Furan is a common hepatotoxic substance that primarily targets the liver in rats and mice. Its toxicity is dose-dependent and most likely results from a genotoxic mechanism (Pettersson et

al., 2005). Liver enzymes like ALT and AST were assessed in the current study as biochemical indicators of heightened hepatocyte permeability, injury, and/or necrosis when their levels are elevated in the serum. According to our present study, furan significantly increased the serum levels of AST and ALT activities for G2 to G7 as compared to the control group. It is believed that significant damage to the tissue membrane is the cause of this surge. These findings align with the research conducted by (Moser et al., 2009 and Hamadeh et al., 2004). The AST and ALT activities dropped in individuals given 500 mg glutathione per kg body weight per day but did not decrease under control, as demonstrated in Figure 1. The use of glutathione for a level 2 mg furan prevented an increase in AST and ALT activity by 55% and 40%, respectively; however, the application of glutathione for a level 4 mg furan prevented a rise in AST and ALT activity by 40% and 29%. Therefore, it is evident from the data that the risks to the hepatic cells were greater at the higher dosage of furan (4 mg/kg bw/day) than they were at the lower dose (2 mg/kg bw/day). Additionally, glutathione significantly reduced the risks at low furan levels compared to higher levels.

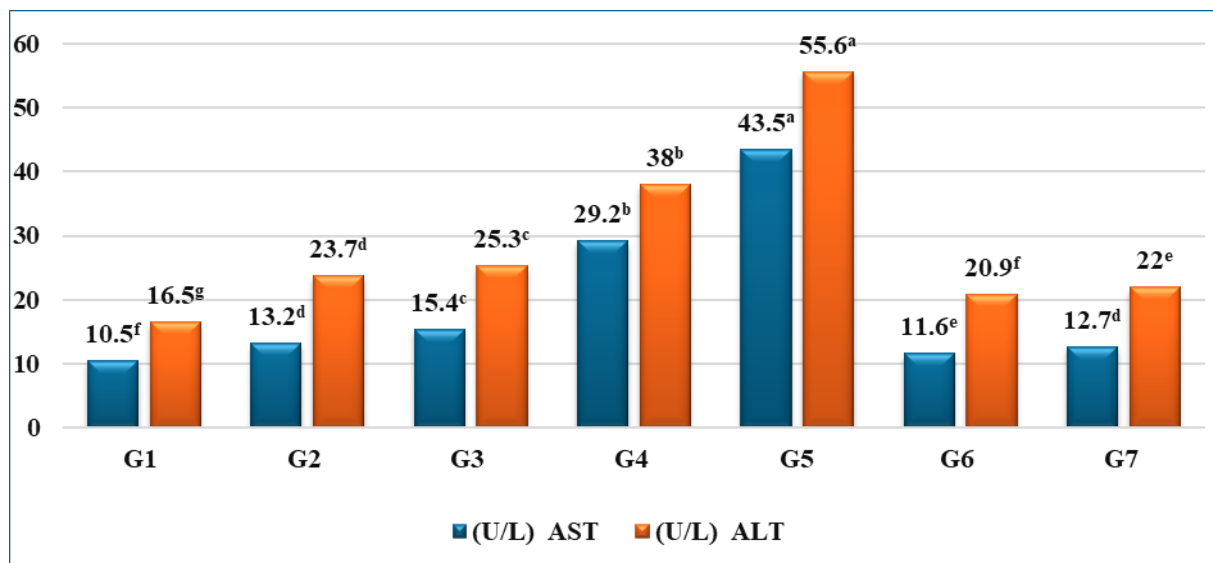


Figure 1. Effects of glutathione on the AST and ALT activities in the serum of furan-treated mice

Columns of the same hue show significant changes when superscript upper case letters differ at ($p < 0.05$).

Consequently, the findings supported the recommendation that mice not be exposed to elevated levels of furan. High dosages of furan cause significant damage in the livers of animals, the major target organ (Bakhiya and Appel 2010). However, utilizing a greater amount of furan (2 and 4 mg) in addition to 500 mg glutathione decreased the level of AST and ALT in mice's serum when compared to lower levels of furan (0.5 and 1mg) without glutathione.

Effect of glutathione on the bilirubin serum and MDA in liver tissues of furan-treated mice

The results shown in Figure 2. indicates that, in comparison to the control group, the rats given varying dosages of furan (0.5, 1, 2, and 4 mg/kg

body weight per day) showed a significant increase in their bilirubin levels. These results imply that exposure to furan could potentially have a direct influence on the functioning of the liver, resulting in an increase in bilirubin levels. The level of bilirubin continued to rise as the concentration of furan increased. (Yuan et al., 2013) reported similar observations. However, after administering glutathione at a dosage of 500 mg/kg bw/day to the mice, the bilirubin levels decreased. This was evident when comparing the levels in groups G6 and G7 to those in groups G4 and G5, respectively. (Salah-Eldina and Ibrahim 2023) have proven that oral glutathione treatment lessens the risk of many hazardous chemicals while improving liver and kidney function.

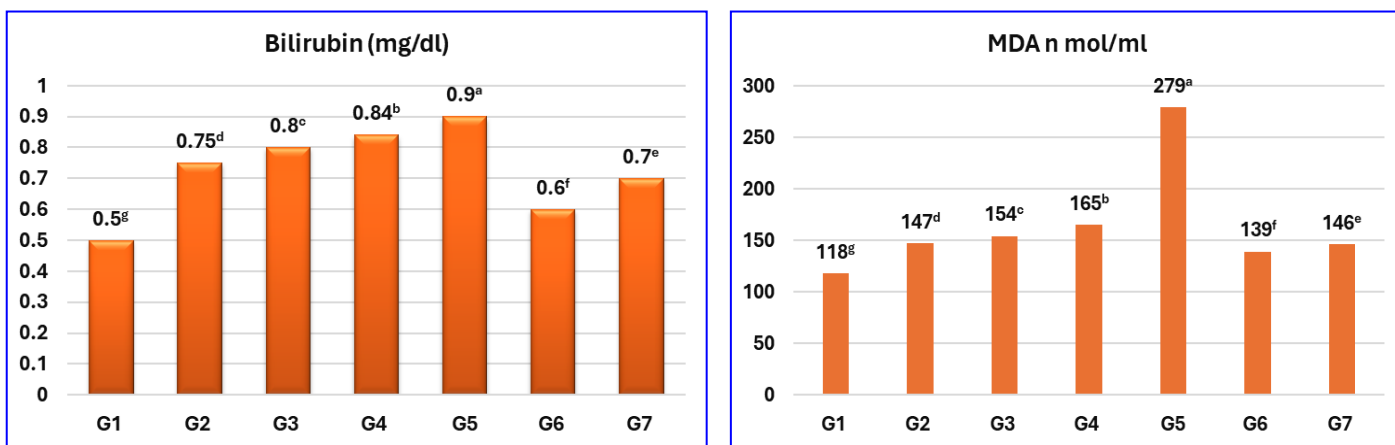


Figure 2. Effect of glutathione on the bilirubin serum and MDA in liver tissues of furan-treated mice

Columns of the same hue show significant changes when superscript upper case letters differ at ($p < 0.05$).

MDA is a significant reactive aldehyde that arises as a result of the peroxidation process of polyunsaturated fatty acids within the biological membranes (Vaca et al., 1988). Consequently, the measurement of MDA serves as a reliable marker indicating an increased occurrence of lipid peroxidation, a process that has the potential to cause harm to tissues. The amount of MDA in the blood is frequently employed as a gauge for the degree of damage resulting from lipid peroxidation mediated by free radicals. This parameter serves as a widely recognized marker in the field (Aksu et al., 2007). MDA levels were determined in the mice's livers treated with furan and glutathione. The data displayed in Figure 2 demonstrate a significant rise in hepatic MDA concentration (147, 154, 165, and 279

nmol/ml, respectively) in the groups administered furan at varying doses (0.5, 1, 2, and 4 mg/kg body weight per day). This increase suggests a heightened occurrence of lipid peroxidation, in contrast to the control group, where the hepatic MDA concentration was 118 nmol/mL. The mice that received oral treatment of glutathione G6 and G7 had significantly lower MDA levels (139 and 146 nmol/ml) compared to the group that was treated with furan at the same concentration without glutathione, such as G4 and G5 (165 and 279 nmol/ml, respectively). Therefore, the study's findings add to the body of research demonstrating the protective effect of glutathione in averting the harm caused by giving mice higher dosages of furan.

Effects of glutathione on the kidneys functions in the serum of furan-treated mice

Figure 3. illustrated the impact of glutathione on the functioning of the kidneys, specifically in relation to uric acid, creatinine, and urea levels in the serum of mice that were treated with furan. The kidneys' uric acid, creatinine, and urea functions in mice treated with furan were found to significantly increase as the intake of furan increased in compari-

son to the control treatment. However, it is important to note that the increase in these functions did not exceed the permissible normal levels. The levels of uric acid, creatinine, and urea in the kidneys were found to have significantly decreased when glutathione was used. This reduction was observed when comparing groups G6 and G7 to groups G4 and G5, respectively. The outcomes agreed with the findings published by (Arrivi et al., 2023).

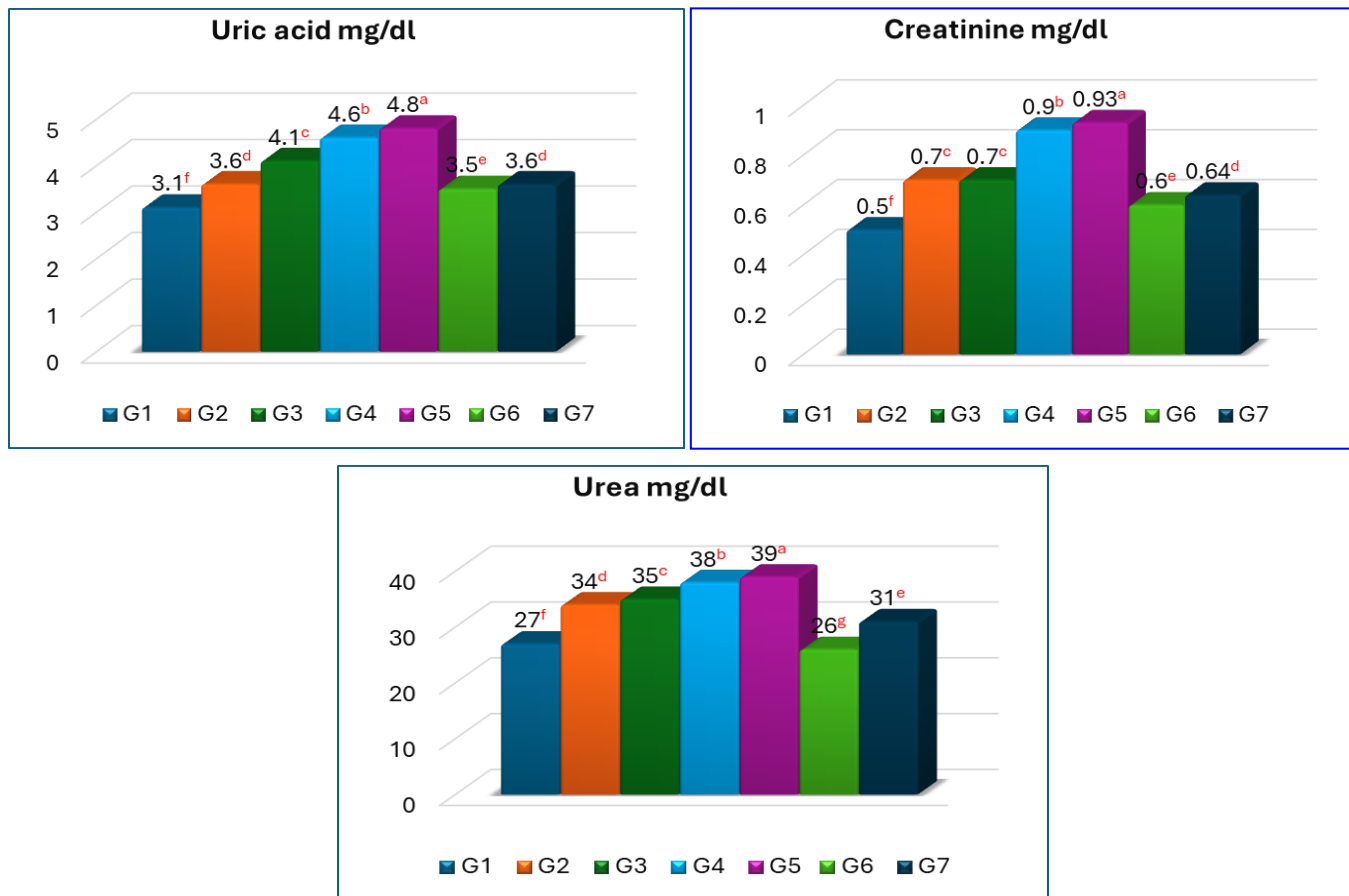


Figure 3. Effects of glutathione on the kidneys functions in the serum of furan-treated mice
Columns show significant changes when superscript upper case letters differ at ($p < 0.05$).

Effects of glutathione on tumor markers (alpha fetoprotein ng/ml) of furan-treated mice

Figure 4. provides a visual representation of the impact of glutathione on the levels of tumor markers, specifically alpha-fetoprotein (measured in nanograms per milliliter), in mice that were treated with furan. Alpha-fetoprotein (AFP) is a glycoprotein with a molecular mass of approximately 70,000 Da. Only tiny levels are seen in the serum in a

normal case. Several malignant disorders, including cancer, acute viral hepatitis, chronic active hepatitis, and cirrhosis, cause excessively high blood AFP levels. Figure 4. displays the results of the experiment where mice were pretreated with different doses of furan (0.5, 1, 2, and 4 mg/kg bw/day). The findings indicate a significant increase in the levels of AFP in the mice, with concentrations of 3.6, 4.1, 4.6, and 4.8 ng/ml for the respective doses.

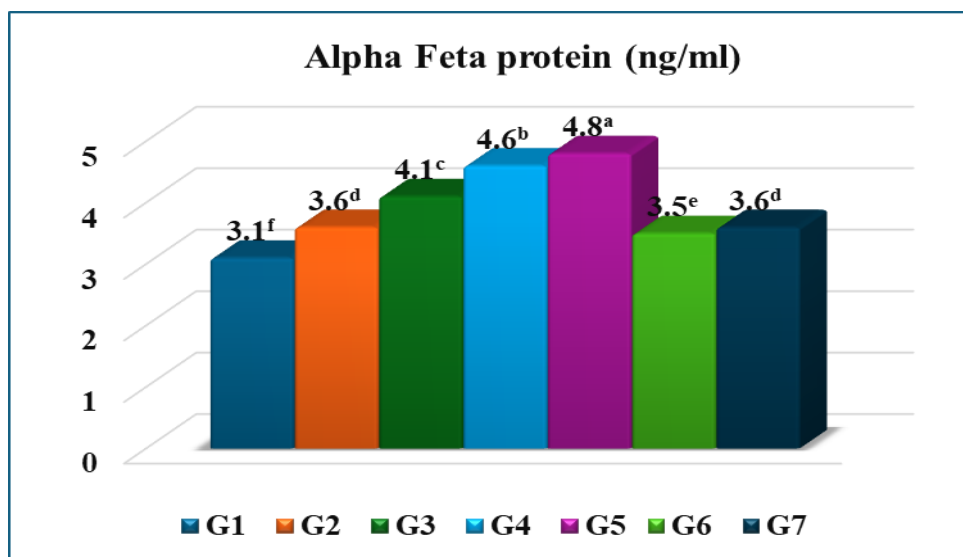


Figure 4 Effects of glutathione on tumor markers (alpha fetoprotein ng/ml) of furan-treated mice

Columns show significant changes when superscript upper case letters differ at ($p < 0.05$)

In comparison, the control group exhibited a lower concentration of AFP (3.1ng/ml). According to (Wong et al., 2015), the increased AFP levels also indicate the extent of liver damage and subsequent liver regeneration. According to reports, serum AFP levels rise as liver histology becomes more severe as the disease progresses from cirrhosis to hepatocellular carcinoma to hepatitis (Liu et al., 2014). Furthermore, elevated AFP levels are occasionally detected in genetically susceptible individuals without a history of liver disease or an underlying malignancy. Meanwhile, moderately elevated AFP levels (<150 ng/mL) usually indicate acute or chronic viral hepatitis and cirrhosis. Moreover, AFP concentrations may increase with hepatocyte regeneration and proliferation during liver disease progression (Turshudzhyan and Wu, 2022). The tumor-infected mice can appear after an increase AFP of about 50 or 250 ng/mL, as reported by (Jag et al., 2022). In the current study, the application of glutathione before treatment had a significant impact on reducing tumor markers (AFP) in groups G6 and G7, with levels of 3.5 and 3.6 ng/mL, respectively. This reduction was in stark contrast to the furan-treated groups, G4 and G5, where the tumor markers were 4.6 and 4.8 ng/ml, respectively, at the same levels of furan concentration. However, despite the reduction in tumor markers, the levels of AFP still remained considerably higher than those observed

in the control group (3.1ng/ml). Additionally, the group that received a daily dosage of 500mg kg^{-1} bw of glutathione demonstrated the most effective protection against hepatic injury caused by furan when compared to other treatments.

Histopathological examination of liver

When examined under a microscope, the liver tissue of mice belonging to Group 1, referred to as the control group, remained unaltered and displayed the typical histological structure. This was observed in both Figures (5a and 5b), indicating that these mice did not undergo any changes in their liver tissue as a result of not receiving either furan or glutathione treatment. In addition to the aforementioned findings, it was observed that the liver of mice belonging to Group 2, which was administered a dosage of 0.5 mg of furan per 1 kg of body weight on a daily basis, did not exhibit any notable alterations in its histological structure, as depicted in Figures 6a and 6b. In contrast, the sections taken from group 3 did not display any histopathological changes, as shown in Figures (7a and 7b). However, a few portions from this group exhibit fibroplasia in the portal triad, which was accompanied by the development of newly formed bile ductules, as depicted in Figure 7c. In the meantime, the liver samples taken from mice in group 4 exhibited the activation of Kupffer cells, as indicated by the findings presented in Figures 8a and 8b.

In the meantime, the liver samples taken from mice in group 4 exhibited the activation of Kupffer cells, as indicated by the findings presented in Figures (8a and 8b). Kupffer cells are specialized phagocytic cells in the liver that form part of the reticuloendothelial system. Its function is to break down red blood cells by phagocytic action and to divide the hemoglobin molecule into a globin chain and a heme molecule (Kalyane et al., 2019). The globin chain is reused; the heme that contains iron is broken down into iron, which is used to build bilirubin, which combines with glucuronic acid in liver cells to form bile juice. Also, the Kupffer cells are the ones that rid the body of gut bacteria, bacterial endotoxins, and microbial debris transported to the liver from the digestive system via the portal vein, and they are the first immune cells in the liver. Any change in the functions of Kupffer cells indicates that the liver is affected by various diseases, such as

alcoholic liver disease, viral hepatitis, intrahepatic cholestasis, steatohepatitis, liver activation or rejection during liver transplantation, and cirrhosis. Activated Kupffer cells can drive hepatocellular epithelial-mesenchymal transition and pro-inflammatory cytokine production through the ROS signaling pathway (Wang et al., 2023). Additionally, there was a noticeable infiltration of inflammatory cells observed in the portal area of the liver, as depicted in Figure 8c. On the contrary, mice's livers from group 5 showed congestion of the central vein, focal hepatocellular necrosis associated with inflammatory cell infiltration (Figure 9a), Kupffer cell activation, portal infiltration with inflammatory cells (Figure 9b), and portal edema (Figure 9c). Furthermore, the livers of mice from groups 6 and 7 exhibited no histopathological alterations (Figures 10a and 10b).

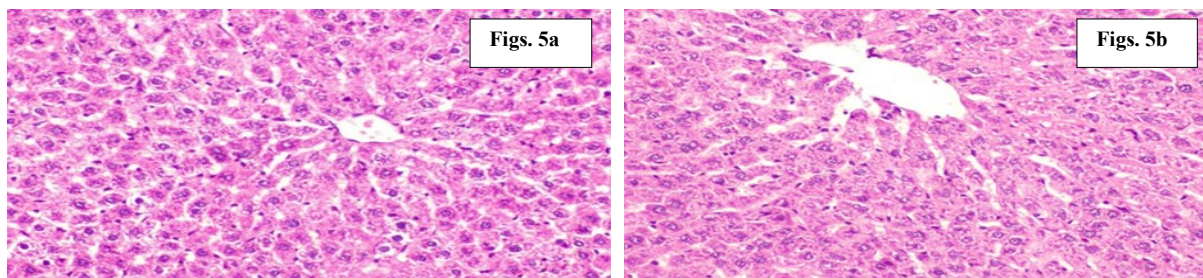


Figure 5. Photomicrograph of liver of mice's from group 1
- Showing the normal histoarchitecture of hepatic tissue

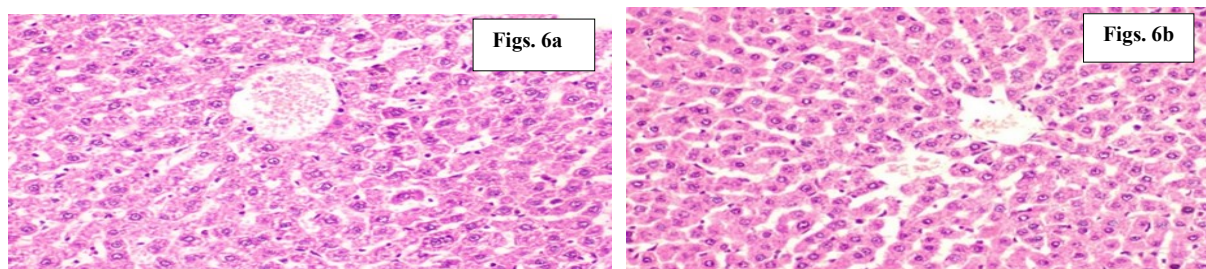


Figure 6. Photomicrograph of liver of mice's from group 2
Showing the normal histoarchitecture of hepatic tissue

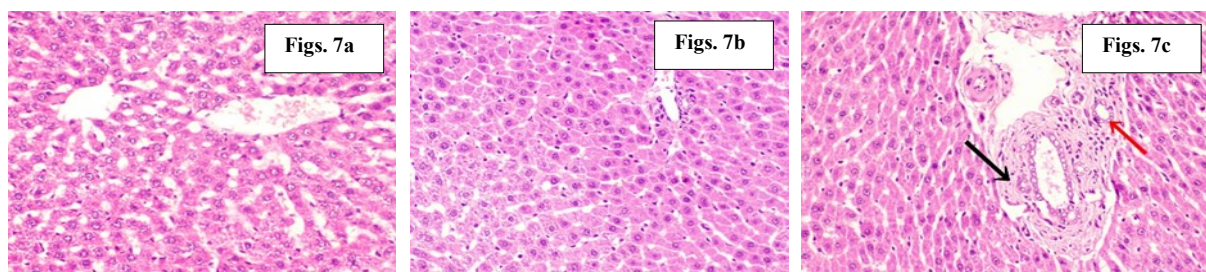


Figure 7: Photomicrograph of liver of mice's from group 3
Figures (7a and 7b) Showing no histopathological alterations while, Figure (7c) showing fibroplasia in the portal triad (black arrow) associated with formation of newly formed bile ductules (red arrow)

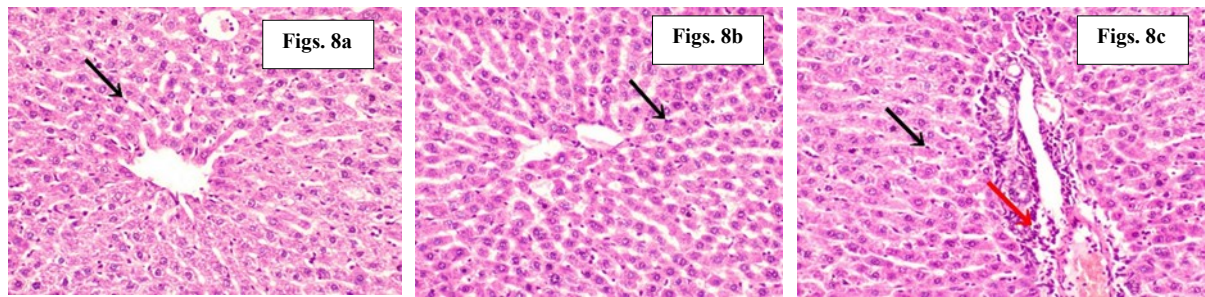

Figure 8. Photomicrograph of liver of mice's from group 4

Fig. 8a, 8b (showing Kupffer cells activation (black arrow), Fig. 8c (showing Kupffer cells activation (black arrow) and portal infiltration with inflammatory cells (red arrow)).

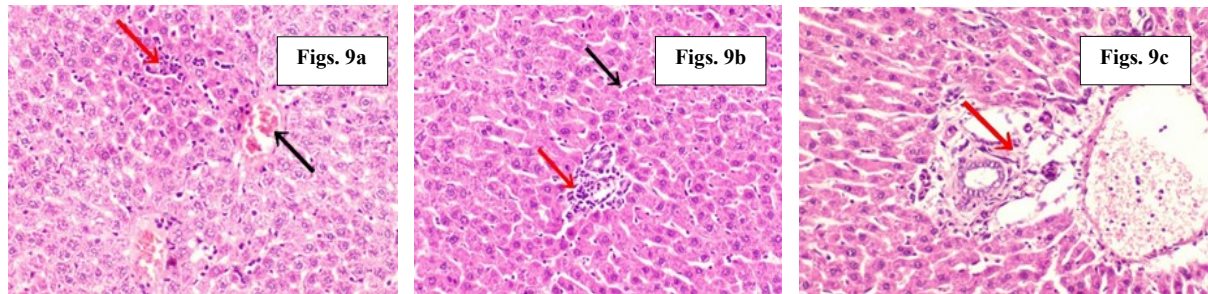


Figure 9. Photomicrograph of liver of mice's from group 5

Fig. 9a (showing congestion of central vein (black arrow) and focal hepatocellular necrosis associated with inflammatory cells infiltration (red arrow)), Fig. 9b (showing Kupffer cells activation (black arrow) and portal infiltration with inflammatory cells (red arrow)), and Fig. 9c (showing portal edema (arrow)).

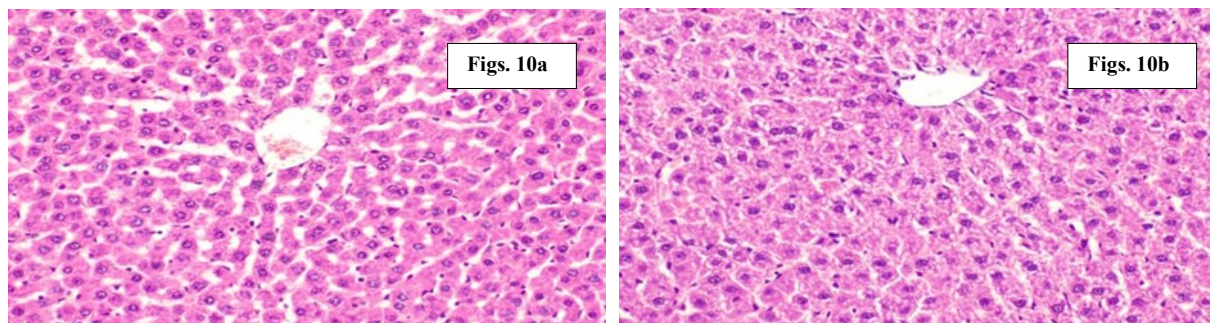


Figure 10. Photomicrograph of liver of mice's from group 6 and 7

Fig. 10a and 10b showing no histopathological alterations

4. Conclusion

Numerous pharmacological effects of glutathione have been discovered through both in vitro and in vivo investigations. It has not been documented, nonetheless, that glutathione protects mice's hepatocytes against damage caused by furans. The present study looks at how glutathione protects liver and kidney function as well as tumor indicators against furan-induced harm in mice. Furan caused severe hepatocyte injury in mice, as demonstrated by the increased activity of aminotransferase (AST) and alanine aminotransferase (ALT). It also promotes oxidative stress due to high malondialdehyde levels.

When compared to the control, it was shown that all furan levels raised tumor markers (AFP). The mice treated with glutathione significantly prevented the hepatocyte damage caused by furan as well as reduced the level of AFP to near control. Glutathione's exceptional capacity to scavenge free radicals may explain its protective properties against furan-induced hepatocyte damage, making it a potential therapeutic and preventative agent for furan-related diseases.

References

- Adinolf, A., Adinolfi, M. Alpha-feto-protein during development and in disease. (1975). *J Med Genet.*, 12(2): 138–151, doi: 10.1136/jmg.12.2.138, indexed in Pubmed: 49425.
- Akillioğlu, H.G., Bahçeci KS, and Gökmen V. (2015). Investigation and kinetic evaluation of furan formation in tomato paste and pulp during heating *Food Research International*, 78, 224–230.
- Aksu B, Inan M, Kanter M, Ozpuyan F, Uzun H, and Durmus G. (2007). The effects of methylene blue on renal scarring due to pyelonephritis in rats. *Pediatric Nephrology*, 22, 992-1001.
- Arrivi A, Truscetti G, Pucci G, Barillà F, Carnevale R, Nocella C, Sordi M, Dominici M, Tanzilli G and Mangieri E. (2023). The Combined Treatment of Glutathione Sodium Salt and Ascorbic Acid for Preventing Contrast-Associated Acute Kidney Injury in ST-Elevation Myocardial Infarction Patients Undergoing Primary PCI: A Hypothesis to Be Validated. *Antioxidants* 2023, 12, 773.
- Aydin Y, Yilmaz B, Dikbasan YU, and Orta-Yilmaz B. (2023). Assessment of the oxidative damage and apoptotic pathway related to furan cytotoxicity in cultured mouse Leydig cells. *Toxicology Research*, Volume 12, Issue 3, June 2023, Pages 400–407.
- Bakhiya N and Appel KE. (2010). Toxicity and carcinogenicity of furan in human diet. *Arch Toxicol*, 84, 563-578.
- Bhadoria M and Nirala SK. (2009). Reversal of acetaminophen induced subchronic hepatorenal injury by propolis extract in rats. *Environ Toxicol Pharmacol*; 27, 17–25.
- EFSA (European Food Safety Authority) (2017): Risks for public health related to the presence of furan and methylfurans in food. EFSA Panel on Contaminants in the Food Chain (CONTAM). *EFSA Journal*, 15 (10):5005.
- EFSA (European Food Safety Authority) (2004): Report of the scientific panel on contaminants in the food chain on provisional findings on furan in food. *EFSA J.*, 137, 1–20.
- Fossati P, Precipe L and Berti G. (1980). Use of 3,5 - dichloro-2-hydroxybenzene sulfonic acid /4 aminophenazonechromogenic system in direct enzymatic assays of uric acid in serum and urine. *Clin Chem.*;26:227- 23.
- Fromberg, A., Mariotti, M.S., Pedreschi, F., Fagt, S. and Granby, K. (2014). Furan and alkylated furans in heat processed food, including home cooked products. *Czech Journal of Food Sciences*, 32, 443–448.
- Halliwell, B. and Gutteridge, J.M. (2015). *Free radicals biology and medicine*. 5th edition ed. Oxford University Press, New York, NY; 2015.
- Halliwell, B. (2013). The antioxidant paradox: less paradoxical now? *Br. J. Clin. Pharmacol.* 75, 637–644.
- Hamadeh, H.K., Jayadev S., Gaillard, E.T., Huang, Q., Stoll, R., and Blanchard, K. (2004). Integration of clinical and gene expression endpoints to explore furan-mediated hepatotoxicity. *Mutation Research/Fundamental and Molecular Mechanisms of Mutagenesis*. 2004; 549(1-2): 169-83.
- Heinegard, D. and Tindstrom, G. (1973). Determination of serum creatinine by a direct colorimetric method. *Clin Chem Acta*, 43:395-410.
- IARC (International Agency for Research on Cancer), IARC Monographs on the Evaluation of Carcinogenic Risks to Humans, Lyon, 1995, pp. 3194–3407.
- Jang, S., Choi, G.H., Chang, W., Jang, E.S., Kim J.W., and Jeong, S.H. (2022). Elevated alpha-fetoprotein in asymptomatic adults: Clinical features, outcome, and association with body composition. *PLoS One*,17(7):e0271407
- Javed, F., Shahbaz, H.M., Nawaz, A., Olaimat, A.N., Stratakos, A., Wahyono, A., Munir, S., Mueen-ud-din, G., Ali, Z., and Park, J. (2021) Formation of furan in baby food products: Identification and technical challenges. *Compr Rev Food Sci Food Saf.* 2021;20:2699–2715.
- Kalyane, D., Maheshwari, R., Raval, N., Chauhan A.S., Tekade, R.K. (2019). Chapter 9 - Transportation and Biointeraction Properties in Nanomaterials Across Biological Systems. In: Tekade RK, editor *Basic Fundamentals of Drug Delivery*: Academic Press, 2019: 343-368.
- Kaya, E., Yilmaz, S., and Ceribasi, S. (2019). Protective role of propolis on low and high dose

- Furan induced hepatotoxicity and oxidative stress in rats. *Journal of Veterinary Research*, 63 (3): 423-31.
- Kettlitz B., Scholz G., Theurillat V., Cselovszky J., Buck N.R., Hagan S.O., Mavromichali E., Ahrens K., Kraehenbuehl K., and Scozzi G., (2019). Furan and methylfurans in foods: An update on occurrence, mitigation, and risk assessment. *Comprehensive Reviews in Food Science and Food Safety* 18 (3):738–52. Doi: 10.1111/1541-4337.12433,.
- Kotsos D., and Tziomalos K. (2023). Microsomal Prostaglandin E Synthase-1 and -2: Emerging Targets in Non-Alcoholic Fatty Liver Disease. *Int. J. Mol. Sci.*, 24, 3049.
- Lee D.H., and Jacobs D.R. (2015). Hormesis and public health: can glutathione depletion and mitochondrial dysfunction due to very low-dose chronic exposure to persistent organic pollutants be mitigated? *J. Epidemiol. Commun. Health*, 69, 294–300
- Liu Y.R., Lin B.B., Zeng D.W., Zhu Y.Y., Chen J., and Zheng Q. (2014). Alpha-fetoprotein level as a biomarker of liver fibrosis status: a cross-sectional study of 619 consecutive patients with chronic hepatitis B. *BMC Gastroenterol*;14:145
- Mary, M., Morales, A., Colell, A., Garcia-Ruiz C. and Fernandez-Checa, J.C. (2015). Mitochondrial glutathione, a key survival antioxidant. Halliwell B, Gutteridge JM. *Free radicals in biology and medicine*. 5th edition ed. Oxford University Press, New York, NY; 2015.
- Mogol, B.A., and Gökmen, V. (2013). Kinetics of furan formation from ascorbic acid during heating under reducing and oxidizing conditions. *Journal of Agricultural and Food Chemistry*, 61, 10191– 10196.
- Moser, G.J., Foley J., Burnett, M., Goldsworthy T.L., and Maronpot R. (2009). Furan-induced dose-response relationships for liver cytotoxicity, cell proliferation, and tumorigenicity. *Exp. Toxicol. Pathol.*, 6, 101–111.
- Niu, B., Liao, K., Zhou, Y., Wen, T., Quan, G., Pan, X., and Wu, C. (2021). Application of Glutathione Depletion in Cancer Therapy: Enhanced ROS-Based Therapy, Ferroptosis, and Chemotherapy. *Biomaterials* 2021, 277, 121110.
- NTP (National Toxicology Program), 1993. Toxicology and carcinogenesis studies of furan (CAS No. 110-00-9) in F344 Rats and B6C3F1 Mice (Gavage Studies). National Toxicology Program Technical Reports Series, 402, 286 pp.
- Parsons, Z.D., and Gates KS. (2013). Thiol-dependent recovery of catalytic activity from oxidized protein tyrosine phosphatases. *Biochemistry*, 52 (37): 6412-6423.
- Peterson, L.A., Cummings, M.E., Vu, C.C., and Matter BA. (2005) Glutathione trapping to measure microsomal oxidation of furan to cis-2-butene-1,4-dial. *Drug Metab Dispos* 33:1453–1458.
- Placer, Z.A., Cushman, L., and Johnson, B.C. (1966). Estimation of products of lipid peroxidation in biological fluids. *Anal Biochem* 1966, 16, 359–364.
- Rahn, A. and Yeretian, C. (2019). Impact of consumer behavior on furan and furan-derivative exposure during coffee consumption. A comparison between brewing methods and drinking preferences. *Food Chemistry*, 272:514–22.
- Salah- Eldina, A., and Ibrahim, H.M. (2023). Effect of some Foods on Glutathione Synthesis to Reduce Hepatic and Renal Toxicity in Rats. *Egypt. J. Chem.* Vol. 66, No. 7 pp. 497 – 508.
- Sampson, E.J., Baird, M.A., Burtis, C.A., Smith E.M., Witte, D.L., and Bayse, D.D. (1980). A coupled enzyme equilibrium method for measuring urea in serum: Optimization and evaluation of the AACC study group on urea candidate reference method. *Clin Chem.*, 26 (7): 816-26
- Tebib, K., Rouanet, J.M., and Beasancon, P. (1997). Antioxidant effects of dietary polymeric grape seed tannins in tissues of rats fed a high cholesterol vitamin E deficient diet. *Food Chemistry*, 59: 135-141.
- Turshudzhyan, A., and Wu, G.Y. (2022). Persistently Rising Alpha-fetoprotein in the Diagnosis of Hepatocellular Carcinoma: A Review. *J Clin Transl Hepatol.*, 10 (1): 159-163.
- Vaca, C.E., Wilhelm, J.M., and Harms-Rihdsahl, M. (1988). Interaction of lipid peroxidation product with DNA. A review. *Mutation Research/Fundamental and Molecular Mechanisms of Mutagenesis*, 195 (2), 137–149.

- Wang S., Chen L., Shi X., Wang Y, and Xu S. (2023). Polystyrene microplastics-induced macrophage extracellular traps contributes to liver fibrotic injury by activating ROS/TGF- β /Smad2/3 signaling axis. *Environ Pollut.*, 324: 121388.
- Wong R.J., Ahmed A., and Gish R.G. (2015). Elevated alpha-fetoprotein: differential diagnosis - hepatocellular carcinoma and other disorders. *Clin Liver Dis.*, 19 (2) :309-323.
- Yilmaz A., and Çomaklı, V. (2023). Investigation of Effects of Some Metal Ions and Some Pesticides on Glutathione S-Transferase (GST) Enzyme Purified from Van Lake Fish (*Chalcalburnus Tarichi*) Kidney. *Iğdır Üniversitesi Fen. Bilim. Enstitüsü Derg.*, 13, 1101–1109.
- Yuan Y, Wu S.J., Liu X, Zhang, L.L. (2013). Antioxidant effect of salidroside and its protective effect against furan-induced hepatocyte damage in mice. *Food and Function*, 4, 763–769. <https://doi.org/10.1039/c3fo00013c>
- Zhang BL, Guo CC, Ding F, Lu YT, and Fu ZW. (2019). 14-3-3s function in plant cadmium response by changes of glutathione and glutathione synthesis in *Arabidopsis*. *Environ Exp. Bot.*, 163:69–77