



EGYPTIAN ACADEMIC JOURNAL OF
BIOLOGICAL SCIENCES
ZOOLOGY


B



ISSN
2090-0759

WWW.EAJBS.EG.NET

Vol. 16 No. 1 (2024)



Ellagic Acid Co-Administration: A Protective Strategy Against Aging and Dietary-Induced Pheochromocytoma in Rats

Gehan M.Morsy, Bakinam A. Mohamed and Alyae M.S.Gabal

Biochemistry and Nutrition Department, Faculty of Women for Arts, Science and Education, Ain Shams University, Cairo, Egypt.

* E-mail : alyeesalah@women.asu.edu.eg

ARTICLE INFO

Article History

Received:22/2/2024

Accepted:24/3/2024

Available:28/3/2024

Keywords:

Ellagic acid;

Pheochromocytoma;

Benign tumors;

Biochemical

alterations;

Antioxidants.

ABSTRACT

Benign tumor incidence increased as a result of bad lifestyle and dietary habits. Finding natural dietary antioxidants may help control tumor incidence and spread. Pheochromocytoma is a rare neoplastic chromaffin cell-based benign tumor in the adrenal glands medulla. Pheochromocytoma incidence may increase as a result of the aging process or due to dietary consumption of sugar alcohols. Ellagic acid is a naturally occurring polyphenolic molecule that possesses multiple health benefits and can potentially compete with the development of pheochromocytoma. 50 male Wistar rats were used to investigate the efficacy of ellagic acid in protecting against aging and dietary-induced pheochromocytoma. Biochemical parameters in all experimental rats were determined. Results revealed that both aged and dietary-induced pheochromocytoma caused significant ($p \leq 0.05$) boost in systolic blood pressure, catecholamines (dopamine and norepinephrine), metabolites, blood glucose, and serum calcium levels. It also impaired significantly ($p \leq 0.05$) renal and hepatic functions, induced oxidative inflammatory status as well as apoptotic gene expression. Ellagic acid consumption protects from pheochromocytoma biochemical alterations and maintains normal body function and hemostasis. Pheochromocytoma is associated with many adverse biochemical changes that may be lethal if it is not diagnosed and treated quickly. Ellagic acid is a promising antioxidant and its consumption can protect from benign tumors. The study is expected to encourage people to change their bad dietary habits and consume natural antioxidants from nature.

INTRODUCTION

Pheochromocytomas are typically neoplastic chromaffin cell-based benign tumors that develop in the adrenal glands, specifically in the adrenal medulla, which exists on top of the kidneys. These tumors lead to the overproduction of catecholamines, including adrenaline and noradrenaline, resulting in various symptoms and health implications. While the precise causes of pheochromocytomas are not always well-defined, they are often associated with genetic mutations in adrenal medulla cells (Lenders and Eisenhofer, 2017).

Excessive catecholamine production in pheochromocytomas frequently results in severe and intermittent hypertension, irregular heart rhythms, palpitations, heart damage,

severe headaches, excessive sweating, tremors, and feelings of anxiety or panic. However, these tumors can also occur spontaneously without a clear genetic predisposition due to dietary and physiological causes such as the aging process (Pacak and Tella, 2018).

Aging is a complicated process caused by the progressive buildup of compounds that damage cells as reactive oxygen species (ROS) over time, leading to problems with cell organelles, disruptions in cell membrane structure, damage to large molecules, and a decline in the functioning of cells and organs (Micheli *et al.*, 2023 and li *et al.*, 2023).

Apoptosis is the apparent mechanism triggered by oxidative stress, which includes protein oxidation, lipid peroxidation, mitochondrial and DNA damage, and the activation of pro-inflammatory responses (li *et al.*, 2023). Endogenous enzymatic and non-enzymatic antioxidant defense mechanisms are compromised by ROS, either through direct or indirect means (Armaini and Imelda, 2021).

D-galactose (D-gal), a monosaccharide, is the prevalent form of galactose found in nature and is widely distributed in dairy products, fruits, and vegetables (Haider *et al.*, 2015). It serves as a crucial component in the D-gal-prompted aging model, which has become increasingly important in aging investigation (Mohamed *et al.*, 2022).

In normal consumption amounts, D-gal is metabolized into glucose. However, in excess, galactose oxidase converts it into aldose and hydroperoxide, leading to the generation of oxygen-derived free radicals and superoxide anions. In addition, excessive amounts of D-gal can attach to free amine groups, leading to the accumulation of advanced glycation end products (AGEs) via a process of non-enzymatic glycation (Budni *et al.*, 2016).

Advanced glycation end products (AGEs) bind to their receptors, triggering ROS production and activating intracellular inflammatory signaling pathways. This, in turn, initiates the transcription of downstream genes, including nuclear factor NF- κ B, which becomes phosphorylated in the nucleus and leads to various responses such as oxidative stress and inflammation leading to the pathogenesis of several disorders (Hudson and Lippman, 2018; Li *et al.*, 2019 and Liu *et al.*, 2021).

Certain dietary components, such as high levels of sorbitol (Sor), lactose, xylitol, and mannitol, along with other sugars and sugar alcohols, have been linked to a greater incidence of pheochromocytomas and adrenal medullary hyperplasia (Chattopadhyay *et al.*, 2014).

These dietary components, which are frequently used as food additives in human food products without apparent adverse effects, have been shown to develop pheochromocytomas in animal models (Tappy and L e, 2010 and Bourdeau *et al.*, 2018).

Sorbitol (Sor), or D-glucitol, is a six-carbon alditol with a sweet flavor that naturally occurs in fruits and vegetables (Chukwuma and Islam, 2017). It is notable for its sweetness as sucrose but with fewer calories (Latona and Akinola, 2020). Sor undergoes metabolism primarily in the liver, with a portion that remains non-absorbed and is metabolized by colonic bacteria. High dietary levels of Sor and certain nutrients can induce pheochromocytomas and adrenal medullary hyperplasia (Al-Salih and Abbas, 2021).

Ellagic acid (EA) is a compound, with the chemical formula $C_{14}H_6O_8$. It is often found in nuts, vegetables, and fruits (Naghibi *et al.*, 2023). EA exhibits powerful antioxidant and anti-aging properties due to its structure, which includes two lactones, four hydroxyl groups, and two hydrocarbon rings (Zhu *et al.*, 2022). EA has garnered significant attention for its diverse health advantages through its capacity to combat harmful reactive oxygen and nitrogen species (RONS), by-products of aerobic metabolism, cellular repair, and collagen production (Chen *et al.*, 2018 and Sharifi-Rad *et al.*, 2022).

Anti-aging effects are typically influenced by a combination of factors, including genetics, lifestyle, and overall diet. Incorporating a well-balanced diet rich in antioxidants,

including EA from natural sources like berries and nuts, can be a valuable part of an anti-aging strategy (Zhu *et al.*, 2022).

The current investigation sought to determine whether EA may have any impact on pheochromocytoma, which was caused by D-gal-induced aging patterns or high dietary Sor levels.

MATERIALS AND METHODS

Chemicals and Reagents:

D-gal (No.100151-230, purity $\geq 99\%$), Sor (No. 200-061-5, purity $\geq 98\%$) and EA (No.207-508-3, purity $\geq 95\%$) were supplied by Sigma-Aldrich Company for Chemicals, (St. Louis, MO, USA), all additional solvents and reagents were of high analytical purity and provided by El-Gomhoria Company for Chemicals in Cairo, Egypt.

Diet:

Commercially available standard diet (National Research Council,1995) bought from the Biological Products and Vaccines Organization (Helwan, Egypt).

Animals:

Fifty male adult albino Wistar rats, 180-200g and 7 weeks old, were bought from the National Research Centre (Cairo, Egypt). The animals were maintained individually in steel enclosures with a regulated temperature of $25\pm 5^\circ\text{C}$, air humidity of $55\%\pm 10\%$, and a light/dark cycle of 12/12 hours. The animals were provided with commercial food and water *ad libitum* for 7 days, (acclimatization period).

Experimental Design:

Animals were split into 5 groups, each consisting of ten rats-:

1-Group 1 (**G1**): Normal control (**NC**), rats received Tween 80 orally and injected with normal saline subcutaneously.

2-Group 2 (**G2**): Aged-induced pheochromocytoma (**AP**), rats were administered D-gal subcutaneously at a dosage of 300mg per kilogram of body weight per day, dissolved in a solution of normal saline with a concentration of 0.9% (weight/volume) (Bo-Htay *et al.*, 2018).

3-Group 3 (**G3**): Aged-induced pheochromocytoma supplied with EA (**AP+EA**), rats were administered subcutaneously with D-gal at a dose of (300mg/kg B.W/d) dissolved in normal saline (0.9%, w/v). EA was dissolved in Tween 80 and delivered via oral gavage at a dose (150 mg/kg B.W) (Wang *et al.*, 2015).

4-Group 4 (**G4**): Dietary-induced pheochromocytoma (**DP**), rats received Sor at a dose of (15g/kg B.W) dissolved in water by oral gavage (WHO, 2023).

5-Group 5 (**G5**): Dietary induced pheochromocytoma supplied with EA (**DP+EA**), rats received Sor at a dose (15g/kg B.W) dissolved in water and EA was dissolved in Tween 80 and delivered via oral gavage at a dose (150 mg/kg B.W).

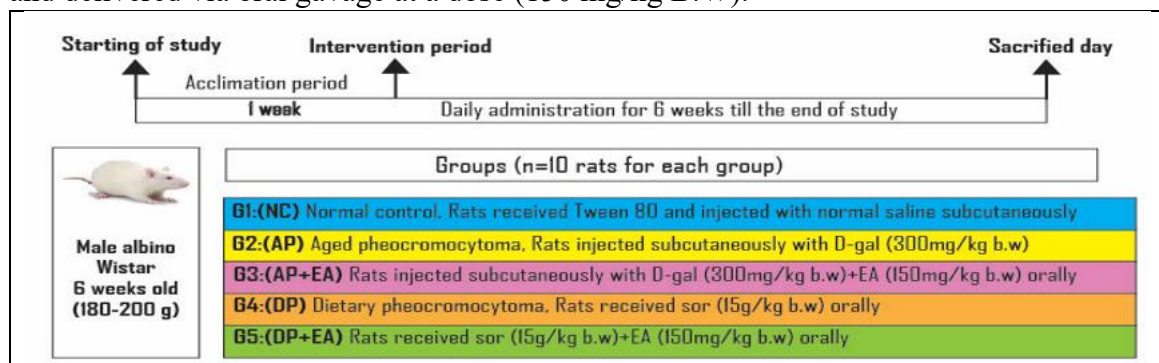


Fig.1:Design of study .D-gal;D-galactose.Sor.Sorbitol;EA;Ellagec acide.

Systolic Blood Pressure Measurement:

The systolic blood pressure (SBP) was determined while the animals were under anesthesia on the sacrifice day. This was accomplished by means of a blood pressure tail-cuff device (Model 29 pulse amplifier equipped with an integrated tail-cuff sensor and a modified rodent restrainer). To determine the final measurement for SBP, three consecutive readings were recorded and averaged (Azlina *et al.*, 2009).

Collection of Samples:

After the 6-week experiment, each animal was put in a metabolic cage to gather urine samples over 24 hours. At first, to the test tubes, a drop of strong hydrochloric acid was added as a preservative (Mariappan *et al.*, 2016). After the urine collection period, rats were administered 1% sodium pentobarbital as an anesthetic to get blood samples after a period of overnight fasting. Serum and plasma were separated from blood and renal tissues homogenate prepared from separated kidneys and then stored in a deep freezer at a temperature of -20°C until analyzed.

Biochemical Analysis:**Determination of Dopamine, Norepinephrine, Chromogranin A and Metanephrine"**

Serum and urine dopamine and norepinephrine, plasma chromogranin A (parathyroid secretory protein 1), and metanephrine in serum and urine were determined using a rat ELISA kit from MyBioSource Company (San Diego, California, USA), in stat fax-2100 equipment.

Determination of Fasting Blood Glucose and Serum Calcium Levels:

Blood glucose during fasting was measured using the enzymatic colorimetric technique (Trinder, 1969), and serum calcium level was measured using the colorimetric method (Gindler and King, 1972).

Determination of Kidney Functions:

Colorimetric test kits obtained from a Bio- diagnostic company (Dokki, Giza, Egypt) were used to measure serum urea, creatinine, and protein levels.

Measurement of Antioxidant Activity and Lipid Peroxidation:

The activity of erythrocyte superoxide dismutase, (SOD) and level of reduced glutathione (GSH) were done (Nishikimi *et al.*, 1972 and Beutler *et al.*, 1963). Serum malondialdehyde (MDA) content was measured (Draper and Hadley, 1990) by a colorimetric assay kit purchased from a Biodiagnostic company (Dokki, Giza, Egypt).

Determination of Inflammatory Markers in Serum:

Tumor necrosis factor – α (TNF- α), interleukin-1 β (IL-1 β), and interleukin-6 (IL-6) levels in serum were analyzed by rat ELISA kit from MyBiosource company (San Diego, California, USA), in stat fax-2100 equipment.

Biochemical Parameters of Hepatic Marker Enzymes:

Serum aspartate aminotransferase (AST) and alanine aminotransferase (ALT) activities were measured using the colorimetric technique using kits of Spectrum Diagnostics, Egypt (Reitman and Frankel, 1957).

Relative Gene Expression of Apoptotic Markers in Renal Tissue:

The real-time quantitative polymerase chain reaction method was used to determine B-cell lymphoma2 (Bcl2) and Bcl2 associated x-protein (BAX) gene expression in renal tissue using SV total RNA isolation system (CAT. NO. #Z3500, Promega, USA) tissue extraction kit, high capacity cDNA reverse transcription kit (CAT. NO. #K4374966, Thermo Fisher Scientific, USA), and Maxima SYBR Green qPCR Master Mix (2X) kit with ROX solution (CAT. NO. #K0252, Thermo Fisher Scientific, USA) following Bcl2 Forward: 5'-GTGGATGACTGAGTACCT -3' and Reverse: 5'- CCAGGAGAAATCAAACAGAG -3' primers as well as forward:5'- CTACAGGGTTTCATCCAG -3'and reverse: 5'-CCAGTTCATCTCCAATTCG -3' primers for BAX (Afonina *et al.*, 1997).

Statistical Analysis:

The findings were presented as mean \pm SE or standard error. Version 20 of the Statistical Program for Social Sciences (SPSS) was used to examine values using one-way ANOVA. The least significant difference (LSD) at the ($P \leq 0.05$) level was used to examine the average difference (Levesque, 2007)

RESULTS**Analysis of Systolic Blood Pressure:**

Data illustrated in Figure 2, revealed that both aged and dietary-induced pheochromocytoma rats suffered from high systolic blood pressure in comparison with normal control rats ($p \leq 0.05$). Contrary EA consumption improved systolic blood pressure levels in affected rats (G3 and G5) ($p \leq 0.05$) in comparison to non-supplemented rats (G2 and G4).

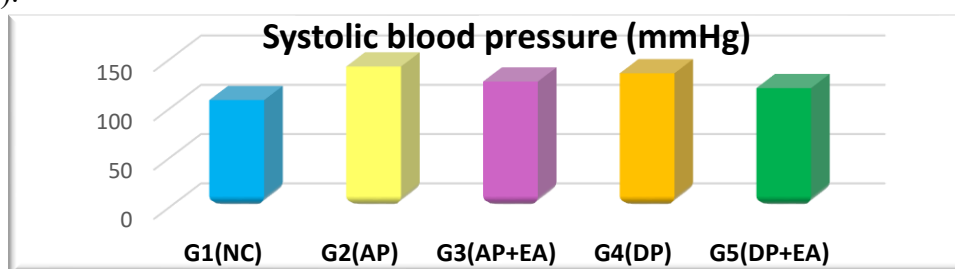


Fig. 2: Systolic blood pressure in all experimental groups.

Dopamine and Norepinephrine Levels:

Results presented in Figure 3 (a,b,c, and d), illustrated that both aged and dietary induction of pheochromocytoma caused an increased secretion of dopamine and norepinephrine resulting in their high level in both serum and urine. On the other hand EA attenuated hormone secretion in supplemented groups. Aged pheochromocytoma rats recorded the highest serum and urine dopamine and norepinephrine levels ($p \leq 0.05$).

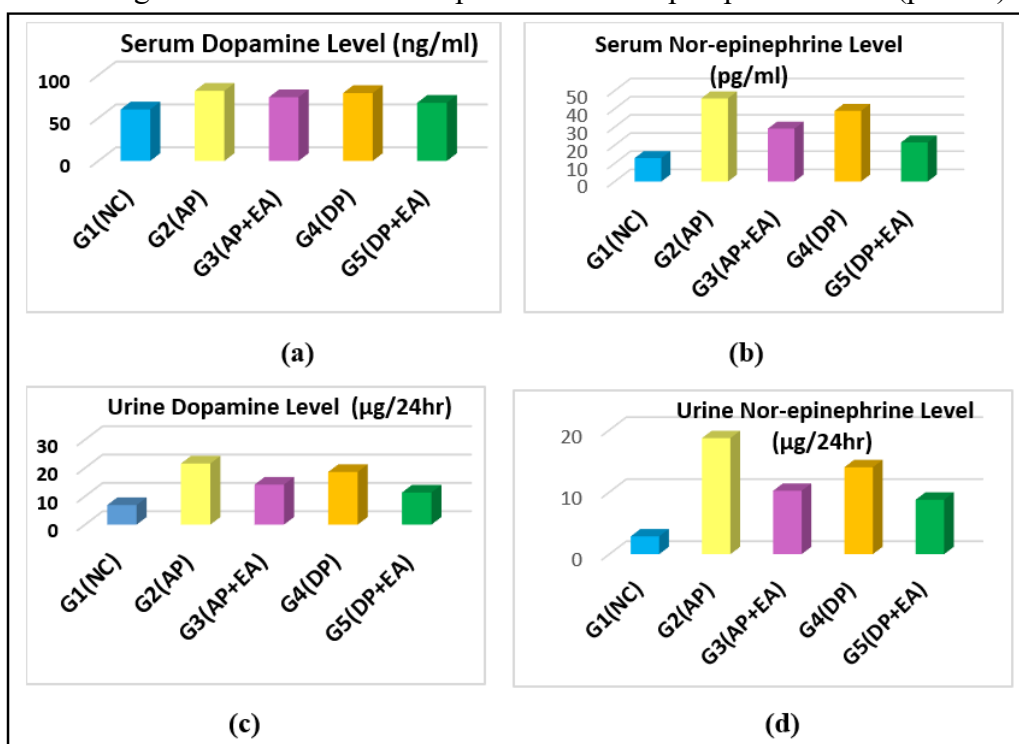


Fig.3: Serum and urine dopamine and nor-epinephrine levels in all experimental groups.

Exploring Chromogranin A and Metanephrine Concentrations

Plasma chromogranin A, plasma, and urine metanephrine concentrations were significantly elevated ($p \leq 0.05$) in aged and dietary-induced pheochromocytoma groups (Fig. 4 a,b, and c). Health-promoting properties of EA improved these results by decreasing levels of plasma chromogranin A and metanephrine in plasma and urine significantly ($p \leq 0.05$) in G3 and G5.

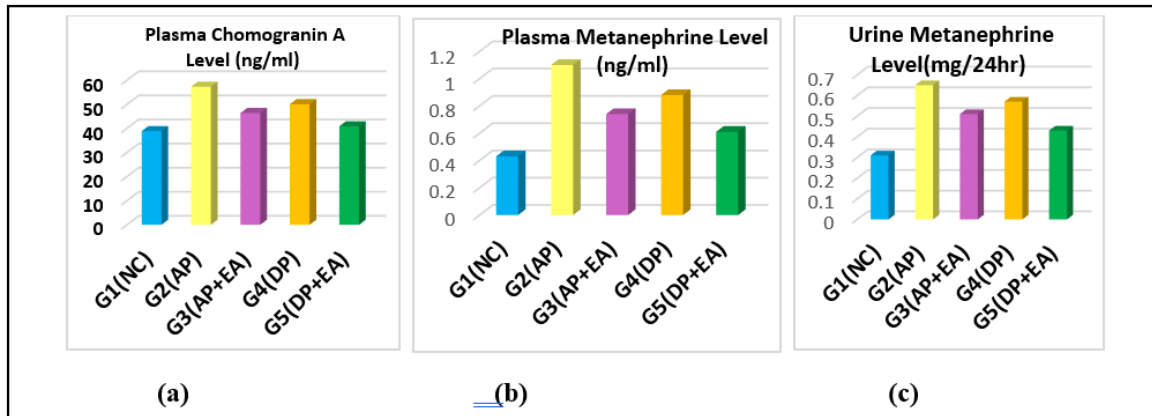


Fig. 4: Chromogranin A and metanephrine concentrations in all experimental groups.

Fasting Blood Glucose and Serum Calcium Levels:

One of the biochemical signs of pheochromocytoma is increased levels of fasting blood glucose and calcium significantly as in G2 and G4 ($p \leq 0.05$) in comparison with the normal control group. EA oral intake in G3 and G5 improved blood glucose and calcium concentrations significantly ($p \leq 0.05$) (Fig. 5 a and b).

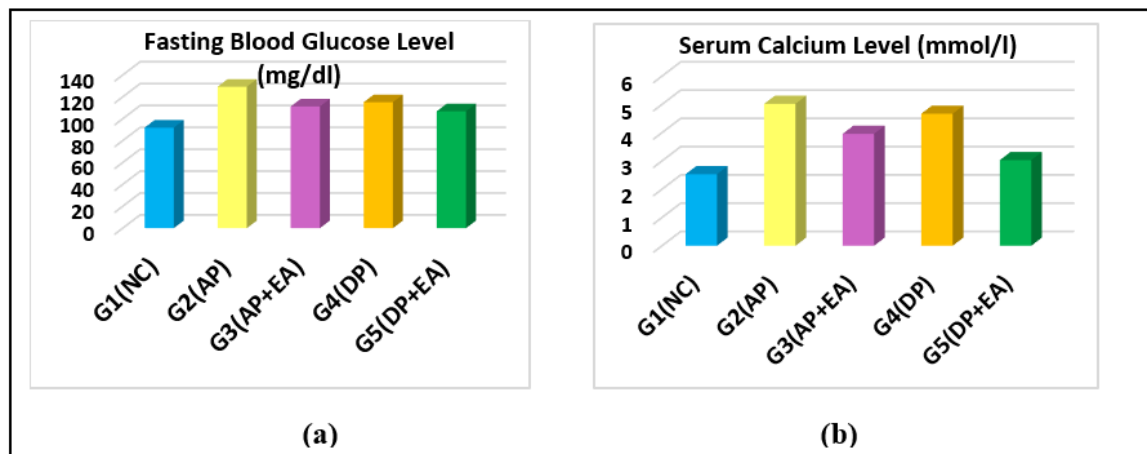


Fig. 5: Fasting blood glucose and serum calcium contents in all experimental groups.

Estimation of Kidney Function:

Pheochromocytoma deteriorated kidney functions (Fig. 6 a, b and c) as indicated by increased serum urea, creatinine, and total protein levels significantly ($p \leq 0.05$) in both aged and dietary forms while EA-consumed rats showed enhanced renal functions as in G3 and G5.

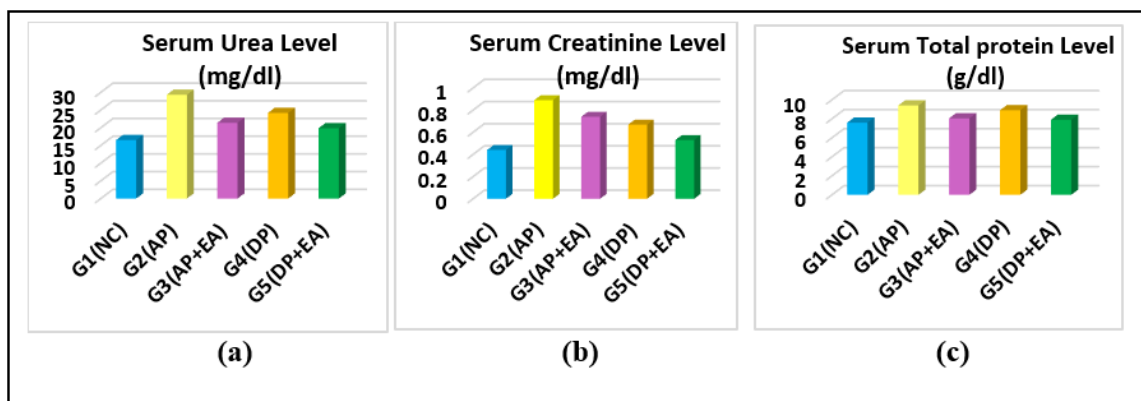


Fig. 6: Serum urea, creatinine, and total protein levels in all experimental groups.

Antioxidants and Lipid Peroxidation Effects:

Values shown in Figure 7(a, b, and c), illustrated that pheochromocytoma caused an oxidative status by decreased SOD activity, GSH level, and increased MDA values significantly ($p \leq 0.05$) in G2 and G4. Antioxidant properties of EA counteracted the oxidative status in supplemented groups by improving antioxidant activity and level with attenuating MDA formation in G3 and G5 significantly ($p \leq 0.05$).

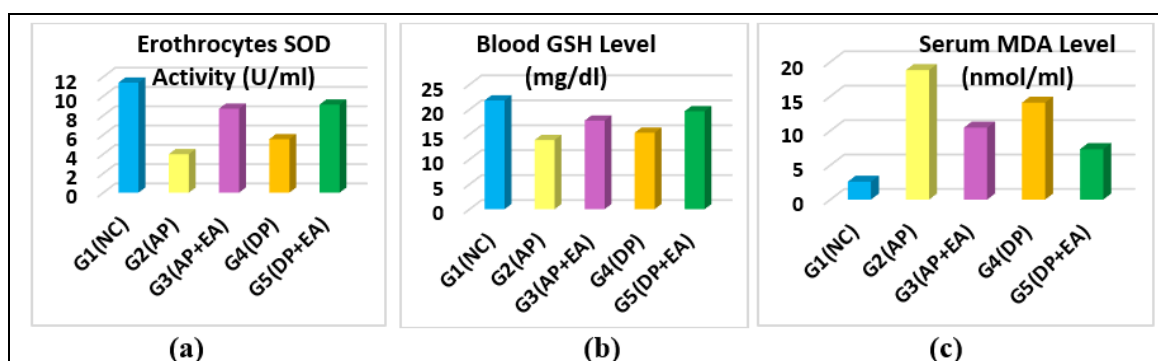


Fig.7: Erythrocytes SOD activity, blood GSH, and serum MDA levels in all experimental groups.

Serum Inflammatory Markers:

Serum inflammatory marker levels such as TNF- α , IL-1 β , and IL-6 were significantly elevated ($p \leq 0.05$) in aged and dietary-induced pheochromocytoma (Fig 8). The most significant ($p \leq 0.05$) increment was recorded in G2 in comparison to a normal control group. EA prevented inflammation in supplemented groups and improved inflammatory marker levels significantly ($p \leq 0.05$) in G3 and G5.

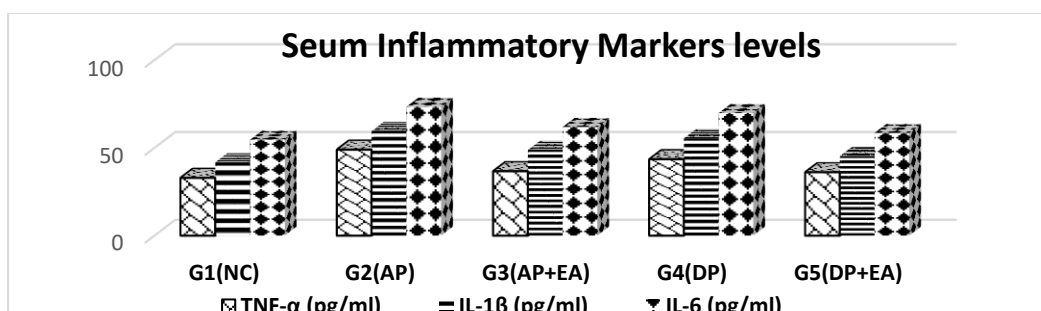


Fig. 8: Serum TNF- α , IL-1 β , and IL-6 levels in all experimental groups.

Serum Hepatic Markers Enzyme Activities:

Liver function deteriorated significantly ($p \leq 0.05$) in pheochromocytoma-induced rats (G2 and G4) (Fig. 9a and b). The most significant increment ($p \leq 0.05$) in serum ALT and AST was recorded in aged-induced pheochromocytoma rats. EA preserved hepatic function in supplemented groups (G3 and G5) significantly ($p \leq 0.05$).

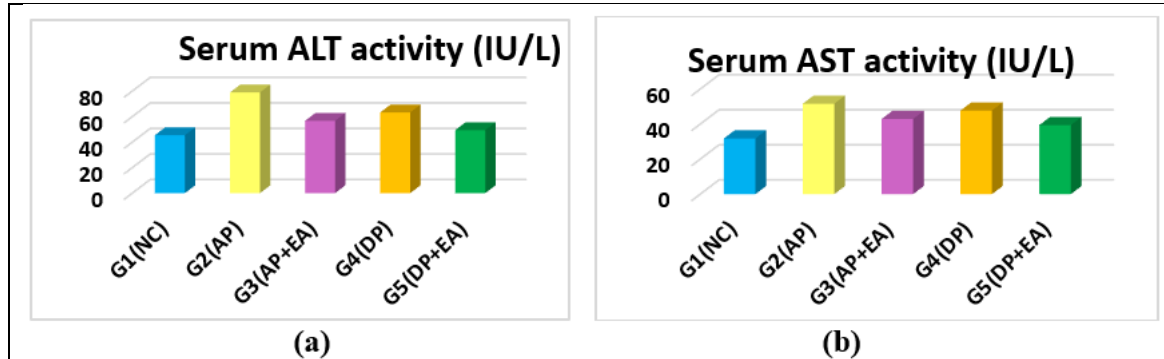


Fig. 9: Serum ALT and AST activities in all experimental groups.

Renal Apoptotic Markers Gene Expression:

As a result of oxidative stress and inflammation apoptosis was initiated in aged and dietary-induced pheochromocytoma rats. Renal apoptotic marker (Bax) gene expression increased significantly while gene expression of renal anti-apoptotic marker (Bcl2) decreased significantly in pheochromocytoma groups (G2 and G4). EA controlled the apoptotic process by improving apoptotic and anti-apoptotic marker gene expression in supplemented groups (Fig 10a and b).

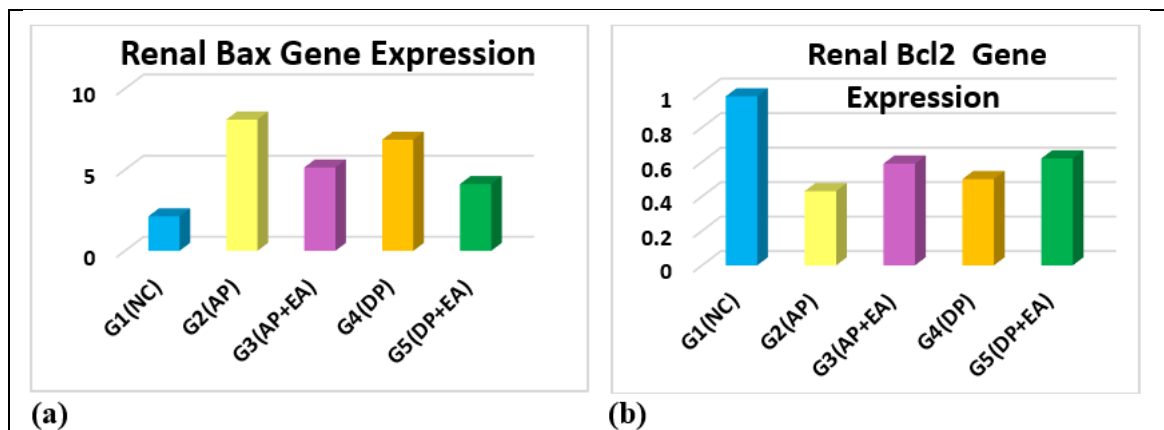


Fig.10: Renal Bax and Bcl2 gene expression in all experimental groups.

DISCUSSION

Pheochromocytomas are typically tumors growing from chromaffin cells, primarily found in the adrenal medulla. Catecholamines including dopamine, epinephrine, and norepinephrine are naturally produced by chromaffin cells. Pheochromocytoma diagnosis usually needs several tests, the most significant of which is biochemical proof of the tumor's excessive synthesis of catecholamines. Measurements of catecholamines and their specific metabolites in urine or plasma are typically used to confirm pheochromocytomas (Lenders et al., 2020 and Gupta and Marwaha, 2023).

Serum and urine dopamine and norepinephrine levels were increased significantly in association with higher systolic blood pressure by D-gal and Sor administration as

evidenced by pheochromocytoma induction. Zuber *et al.*, (2011) found favorable associations between dopamine, epinephrine, and norepinephrine excretion in the urine and systolic blood pressure.

Tischler *et al.*, (1996) found that rats who ate diets containing 20 percent xylitol or Sor, showed an increase in catecholamine concentration in their adrenal glands. This suggests that dietary sugars and their alcohols affect the function of the adrenal medulla. This elevation was minimized in groups supplemented with EA and such results are emphasized by another study done by Hoseinynejad *et al.*, (2021) who found that EA is effective as a therapy for illnesses involving the kidneys. EA's antioxidant action demonstrates its ability to block the angiotensin-converting enzyme, which has rendered it a desirable molecule for the management of hypertension (Sharifi-Rad *et al.*, 2022 and Gbinigie *et al.*, 2017).

Adrenal tumor chromaffin cells increase the generation of norepinephrine and adrenal hormones, which are then metabolized into metanephrine and normetanephrine (Mohr *et al.*, 2021). Plasma metanephrine is a highly sensitive and specific way to diagnose pheochromocytomas and its concentration is correlated with the size of the tumor (Mula-Abed *et al.*, 2015).

Chromogranin A (parathyroid secretory protein 1) is a biomarker for the assessment of neuro-endocrine tumors including adrenal system tumors such as pheochromocytoma. It has been proposed that employing chromogranin A as an indicator could aid in differentiating pheochromocytoma as part of the secondary diagnostic assessment for arterial hypertension (Bílek *et al.*, 2019).

Chromogranin A and catecholamine release, which affects the control of blood pressure, have a more complex interaction, the kidneys eliminate chromogranin A, and even a little renal failure can cause large increases in its serum concentration (Mir *et al.*, 2020).

The value of measuring the amount of chromogranin A; (a tumor marker for several diseases) was higher in 89% of pheochromocytomas (Bílek *et al.*, 2019).

Pheochromocytomas in rats can lead to the formation of the rat's adrenal medulla proliferative lesions. These lesions function by changing the calcium homeostasis, which causes the adrenal medulla's cells to proliferate. Numerous non-genotoxic substances that cause pheochromocytomas in rats appear to share this route (Tischler *et al.*, 1996; Tischler *et al.*, 1999 and Greim, *et al.*, 2009).

In rats, the development of adrenal tumors caused by high dosages of slowly or poorly absorbed carbohydrates, such as lactose or sugar alcohols like Sor, is influenced by three main factors. These factors include a strong genetic susceptibility that predisposes to adreno-medullary proliferation, excessive absorption of calcium in the intestines which leads to disruption of the hormonal system responsible for maintaining calcium balance, and the adrenal gland's proliferative and functional response to such changes in calcium homeostasis (Lynch *et al.*, 1996 and Tischler *et al.*, 1996).

Ca²⁺ up-controls tyrosine hydroxylase, which in turn controls the synthesis of catecholamines (Liu *et al.*, 2020). It was proposed that abnormal calcium homeostasis would promote the growth of chromaffin cells, which are susceptible to oxidative damage from byproducts of catecholamine metabolism (Tischler *et al.*, 1996 and Baez *et al.*, 1994) ultimately leading to the development of pheochromocytomas in rats (Tischler *et al.*, 1999 and Berends *et al.*, 2019).

The organs and blood vessels' receptors for catecholamines respond with released catecholamines, activating an intracellular signal chain through membrane-bound G proteins. Increased basal metabolic rate, increased muscle perfusion, increased heart rate, elevated blood pressure, and an increase in the values of glucose and free fatty acids in the blood linked with insulin resistance are all triggered by two main mechanisms: direct

adrenergic receptor stimulation and indirect glucagon secretion (Greim *et al.*, 2009 and Moustaki *et al.*, 2023).

Norepinephrine and dopamine play a role in controlling renal function. Both dopamine and norepinephrine are released by the renal nerves, and the excretion of both catecholamines in the urine is significantly changed when the kidney is enervated (Choi *et al.*, 2015). This explained the impaired renal function in AP and DP groups. Many research studies have proved the effectiveness of EA as a preventative and treatment for renal problems (Hoseinynejad *et al.*, 2021). EA may be able to avoid nephrotoxicity by reducing biochemical oxidative stress, as measured by parameters such as MDA, which is linked to an improvement in the evaluation of kidney function (Sonaje *et al.*, 2007).

Both AP and DP biochemical investigations were linked with elevated ROS production causing oxidative stress, inflammation, mitochondrial malfunction, and apoptosis. TNF- α , IL-6, and IL-1 β are among the cytokines that manipulate a crucial part in the onset and advancement of oxidative stress because they are linked to ROS (Ullah *et al.*, 2015 and Wang *et al.*, 2022).

While EA intake improved the antioxidant activity, because of its basic structure that scavenges both superoxide radicals and hydroxyl anion. EA's pharmacological properties are dependent on its antioxidant activity (Chen *et al.*, 2018 and Naraki *et al.*, 2023).

In addition, EA can stimulate the activation of genes responsible for the production of molecules involved in antioxidant defense. It also promotes proteins, enzymes, and transcription factors expression that inhibit pathways that produce oxidative stress, such as cytochrome P450-dependent phase I enzymes and nicotinamide adenine dinucleotide phosphate oxidase (Zhong *et al.*, 2018 and Alfei *et al.*, 2020).

Rats given EA exhibited a considerable decrease in the levels of cytokines linked to inflammation (Gupta *et al.*, 2021). Results suggest that EA effectively minimizes inflammation in AP and DP rats by modulating the production of ROS and pro-inflammatory mediators consequently reducing TNF- α , IL-1 β , and IL-6 levels, hence preventing renal cell death (Marín *et al.*, 2013 and Liu *et al.*, 2020).

Elevated ALT and AST activities were recorded in AP and DP rats. There are numerous facets of liver physiology in which catecholamines are involved. Previous reports have indicated their involvement in several pathophysiological processes, including the initiation of fibrosis and the advancement of cancer through inflammation and lipid precipitation (Lelou *et al.*, 2022). There have been reports of liver injury and malfunction after D-gal injection, which would result in various serum enzymes elevated activities (Li *et al.*, 2016). Also, the liver is the main organ responsible for metabolizing Sor. Sor enters the glycolytic route in the liver after being converted to fructose or glucose, which may have an impact on lipogenesis (Ellwood *et al.*, 1999 and Iizuka, 2023).

In the present study elevation of apoptotic marker BAX and decreases in anti-apoptotic marker Bcl2 in AP and DP groups as a result of pheochromocytoma development associated with oxidative stress and inflammation initiating apoptosis and cell death. Administration of EA caused correction of such levels, this is in approval with (Guo and Li, 2018; Liu *et al.*, 2020 and Mohammed *et al.*, 2021). In the meantime, BAX's primary role is to speed up apoptosis. It works in tandem with Bcl2 to control cell death. Consequently, EA treatment reduces apoptosis by dramatically regulating the production of Bcl2 and BAX proteins (Chen *et al.*, 2018 and Čižmáriková *et al.*, 2023).

CONCLUSION

Pheochromocytoma is a neoplastic chromaffin benign tumor that develops in the adrenal medulla atop the kidney. Its development is associated with genetic causes but changes in lifestyle with more consumption of food additives such as D-gal and Sor made pheochromocytoma more common. Investigation of pheochromocytoma is not easy as a result of its associated various symptoms but its main symptom and cause is the increased

catecholamines secretion. Incorporating dietary polyphenolic compounds as EA competes with such diseases due to its many health benefits.

Declarations:

Ethical Approval: The research ethics committee of the Faculty of Women for Arts, Science, and Education maintains records pertaining to animal laboratory regulations and treatment (sci1432305004) that were followed during the animal experiments.

Conflicts of Interest: The authors claim that there are no conflicts of interest.

Authors Contributions: I hereby verify that all authors mentioned on the title page have made substantial contributions to the conception and design of the study, have thoroughly reviewed the manuscript, confirm the accuracy and authenticity of the data and its interpretation, and consent to its submission.

Funding: This investigation received no external funding.

Availability of Data and Materials: All datasets analysed and described during the present study are available from the corresponding author upon reasonable request.

Acknowledgements: Not applicable.

REFERENCES

- Afonina, I.; Zivarts, M.; Kutyavin, I.; Lukhtanov, E.; Gamper, H.; and Meyer, R. B. (1997). Efficient priming of PCR with short oligonucleotides conjugated to a minor groove binder. *Nucleic acids research*, 25(13), 2657–2660. <https://doi.org/10.1093/nar/25.13.2657>.
- Alfei, S.; Marengo, B.; and Zuccari, G. (2020). Oxidative stress, antioxidant capabilities, and bioavailability: ellagic acid or urolithins? *Antioxidants*, 9, 707. <https://doi.org/10.3390/antiox9080707>
- Al-Salih R. M. H. and Abbas, R. K. (2021). Effect of prolonged overdose sorbitol and aspartame administration on serum lipid profile: experimental finding. *Medico-legal Update*, 21, 2:966-976.
- Armaini, A. and Imelda, I. (2021). The protective effect of scenedesmus dimorphus polysaccharide as an antioxidant and antiaging agent on aging rat model induced by D-galactose. *Journal of Applied Pharmaceutical Sciences*, 11; 5:54–63, doi: 10.7324/JAPS.2021.110508.
- Azlina, A.A.; Fariyah, H.S.; Qodriyah, H.M.S.; and Azlina, M.F.N. (2009): Effects of piper sarmentosum water extract on 11 β -hydroxysteroid dehydrogenase type 1 bioactivity in ovariectomy-induced obese rats. *International Journal of Pharmacology*, 5(6):362-369.
- Baez, S.; and Segura-Aguilar, J. (1994). Formation of reactive oxygen species during one-electron reduction of noradrenochrome catalyzed by NADPH-cytochrome P-450 reductase. *Redox report : communications in free radical research*, 1(1), 65–70. <https://doi.org/10.1080/13510002.1994.11746958>
- Berends, A.M.A.; Eisenhofer, G.; Fishbein, L.; Horst-Schrivers, A.N.A.V.D.; Kema, I.P.; Links, T.P.; Lenders, J.W.M.; and Kerstens, M.N. (2019). Intricacies of the molecular machinery of catecholamine biosynthesis and secretion by chromaffin cells of the normal adrenal medulla and in pheochromocytoma and paraganglioma. *Cancers (Basel)*, 6; 11(8):1121. doi: 10.3390/cancers11081121. PMID: 31390824; PMCID: PMC6721535.
- Beutler, E.; Duron, O.; and Kelly, B. M. (1963). Improved method for the determination of blood glutathione. *The journal of laboratory and clinical medicine*, 61, 882–888.
- Bílek, R.; Vlček, P.; Šafařík, L.; Michalský, D.; Novák, K.; Dušková, J.; Václavíková, E.; Widimský, J.; Jr.; and Zelinka, T. (2019). Chromogranin A in the laboratory

- diagnosis of pheochromocytoma and paraganglioma. *Cancers (Basel)*, 25;11(4):586. doi: 10.3390/cancers11040586.
- Bo-Htay, C.; Palee, S.; Apaijai, N.; Chattipakorn, S. C.; and Chattipakorn, N. (2018). Effects of D-galactose-induced ageing on the heart and its potential interventions. *Journal of cellular and molecular medicine*, 22(3), 1392–1410. <https://doi.org/10.1111/jcmm.13472>
- Bourdeau, I.; El Ghorayeb, N.; Gagnon, N.; and Lacroix, A. (2018). Management of endocrine disease: Differential diagnosis, investigation and therapy of bilateral adrenal incidentalomas. *European journal of endocrinology*, 179(2), R57–R67. <https://doi.org/10.1530/EJE-18-0296>
- Budni, J.; Pacheco, R.; Da Silva, S.; Garcez, M. L.; Mina, F.; Bellettini-Santos, T.; de Medeiros, J.; Voss, B. C.; Steckert, A. V.; Valvassori, S.daS.; and Quevedo, J. (2016). Oral administration of d-galactose induces cognitive impairments and oxidative damage in rats. *Behavioural brain research*, 302, 35–43. <https://doi.org/10.1016/j.bbr.2015.12.041>
- Chattopadhyay, S.; Raychaudhuri, U.; and Chakraborty, R. (2014). Artificial sweeteners - a review. *Journal of food science and technology*, 51(4), 611–621. <https://doi.org/10.1007/s13197-011-0571-1>
- Chen, P.; Chen, F.; and Zhou, B. (2018). Antioxidative, anti-inflammatory and anti-apoptotic effects of ellagic acid in liver and brain of rats treated by D-galactose. *Scientific reports*, 8(1), 1465. <https://doi.org/10.1038/s41598-018-19732-0>
- Choi, M.R.; Kouyoumdzian, N.M.; Rukavina Mikusic, N.L.; Kravetz, M.C.; Rosón, M.I.; Rodríguez Fermepin, M.; and Fernández, B.E.(2015). Renal dopaminergic system: Pathophysiological implications and clinical perspectives. *World journal of nephrology*, 6;4(2):196-212. <https://doi.org/10.5527/wjn.v4.i2.196>.
- Chukwuma, C. I.; and Islam, S. (2017). Xylitol improves anti-oxidative defense system in serum, liver, heart, kidney and pancreas of normal and type 2 diabetes model of rats. *Acta poloniae pharmaceutica*, 74(3), 817–826.
- Čižmáriková, M.; Michalková, R.; Mirossay, L.; Mojžišová, G.; Zígová, M.; Bardelčíková, A.; and Mojžiš, J.(2023). Ellagic acid and cancer hallmarks: insights from experimental evidence. *Biomolecules*, 15;13(11):1653.<https://doi.org/10.3390/biom13111653>.
- Draper, H. H.; and Hadley, M. (1990). Malondialdehyde determination as index of lipid peroxidation. *Methods in enzymology*, 186, 421–431. [https://doi.org/10.1016/0076-6879\(90\)86135-i](https://doi.org/10.1016/0076-6879(90)86135-i).
- Ellwood, K. C. ; Bhatena, S. J. ; Johannessen, J. N. ; Bryant, M. A. and O'Donnell, M. W. (1999).Biomarkers used to assess the effect of dietary xylitol or sorbitol in the rat.*Nutrition research*, 19(11):1637–1648. [https://doi.org/10.1016/S0271-5317\(99\)00119-0](https://doi.org/10.1016/S0271-5317(99)00119-0).
- Gbinigie, O. A.; Onakpoya, I. J.; and Spencer, E. A. (2017). Evidence for the effectiveness of pomegranate supplementation for blood pressure management is weak: A systematic review of randomized clinical trials. *Nutrition research (New York, N.Y.)*, 46, 38–48. <https://doi.org/10.1016/j.nutres.2017.07.007>
- Gindler, E. M.; and King, J. D. (1972).Rapid colorimetric determination of calcium in biologic fluids with methylthymol blue,” *American journal of clinical pathology*, 58(4):376–382. <https://doi.org/10.1093/AJCP/58.5.376>.
- Greim, H.; Hartwig, A.; Reuter, U.; Richter-Reichhelm, H. B. ; and Thielmann, H. W. (2009).Chemically induced pheochromocytomas in rats: mechanisms and relevance for human risk assessment. *Critical reviews in toxicology*, 39(8):695–718. <https://doi.org/10.1080/10408440903190861>.

- Guo, R.; and Li, G. (2018). Tanshinone modulates the expression of Bcl-2 and Bax in cardiomyocytes and has a protective effect in a rat model of myocardial ischemia-reperfusion. *Hellenic journal of cardiology*, 59(6):323–328. <https://doi.org/10.1016/J.HJC.2017.11.011>.
- Gupta, A.; Singh, A. K. ; Kumar, R. ; Jamieson, S. ; Pandey, A. K. ; and Bishayee, A. (2021). Neuroprotective potential of ellagic acid: a critical review. *Advances in Nutrition*, 12(4). Oxford University Press:1211–1238 <https://doi.org/10.1093/advances/nmab007>.
- Gupta, P.K.; and Marwaha, B.(2023). Pheochromocytoma. Treasure Island (FL): StatPearls Publishing;. <https://www.ncbi.nlm.nih.gov/books/NBK589700/>
- Haider, S.; Liaquat, L.; Shahzad, S.; Sadir, S.; Madiha, S.; Batool, Z.; Tabassum, S.; Saleem, S.; Naqvi, F.; and Perveen, T. (2015). A high dose of short term exogenous D-galactose administration in young male rats produces symptoms simulating the natural aging process. *Life sciences*, 124, 110–119. <https://doi.org/10.1016/j.lfs.2015.01.016>.
- Hoseinynejad, K.; Mard, A.; and Dianat, M. (2021) .An Overview on antioxidant and anti-inflammatory properties of ellagic acid in renal dysfunction. *Undishapur journal of physiology*, 2 (1): 16-21.
- Hudson, B. I.; and Lippman, M. E. (2018) Targeting RAGE signaling in inflammatory disease. *Annual review of medicine*, 69: 349–364. <https://doi.org/10.1146/annurev-med-041316-085215>
- Iizuka K.(2023). Recent progress on fructose metabolism-chrebp, fructolysis, and polyol pathway. *Nutrients*, 5;15(7):1778. <https://doi.org/10.3390/nu15071778>.
- Latona, D. F.; and Akinola, A. E. (2020). Substrate inhibition: oxidation of D-sorbitol and D-dulcitol by mn(vii) in alkaline medium. *Journal of chemistry and biochemistry*, 8(1):1:8, <https://doi.org/10.15640/jcb.v8n1a2>.
- Lelou, E.; Corlu, A.; Nessler, N.; Rauch, C.; Mallédant, Y.; Seguin, P.; and Aninat, C. (2022). The role of catecholamines in pathophysiological liver processes. *Cells*, 11(6), 1021. <https://doi.org/10.3390/cells11061021>
- Lenders, J. W. M.; and Eisenhofer, J. W. M. G. (2017). Update on modern management of pheochromocytoma and paraganglioma. *Endocrinology and metabolism*, 32(2), 152–161. <https://doi.org/10.3803/ENM.2017.32.2.152>.
- Lenders, J. W. M.; Kerstens, M. N.; Amar, L.; Prejbisz, A.; Robledo, M.; Taieb, D.; Pacak, K.; Crona, J.; Zelinka, T.; Mannelli, M.; Deutschbein, T.; Timmers, H. J. L. M.; Castinetti, F.; Dralle, H.; Widimský, J.; Gimenez-Roqueplo, A. P.; and Eisenhofer, G. (2020). Genetics, diagnosis, management and future directions of research of phaeochromocytoma and paraganglioma: a position statement and consensus of the Working Group on Endocrine Hypertension of the European Society of Hypertension. *journal of hypertension*, 38(8), 1443–1456. <https://doi.org/10.1097/HJH.0000000000002438>
- Levesque, R. (2007): SPSS programming and data management: A Guide for SPSS and SAS user.3rd Edition, United States of America.
- Li, H.; Zheng, L.; Chen, C.; Liu, X.; and Zhang, W. (2019). Brain senescence caused by elevated levels of reactive metabolite methylglyoxal on d-galactose-induced aging mice. *Frontiers in neuroscience*, 13: 1004. <https://doi.org/10.3389/fnins.2019.01004>
- Li, X.; Wang, L.; Li, C, et al(2023). Phillyrin ameliorates oxidative stress in d-galactose-induced senescence in the brain of mice by regulating the Nrf2/ HO-1 signaling pathway. *Natural Product Communications*, 18(5). doi:10.1177/1934578X231173237

- Li, Y. J.; Han, Z.; Ge, L.; Zhou, C. J.; Zhao, Y. F.; Wang, D. H.; Ren, J.; Niu, X. X.; and Liang, C. G. (2016). C-phycoerythrin protects against low fertility by inhibiting reactive oxygen species in aging mice. *Oncotarget*, 7(14), 17393–17409. <https://doi.org/10.18632/oncotarget.8165>
- Liu, B.; Xie, Y.; Chen, J.; Xue, J.; Zhang, X.; Zhao, M.; Jia, X.; Wang, Y.; and Qin, S. (2021). Protective effect of molecular hydrogen following different routes of administration on d-galactose-induced aging mice. *Journal of inflammation research*, 14:5541–5550. <https://doi.org/10.2147/JIR.S332286>
- Liu, Q.; Liang, X.; Liang, M.; Qin, R.; Qin, F.; and Wang, X. (2020). Ellagic acid ameliorates renal ischemic-reperfusion injury through NOX4/JAK/STAT signaling pathway. *Inflammation*, 43(1):298–309. <https://doi.org/10.1007/S10753-019-01120-Z>.
- Liu, Y.; He, X.; Ma, P.; Huang, Y.; Li, X.; Sun, Y.; Wang, X.; and Song, D. (2020). Fluorometric detection of dopamine based on 3-aminophenylboronic acid-functionalized AgInZnS QDs and cells imaging. *Talanta*, 217: 121081 <https://doi.org/10.1016/J.TALANTA.2020.121081>.
- Liu, Y.; Wang, Y.; Zhou, M.; Zhang, L.; Pang, Y.; Wang, C.; Xiao, Q.; and Liu, L. (2020). Metabolism and secretion mechanisms of catecholamine syndrome and related treatment strategies. *Journal of xiangya medicine*, 5:39 <http://dx.doi.org/10.21037/>
- Lynch, B.S.; Tischler, A.S.; Capen, C.; Munro, I.C.; McGirr, L.M. and McClain, R.M. (1996) Low digestible carbohydrates (polyols and lactose): significance of adrenal medullary proliferative lesions in the rat. *Regulatory toxicology and pharmacology*, 23(3):256-297. <https://doi.org/10.1006/rtph.1996.0055>. (<https://www.sciencedirect.com/science/article/pii/S0273230096900550>).
- Mariappan, A.; Ganapathy, G.; and Banumathi, V. (2016): Anti-urolithiatic evaluation of siddha formulation seenakara parpam against zinc disc implantation induced urolithiasis in wistar albino rats. *International journal of advanced research in biological science*, 2016; 3(12):7-13.
- Marín, M.; María Giner, R.; Ríos, J. L.; and Recio, M. C. (2013). Intestinal anti-inflammatory activity of ellagic acid in the acute and chronic dextrane sulfate sodium models of mice colitis. *Journal of ethnopharmacology*, 150(3), 925–934. <https://doi.org/10.1016/j.jep.2013.09.030>
- Micheli, L.; Bertini, L.; Bonato, A.; Villanova, N.; Caruso, C.; Caruso, M.; Bernini, R.; and Tirone, F. (2023) Role of hydroxytyrosol and oleuropein in the prevention of aging and related disorders: focus on neurodegeneration, skeletal muscle dysfunction and gut microbiota. *Nutrients*, 15: 1767. <https://doi.org/10.3390/nu15071767>
- Mir, S.A.; Biswas, N.; Cheung, W.; Wan, J.; Webster, N.; Macedo, E.; O'Connor, D.T.; Vaingankar, S.M. (2020). Chromogranin A pathway: from pathogenic molecule to renal disease. *Journal of hypertension*, 38(3):456-466. <https://doi.org/10.1097/HJH.0000000000002295>.
- Mohamed, D. A.; Mohammed S. E.; El-Sayed H. S.; Mabrok H. B.; and Mohamed, R. S. (2022) .Ameliorative effect of probiotic-fermented milk and costus extract in alzheimer's disease model induced by D-galactose and aluminum chloride," *Egyptian journal of chemistry*, 65(4): 411–421. <https://doi.org/10.21608/EJCHEM.2021.98261.4577>.
- Mohammed, M.; Moawed, F.; Abo Zaid, O.; and Elshewyi, O. (2021). Neuromodulatory influences of vitamin C on D-galactose induced neuronal metabolic dysfunction model ; *Benha veterinary medical journal*, 40 (2021) 80-83 <https://doi.org/10.21608/BVMJ.2021.67215.1360>.

- Mohr, H.; Foscarini, A.; Steiger, K.; Ballke, S.; Rischpler, C.; Schilling, F.; and Pellegata, N. S. (2021). Imaging pheochromocytoma in small animals: preclinical models to improve diagnosis and treatment. *European journal of nuclear medicine and molecular imaging research*, 11(1), 121. <https://doi.org/10.1186/s13550-021-00855-x>
- Moustaki, M.; Paschou, S. A.; Vakali, E.; Xekouki, P.; Ntali, G.; Kassi, E.; Peppas, M.; Psaltopoulou, T.; Tzanela, M.; and Vryonidou, A. (2023). Secondary diabetes mellitus in pheochromocytomas and paragangliomas. *Endocrine*, 82(3), 467–479. <https://doi.org/10.1007/s12020-023-03492-7>
- Mula-Abed, W.A.; Ahmed, R.; Ramadhan, F.A.; Al-Kindi, M.K.; Al-Busaidi, N.B.; Al-Muslahi, H.N.; and Al-Lamki, M.A. (2015). A Rare case of adrenal pheochromocytoma with unusual clinical and biochemical presentation: A case report and literature review. *Oman medical journal*, 30(5):382-90. <https://doi.org/10.5001/omj.2015.76>.
- Naghbi, N.; Sadeghi, A.; Movahedinia, S.; Rahimi Naiini, M.; Rajizadeh, M. A.; Bahri, F. and Nazari-Robati, M. (2023). Ellagic acid ameliorates aging-induced renal oxidative damage through upregulating SIRT1 and NRF2. *BMC complementary medicine and therapies*, 23(1), 77. <https://doi.org/10.1186/s12906-023-03907-y>
- Naraki, K.; Ghasemzadeh Rahbardar M.; Ajiboye, B.O.; and Hosseinzadeh, H. (2023). The effect of ellagic acid on the metabolic syndrome: A review article. *Heliyon*, 31;9(11):e21844. <https://doi.org/10.1016/j.heliyon.2023.101611>.
- National Research Council. Nutrient Requirements of Laboratory Animals. 4th ed. Washington, DC: National Academy Press; 1995.
- Nishikimi, M.; Appaji, N.; and Yagi, K. (1972). The occurrence of superoxide anion in the reaction of reduced phenazine methosulfate and molecular oxygen. *Biochemical and biophysical research communications*, 46(2), 849–854. [https://doi.org/10.1016/s0006-291x\(72\)80218-3](https://doi.org/10.1016/s0006-291x(72)80218-3)
- Pacak, K.; and Tella, S.H. (2018). Pheochromocytoma and Paraganglioma. In: Feingold KR, Anawalt B, Blackman MR, et al., editors. Endotext [Internet]. South Dartmouth (MA): MDText.com, Inc.; 2000-. doi: <https://www.ncbi.nlm.nih.gov/books/NBK481899>.
- Reitman, A.; and Frankel, S. (1957): A colorimetric method for the determination of serum glutamic oxaloacetic and glutamic pyruvic transaminases. *American journal of clinical pathology*, 28(1): 56–63. <https://doi.org/10.1093/ajcp/28.1.56>.
- Sharifi-Rad, J.; Quispe, C.; Castillo, C. M. S.; Caroca, R.; Lazo-Vélez, M. A.; Antonyak, H.; Polishchuk, A.; Lysiuk, R.; Oliinyk, P.; De Masi, L.; Bontempo, P.; Martorell, M.; Daştan, S. D.; Rigano, D.; Wink, M. and Cho, W. C. (2022). Ellagic acid: A review on its natural sources, chemical stability, and therapeutic potential. *Oxidative medicine and cellular longevity*, 2022: 3848084. <https://doi.org/10.1155/2022/3848084>.
- Sonaje, K. ; Italia, J. L.; Sharma, G.; Bhardwaj, V.; Tikoo, K.; and Kumar, M. N. V. R. (2007). Development of biodegradable nanoparticles for oral delivery of ellagic acid and evaluation of their antioxidant efficacy against cyclosporine A-induced nephrotoxicity in rats. *Pharmaceutical research*, 24(5):899–908. <https://doi.org/10.1007/S11095-006-9207-Y>.
- Tappy, L.; and Lê, K. A. (2010). Metabolic effects of fructose and the worldwide increase in obesity. *Physiological reviews*, 90(1):23–46. <https://doi.org/10.1152/physrev.00019.2009>
- Tischler A. S.; Powers, J. F.; Pignatello, M.; Tsokas, P., Downing, J. C.; and McClain R. M. (1999). Vitamin D3-induced proliferative lesions in the rat adrenal medulla. *Toxicological sciences*. 51(1):9–18. <https://doi.org/10.1093/TOXSCI/51.1.9>.

- Tischler A. S.; Sheldon, W.; and Gray, R.(1996).Immunohistochemical and morphological characterization of spontaneously occurring pheochromocytomas in the aging mouse. *Veterinary Pathology*, 33(5):512–520. <https://doi.org/10.1177/030098589603300505>.
- Tischler, A. S.; Powers, J. F.; Downing, J. C.; Riseberg, J. C.; Shahsavari, M.; Ziar, J.; and McClain, R. M. (1996). Vitamin D3, lactose, and xylitol stimulate chromaffin cell proliferation in the rat adrenal medulla. *Toxicology and applied pharmacology*, 140(1):115–123. <https://doi.org/10.1006/taap.1996.0204>.
- Trinder, P. (1969).Determination of glucose in blood using glucose oxidase with an alternative oxygen acceptor. *Annals of clinical biochemistry: International journal of laboratory medicine*, 6(1):24–27, <https://doi.org/10.1177/000456326900600108>.
- Ullah, F.; Ali, T.; Ullah, N.; and Kim, M. O. (2015). Caffeine prevents D-galactose-induced cognitive deficits, oxidative stress, neuroinflammation and neurodegeneration in the adult rat brain. *Neurochemistry international*, 90: 114–124. <https://doi.org/10.1016/J.NEUINT.2015.07.001>.
- Wang, W.; Wang, S.; Liu, Y.; Wang, X.; Nie, J.; Meng, X.; and Zhang, Y. (2022) Ellagic acid: A dietary-derived phenolic compound for drug discovery in mild cognitive impairment. *Frontiers aging neurosciences*, 14:925855. <https://doi.org/10.3389/fnagi.2022.925855>
- Wang, Y.; Qiu, Z.; Zhou, B.; Liu, C.; Ruan, J.; Yan, Q.;Liao, J.; and Zhu, F. (2015). *In vitro* antiproliferative and antioxidant effects of urolithin A, the colonic metabolite of ellagic acid, on hepatocellular carcinomas HepG2 cells. *Toxicology in vitro*, 29(5), 1107–1115. <https://doi.org/10.1016/j.tiv.2015.04.008>
- WHO(2023).349. Sorbitol (WHO Food Additives Series 5).” Accessed: Oct. 20, 2023. [Online]. Available: <https://inchem.org/documents/jecfa/jecmono/v05je91.htm>
- Zhong, L.; Liu, H.; Zhang, W.; Liu, X.; Jiang, B.; Fei, H.; and Sun, Z. (2018). Ellagic acid ameliorates learning and memory impairment in APP/PS1 transgenic mice via inhibition of β -amyloid production and tau hyperphosphorylation. *Experimental and therapeutic medicine*, 16: 4951-4958. <https://doi.org/10.3892/etm.2018.6860>
- Zhu, H.; Yan, Y.; Jiang, Y. and Meng, X. (2022). Ellagic Acid and its anti-aging effects on central nervous system. *International journal of molecular sciences*, 23(18): 10937. <https://doi.org/10.3390/ijms231810937>.
- Zuber, S.M.; Kantorovich, V.; and Pacak, K.(2011).Hypertension in pheochromocytoma: characteristics and treatment. *Endocrinology and metabolism clinics*,40(2):295-311.<https://doi.org/10.1016/j.ecl.2011.02.002>.