

## EVALUATION OF COLLAGEN VERSUS PLATELET RICH FIBRIN MEMBRANE ON THE OSTEOGENIC POTENTIAL OF BONE MARROW ASPIRATE CONCENTRATE FOR LATERAL SINUS FLOOR AUGMENTATION: A RANDOMIZED CLINICAL TRIAL

Walaa Kadry \* , Walaa Abd El Aty Ahmed \*\*  and Eman Said \* 

### ABSTRACT

**Aim:** The purpose of the current study was to radiographically evaluate the effect of platelet rich fibrin (a source of growth factors) versus collagen on the osteogenic potential of bone marrow aspirate concentrate loaded on bovine graft in sinus floor augmentation.

**Patients & methods:** Lateral sinus floor augmentation was performed for twelve eligible patients utilizing bovine bone graft loaded with bone marrow aspirate concentrate. The lateral osteotomy window was covered with platelet rich fibrin membrane in the study group (6 sinuses) in comparison to collagen membrane for the control group (6 sinuses). The newly formed bone height and density were measured immediate (one week) and at four months follow up period on CBCT.

**Results:** The mean age of the patients in the study group was (46.83±5.64) years and in the control group it was (44.03±7.60) years. The control group had significantly higher density than the study group (p<0.05). However, there was no significant difference between the tested groups regarding bone height (p=0.205).

**Conclusions:** Collagen membrane utilization has yielded higher bone density compared to the PRF membrane in sinus floor augmentation. No significant difference among the studied groups was observed in the bone height.

**Trial registration:** ClinicalTrials.gov Identifier: NCT05985317.

**KEYWORDS:** Collagen membrane, bone marrow aspirate, bone density, platelet rich fibrin

\* Lecturer of Oral and Maxillofacial Surgery, Faculty of Dentistry, Cairo University, Cairo, Egypt.

\*\* Lecturer of Oral and Maxillofacial Radiology, Faculty of Dentistry, Cairo University, Cairo, Egypt.

## INTRODUCTION

Maxillary sinus augmentation surgery is considered a common pre-prosthetic surgery for rehabilitation of the posterior maxilla which has got atrophied from loss of alveolar bone height and sinus pneumatization <sup>[1]</sup>.

Autologous bone graft is the gold standard material for grafting since it has osteogenic, osteoconductive and osteo-inductive properties. However, it has the disadvantages of limitation of the amount of bone, need for another surgery, complications of the donor site and more surgical time <sup>[2]</sup>.

To overcome these drawbacks, alternative bone substitutes have been utilized for sinus floor augmentation. The most widely used bone substitute is the xenograft material with a reported long term success rate through literature <sup>(3,4)</sup>

However, xenograft provides only the osteoconductive property. Therefore, many authors have investigated the effect of addition of several biomaterials such as bone marrow aspirate concentrate (BMAC), leucocyte and platelet-rich fibrin (PRF), bone morphogenetic protein-2, or enamel matrix for graft enhancement on the improvement of the percentage of the newly-formed bone. <sup>[5-7]</sup>.

BMAC is one of the sources of mesenchymal stem cells (MSCs). The latter has the potential to differentiate into different tissues lineages, including bone tissue <sup>[8]</sup>.

BMAC has been utilized in combination with xenograft to add to the graft' osteoconductive property, osteo-inductive and osteogenic potentials for enhancement of new bone formation in maxillary sinus augmentation <sup>[9-11]</sup>.

PRF is a fibrin matrix that comprises platelets and leukocytes which act as a reservoir with sustained release of different growth factors and cytokines including transforming growth factor-beta1 (TGF- $\beta$ 1), platelet-derived growth factor

(PDGF), vascular endothelial growth factor (VEGF) and interleukins (IL-1 $\beta$ , IL-4 & IL-6) <sup>[12]</sup>.

Studies show that PRF has the ability to stimulate the osteogenic differentiation of the undifferentiated MSCs isolated from different tissue sources <sup>[13,14]</sup>. PRF has the ability to stimulate cell proliferation, migration and osteogenic differentiation of MSCs isolated from Schneiderian membrane of the rabbit's maxillary sinus <sup>[14]</sup>. Moreover, PRF has shown to improve the mineralization when combined with BMA. <sup>(15)</sup>.

Collagen membrane is an absorbable natural polymeric membrane that has been used extensively during the procedure of sinus augmentation due to its bioactivity and biocompatibility <sup>[16]</sup>. It has the advantage of lower exposure rate than non-absorbable membranes, Hence, the aim of the current study was to compare the effect of PRF membrane as a growth factor reservoir versus collagen membrane on the osteogenic potential of BMAC that's loaded on xenograft, in terms of changes of bone density and height on cone beam CT (CBCT).

## PATIENTS AND METHODS

The current randomized parallel controlled trial was approved by the ethical committee of the faculty of dentistry, Cairo University that follows the declarations of Helsinki regulations. Highly motivated patients with residual alveolar bone height ranging from 4 to 6 mm of posterior maxilla were included to the current study. Patients were excluded if: 1. They suffer from any systemic disease or under any medication that may interfere with normal bone healing, 2. They have any sinus pathosis, 3. They have conditions that could potentially compromise BM quality, including history of hematologic malignancy, current chemotherapy, BM suppressive or anti-platelet medications, previous BMA, or acute illness. 4. They're Heavy smoker (> 20 cigarettes daily). Eligible patients were selected from the outpatient clinic of the oral and maxillofacial surgery

department, faculty of dentistry, Cairo university, Egypt and asked to sign informed consent after explaining the surgical procedure to them.

### **Patient allocation**

The sample size was calculated according to the answer of the following research question, would utilization of PRF with BMAC/bovine graft provide greater bone height and density compared to the collagen with BMAC/bovine graft, that would be interpreted in a clinical success of future implant placement. There was no precise answer regarding exact methodology in the literature on this topic; however, it is believed that an increased amount of new bone formation is crucial for implant success.

Twelve eligible patients were enrolled to the current study with 1:1 allocation ratio. Sinus membrane elevation (SME) and augmentation with BMAC loaded on bovine graft was performed and the osteotomy window was covered with PRF membrane for the study group and collagen membrane for the control group.

Preoperative panoramic radiograph was ordered for all patients for initial screening and to exclude the presence of any local pathosis. CBCT was later requested to assess the preoperative remaining alveolar bone height. Preoperative laboratory investigations (complete blood count, coagulation profile) were requested also to exclude any bone marrow disorder.

### **Bone Marrow Aspirate Harvesting technique**

For all patients, BM was aspirated under local anesthesia while the patient was sitting in the supine position to gain access to the anterior superior iliac spine. Scrubbing and draping of the BM aspiration site was carried out under the standard sterile conditions. Following attaining the proper angulation, the aspiration needle was advanced to the periosteum. A clockwise-counterclockwise back and forth turning motion was performed while maintaining a gentle

forward pressure through the bone trabeculae till reaching the bone marrow cavity. The stylet was then removed and a 20 cm pre-heparinized syringe was attached to the aspiration needle. An average of 20 ml BMA was concentrated through centrifugation and then loaded on bovine graft Tutobone (Tutogen Medical GmbH, Neunkirchen a. Brand, Germany) to be ready for sinus floor augmentation (SFA).

### **PRF membrane preparation**

A blood sample (10cc) was obtained from the patients of the study group. The sample was then centrifuged at 3000 rpm for 15 minutes. The middle of the three resultant layers (PRF) was then compressed to form membrane.

### **Sinus floor augmentation**

A prophylactic antibiotic (Clindamycin 300 mg) and analgesic (Ibuprofen 400 mg) capsule were prescribed on the preoperative day and one hour Preoperatively. Under local anesthesia (Articaine 4% with epinephrine 1:100,000), a mid-crestal incision with mesial vertical releasing incision was performed. A full thickness mucoperiosteal flap was elevated to access the lateral wall of the maxillary sinus. A round diamond bur was used to delineate the lateral Maxillary wall under copious saline irrigation. The lateral wall and sinus membrane was then elevated. BMAC loaded on deproteinized bone graft material was used for sinus augmentation (Fig 1) and the graft was then covered with: PRF membrane for the study group and collagen membrane for the control group. (Fig 2) The flap was then repositioned over the membrane and sutured.

Patients were encouraged to follow strict oral hygiene measures and continue the preoperative antibiotics and analgesics every eight hours per day for 5 days. Nasal decongestant oxymetazoline hydrochloride 50% (Afrin, MUP, city, Egypt) nasal drops were prescribed also. An antibiotic ointment was prescribed for the BMA site.

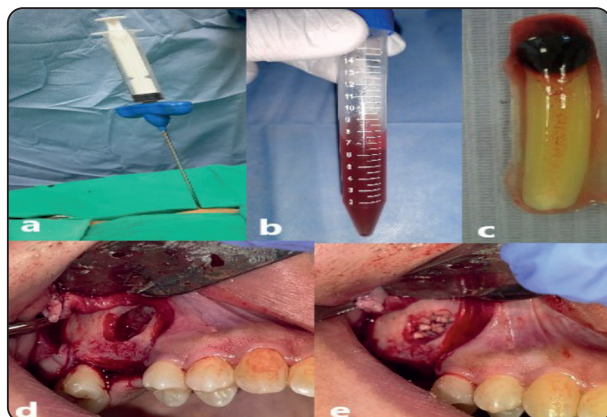


Fig. (1) Clinical intraoperative photograph showing: a) Bone marrow aspiration from the anterior iliac crest, b) The BMA following centrifugation, c) PRF membrane, d) Lateral anrostomy window before grafting & e) SFA using xenograft mixed with BMAC.

### Data analysis & Randomization

A computer software was utilized to generate random numbers. The numbers were encased in sealed envelopes. Simple randomization was then performed to enroll the patients to the assigned group via envelope selection. Radiographic outcome assessor was blinded regarding the assigned group.

### Radiographic assessment

A postoperative CBCT scan (90 KV, 6.3 mA, exposure period of 12 s, voxel size 0.2mm) of maxilla was ordered for each patient immediate and 4 months postoperative. The dicom files were then imported in mimics software (version 21, Materialize, Leuven, Belgium) for image reconstruction.

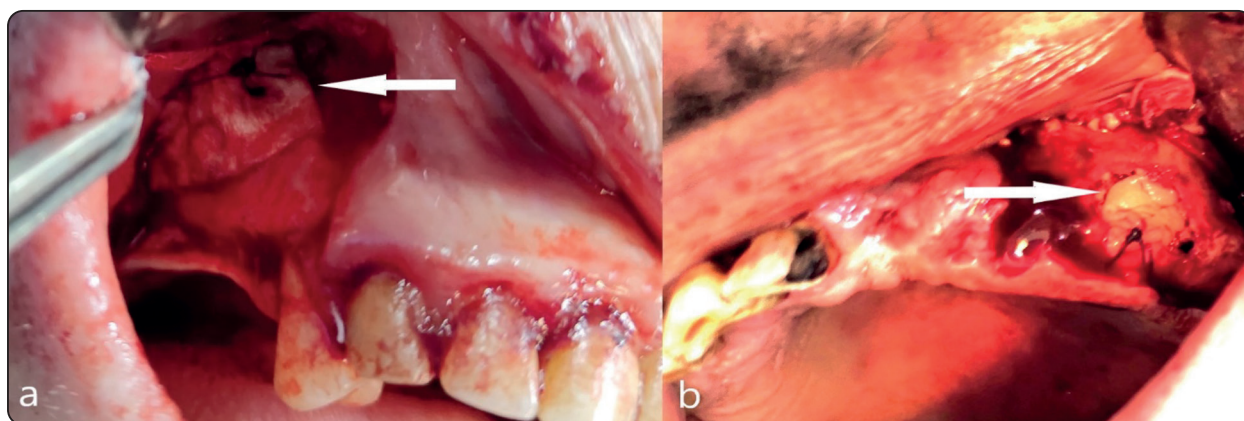


Fig. (2) Clinical intraoperative photograph showing the lateral anrostomy window which is covered with: a) The collagen membrane in the control group (arrow), b) PRF membrane in the study group (arrow).

### Study variables (Measurement of bone height & density)

Patients were recalled immediate (one week) postoperatively, weekly for the first month then monthly for additional 3 months. Assessment included bone density and height at the grafted sinus for both groups immediate and 4 months postoperative. For density measurements, on the Coronal cuts, graft density was measured randomly at three different sites and the average of all readings was included in the statistical analysis. (Fig 3)

Regarding the graft height, it was measured on the coronal cuts from the alveolar bone to the sinus floor at different sites and the average of all readings was included in the statistical analysis (Fig 4). All measurements were assessed by the same examiner (W.A) at two different times to remove the inter-observer error.

### Statistical analysis

Categorical data were presented as frequency and percentage values and were analyzed using

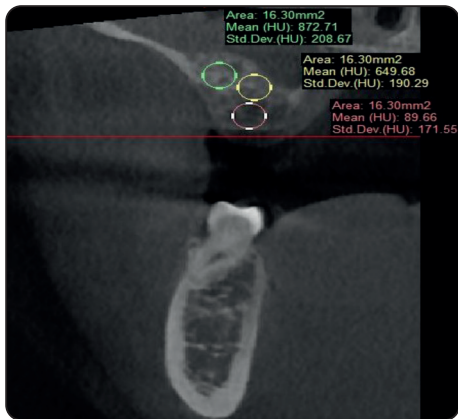


Fig. (3) Coronal cut of CBCT showing the density measurements at the grafted maxillary sinus floor immediate postoperative

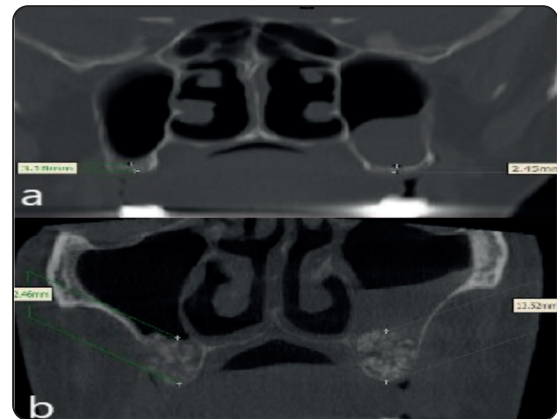


Fig. (4) Coronal cut of CBCT showing residual ridge height assessment: a) Preoperative, b) Postoperative following grafting.

chi-square test. Numerical data were presented as mean and standard deviation values. They were analyzed for normality using Shapiro-Wilk’s test. Parametric data were analyzed using independent t-test for intergroup comparisons and paired t-test for intragroup comparisons. Non-parametric data were analyzed using Mann-Whitney U test for intergroup comparisons and signed rank test for intragroup comparisons. The significance level was set at  $p < 0.05$  within all tests. Statistical analysis was performed with R statistical analysis software version 4.3.1 for Windows.

**RESULTS**

The study was conducted on 12 patients that were randomly and equally allocated to each of the studied groups (i.e., 6 patients each). There were

a single male and five females in the study group, while in the control group there were 3 males and females. The mean age of the cases in the study group was  $(46.83 \pm 5.64)$  years and in the control group it was  $(44.03 \pm 7.60)$  years. There was no significant difference between tested groups regarding gender ( $p = 0.221$ ), age ( $p = 0.480$ ). Demographic data are presented in **table (1)**.

**Clinical results**

Soft tissue healing went uneventful in all cases till the end of follow up period except for one case of the control group. Soft tissue dehiscence, infection and pus were encountered in such case. This coincided with the radiographic evidence of graft dispersion through the sinus. Patients were assessed also for BMA site adverse effects with negative results.

TABLE (1) Intergroup comparisons and summary statistics of demographic data

Parameter		Study	Control	Test statistic	p-value
Gender [n(%)]	Male	1 (16.7%)	3 (50.0%)	1.50	0.221
	Female	5 (83.3%)	3 (50.0%)		
Age (Mean±SD) (years)		46.83±5.64	44.03±7.60	0.73	0.480
Pre-operative bone height (Mean±SD) (mm)		4.00±1.17	4.78±0.77	1.36	0.205

### Radiographic results

The mean pre-operative bone height of the cases in the study group was (4.00±1.17) mm and in the control group it was (4.78±0.77) mm. There was no significant difference between tested groups regarding pre-operative bone height (p=0.205). (**Table 1**)

Results of inter and intragroup comparisons of bone height are presented in **table (2)**, and showed that within both intervals, there was no significant

difference between both groups (p>0.05), and within both groups, there was no significant difference between values that was measured at both intervals (p>0.05).

Regarding bone density, the inter and intragroup comparisons showed that within all intervals, control group had significantly higher density than the study group (p<0.05). For the study group, there was no significant difference between values measured immediately post-operative and after 4 months for bone graft (p=0.251). (**Table 3**)

TABLE (2) Inter and intragroup comparisons of bone height (mm)

Interval	Bone height (mm)		t-value	p-value
	Study	Control		
Immediately after	12.02±3.71	13.16±1.81	0.67	0.517ns
After 4 months	10.01±2.43	12.66±1.97	2.08	0.064ns
t-value	1.04	2.07		
p-value	0.346	0.093		

TABLE (3) Inter and intragroup comparisons of bone density (HU)

Interval	Bone density (HU)		t-value	p-value
	Study	Control		
Immediately after	211.16±24.93	484.22±69.50	9.06	<0.001*
After 4 months (graft)	228.06±18.79	529.36±74.40	9.62	<0.001*
t-value	-1.30	-8.65		
p-value	0.251	<0.001*		

(\* = significant when <0.05)

## DISCUSSION

Various grafting materials have been utilized for sinus augmentation procedure to rehabilitate the atrophic posterior maxilla. Lack of the osteogenic potential of all the commercially available autograft alternatives, encouraged the researchers to utilize BMAC on bovine graft for sinus floor augmentation in the present study. Few studies have utilized this graft combination for sinus floor augmentation<sup>[9,10,17-19]</sup>.

However, none of the forementioned studies investigated utilization of an additional factor that might contribute to the enhancement of the osteogenic potential of the BMAC. Such an external factor may accelerate the remodeling and mineralization of the grafting material. In the present study, authors investigate the effect of utilization of PRF membrane as a growth factor reservoir on the osteogenic potential of the BMAC in comparison to collagen membrane for covering the lateral osteotomy window.

The forementioned studies assessed the resultant bone quality only via a histomorphometric analysis of a core biopsy before implant placement. No radiographic outcome was assessed. Moreover, none of those studies has utilized PRF with BMAC. Hence, this point is still open to research. Therefore, in the current study, the newly formed bone quality and quantity were assessed via measurement of the newly formed bone density and height respectively.

Moreover, utilization of one of the different types of the available barrier membranes is necessary for guided bone regeneration to prevent the rapid ingrowth of unwanted type of cells and allow only the bone forming cells to grow in the bony defect<sup>[20]</sup>.

Regarding membrane quality, a recent study has investigated the barrier function against bacterial invasion through comparing PRF to different commercially available collagen membranes. PRF

revealed less Staph aureus bacterial penetration, non-significant membrane degradation and better wound healing compared to two different collagen membranes<sup>[21]</sup>.

Regarding combination of PRF with bovine graft, different studies showed non-significant advantages for sinus lift procedure outcomes. The only documented advantage was for soft tissue healing enhancement<sup>[22, 23]</sup>.

Another study has compared PRF added bovine graft to bovine graft only. The percentage of new bone formation was higher in the PRF group while percentage of graft remnants was higher in the graft group with no significant difference.<sup>[24]</sup> A recent review concluded that there was no statistically significant difference among bovine graft combined with PRF and bovine graft alone. A single occurrence of reduction of graft resorption was encountered in the PRF group<sup>[25]</sup>.

Furthermore, another study concluded that the addition of PRF to bovine bone has neither increase the amount of regenerated bone nor the integration of graft in the defect via histomorphometric analysis.<sup>[26]</sup>

**Bolukbasi N et al., 2015** has compared the effect of collagen versus PRF membrane for 32 sinus augmentation procedures with Bio-oss alone (without BMAC) and in terms of histological and histomorphometric core biopsy assessment<sup>[27]</sup>. There was no statistically significant difference between the two groups nor the remnants of the grafting material. Moreover, the radiographic height changes were significantly lower in the PRF group. This is in the contrary to the radiographic height results of the present study where there was no significant difference among groups. The density of the newly formed bone was not assessed. However, BMAC was not utilized in the forementioned study for SFA. Actually, such combination (PRF, BMAC and bovine graft) was not reported in literature for SFA to compare with the results of the current study.

The biological combination of BMAC and PRF was investigated only for its efficacy in nonunion fractures together with the traditional fixation methods compared to traditional fixation alone with superior results (clinical and radiographic) for the combination methods [28].

**Wang W et al., 2017** postulated that graft enhancement with proteins or growth factors increase the osteointegration of the graft and guarantee the long-term success [29]. Sinus floor augmentation, despite being a predictable procedure with commercially available autograft alternatives, the search for the ideal grafting material with least complications is still open [30].

Through literature, different variables have been used to assess the success of the SFA procedure. They include newly formed bone height [31, 32], volume [33,34], percentage by histomorphometric analysis of core biopsy [35, 36], density [37, 38] and implant survival rate [39,40]. In the current study, the newly formed bone density and height were the main indicators for increased osteogenic potential with the associated membrane.

At the 4 months follow up period, the newly formed bone density was significantly higher in the control group. Moreover, the graft density increased from baseline (immediate postoperative) to 4 months follow up. This might be attributed to insufficient time that has provided for the maturation of the bone graft period as documented by Kadry W. et al., 2021 [41]. Increasing the follow up period might contribute to changes in the density measurements among the studied groups. Time dependent increase in the graft density has been also reported in literature up to 2 years according to Gerhardt DMJM et al., 2018 [42].

On the other hand, changes in the bone density among the studied groups might be attributed to the membranes' mechanical properties. The difference in the degradation potential of the two membranes was investigated by **Sam G et al., 2015** who reported that PRF exhibits 36% degradation

of its initial weight by the end of the first week compared to 3 % degradation of bovine collagen membrane after the same period of time. [43] The faster degradation of PRF could have affected the sustained release of the resident growth factors with subsequent compromised membrane efficiency on the short-term.

To the best of our knowledge, no recent study compared the effect of the two membranes on the osteogenic potential of BMAC in terms of the yielded bone quality (density) and quantity (height) at 4 months of SFA. Decreased bone density of the study group is expected to increase on a time dependant manner or when subjected to loading of the implant [44]. However, bone height was comparable for both groups.

Within the limitations of the present study of relatively decreased follow up period and the absence of culture of stem cells for ethical concerns; the utilization of a triad of stem cell source, growth factors and appropriate scaffold seems promising, applicable to different age groups and both sexes and spares a second surgical site morbidity.

## CONCLUSION

Collagen membrane utilization has yielded higher bone density compared to the PRF membrane in sinus floor augmentation. No significant difference among the studied groups was observed in the bone height. Authors recommend further long-term clinical trials with further density assessment in SFA procedures.

## Abbreviations

BMAC: bone marrow aspirate concentrate; PRF: Platelet rich fibrin membrane; SFA: sinus floor augmentation; MSCs: mesenchymal stem cells; CBCT: cone beam CT; TGF- $\beta$ 1; transforming growth factor-beta1; PDGF: platelet-derived growth factor; VEGF: vascular endothelial growth factor; IL: interleukin.



## REFERENCES

1. Duong HY, Rocuzzo A, Stähli A, Salvi GE, Lang NP, Sculean A (2022) Oral health-related quality of life of patients rehabilitated with fixed and removable implant-supported dental prostheses. *Periodontol 2000*. 2022 Feb;88(1):201-237. doi: 10.1111/prd.12419.
2. Sakkas A, Wilde F, Heufelder M, Winter K, Schramm A (2017) Autogenous bone grafts in oral implantology-is it still a “gold standard”? A consecutive review of 279 patients with 456 clinical procedures. *Int J Implant Dent*. 3(1):23. doi: 10.1186/s40729-017-0084-4.
3. Alfonsi F, Borgia V, Iezzi G, Piattelli A, Covani U, Tonelli P, Barone A (2017) Molecular, Cellular and Pharmaceutical Aspects of Filling Biomaterials During the Management of Extraction Sockets. *Curr Pharm Biotechnol*. 18(1):64-75. doi: 10.2174/1389201018666161223152607.
4. Scarano A, Pecora G, Piattelli M, Piattelli A. (2004) Osseointegration in a sinus augmented with bovine porous bone mineral: histological results in an implant retrieved 4 years after insertion. A case report *J Periodontol*. 2004 Aug;75(8):1161-6. doi: 10.1902/jop.2004.75.8.1161.
5. Sauerbier S, Rickert D, Gutwald R, Nagursky H, Oshima T, Xavier SP, Christmann J, Kurz P, Menne D, Vissink A, Raghoobar G, Schmelzeisen R, Wagner W, Koch FP (2011) Bone marrow concentrate and bovine bone mineral for sinus floor augmentation: a controlled, randomized, single-blinded clinical and histological trial—per-protocol analysis. *Tissue Eng Part A*. 17(17-18):2187-97. doi: 10.1089/ten.TEA.2010.0516.
6. Zhang Y, Tangl S, Huber CD, Lin Y, Qiu L, Rausch-Fan X (2012) Effects of Choukroun’s platelet-rich fibrin on bone regeneration in combination with deproteinized bovine bone mineral in maxillary sinus augmentation: a histological and histomorphometric study. *J Craniomaxillofac Surg*. 40(4):321-8. doi: 10.1016/j.jcms.2011.04.020.
7. Vincent-Bugnas S, Charbit Y, Charbit M, Dard M, Pip-penger B (2020) Maxillary Sinus Floor Elevation Surgery with BioOss Mixed with Enamel Matrix Derivative: A Human Randomized Controlled Clinical and Histologic Study. *J Oral Implantol*. 46(5):507-513. doi: 10.1563/aaid-joi-D-19-00119.
8. Gulotta LV, Kovacevic D, Ehteshami JR, Dagher E, Packer JD, Rodeo SA (2009) Application of bone marrow-derived mesenchymal stem cells in a rotator cuff repair model. *Am J Sports Med*. 37(11):2126-33. doi: 10.1177/0363546509339582.
9. Pasquali PJ, Teixeira ML, de Oliveira TA, de Macedo LG, Aloise AC, Pelegrine AA (2015) Maxillary Sinus Augmentation Combining Bio-Oss with the Bone Marrow Aspirate Concentrate: A Histomorphometric Study in Humans. *Int J Biomater*. 2015:121286. doi: 10.1155/2015/121286.
10. de Oliveira TA, Aloise AC, Orosz JE, de Mello E Oliveira R, de Carvalho P, Pelegrine AA (2016) Double Centrifugation Versus Single Centrifugation of Bone Marrow Aspirate Concentrate in Sinus Floor Elevation: A Pilot Study. *Int J Oral Maxillofac Implants*. 31(1):216-22. doi: 10.11607/jomi.4170.
11. Canellas JVDS, Drugos L, Ritto FG, Fischer RG, Medeiros PJD (2021) Xenograft materials in maxillary sinus floor elevation surgery: a systematic review with network meta-analyses. *Br J Oral Maxillofac Surg*. 59(7):742-751. doi: 10.1016/j.bjoms.2021.02.009.
12. Dohan Ehrenfest DM, de Peppo GM, Doglioli P, Sammartino G (2009) Slow release of growth factors and thrombospondin-1 in Choukroun’s platelet-rich fibrin (PRF): a gold standard to achieve for all surgical platelet concentrates technologies. *Growth Factors*. 27(1):63-9. doi: 10.1080/08977190802636713.
13. Okaş B, Çırpar M, Şanlı E, Canbeyli İD, Bozdoğan Ö (2021) The effect of the platelet-rich plasma on osteogenic potential of the periosteum in an animal bone defect model. *Jt Dis Relat Surg*. 32(3):668-675. doi: 10.52312/jdrs.2021.199.
14. Wang J, Sun Y, Liu Y, Yu J, Sun X, Wang L, Zhou Y (2022) Effects of platelet-rich fibrin on osteogenic differentiation of Schneiderian membrane derived mesenchymal stem cells and bone formation in maxillary sinus. *Cell Commun Signal*. 15;20(1):88. doi: 10.1186/s12964-022-00844-0.
15. Mossaad AM, Ahmady HHA, Ghanem WH, Abdelrahman MA, Abdelazim AF, Elsayed SA (2021) The Use of Dual Energy X-Ray Bone Density Scan in Assessment of Alveolar Cleft Grafting Using Bone Marrow Stem Cells Concentrate/Platelet-Rich Fibrin Regenerative Technique. *J Craniofac Surg*. 01;32(8):e780-e783. doi: 10.1097/SCS.00000000000007772.
16. Wang J, Wang L, Zhou Z, Lai H, Xu P, Liao L, Wei J (2016) Biodegradable Polymer Membranes Applied in Guided Bone/Tissue Regeneration: A Review. *Polymers (Basel)*. 2016 Mar 29;8(4):115. doi: 10.3390/polym8040115.
17. Sauerbier S, Stricker A, Kuschnierz J, Bühler F, Oshima T, Xavier SP, Schmelzeisen R, Gutwald R (2010) In vivo

- comparison of hard tissue regeneration with human mesenchymal stem cells processed with either the FICOLL method or the BMAC method. *Tissue Eng Part C Methods*. 16(2):215-23. doi: 10.1089/ten.TEC.2009.0269.
18. Wildburger A, Payer M, Jakse N, Strunk D, Etchard-Liechtenstein N, Sauerbier S. (2014) Impact of autogenous concentrated bone marrow aspirate on bone regeneration after sinus floor augmentation with a bovine bone substitute--a split-mouth pilot study. *Clin Oral Implants Res*. 25(10):1175-81. doi: 10.1111/clr.12228.
  19. Payer M, Lohberger B, Strunk D, Reich KM, Acham S, Jakse N (2014) Effects of directly autotransplanted tibial bone marrow aspirates on bone regeneration and osseointegration of dental implants. *Clin Oral Implants Res*. 25(4):468-74. doi: 10.1111/clr.12172.
  20. Zhou Z, Yun J, Li J, Chen Y, Duan T, Wang L, Han J, Jiang HB, Niu G (2023) Comparison of the efficacy of different biodegradable membranes in guided bone/tissue regeneration: a systematic review and network meta-analysis. *Biomed Mater*. 19;18(3). doi: 10.1088/1748-605X/acc99a.
  21. Qiu, Y., Bao, S., Wei, H., Miron R J, Bao S, Zhang Y & Wang Y (2023) Bacterial exclusion and wound healing potential of horizontal platelet-rich fibrin (H-PRF) membranes when compared to 2 commercially available collagen membranes. *Clin Oral Invest*. <https://doi.org/10.1007/s00784-023-05108-w>
  22. Ali S, Bakry SA, Abd-Elhakam H (2015) Platelet-Rich Fibrin in Maxillary Sinus Augmentation: A Systematic Review. *J Oral Implantol*. 41(6):746-53. doi: 10.1563/aaid-joi-D-14-00167.
  23. Davide Gerardi, Nicolò Santostasi, Diana Torge, Fabiola Rinaldi, Sara Bernardi, Serena Bianchi, Maurizio Piattelli, Giuseppe Varvara (2023) Regenerative Potential of Platelet—Rich Fibrin in Maxillary Sinus Floor Lift Techniques: A Systematic Review. *Journal of Biological Regulators and Homeostatic Agents*. 37(5): 2357-2369. <https://doi.org/10.23812/j.biol.regul.homeost.agents.20233705.232>
  24. de Almeida Malzoni, C.M., Pichotano, E.C., Freitas de Paula, L.G. et al. Combination of leukocyte and platelet-rich fibrin and demineralized bovine bone graft enhanced bone formation and healing after maxillary sinus augmentation: a randomized clinical trial. *Clin Oral Invest* 27, 5485–5498 (2023). <https://doi.org/10.1007/s00784-023-05167-z>
  25. Idiri Katia, Octave Bandiaky, Assem Soueidan, Christian Verner, Emmanuelle Renard, and Xavier Struillou. 2023. “The Effectiveness of the Addition of Platelet-Rich Fibrin to Bovine Xenografts in Sinus and Bone Ridge Augmentation: A Systematic Review” *Journal of Functional Biomaterials* 14, no. 7: 389. <https://doi.org/10.3390/jfb14070389>
  26. Nejat Nizam, Gülnihal Eren, Aliye Akcalı, Nikolaos Dinos. (2017). Maxillary sinus augmentation with leukocyte and platelet-rich fibrin and deproteinized bovine bone mineral: A split-mouth histological and histomorphometric study *Clinical Oral Implants Research*, Volume 29, Issue 1, 67-75, <https://doi.org/10.1111/clr.13044>
  27. Bolukbasi N, Ersanlı S, Keklikoglu N, Basegmez C, Ozdemir T (2015) Sinus Augmentation with Platelet-Rich Fibrin in Combination with Bovine Bone Graft Versus Bovine Bone Graft in Combination with Collagen Membrane. *J Oral Implantol*. 41(5):586-95. doi: 10.1563/AAID-JOIID-13-00129.
  28. Mazzotta A, Stagni C, Rocchi M, Rani N, Del Piccolo N, Filardo G, Dallari D (2021) Bone marrow aspirate concentrate/platelet-rich fibrin augmentation accelerates healing of aseptic upper limb nonunions. *J Orthop Traumatol*. 5;22(1):21. doi: 10.1186/s10195-021-00582-y.
  29. Wang W, Yeung KWK (2017) Bone grafts and biomaterials substitutes for bone defect repair: A review. *Bioact Mater*. 7;2(4):224-247. doi: 10.1016/j.bioactmat.2017.05.007.
  30. Lee EY, Kim ES, Kim KW (2014) Vertical Augmentation of Maxillary Posterior Alveolar Ridge Using Allogenic Block Bone Graft and Simultaneous Maxillary Sinus Graft. *Maxillofac Plast Reconstr Surg*. 36(5):224-9. doi: 10.14402/jkamprs.2014.36.5.224.
  31. SÁñchez-Recio, Cristina & PeÑarrocha-Diago, Maria & Penarrocha, Miguel & Penarrocha-Oltra, David (2009) Maxillary sinus lift performed using ultrasound. Evaluation of 21 patients. *Medicina oral, patología oral y cirugía bucal*. 15. e371-4. 10.4317/medoral.15.e371.
  32. Tsai CF, Pan WL, Pan YP, Chan CP, Ju YR, Wang YM, Lin CY, Chang CC (2020) Comparison of 4 sinus augmentation techniques for implant placement with residual alveolar bone height  $\leq 3$  mm. *Medicine (Baltimore)*. 13;99(46): e23180. doi: 10.1097/MD.00000000000023180.
  33. Uchida Y, Goto M, Katsuki T, Soejima Y (1998) Measurement of maxillary sinus volume using computerized tomographic images. *Int J Oral Maxillofac Implants*. 3(6):811-8. PMID: 9857592.

34. Kwon, J-J, Hwang, JJ, Kim, Y-D, Shin, S-H, Cho, B-H, Lee, J-Y (2019) Automatic three-dimensional analysis of bone volume and quality change after maxillary sinus augmentation. *Clin Implant Dent Relat Res.* 21: 1148– 1155. <https://doi.org/10.1111/cid.12853>
35. Trimmel, B, Gede, N, Hegyi, P, et al. Relative performance of various biomaterials used for maxillary sinus augmentation: A Bayesian network meta-analysis. *Clin Oral Impl Res.* 2021; 32: 135– 153. <https://doi.org/10.1111/clr.13690>
36. Pierre L, Nabih N, Ronald Y (2022) Sinus Augmentation Using Mineralized Bone Allografts: A 6-Month Histological and Histomorphometric Analysis. *J Maxillofac Oral Surg.* 21(4):1180-1190. doi: 10.1007/s12663-022-01728-z.
37. Khaled H, Atef M, Hakam M (2019) Maxillary sinus floor elevation using hydroxyapatite nano particles vs tenting technique with simultaneous implant placement: A randomized clinical trial. *Clin Implant Dent Relat Res.* 21: 1241– 1252. <https://doi.org/10.1111/cid.12859>
38. Liat Chaushu, Erick Ricardo Silva, Vitor Ferreira Balan, Gavriel Chaushu, Samuel Porfirio Xavier (2021) Sinus augmentation - autograft vs. fresh frozen allograft: Bone density dynamics and implant stability, *Journal of Stomatology, Oral and Maxillofacial Surgery*, 122, (5), 467-471, <https://doi.org/10.1016/j.jormas.2020.08.012>.
39. Dragonas P, Foote M, Yu Q, Palaiologou A, Maney P (2020) One-year implant survival following lateral window sinus augmentation using plasma rich in growth factors (PRGF): a retrospective study. *Med Oral Patol Oral Cir Bucal.* 1;25(4): e474-e480. doi: 10.4317/medoral.23482.
40. Lie SAN, Leung CAW, Claessen RMMA, Merten HA, Kessler PAWH (2021) Implant survival after graftless sinus floor augmentation in highly atrophic maxillae: a randomized controlled trial in a split mouth study. *Int J Implant Dent.* 18;7(1):107. doi: 10.1186/s40729-021-00387-y.
41. Wala Kadry, Mervat Eldeftar, Yasmine Nassar, Adel Abou-El-fetouh, Maha Mohamed Hakam (2021) Clinical, volumetric and densitometric evaluation of tissue engineered constructs for secondary alveolar cleft reconstruction: A randomized clinical trial, *Journal of Cranio-Maxillofacial Surgery*, 49, (12): (1141-1150), <https://doi.org/10.1016/j.jcms.2021.09.003>.
42. Gerhardt DMJM, De Visser E, Hendrickx BW, Schreurs BW, Van Susante JLC (2018) Bone mineral density changes in the graft after acetabular impaction bone grafting in primary and revision hip surgery. *Acta Orthop.* 89(3):302-307. doi: 10.1080/17453674.2018.1460776.
43. Sam G, Vadakkekuttical RJ, Amol NV. In vitro evaluation of mechanical properties of platelet-rich fibrin membrane and scanning electron microscopic examination of its surface characteristics. *J Indian Soc Periodontol.* 2015 Jan-Feb;19(1):32-6. doi: 10.4103/0972-124X.145821. PMID: 25810590; PMCID: PMC4365153.
44. Sun J, Zhang X, Li R, Chen Z, Huang Y, Chen Z (2018) Biological Effects of Orthodontic Tooth Movement into the Grafted Alveolar Cleft. *J Oral Maxillofac Surg.* 76(3):605-615. doi: 10.1016/j.joms.2017.08.029.