



## Histological Study of Antibiotic Effect on Liver, Kidney and Breast Muscle in Poultry



Bader Khatlan Hameed<sup>1</sup>, Marwa Adil Hameed<sup>1</sup>, Hadeel M. Hussein<sup>2\*</sup> and Siham Agmee Wadee<sup>2</sup>

<sup>1</sup>Department of Anatomy and Histology, College of Veterinary Medicine, University of Tikrit, Tikrit, Iraq.

<sup>2</sup>Department of Physiology, Pharmacology and Biochemistry, College of Veterinary Medicine, University of Tikrit, Tikrit, Iraq.

### Abstract

VETERINARIANS and the poultry industry utilize antibiotics to improve the health and growth rates of their birds, as well as to increase egg output, feed efficiency, and the frequency of illnesses in poultry. The Antibiotic was utilized in the chicken industry- for both preventative and therapeutic purpose. However, the illicit use of these medications has resulted in the build-up of harmful poultry products containing antibiotics residue that are intended to conception of human. Furthermore, there is serious risk occurring in the community from this may be, microbiological, immunological, or toxicological. The present study was conducted to demonstrate the effect antibiotics on the histological structure of different poultry tissues (Liver, Kidney and Breast muscle). In this study 300 chicken were used and divided into two groups. Group(A): chicken are aged 38 day and subdivide into three subgroups, first group fed with ciprofloxacin in age 20 day for 4 days and second group fed with colistin in age 30 day for 4 days and last group in age 5 days used neomycin for 2 day. Group (B): chicken are aged 42 day and subdivided into two subgroups, first used colistin and tylosin antibiotics in age 13 day for 3 days and second group used erythromycin in age 20 day for 4 days. the dose of antibiotic ranged from 5-15 mg /kg of body weight. After the chickens were killed, a tissue sample was taken. Outcome includes effects on the kidney, glomerular atrophy and reduction of convoluted tubule epithelial cells. Hemolysis in blood vessels, while in liver caused cell degradation. Furthermore, results showed an impact on the breast muscle that led to nerve fiber degeneration and muscle fiber atrophy. The aim of the study was to investigate the histopathological effects of antibiotic residues on various bird tissues and potential health risks for humans.

**Keywords:** Residue, Antibiotics, Nerve fibers degeneration, Glomeruli.

### Introduction

Natural, semi-synthetic, and synthetic substances with antibacterial effects action can be applied topically, orally, or by parenteral are known as antibiotics [1]. In the poultry industry, antibiotics are some of the most commonly utilized veterinary medications. [2]. Poultry is given antibiotics to promote rapid growth and prevent illness [3, 4]. The majority of antibiotics utilized in chicken production are fed to the birds or added to their drinking water. According to reports, these medications are rapidly absorbed from the chicken's digestive system after being administered [5].

In chicken farms, antibiotics are used for preventive, medicinal, and growth-promoting purpose. However, the use antibiotics at lower doses over longer periods of time is consider

crucial, because it leads to the evolution of resistant bacterial strains. In underdeveloped countries, antibiotics are added to feed additives without proper monitoring in an effort to increase yields [6]. The macrolide antibiotics are mostly a class of bacteriostatic substances that are structurally similar to erythromycin, tylosin, and spiramycin [7]. Macrolides are effective against gram-positive bacteria including *Streptococcus* and *Staphylococcus* species and against *Mycoplasma* species, but they have very little effects against gram-negative bacteria [8]. The liver breaks down macrolides, which are then eliminated into bile. [9].

The majority of the animal industries used to produce food around the world consist of poultry. It is a major source of animal waste that has an adverse effect on the environment and one of the

\*Corresponding author: Hadeel Mahdi Hussein, E-mail: hadeelmh433@gmail.com, Tel.: +9647716884245

(Received 08/01/2024, accepted 26/03/2024)

DOI: 10.1010.21608/EJVS.2024.250672.1680

©2025 National Information and Documentation Center (NIDOC)

biggest users of antibiotics. The U.S. Food and Administration Drugs (FDA) says that most antibiotics used in chicken farming are administered orally and blended with feed or water [10, 11]. Antibiotic-resistant bacteria are widespread across the global chicken production chain, irrespective of the degree of direct antibiotic exposure [12, 13]. Additionally, the architecture and physiology of birds and mammals are different, and zoonotic pathogens-including those that originate in poultry, and may have the potential to direct impact on human health [14,15]. The improper use of antibiotics and hormones in growth-promoting may leave trace amounts of these substances as residuals in chicken carcasses [16,17], and this impact on human health because humans are the final users of these harmful antibiotics that remain in these products [18].

There are several ways in which chickens exposed to drugs or other pollutants, which lead to presence of drug in their meat and eggs, these include: 1.: Off-label or illegal drug usage, 2. Inadvertent cross-contamination of feed during feed mixing, and 3. Mislabeling of feed. Eggs and poultry meat are vital food commodities for humans. Unfortunately, since antibiotics are used improperly and continuously in chicken, edible bird tissues may be contaminated with dangerously and high level of drug residues [19], therefore the drawings of approved veterinary medications should take from days to weeks [20].

## **Material and Methods**

### **Animal preparation**

a total (300) chicken were divided into two groups; group A and B.

**Group(A):** chicken in this group are aged 38 day and subdivide into three subgroups, first group fed with ciprofloxacin in age 20 day for 4 days and second group fed with colistin in age 30 day for 4 days and last group in age 5 days used neomycin for 2 day in food.

**Group (B):** chicken in this group is aged 42 day and subdivided into two subgroups, first used colistin and tylosin antibiotics in age 13 day for 3 days and second group used erythromycin in age 20 day for 4 days.

**Samples collection:** A total of twelve various tissues specimens include (liver, kidney and breast muscle) were collected from chicken farms located near Samarra city.

A tissue sample was about 1-2 g from all tissues that obtain from recently slaughtered chickens. Samples were placed in formalin 10% until transported to the laboratory at the College of Veterinary Medicine- University of Tikrit for Preparation and histological study.

## **Results**

**Kidneys of Group (A):** Results showed that the kidney's cortex had atrophied glomeruli, which were visible as a small mass displaced to the periphery of Bowman's capsule. Moreover, the cells lining the renal tubes in the medulla of the kidneys were degraded and the cytoplasm of the cell vacuolated and under mild strain. In addition, the capsular space was wide. The proximal and distal convoluted tubule cells were degenerated and the tubule lumens were filled with glomerular filtrated material. The glomeruli's basement membrane was thickened in the interstitial C.T., (fig. 1).

**Liver of Group (A):** The liver's central veins and major blood arteries had thicker walls with WBC infiltration surrounding them, causing significant blood congestion in the parenchyma (fig. 2).

The results showed dilatation in C.T. of interstitial collagen fibres in a group of liver cells in the parenchyma which formed the liver. The periphery of liver was containing wide network of blood sinusoid with great number of kupffers cells associated atrophy of liver cell (fig. 3).

**Breast Muscle of Group (A):** Each bundle of skeletal muscle fibers surrounded by perimysium (the connective tissue that encircles the muscle bundle). A portion of the skeletal muscle fibers showed atrophy, and the nerve fibers between the muscle fibers showed partial degeneration of their sarcoplasm in other cases (fig. 4).

**Kidney of Group (B):** The majority of renal cortex's of glomeruli were atrophied and showed up as a denes mass inside the Bowman's capsular space, which was quite large. The cells lining the proximal and distal convoluted tubules appeared on a mass and the tubules themselves contracted away from the basement membrane. As well as, lymphocyte penetrated the interstitial C.T. (fig. 5). Blood containing hemosiderin pigment was seen in severely clogged blood arteries (figs. 5,6). The epithelial cells of renal tubules present in the kidney's medulla were contracted from the basement membrane. As a result, the renal tubule's current gap was destroyed, and the interstice C.T. had congested blood capillaries (fig. 6). Additionally, a number of the renal medulla's collecting ducts resulted in deteriorated epithelial cells that were sloughing in the tubule lumen. There was also a significant amount of lymphocyte infiltration and other inflammatory cells.

**Liver of Group (B):** The liver's parenchyma contained degenerated cells that had lost their polygonal shape and were presented in small groups that did not contain cytoplasm. Several of these cells were also atrophied, and blood sinusoids contained hemolyzed blood and were associated with a wide zone of lymphocytic infiltration. Hepatocytes and sinusoids surrounded the

hemolyzed blood in the portal vein, which was also severely congested from degenerated liver cells and blood sinusoids (Fig. 7).

#### **(H&E X40)**

**Breast Muscle of Group (B):** The breast muscle fibers were seen in different size, but certain numbers were atrophied partially, the sarcoplasm was degenerated and lost its nuclei. Loose C.T (endomysium) which surrounding the individual skeletal muscle fibers appeared scattered and not adhered to the membrane of the muscle fibers. Moreover, there was a partially degeneration in the nerve fibers which are ending the membrane of the muscle fibers and associated with lymphocytic diffusion around it (Fig. 8).

#### **Discussion**

The results of a recent study revealed that the kidney contained atrophied glomeruli, which appeared as a small mass displaced to the periphery of Bowman's capsule. The capsular space was wide. The proximal and distal convoluted tubule cells were degenerated, and the lumen of cortex number of these tubule were filled with glomerular filtrate. The basement membrane of glomeruli was thickened were broken down, there were vacuolated regions of mild strain in the cytoplasm of the cell, and lymphocytes had pierced the interstitial CT. that agreement with katarzyna slizewiska [23].

Our result agreement with Berghiche study, and results [24]. The liver's parenchyma contained degenerated cells that had lost their polygonal shape and were present in small groups with no longer containing cytoplasm. Some of these cells were also atrophied, and the blood sinusoids that were present had some hemolyzed blood and were linked to a large area of lymphocytic infiltration. Additionally, hemolyzed blood filled the portal vein, which was surrounded by degenerated hepatocytes and sinusoids. The fibers of the breast muscle were visible, varying in size, but some had partially atrophied.

The loose C.T. (endomysium) that surrounded each individual skeletal muscle fiber seemed scattered and not adherent to the muscle fiber membrane. The sarcoplasm was deteriorated and lost its nuclei. There was lymphocytic dissemination surrounding the partially degenerated nerve fibers that terminate the muscle fiber membrane.

In the previous study high quantity of antibiotic residues in the kidney; these results indicated that antibiotic residues in meat pose health risks [9]. Hala, study agreement with our study and Liver, Muhammad's study supported our result that explain the kidneys had larger quinolone residuals than muscles and eggs. This study agreement with our study [12].

Present study agreement with Soliman, A.M. and Sedeik , Abenavoli they found A histological alterations in the liver brought on by antibiotics'

harmful effects, particularly when they are taken in high concentrations or for an extended period of time [1, 18].

#### **Conclusion**

The detection of measurable quantities of antibiotic residues in poultry tissue during screening may be a sign of widespread antibiotic overuse in poultry farms and a lack of knowledge among farmers regarding the advised drug withdrawal times.

When antibiotics are used indiscriminately and irrationally in poultry without adhering to the withdrawal time, animal food may include unanticipated residues that pose a major risk to human health.

All chicken farms should follow a sufficient withdrawal period after using antibiotics therapeutically in order to prevent the emergence of antimicrobial resistance and preserve the antibiotics' efficacy for use in human medicine..

In order to ensure the safety of food supply, strict regulatory monitoring of antibiotic use must be carried out before any antibiotic is approved for use in the poultry industry.

The veterinary feed guideline prohibits the use of antibiotics for animal therapy if they are deemed vitally important. The role of veterinarians in the usage of antibiotics is another significant concern.

Inadequate consultation with veterinarians may lead to the incorrect prescription of antibiotics, hence increasing hazards. To improve the careful and sensible use of antibiotics in animals, farmers must also be aware of the effects that improper use of antibiotics in animals can have on human health and the environment.

By using good farm management practices and providing animals with a clean environment, the use of antibiotics as growth promoters or for any other purpose should be minimized. Additionally, some basic infrastructure should be provided for a national program of residue monitoring and periodic surveillance of antibiotic residues in edible tissues at the level of abattoirs, farms, markets, etc.

#### *Acknowledgment*

A special thanks and deep gratitude to Departments of Anatomy and Histology, and Pharmacology, physiology and biochemistry, College of Veterinary Medicine, University of Tikrit, Iraq, for their support and help in finishing this work.

#### *Statement on Conflicts of Interest.*

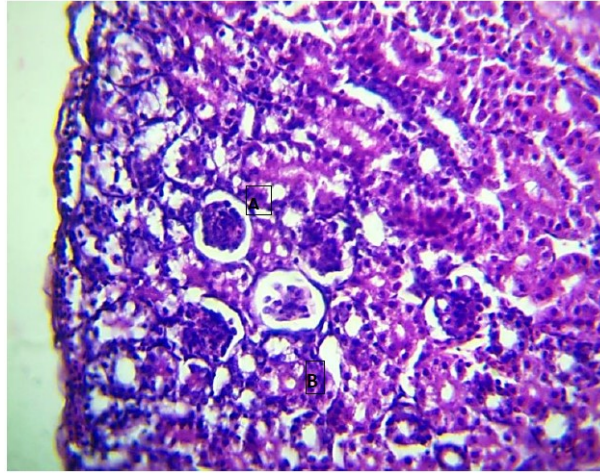
The writers say they have no competing interests.

#### *Ethical approval*

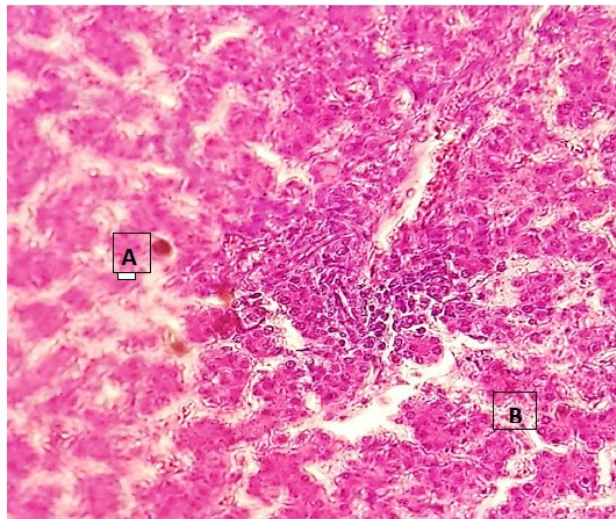
This study proposal approved by the faculty of veterinary medicine Tikrit University, Iraq.

#### *Authors' contribution*

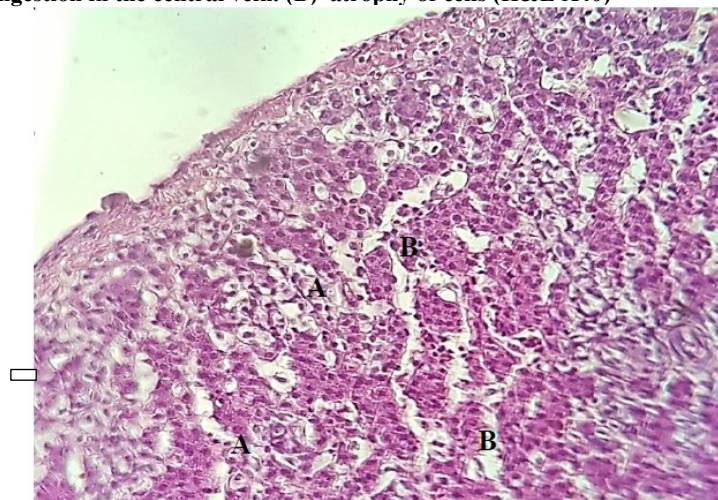
Conceptualization, BKH, MAH, SAW; methodology and write; BKH, MAH, SAW , HMH; anatomical part BKH, Histological part ;MAH ; pharmacological part, SAW, HMH;



**Fig. 1. (A) The cortex of kidney demonstrating the atrophy of glomeruli .(B) degeneration the cell of convoluted tubules .(H&E X40).**



**Fig. 2. (A) Blood congestion in the central vein. (B) atrophy of cells (H&E X40)**



**Fig. 3. (A) liver's periportal, displaying a vast network of sinusoids and kupffer cells. (B) Atrophy of liver cell (H&E X40).**

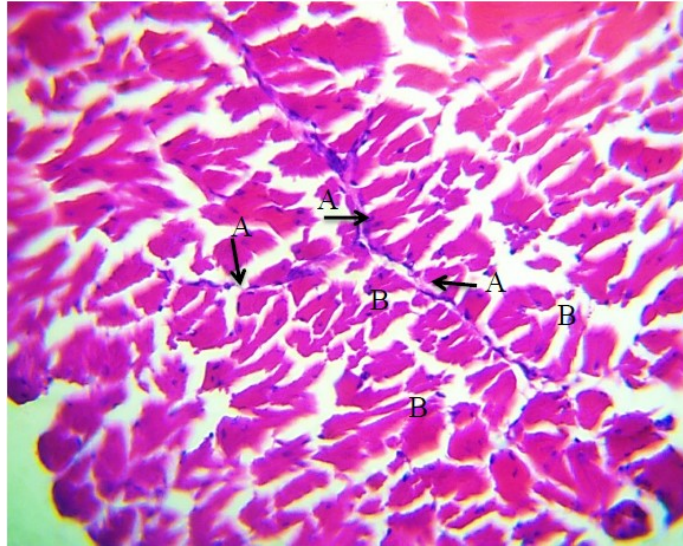


Fig. 4. (A)The nerve fibers were degeneration. (B) certain number of breast muscle fibers were atrophied . (H&E X40).

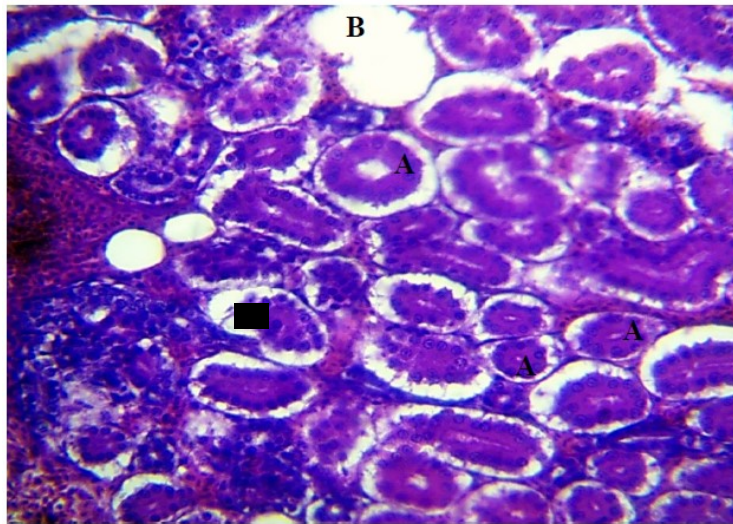


Fig. 5. (A) Shrinkage of epithelial cell of convoluted tubules of kidney from basement membrane.(B) complete disappearance of renal tubules (H&E X40)

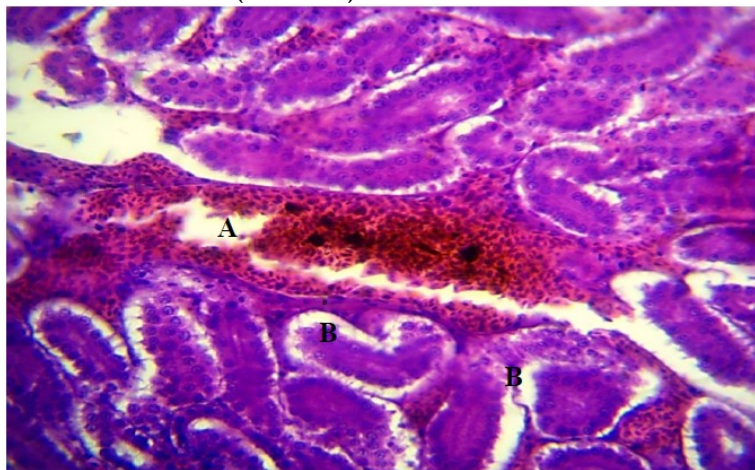
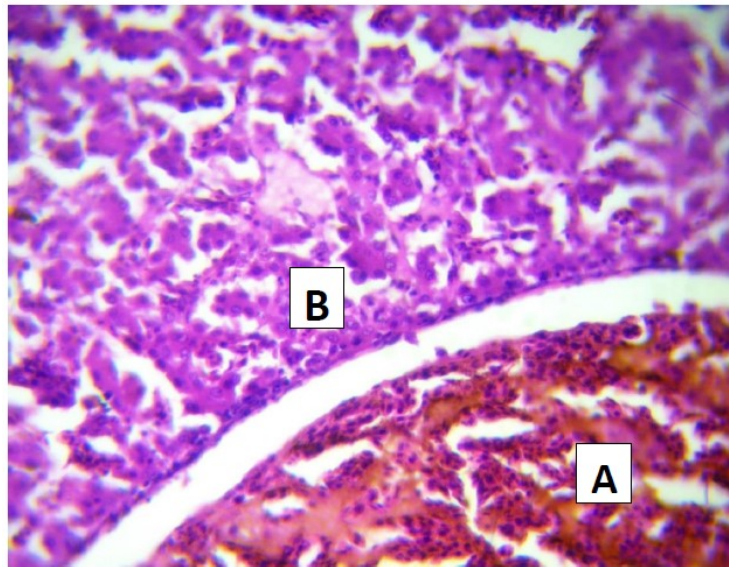
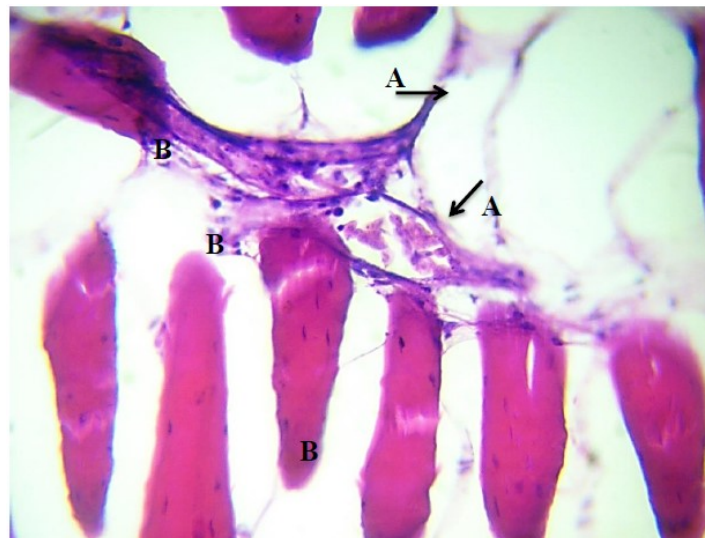

Fig. 6. (A) Blood congestion of blood vessels with presence of hemosiderin. (B) Shrinkage of renal tubules (HE X40).



**Fig. 7. (A) congestion of blood inside the portal vein.(B) Degeneration of liver cell .**



**Fig. 8. (A) Degeneration of nerve fibers. (B) associated with atrophied skeletal muscle fibers. (H&E X40).**

### References

1. Geidam, Y.A., Usman, H., Musa, H.I., Anosike, F. and Adeyemi, Y. Oxytetracycline and Procain. Penicillin residues in tissues of slaughtered cattle in Maiduguri, Bornostate, Nigeria. *Terrestrial and Aquatic Environmental Toxicology*, **3**(2), 68-70(2009).
2. Simon A.H. and Baxter, G.A. Biosensor screening for veterinary drug residues in food stuffs. *J. AOAC Int.*, **89**(3), 862-867(2006).
3. Nisha, A. Antibiotic residues—a global health hazard. *Vet. World*, **1**,375–377 (2008).
4. Moreno-Bondi, M. C., Mar Azuela M. D., Herranz, S. and Rodriguez, E. An overview of sample preparation procedures for LC-MS multiclass antibiotic determination in environmental and food samples. *Anal. Bioanal. Chem.*, **395**, 921– 946 (2009).
5. Wang, H. H. Antibiotic resistance mitigation: a complicated issue begging for targeted investigation. *Microbe*, **5**, 504–505 (2010). [Google Scholar]
6. Wegener, H. C. Antibiotics in animal feed and their role in resistance development. *Curr. Opin. Microbiol.*, **6**, 439–445 (2003).
7. Papich, M.G. and Riviere, J.E. Chloramphenicols and derivatives, macrolides, lincosamides, and miscellaneous antimicrobials. In *Veterinary Pharmacology and Therapeutics*, 8th edn. Ed. Adams, H.R., pp. 868–917. Iowa State University Press, Ames, IA. (2001).
8. Botsoglou , N.A. and Fletouris, D.J. *Drug Residues in Food*. Marcel Dekker, Inc., New York, NY. (2001)

9. Giguere, S. Macrolides, azalides, and ketolides. In Antimicrobial Therapy in Veterinary Medicine. Eds Giguere, S., Prescott, J.F., Baggot, J.D., Walker, R.D. & Dowling, P.M., pp. 191–206. Blackwell Publishing, Ames, IA. (2006).
10. U.S. Food and Drug Administration. Summary Report On Antimicrobials Sold or Distributed for Use in Food-Producing Animals, ed. Medicine C. F. V. (Paris: US Food & Drug Administration; ) (2018).
11. U.S. Food and Drug Administration. Important Safety Alert Regarding Use of Fecal Microbiota for Transplantation and Risk of Serious Adverse Reactions Due to Transmission of Multi-Drug Resistant Organisms [Online]. Paris: FAO (2019).
12. Baron, S., Le Devendec, L., Touzain, F., Jouy, E., Lucas P., de Boissezon, C., Longitudinal study of *Escherichia coli* plasmid resistance to extended-spectrum cephalosporins in free-range broilers. *Vet. Microbiol.*, **216**, 20–24(2018) . DOI: 10.1016/j.vetmic.2018.01.012.
13. Apostolakos , I., Mughini-Gras, L., Fasolato, L., Piccirillo, A., Assessing the occurrence and transfer dynamics of ESBL/pAmpC-producing *Escherichia coli* across the broiler production pyramid. *PLoS One*, **14**, e0217174(2019). DOI :10.1371/journal.pone.0217174
14. Knudsen, P. K., Gammelsrud, K. W., Alfsnes, K., Steinbakk, M., Abrahamsen, T. G. and Muller, F. Transfer of a bla CTX-M-1-carrying plasmid *p*. *Scientific Reports*, **8**(1), 280(2018). DOI:10.1038/s41598-017-18659-2
15. Borges, C. A., Tarlton, N. J., Riley, L. W. *Escherichia coli* from commercial broiler and backyard chickens share sequence types, antimicrobial resistance profiles, and resistance genes with human extraintestinal pathogenic *Escherichia coli*. *Foodborne Pathog. Dis.*, **16** 813–16822(2019). DOI.10.1089/fpd.2019.2680
16. Abenavoli, L., Libri, E., Bosco, D., Gallo, D. and Luzzza, F. Drug-induced liver injury. *Recenti. Prog. Med.*, **103**(2), 79-84 (2012) .
17. Hala .I. M . Residues of Antibiotic in poultry meat. May 2019. *Antibiotics*, **4**,47(2006).
18. Olatoye, I.O. and Ehinwomo, A.A. Oxytetracycline Residues in Edible tissues of cattle slaughtered in Akure, Nigeria. *Internet. J. Food Safety*, **11**, 62-66 (2009).
19. Shareef, A.M., Jamel, Z.T. and Yonis, K.M. Detection of antibiotic residues in stored poultry products. *Iraq J. Vet. Sci.*, **23**(1), 45-48(2009).
20. Doyle, M.E. Veterinary drug residues in processed meats potential health risk: A review of the scientific literature. Food Research Institute, University of Wisconsin, Madison. (2006).
21. Muhammad N. and Khalida K.S. Determination of Residues of Quinolones in Poultry Products by High Pressure Liquid Chromatography. *Journal of Applied Sciences*. **6**, 373-379 (2006).
22. Wegener, H. C. Antibiotics in animal feed and their role in resistance development. *Curr. Opin. Microbiol.*, **6**, 439–445 (2003).
23. Ślizewska, K., Cukrowska, B., Smulikowska, S. and Cielecka-Kuszyk, J. The Effect of Probiotic Supplementation on Performance and the Histopathological Changes in Liver and Kidneys in Broiler Chickens Fed Diets with Aflatoxin B<sub>1</sub>. *Toxins (Basel)*. **11**(2),112 (2019). doi: 10.3390/toxins11020112. PMID: 30781814; PMCID: PMC6409979.
24. Berghiche, A., Khenenou, T., Bouzid, R., Rahem, S., Labied, I. and Boulebda, N. Evaluation of Adverse Effects of Antibiotics on Broiler Chickens. *J. World Poult. Res.*, **10**(2S), 145-150(2020). DOI: <https://dx.doi.org/10.36380/jwpr.2020.19>

## دراسة نسيجية لتأثير المضادات الحيوية على الكبد والكلى وعضلات الثدي في الدواجن .

بدر ختلان حميد<sup>1</sup> ، مروة عادل حميد<sup>1</sup> ، سهام عجمي وادي<sup>2</sup> ، سهام عجمي وادي<sup>2</sup> و هديل مهدي حسين<sup>2</sup>

<sup>1</sup> فرع التشريح والأنسجة - كلية الطب البيطري - جامعة تكريت - تكريت - العراق.

<sup>2</sup> فرع الفسجلة والأدوية والكيمياء الحياتية - كلية الطب البيطري - جامعة تكريت - تكريت - العراق.

### الخلاصة

يستخدم الأطباء البيطريون وصناعة الدواجن المضادات الحيوية لتحسين صحة ومعدلات نمو الطيور ، وكذلك لزيادة إنتاج البيض وكفاءة الأعلاف وتواتر الأمراض في الدواجن. تم استخدام المضاد الحيوي في صناعة الدجاج. للأغراض الوقائية والعلاجية. ومع ذلك، أدى الاستخدام غير المشروع لهذه الأدوية إلى تراكم منتجات الدواجن الضارة التي تحتوي على بقايا المضادات الحيوية التي تهدف إلى الحمل البشري. علاوة على ذلك ، هناك خطر جسيم يحدث في المجتمع من هذا قد يكون ميكروبيولوجيا أو مناعيا أو سميا. أجريت هذه الدراسة لبيان تأثير المضادات الحيوية على التركيب النسيجي لأنسجة الدواجن المختلفة (الكبد والكلى وعضلة الثدي). في هذه الدراسة تم استخدام 300 دجاجة وتقسيمها إلى مجموعتين. المجموعة (أ): يبلغ عمر الدجاج 38 يوما وينقسم إلى ثلاث مجموعات فرعية ، المجموعة الأولى تتغذى على سيبروفلوكساسين في سن 20 يوما لمدة 4 أيام والمجموعة الثانية التي تغذت على الكوليستين في سن 30 يوما لمدة 4 أيام والمجموعة الأخيرة في سن 5 أيام استخدمت النيومايسين لمدة 2 يوم. المجموعة (ب): عمر الدجاج 42 يوم وينقسم إلى مجموعتين فرعيتين ، استخدمت الأولى مضادات الكوليستين والتايلوسين في سن 13 يوما لمدة 3 أيام والمجموعة الثانية استخدمت الارينثروميسين في سن 20 يوما لمدة 4 أيام. تراوحت جرعة المضادات الحيوية من 5-15 ملغم \ كغم من وزن الجسم. بعد قتل الدجاج، تم أخذ عينة من الأنسجة تشمل النتيجة التأثيرات على الكلى وضمور الكبيبات وتقليل الخلايا الظهارية الملطوية للنببيات. انحلال الدم في الأوعية الدموية، بينما في الكبد تسبب في تدهور الخلايا. علاوة على ذلك ، أظهرت النتائج تأثيرا على عضلة الثدي أدى إلى تنكس الألياف العصبية وضمور الألياف العضلية. كان الهدف من الدراسة هو التحقق في الآثار النسيجية المرضية لبقايا المضادات الحيوية على أنسجة الطيور المختلفة والمخاطر الصحية المحتملة على البشر.

**الكلمات الدالة:** المضادات الحيوية ، تنكس الألياف العصبية ، الكبيبات.