

CLINICAL EVALUATION OF FULL DIGITAL WORKFLOW TO PROVIDE A PREFABRICATED IMMEDIATE RESTORATION AFTER SINGLE-IMPLANT PLACEMENT

Haitham A. Ismail *^{ID} , Muhammed Badee El-Danasory **^{ID} , Yassmin A. Tahamawy *^{ID} ,
Naema A. Ammar ***^{ID} , Mohamed Moataz Khamis ****^{ID} ,
Ahmed M. Abdelhamid *****^{ID} and Mariam M. Bahgat **^{ID}

ABSTRACT

Introduction: The utilization of advanced technologies into the day by day practice in dental implantology is developing quickly. The development of the recent digital technologies for implant treatment such as the CBCT (Cone Beam Computed Tomography), 3D implant planning software and CAD/CAM (computer-aided design/computer-assisted manufacturing) has enabled a full digital prosthetically driven approach.

Objectives: The study aimed to clinically evaluate the accuracy of a full digital workflow for constructing a prefabricated immediate restoration for a single tooth implant.

Materials and Methods: Fifteen immediately-loaded dental implants were placed to restore a missing mandibular first molar. For each implant, a prefabricated restoration was designed based on the virtual implant planning. A fully guided surgical template was used to place the dental implant and the prefabricated acrylic restoration was delivered. Linear and angular deviations between the inserted and planned restorations were measured using 3D analysis software at occlusal and hex levels.

Results: The mean linear deviations (in mm) at the occlusal level were 0.17, 0.17, 0.45 in the buccolingual, mesiodistal, and occlusolingival directions respectively while at the hex level the linear deviations were 0.22, 0.31, 0.46 respectively. The mean horizontal and vertical angular deviations (in degrees) were 2.78 and 2.66 respectively.

Conclusion: Within the limitations of the present clinical study, the proposed workflow can be used for constructing a prefabricated immediate restoration for a single implant with the need for minor chairside adjustments.

KEYWORDS: Digital workflow, Prefabricated restoration, Immediate implant loading, Linear deviation, Angular deviation.

* Assistant Lecturer, Department of Prosthodontics, Faculty of Dentistry, Alexandria University, Alexandria, Egypt.

** Lecturer, Department of Prosthodontics, Faculty of Dentistry, Alexandria University, Alexandria, Egypt.

*** Assistant Lecturer, Department of Prosthodontics, Faculty of Dentistry, Pharos University of Alexandria, Alexandria, Egypt.

**** Professor and Chairman, Department of Prosthodontics, Faculty of Dentistry, Alexandria University, Alexandria, Egypt.

***** Professor, Department of Prosthodontics, Faculty of Dentistry, Alexandria University, Alexandria, Egypt.

INTRODUCTION

High survival rates of implant-supported restorations have attracted more and more patients to implant therapy. The increasing numbers of patients have been accompanied by a growing demand for rapid restoration of esthetics and function. The increasing demand for reducing the time of treatment and surgical procedures along with the improved designs and surface properties of dental implants have led to the emergence of the immediate loading protocol.

Immediate loading protocol can guide the healing of the peri-implant soft tissues and eliminate second-stage surgery⁽¹⁾. Immediate implant-supported restorations can be fabricated using different prosthetic techniques which are based on either clinical relining of prefabricated shells⁽²⁻⁶⁾, adjusting prefabricated restorations⁽⁷⁻¹¹⁾ or delivering postoperatively fabricated restorations^(12,13). The current techniques made use of the technologies of Computer-Aided Design/ Computer-Aided Manufacturing (CAD/CAM) and digital dentistry.

Prefabricated shells are provided as readymade polycarbonate crowns⁽⁵⁾ or constructed either using manual waxing-up^(2,3) or CAD/CAM technologies^(4,6). Clinical adaptation of these shells requires much chairside time and skills for relining, finishing and polishing procedures. On the other hand, postoperative immediate restorations are constructed after implant placement and delivered within 72 hours⁽¹⁴⁾. They are fabricated using either a conventional impression and manual laboratory procedures⁽¹²⁾ or an intra-oral scanning and CAD/CAM systems⁽¹³⁾. Although postoperative restorations are accurate and require less chairside time than the prefabricated shells, they require taking a postoperative impression, a second visit for insertion and may require facilities and equipment that are not available for every clinician due to financial limitations.

Midway between the prefabricated shells and the postoperative restorations, there are the

prefabricated restorations. They were constructed by placing an implant analogue into the study cast in the position of the planned implant, attaching the abutment and constructing the restoration before the surgical placement of the implant.⁽⁹⁾ The delivered restorations had high clinical inaccuracy due to lack of guidance that can limit the implant depth and position in the alveolar ridge.

The accuracy of prefabricated restorations has been increased with the integration of CAD/CAM technology into implant treatment and evolution of full guided implant surgeries. The clinical accuracy of the prefabricated restorations is based on the accurate transfer of virtual implant planning to a cast for constructing the immediate restoration and the accuracy of the fully guided surgical template to transfer the virtual planning to the patient mouth^(7,8). Transferring the virtual implant planning for constructing the restoration can be accomplished by placing implant analogues into a cast that is either printed according to the implant planning⁽⁷⁾ or poured using a fully guided surgical template⁽⁸⁾. Presence of many laboratory procedures that can affect the accuracy of the delivered restorations has aroused the need for a more precise and faster technique.

A full digital workflow was formulated to reduce the laboratory procedures and hence, increase the accuracy of the prefabricated restorations. The virtual implant planning is transferred to a prosthesis-designing software via an STL file of the digital cast containing scan bodies that indicate the position and orientation of the planned implants^(10,11).

Although the in-vitro evaluation of the full digital workflow has showed promising results⁽¹⁵⁾, clinical evaluation is mandatory. Accurate evaluation can be carried out by the virtue of the increased accuracy of the intra-oral scanners and the improvements in the three-dimensional analysis software.⁽¹⁶⁾ The current study, therefore, aims to digitally evaluate the clinical

accuracy of a full digital workflow for constructing a prefabricated restoration for immediate loading of a single tooth implant. The null hypothesis posited that there would be no linear and angular deviations at the Hex and occlusal levels between the planned and inserted restorations.

MATERIAL AND METHODS

The present study was conducted as a prospective single-arm controlled clinical trial. The study was approved under the number IORG0008839 by the ethical committee of the Faculty of Dentistry, Alexandria University and registered at clinicaltrial.org with registration number NCT04329169 and conducted in accordance with the Helsinki Declaration of 1975 as revised in 2013. Sample size was calculated by using a software program (G*Power version 3.1.9.2; Heinrich Heine University Düsseldorf) based on the results of a study evaluating the deviation of a prefabricated immediate restoration for single implant.⁽¹⁵⁾ The significance level was set to 95% with a power of 80%. The sample size required to evaluate the accuracy of a full digital implant protocol was 15.

Patient selection

Ten patients (7 females and 3 males; average age 30.8 ± 5.7) were enrolled in the current study. They were selected from those administered at the Department of Prosthodontics, Faculty of Dentistry, University of Alexandria. Patients were selected according to strictly identified inclusion and exclusion criteria. They had a unilateral / bilateral missing mandibular first molar. Edentulous areas were bounded. Each patient had enough bone for placing an implant at least 4 mm in diameter and 10 mm in length. Patients with a history of bone diseases, radiotherapy or chemotherapy or having a mouth opening less than 40 mm⁽¹⁷⁾ were excluded. All patients had provided their informed consent prior to inclusion in the study.

Virtual Implant Planning

All patients underwent a CBCT examination (3DAccutomo 170; J. Morita Corp) and intraoral scan (Medit i500; DentCore) of the dental arches and maximum intercuspation. Accurate virtual waxing up of the missing tooth was performed using prosthesis-designing software (Exocad DentalCAD 2.2 Valletta; Exocad GmbH) (Figure 1)

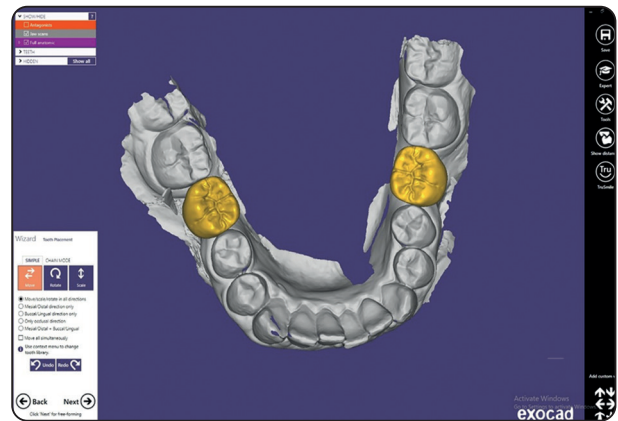


Fig. (1) Virtual waxing-up of the missing mandibular first molar.

The Digital Imaging and Communications in Medicine (DICOM) file from the CBCT examination and the Standard Tessellation Language (STL) file from the prosthesis-designing software were imported and merged in implant-planning software (Real Guide 5.0; 3Diemme Bioimaging technologies) for prosthetically-driven virtual implant planning and surgical guide designing. The superimposition was obtained as follows. First, the intraoral scan file was superimposed to the CBCT file using “best fit alignment” function then the final alignment was performed using “three-point” registration tool.

Design & Fabrication of the Surgical Guide

According to the virtual implant plan, a CAD/CAM tooth supported surgical guide was fabricated from a photopolymer resin (Clear resin 1 L, Formlabs, USA) using a 3D printing machine (Form 2, Formlabs, USA). a hexed metal sleeve was fixed to reflect the direction of the hex of the planned implant (Figure 2).

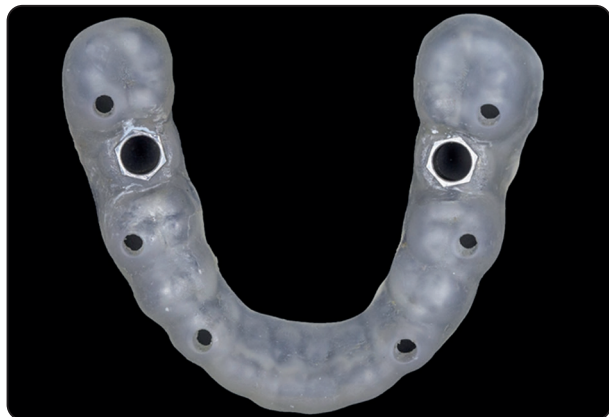

Fig. (2): Surgical guide with hexed metal sleeve.

Fabrication of the prefabricated restoration

A compatible virtual scan body was attached to the planned implant and the STL file was exported to the prosthesis-designing software for designing a one-piece, screw-retained crown with hex connection. The previously designed waxing-up was modified so that the crown had a clearance of 1 mm from the opposing and adjacent teeth to minimize occlusal forces and allow easy insertion without interference from adjacent contact areas. The designed crown was milled from a polymethylmethacrylate resin block (PMMA CAM; Concept Co., Italy). (Figure 3) Finally, the designed crown with the mandibular arch were saved as an STL file for the intended evaluation.

Implant placement and loading

The patient's mouth was rinsed with a solution of chlorhexidine digluconate 0.2% for 2 minutes and local anesthetic was obtained using 4% lidocaine HCL 20mg/mL. The tooth-supported surgical guide was positioned and checked for accuracy of fit then flapless placement of the dental implant (Oxyimplant, Biomec s.r.l, Italy) was performed. Implants were tightened till the orientation of the hex of the implant mount was coincident with that of the hex of the sleeve secured into the surgical guide (Figure 4). Primary implant stability was checked using a torque wrench. Readings of over 30 Ncm were recorded for all implants.

After removing the surgical guide, the screw retained restoration was inserted (Figure 5) and the patient underwent a postoperative scan using the same intra-oral scanner for future evaluation. Finally, the proximal surfaces of the restoration were restored using composite resin (Tetric N-ceram; ivoclar Vivadent AG, USA) to achieve contact with neighboring teeth. The restoration was kept out of occlusion. Patients were scheduled for the definitive restoration after 3 months. Postoperative instructions of the immediate loading protocol were explained.

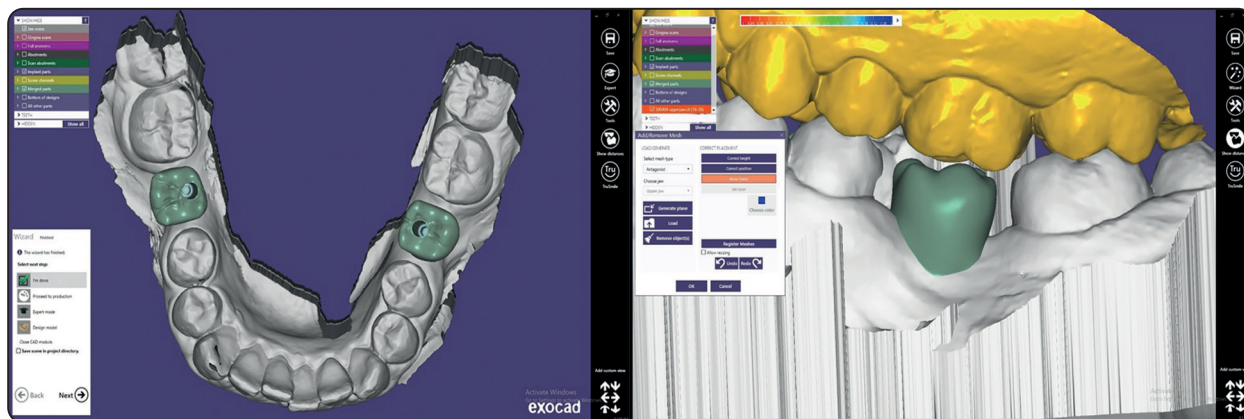


Fig. (3): The designed prefabricated crown.

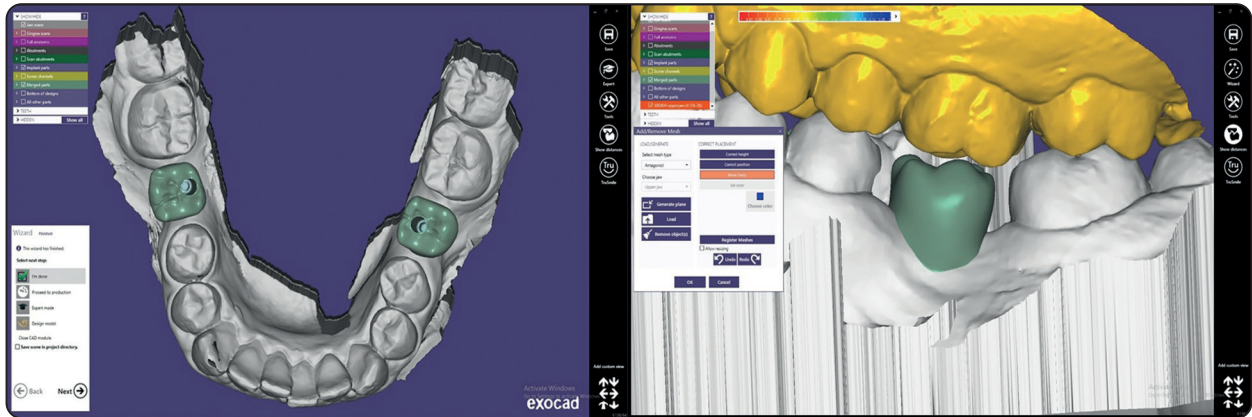


Fig. (4): The hex of the implant mount was aligned with that of the surgical guide.

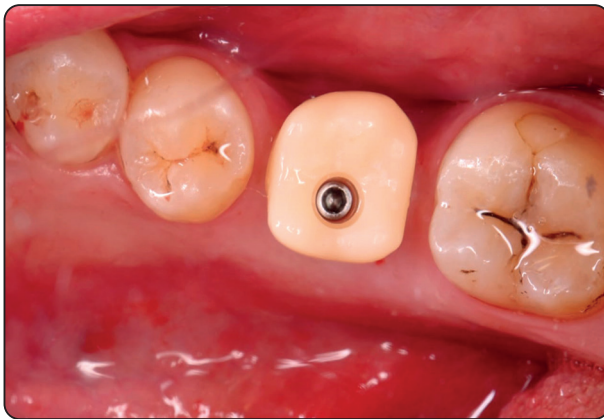


Fig. (5): The inserted restoration.

Outcome assessment

Using a 3D analysis software (GOM Inspect; GOM Co., Germany) the postoperative digital impression was superimposed on the STL file of the planned crown (Figure 6). The superimposition was performed for perfect matching of the natural neighboring teeth. It was obtained as follows. Initial alignment was made using “three-point” registration tool then “best fit alignment” function was performed for the final alignment. The STL file of the planned crown was exported to a CAD software (Autodesk Meshmixer; Autodesk Inc., USA) to isolate the planned crown. The isolated crown was saved as an STL file and imported into the 3D analysis software. On the planned crown, the axis of its screw channel was located (Figure 7) by

constructing a cylinder having the same direction of the screw channel and superimposed on it. The position of the axis of the cylinder was defined by locating the intersecting point of lines connecting between the corners of the hex.

On the axis of the constructed cylinder, two reference points were created (Figure 7); the first point (A) was located at the hex level at the level of the implant shoulder, the second point (B) was located at the occlusal level at the occlusal end of the screw channel. The planned crown with its accompanying constructions were duplicated (Figure 8) then the duplicated crown with its accompanied constructions were accurately superimposed on the inserted crown using “best fit alignment” function (Figure 9). The tip of the mesio-buccal cusp of the mandibular second molar was selected to be the origin of a customized coordinate system pointing to the bucco-lingual (BL), mesio-distal (MD) and Occluso-gingival (OG) directions (Figure 10).

The distances from the reference points on the planned and duplicated crowns (A, B, and corresponding duplicated points) to the planes of the customized coordinate system were measured. By subtracting the corresponding measurements, the linear deviations between the planned and the inserted crowns were defined at the hex and occlusal levels in the BL, MD, and OG directions (Figure 11). In addition, the vertical angular deviation

between the axes of the screw channels and the horizontal angular deviation between the hexes of the two crowns were defined.

Statistical Analysis

Normality was checked for all variables using descriptive statistics, plots, and normality tests. All data showed non-normal distribution, so non-parametric analysis was adopted. Descriptive statistics were calculated as means, standard deviation (SD), medians, and interquartile range

(IQR) for quantitative variables, in addition to frequencies (n) and percentages (%) for qualitative variables. Comparisons of linear deviation between the planned and inserted restorations at the hex and occlusal levels of the restorations were performed using Wilcoxon signed ranks test, while comparisons of the direction (B/L and M/D) were performed using McNemar test. Significance level was set at p value <0.05. Data were analyzed using IBM SPSS for Windows (Version 26.0)

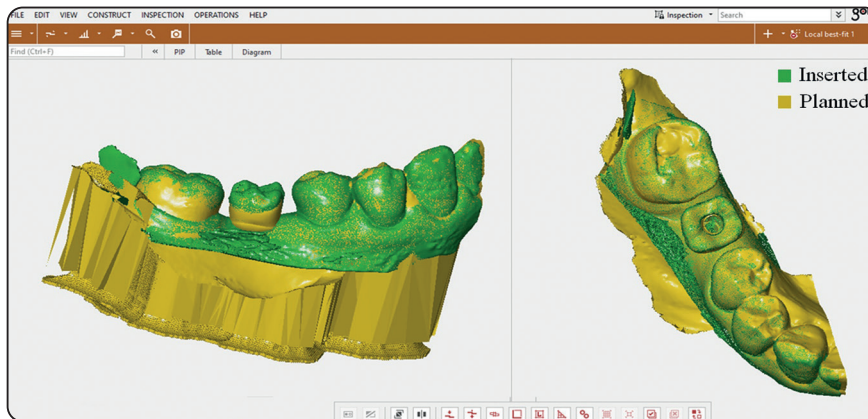


Fig. (6) Superimposed planned and inserted crowns.

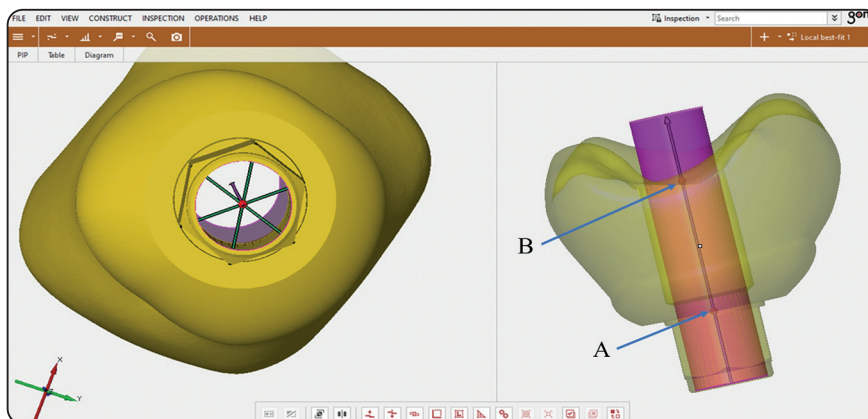


Fig. (7) Constructed cylinder for locating the axis of the screw channel with reference points (A) and (B).

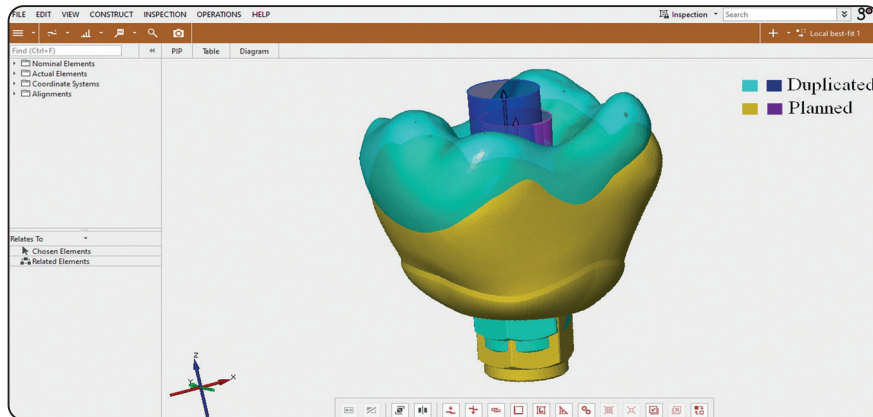


Fig. (8) Duplication of the planned crown with its constructions.

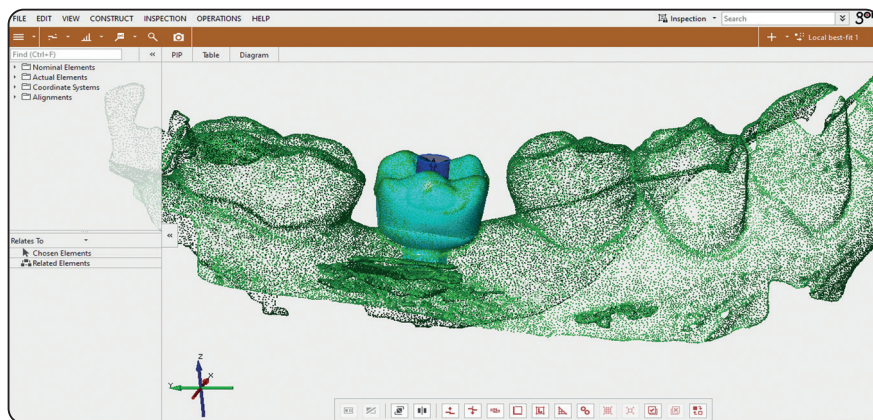


Fig. (9) Alignment of the duplicates with the inserted crown.

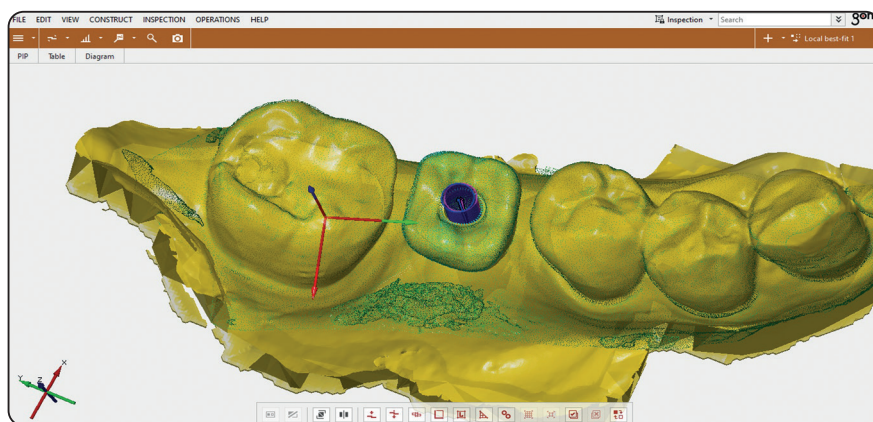


Fig. (10) The customized coordinate system.

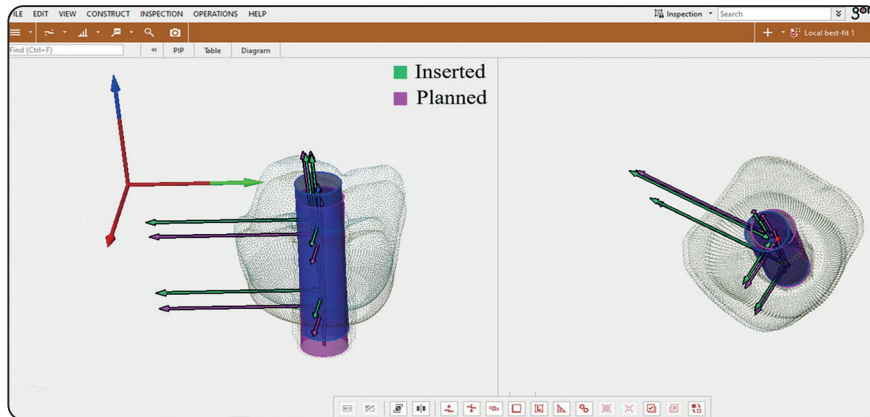


Fig. (11) The measured distances between the reference points and the planes of the customized coordinate system.

RESULTS

Table 1 shows the linear and angular deviations between the planned and inserted crowns. The linear horizontal deviations in the BL, MD and OG directions between the planned and inserted crowns at the hex level were higher than the deviations

at the occlusal level with significant difference in MD direction and non-significant difference in BL and OG direction but with significant difference in 3D. While the inserted crowns showed no tendency to deviate to either buccal or lingual directions, they had a clear tendency to deviate mesially. The vertical and horizontal angular deviations were low.

TABLE (1) Linear and angular deviations at the Hex and occlusal levels between the planned and inserted restorations

			Hex	Occlusal	P value
Linear deviations	BL	Mean (SD)	0.22 ± 0.15	0.17 ± 0.09	0.26
		Median (IQR)	0.20 (0.08, 0.33)	0.17 (0.10, 0.23)	
		B: n (%)	9 (60%)	7 (46.7%)	0.69
		L: n (%)	6 (40%)	8 (53.3%)	
	MD	Mean (SD)	0.31 ± 0.23	0.17 ± 0.08	0.04*
		Median (IQR)	0.23 (0.14, 0.52)	0.16 (0.09, 0.24)	
		M: n (%)	12 (80%)	10 (66.7%)	0.69
		D: n (%)	3 (20%)	5 (33.3%)	
	OC	Mean (SD)	0.46 ± 0.23	0.45 ± 0.22	0.59
		Median (IQR)	0.39 (0.30, 0.52)	0.40 (0.31, 0.52)	
3D	Mean (SD)	0.63 ± 0.29	0.53 ± 0.22	0.03*	
	Median (IQR)	0.63 (0.39, 0.93)	0.49 (0.36, 0.57)		
Angular deviations	H-angle	Mean (SD)		2.78 (1.38)	
		Median (IQR)		2.28 (1.65, 3.67)	
		BD: n (%)		9 (60%)	
		BM: n (%)		6 (40%)	
	V-angle	Mean (SD)		2.66 (1.54)	
		Median (IQR)		2.08 (1.28, 3.96)	

DISCUSSION

The null hypothesis was rejected based on the current study's findings, which showed that there were linear and angular deviations between the planned and inserted restorations at the occlusal and Hex levels.

Digital technology has taken dental implantology to a new level to cope with patient's demands and expectations. Nowadays, many hardware and software can allow a full digital workflow for designing prefabricated restorations for immediate loading of dental implants. The full digital workflow facilitates the construction of the prefabricated restorations as it eliminates the need of physical implant and abutment analogues, stone casts or 3D printed casts. It also saves much laboratory work and chairside time, reduces the human error and produces restorations with high dimensional accuracy ⁽¹⁰⁾.

The accuracy of the prefabricated restorations depends on two factors. The first factor is the accuracy of transferring the virtual implant planning to the cast on which the immediate restoration will be made. Compared to the other techniques ^(7,8), this factor was well controlled in the presented digital workflow as the virtual implant planning was transferred to the prosthesis-designing software using a virtual scan body which was accurately positioned by the implant-planning software. Consequently, the process was not affected by the errors resulting from technician skills or dimensional changes accompanying physical casts.

The second factor is the accuracy of transferring the virtual implant planning to the patient mouth. This factor is controlled by the accuracy of the surgical template and the clinician skills. In spite of the reported clinically acceptable accuracy of surgical templates, there are many sources of errors that can affect this accuracy ⁽¹⁸⁾. Errors may accompany the digital impression ⁽¹⁹⁾, aligning the CBCT with the digital cast, printing the surgical template ⁽²⁰⁾, sleeve-guide tolerance, seating the

metal sleeve into the surgical guide and stabilizing the guide intraorally prior to surgery. In addition, sleeve-drill tolerance and interference of the opposing dentition can deviate the final position of the implant ⁽²¹⁾.

Planning a prefabricated restoration for a single implant complicates the transfer of the virtual implant planning to the patient mouth as beside transferring the implant position in the dental arch, the direction of the implant hex should be accurately transferred. The direction of the hex affects the position of the proximal contacts of the crown with the neighboring teeth which may interfere with the proper seating and orientation of the crown.

For transferring the direction of the hex, the surgical template should reflect the direction of the hex of the planned implant. Meanwhile, the implant mount should reflect the direction of the hex of the implant being inserted. Therefore, aligning the implant mount with the surgical template will transfer the direction of the hex of the planned implant to the patient mouth. Considering these requirements, the used implant system provided a hexed implant mount and a matching hexed metal sleeve for the surgical template.

Throughout the present clinical trial, sources of inaccuracy were minimized as much as possible. Patients were selected to have a mouth opening of at least 40 mm. The accuracy of aligning the CBCT with the digital cast was checked through different axial and coronal cross-sections. The surgical templates were designed to be supported by at least four teeth ⁽²²⁾. The metal sleeves were checked to be fully seated into the surgical templates. The immediate restoration was milled using 5-axis milling machine (Arum 5X-200; Arum Europe GmbH, Germany) for high accuracy ⁽²³⁾. Intra-oral seating and stability of the surgical templates were checked prior to surgery. Meticulous effort was exerted for aligning the hex of the implant mount with that of the surgical template.

However, there was an inevitable error which yielded minor linear and angular deviations. This could be attributed to the inaccuracies accompanying the digital impression and the fabrication of the surgical template, sleeve-drill tolerance and the human errors during implant placement.

The linear deviations at the hex level were measured at the level of the implant shoulder so they can be related to the deviations of the implants at their entry point. In comparison with studies evaluating the accuracy of the surgical template⁽²⁴⁾ ⁽²⁶⁾ the reported mean linear deviation at the hex level was less than that of the implant at its entry point.

The reported horizontal angular deviation (2.78°) was much less than the angular deviation (6.94°) reported by Oh et al ⁽¹⁵⁾. The observation that can be attributed to the use of the hexed implant mount and the hexed metal sleeve which guided the clinician to transfer the direction of the hex of the planned implant to the patient mouth. While the vertical angular deviation (2.66°) was higher than that reported by Cristache and Gurbanescu ⁽²⁴⁾, it was lower than values reported by Smitkarn et al ⁽²⁵⁾, Tahmaseb et al ⁽¹⁸⁾ and Kaewsiri et al (2019) ⁽²⁷⁾.

CONCLUSION

Within the limitations of the current study, the prefabricated restorations made using the presented digital workflow may need minor clinical adjustments. Further clinical trials with larger sample size are recommended to support the obtained results.

CONFLICT OF INTEREST

The authors declare that they have no conflicts of interest.

Funding

The authors received no specific funding for this work.

Availability of data and materials

The study data are ready with the corresponding author when requested.

Authors' contributions

M.B.E., M.M.B., H.A.I., Y.A.T., N.A.A., M.M.K. and A.M.A. conceived the ideas; M.M.K. supervised prosthetic procedures; A.M.A. supervised surgical procedures; Y.A.T. and N.A.A. placed the dental implant; M.B.E. and H.A.I. underwent the evaluation and collected the data; M.M.B. analyzed the data; and M.M.K, M.B.E. and M.M.B led the writing.

REFERENCES

1. Chung, S., Mccullagh, A., & Irinakis, T. (2011). Immediate Loading in the Maxillary Arch: Evidence-Based Guidelines to Improve Success Rates: A Review. *J. Oral. Implantol.*, 37(5): 610-621. doi: 10.1563/aaid-d-joi-10-00058.1.
2. Harbi, S. A., and Edgin, W. A. (2007). Preservation of soft tissue contours with immediate screw-retained provisional implant crown. *J. Prosthet. Dent.*, 98(4): 329-332. doi: 10.1016/s0022-3913(07)60107-3.
3. Kan, J. Y. K., Rungcharassaeng, K., Deflorian, M., Weinstein, T., Wang, H.-L., & Testori, T. (2018). Immediate implant placement and provisionalization of maxillary anterior single implants. *Periodontol 2000.*, 77(1): 197-212. doi: 10.1111/prd.12212
4. Oh, K. C., Jeon, C., Park, J.M., & Shim, J. S. (2019). Digital workflow to provide an immediate interim restoration after single-implant placement by using a surgical guide and a matrix-positioning device. *J. Prosthet. Dent.*, 121(1): 17-21. doi: 10.1016/j.prosdent.2018.03.029.
5. Tselios, N., Parel, S. M., & Jones, J. D. (2006). Immediate placement and immediate provisional abutment modeling in anterior single-tooth implant restorations using a CAD/CAM application: A clinical report. *J. Prosthet. Dent.*, 95(3): 181-185. doi: 10.1016/j.prosdent.2006.01.014A1.
6. Vafiadis, D., Goldstein, G., Garber, D., Lambrakos, A., & Kowalski, B. (2016). Immediate Implant Placement of a Single Central Incisor Using a CAD/CAM Crown-Root Form Technique: Provisional to Final Restoration. *J. Esthet. Restor. Dent.*, 29(1), 13-21. doi: 10.1111/jerd.12265.
7. Arunyanak, S.P., Harris, B. T., Grant, G.T., Morton, D., Lin, W. S. (2016). Digital approach to planning computerguided surgery and immediate provisionalization in a partially edentulous patient. *J. Prosthet. Dent.*, 116(1): 8-14.
8. Barros, V.deM., Costa, N. R., Martins, P. H., Vasconcellos, W. A., Discacciati, J. A., & Moreira, A. N. (2015). Definitive Presurgical CAD/CAM-Guided Implant-

- Supported Crown in an Esthetic Area. *Braz. Dent J.*, 26(6): 695-700.
9. Block, M. S., Mercante, D. E., Lirette, D., Mohamed, W., Ryser, M., & Castellon, P. (2009). Prospective Evaluation of Immediate and Delayed Provisional Single Tooth Restorations. *J. Oral Maxillofac. Surg.*, 67(11): 89-107. doi: 10.1016/j.joms.2009.07.009.
 10. Dolcini, G. A., Colombo, M., & Mangano, C. (2016). From Guided Surgery to Final Prosthesis with a Fully Digital Procedure: A Prospective Clinical Study on 15 Partially Edentulous Patients. *Int. J. Dent.*, 2016:1-7. doi: 10.1155/2016/735842.
 11. Proussaefs, P. (2016). A Novel Technique for Immediate Loading Single Root Form Implants with an Interim CAD/CAM Milled Screw-Retained Crown. *J. Oral. Implantol.*, 42(4): 327-332. doi: 10.1563/aaid-joi-d-15-00087.
 12. Barone, A., Rispoli, L., Voza, I., Quaranta, A., & Covani, U. (2006). Immediate Restoration of Single Implants Placed Immediately After Tooth Extraction. *J Periodontol.*, 77(11): 1914-1920. doi: 10.1902/jop.2006.060072.
 13. Weerapong, K., Sirimongkolwattana, S., Sastraruji, T., & Khongkhunthian, P. (2019). Comparative Study of Immediate Loading on Short Dental Implants and Conventional Dental Implants in the Posterior Mandible: A Randomized Clinical Trial. *Int. J. Oral. Maxillofac. Implants.*, 34(1): 141-149. doi: 10.11607/jomi.6732.
 14. Aparicio, C., Rangert, B., & Sennerby, L. (2003). Immediate/Early Loading of Dental Implants: a Report from the Sociedad Espanola de Implantes World Congress Consensus Meeting in Barcelona, Spain, 2002. *Clin. Implant. Dent. Relat. Res.*, 5(1): 57-60. doi: 10.1111/j.1708-8208.2003.tb00183.x.
 15. Oh, K. C., Kim, J.H., Woo, C.W., & Moon, H. S. (2019). Accuracy of Customized Prefabricated Screw-Type Immediate Provisional Restorations after Single-Implant Placement. *J.Clin.Med.*, 8(4): 490. doi: 10.3390/jcm8040490.
 16. Zhang, Y., Tian, J., Wei, D., Di, P., & Lin, Y. (2019). Quantitative clinical adjustment analysis of posterior single implant crown in a chairside digital workflow: A randomized controlled trial. *Clin. Oral. Implants. Res.*, 30(11): 1059-1066. doi: 10.1111/clr.13519.
 17. Dworkin, S.F., and LeResche, L. (1992) Research diagnostic criteria for temporomandibular disorders: review, criteria, examinations and specifications, critique. *J Craniomandib Disord.*, 6(4): 301-355.
 18. Tahmaseb, A., Wu, V., Wismeijer, D., Coucke, W., & Evans, C. (2018). The accuracy of static computer-aided implant surgery: A systematic review and meta-analysis. *Clin. Oral. Implants. Res.*, 29(S16): 416-435. doi: 10.1111/clr.13346.
 19. Gjelvold, B., Chrcanovic, B. R., Korduner, E. K., Collin-Bagewitz, I., & Kisch, J. (2015). Intraoral Digital Impression Technique Compared to Conventional Impression Technique. A Randomized Clinical Trial. *J. Prosthodont.*, 25(4): 282-287. doi: 10.1111/jopr.12410.
 20. Gjelvold, B., Mahmood, D. J. H., & Wennerberg, A. (2019). Accuracy of surgical guides from 2 different desktop 3D printers for computed tomography-guided surgery. *J. Prosthet. Dent.*, 121(3):498-503. <https://doi.org/10.1016/j.prosdent.2018.08.009>
 21. Cassetta, M., Di Mambro, A., Giansanti, M., Stefanelli, L. V., & Cavallini, C. (2013). The intrinsic error of a stereolithographic surgical template in implant guided surgery. *Int. J. Oral. Maxillofac. Surg.*, 42(2): 264-275. <https://doi.org/10.1016/j.ijom.2012.06.010>
 22. El Kholly, K., Lazarin, R., Janner, S. F. M., Faerber, K., Buser, R., & Buser, D. (2019). Influence of surgical guide support and implant site location on accuracy of static Computer-Assisted Implant Surgery. *Clin. Oral. Implants. Res.*, 30(11):1067-1075. <https://doi.org/10.1111/clr.13520>
 23. Bosch, G., Ender, A., & Mehl, A. (2014). A 3-dimensional accuracy analysis of chairside CAD/CAM milling processes. *J. Prosthet. Dent.*, 112(6): 1425-1431. doi: 10.1016/j.prosdent.2014.05.012.
 24. Cristache, C. M., and Gurbanescu, S. (2017). Accuracy Evaluation of a Stereolithographic Surgical Template for Dental Implant Insertion Using 3D Superimposition Protocol. *Int. J. Dent.*, 2017: 1-9. doi: 10.1155/2017/4292081.
 25. Smitkarn, P., Subbalekha, K., Mattheos, N., & Pimkhaokham, A. (2019). The accuracy of single-tooth implants placed using fully digital-guided surgery and freehand implant surgery. *J. Clin. Periodontol.*, 46(9): 949-957. doi: 10.1111/jcpe.13160.
 26. Tahmaseb, A., Wismeijer, D., Coucke, W., & Derksen, W. (2014). Computer Technology Applications in Surgical Implant Dentistry: A Systematic Review. *Int. J. Oral. Maxillofac. Implants.*, 29(Suppl): 25-42. doi: 10.11607/jomi.2014suppl.g1.2.
 27. Kaewsiri, D., Panmekiate, S., Subbalekha, K., Mattheos, N., & Pimkhaokham, A. (2019). The accuracy of static vs. dynamic computer-assisted implant surgery in single tooth space: A randomized controlled trial. *Clin Oral Implants Res.*, 30(6): 505-514. doi: 10.1111/clr.13435.