

CLINICAL AND RADIOGRAPHIC EVALUATION OF SECTIONAL VERSUS CIRCUMFERENTIAL MATRIX SYSTEMS: A ONE-YEAR RANDOMIZED CLINICAL TRIAL

Monaliza Maher Abdelaziz*^{ID}, Shereen Essameldein Fahim*^{ID}
and Ahmed Gamal Abdelwahed*^{ID}

ABSTRACT

Aim: To evaluate clinically and radiographically the performance of two sectional matrix systems (TOR VM 1.398 and Composit-Tight 3D Fusion™) versus one circumferential matrix system (Tofflemire system) for 12 months.

Materials and methods: 39 class II cavities were prepared. The teeth were equally divided into three groups (n=13) according to the type of applied matrix system: Group 1: TOR VM (TOR VM dental manufacturing company, Russia), Group 2: Composit-Tight 3D Fusion™ (Garrison Dental Solutions, USA), Group 3: Tofflemire Matrix Retainer Universal (Produits Dentaires S.A., Switzerland). All teeth were restored using bulk-fill resin composite (X-tra fil, Voco, Germany). The restorations were evaluated clinically and radiographically at baseline, 6-, and 12-month. The proximal contacts were categorized following the FDI recommendations as optimum, tight, or open. The proximal overhangs were assessed using digital bitewing radiographs. The proximal overhangs were categorized as absent, positive, or negative. Data were analyzed using the chi-square test, followed by multiple z-tests with Bonferroni correction.

Results: The Tofflemire matrix retainer group showed higher percentages of restorations with tight or open contacts in comparison to other groups, but the difference was not statistically significant ($p > 0.05$). The percentages of restorations free of overhangs in TOR VM and Composit-Tight 3D Fusion™ were found to be significantly higher than that of the Tofflemire matrix retainer group ($p < 0.001$).

Conclusions: The restorations placed with TOR VM and Composit-Tight 3D Fusion™ showed proximal contacts with optimum tightness and contour as compared to the circumferential matrix system.

KEYWORD: Sectional matrix, Circumferential matrix, Contact tightness, Proximal overhang

* Lecturer, Conservative Dentistry Department, Faculty of Dentistry, October 6 University.

INTRODUCTION

The longevity of posterior restorations necessitates proper restoration of tooth form and anatomy^[1]. Restoring proper anatomical proximal contour and tight interproximal contact represent great challenges facing most clinicians during the restoration of class II cavities^[2, 3]. To establish correct proximal geometry, the proximal contour of a class II restoration should resemble that of the sound tooth^[4]. The restoration of ideal contact and contour minimizes food impaction, protects the interdental gingival papilla, preserves a healthy periodontium, and stabilizes the dental arch by maintaining the normal mesiodistal relationship between teeth^[1, 5]. Improper proximal contact or contour is associated with malaligned teeth, leading to food lodgment, which can cause halitosis, initiation of dental caries, and periodontal diseases^[6-11]. Clinically, obvious inter and intra individual variations in the tightness of proximal contact were observed^[4]. It was also noticed that restoring proximal cavities is associated with changes in the tightness of proximal contact^[12].

Over the previous three decades, noticeable improvements in armamentarium and dental material formulations and clinical procedures have been made, particularly in the restoration of posterior teeth with aesthetic, tooth-like restorative materials^[9, 11, 13]. The usage of dental amalgam restorations is steadily decreasing due to the public's increased desire for a beautiful smile as well as concerns about mercury's potential health and environmental side effects. As a result, resin composite has surpassed dental amalgam as the preferred posterior restorative material^[14, 15].

One of the main challenges in class II resin composite restorations is regaining the proper tightness of proximal contact. This difficulty is attributed to several factors, including the application of rubber dam, the elasticity and thickness of the matrix band, the incondensability of resin composites, and the volumetric shrinkage occurring during polymerization^[2, 4, 5, 16-18]. Several

techniques and instruments, such as separation rings, precontoured matrix bands, and high-viscosity resin composites, were investigated to provide adequate proximal contact and contour^[2, 6, 18-20]. Among these techniques, the type of matrix was reported to be the most important factor^[21, 22].

A dental matrix band is a piece of metal or non-metal that serves as a temporary wall to provide support and give form to the restorative material during insertion until the hardening of the restoration. Dental matrix systems are categorized according to the type of matrix band and the technique of application^[9]. There are a wide variety of matrix systems on the market that are designed for posterior direct resin composite restorations. The two most frequently used are the circumferential and sectional matrix systems^[23, 24]. In 1871, the circumferential matrix band was first introduced by Dr. Louis Jack. Following the Jack matrix, different systems were introduced^[9]. In 1946, Dr. Joseph Tofflemire developed the Tofflemire retainer and band, which are still used today^[25]. Circumferential matrix systems are easy to use and time-saving^[26], but they usually recreate a single point of contact rather than an area and fail to reproduce proper contact tightness and position^[10, 27]. To solve these problems, sectional matrix systems were developed. They were reported to favor the reproduction of a more physiologic contact, reduce food lodgment, and reduce the possibility of caries, periodontal diseases, and marginal ridge fracture^[28]. Despite these proved advantages, the use of sectional matrices is not widely adopted among practitioners due to a lack of enough training to use them, in addition to concerns regarding more time consumption, increased cost, and increased risk of band distortion during application^[23, 29]. Therefore, surveys have revealed that the Tofflemire system is still used more than the sectional matrix systems with direct class II resin composite restorations, even in developed countries^[29, 30].

Although new sectional matrix systems are constantly being introduced, little evidence is

available to suggest that one system is superior to the others. A recent survey reported that 54% of Egyptian dentists preferred to use the TOR VM system (Moscow, Russia) mainly due to its relatively low cost in comparison to other available systems, while only 20% of them used the Composi-Tight (Garrison Dental Solutions, Michigan, USA) [31]. Therefore, the current study evaluated clinically and radiographically the performance of two sectional matrix systems (TOR VM 1.398 and Composi-Tight 3D Fusion™) versus one circumferential matrix system (Tofflemire system) for 12 months. The two tested null hypotheses were that (1) there would be no differences in the tightness of proximal contact and proximal contour between the three matrix systems and (2) no changes would occur over a one-year evaluation period.

METHODS

This randomized controlled clinical trial involved a parallel, single-blinded, prospective, three-arm, with 1:1:1 allocation ratio study design. This trial was performed in the clinic of the Conservative Dentistry Department, Faculty of Dentistry, October 6 University, between December 7, 2021, and January 24, 2023, after obtaining ethical approval from the Research Ethics Committee at Faculty of Dentistry, October 6 University, on October 2, 2021 (Approval No. RECO6U/9-2021). The study was registered at the Pan African Clinical Trials Registry (PACTR). The registration was approved on 29/11/2021 with identification number PAC-TR202111664034062.

A power analysis was designed to have adequate power to apply a statistical test of the null hypothesis that there would be no difference between tested groups regarding proximal contact tightness. By adopting an alpha level of (0.05) a beta level of (0.2) i.e., power = 80% and an effect size (W) of (0.800) calculated based on the results of a previous study [32], the predicted sample size (n) was found to be a total of 30 participants (i.e. 10 participants per group). Sample size was increased by 25% to

account for possible dropouts during follow-up intervals to be 39 participants (i.e., 13 participants per group). Sample size calculation was performed using Power Analysis and Sample Size Software (PASS 15, NCSS, LLC. Kaysville, Utah, USA).

Patients with compound class II (OM or OD) supragingival lesions not extending more than 1/3 of the intercuspal distance were recruited to participate in this study. Patients included in the study were of at least 18 years of age with fully erupted occluding permeant posterior teeth having contact with adjacent teeth; however, patients with complex class II lesions, crowding or spacing, tooth mobility, or any signs of periodontal diseases were excluded. A total of 87 compound class II cavities were primarily screened for eligibility for this trial. 48 of these cavities were excluded for different reasons: 18 cavities were due to periodontal reasons; 13 cavities were deep or had signs of pulp involvement; in 7 cavities, the adjacent proximal surfaces were restored; 6 cavities, their patients refused to participate in the study; and in 4 cavities, there were spaces with adjacent teeth. The patients who fulfilled the eligibility criteria were enrolled in the study after obtaining their written informed consent, and they were able to withdraw from the trial at any time of evaluation without justification. A consort flow chart presents the flow of participants through each stage of the study (Fig. 1).

The enrolled participants were randomly divided into three groups using the simple randomization technique by generating numbers from 1:39 using RANDOM.ORG (<https://www.random.org/>) into three columns. The participants obtained random numbers from a sealed, opaque envelope. The operator and participants could not be blinded to the matrix system assignment due to the different application procedures of matrix systems; however, the outcome assessors were blinded. All restorations were performed by a single operator (M.M.A.) with 15 years of clinical experience and well-trained in applying sectional matrix systems. The operator was not involved in the following clinical and radiographic assessments.

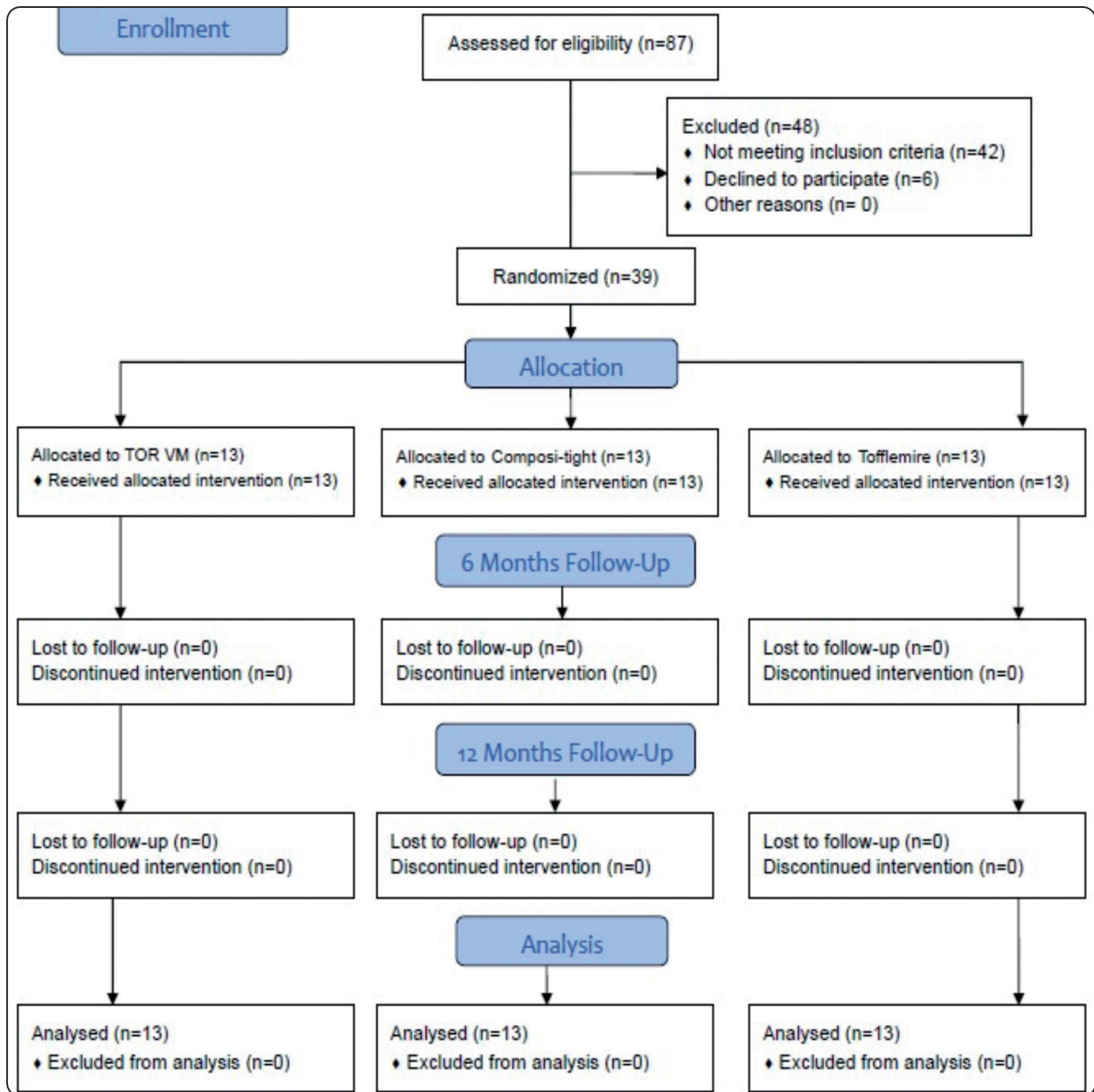


Fig. (1) Consort flow chart of the study

Local anesthesia (Artapharmdent 4%, Artpharma Egypt Pharmaceuticals, 6th of October city, Egypt) was administrated. Rubber dam was used for isolation of the entire quadrant containing the carious tooth. Cavities were prepared using a high-speed handpiece (T3 Racer, Dentsply Sirona, NA, USA) with a diamond fissure bur (ökoDENT, ökoDENT GmbH & Co KG, Lindenweg, Germany). All cavity preparations followed a conservative

design, restricted to carious tissue, and undermined tooth structure removal. After completing the preparation, the cavities were randomly assigned to one of the three matrix systems:

Group 1: TOR VM 1.398 (TOR VM dental manufacturing company, Moscow, Russia) and hard stainless steel sectional metal matrix with 0.050 mm thickness.

Group 2: Composit-Tight 3D Fusion™ (Garrison Dental Solutions, Michigan, USA) and soft stainless steel sectional metal matrix with 0.038 mm thickness.

Group 3: Tofflemire Matrix Retainer Universal (Produits Dentaires S.A., Vevey, Switzerland) and circumferential matrix band with 0.05mm thickness.

Wooden wedges were used in groups 1 and 3 while Composit-Tight® 3D Fusion™ interproximal wedges were used in group 2 to secure the matrices properly in place prior to restorative procedures.

In very deep cavities, a calcium hydroxide liner (Dycal®, Dentsply Sirona, NA, USA) was applied. The enamel margins of the prepared cavities were etched for 15 seconds using 37% phosphoric acid (GEL ETCHANT™, jk Dental Vision, Daqahliyah, Egypt). A universal adhesive system (Futurabond M+, Voco, Cuxhaven, Germany) was applied for 20 seconds and light-cured for 10 seconds using Premium Plus™ LED light curing unit (Premium Plus Dental Supplies Inc., NY, USA) at a light intensity of 1200 mW/cm². All preparations were restored using a packable bulk-fill resin composite (X-tra fil, Voco, Cuxhaven, Germany), which was light-cured for 20 seconds at a light intensity of 1400 mW/cm². Restorations were finished under water cooling with fine-grit diamond burs (ökoDENT, ökoDENT GmbH & Co KG, Lindenweg, Germany) and polished by polishing discs (Sof-Lex, 3 M, MN, US).

Two calibrated assessors (A.G.A. and S.E.F.), who were blinded about the type of matrix system, independently evaluated the restorations clinically and radiographically at baseline, 6-, and 12-month. When the two assessors disagreed, they evaluated the restorations together until a consensus rating was determined. Waxed dental floss (Oral-B, Procter and Gamble, New Cairo, Egypt) was used to examine the tightness of the interproximal contact area while the participants were sitting in a standardized seating position according to the

method described in previous studies [14, 33, 34]. The interproximal contacts were categorized following the FDI recommendations as optimum, tight, or open [35]. An optimum interproximal contact was categorized if dental floss could be passed with either little resistance or resistance equal to that of the natural teeth on the opposing side. If dental floss was unable to pass at all or shredded, the interproximal contact was categorized as tight. If the dental floss was allowed to pass without resistance, the interproximal contact was considered optimum contact [32, 36].

The proximal overhangs of restorations were examined using digital bitewing radiographs. All radiographs were taken using (xgenus® dc, de Götzen S.r.l. a socio unico, VA, Italy) and processed by (Sordex DIGORA® Optime, KaVo, NC, USA). To standardize the radiographs taken at different evaluation periods, a paralleling film holder kit (Ean-Hu™ XCP ds-fs) was used. The proximal overhangs were categorized as absent, positive, or negative. If there was a smooth transition of restoration and tooth surface at the proximal step, it was categorized as an absent overhang. Positive overhang was classified if an excess of restoration extended beyond the cavity margin at the proximal step. On the other hand, if the restoration was found short of the cavity margin at the proximal step of the restoration, it was categorized as a negative overhang [14, 36]. Inter-examiner agreement was calculated using the Kappa coefficient which revealed an agreement of 0.86 between the two assessors which reflected almost an excellent agreement.

Categorical data were presented as frequency and percentage values. They were analyzed using the chi-square test, followed by multiple z-tests with Bonferroni correction for intergroup comparisons and generalized estimating equation modelling for intragroup comparisons. Statistical analysis was performed with R statistical analysis software version 4.3.1 for Windows (R Core Team 2023).

RESULTS

A total of thirty-nine restorations were placed in the prepared cavities of thirty-two participants. Twenty-six participants had one restoration, five participants had two restorations, and one participant had three restorations. For participants who had more than one eligible cavity, each restoration was placed at a separate visit. All participants attended the 6- and 12-month evaluations. The participants were twenty-one females (restorations = 28) and eleven males (restorations = 11), with an age range of 19–43 years (median age was 26.7 years). The distribution of the restorations according to the type

of tooth and arch was presented in (Table 1).

Results of clinical evaluation

Results of inter- and intragroup comparisons for interproximal contact tightness are presented in (Table 2 and Fig. 2). Within all intervals, the Tofflemire Matrix Retainer group had higher percentages of restorations with tight or open contacts in comparison to other groups, yet the difference was not statistically significant ($p>0.05$). Within all groups, there was no significant difference between proximal contact status at different intervals ($p>0.05$).

TABLE (1) Distribution of restorations in different groups

	Maxillary		Mandibular	
	Premolars	Molars	Premolars	Molars
TOR VM	2	4	2	5
Composi-Tight 3D Fusion™	2	3	2	6
Tofflemire Matrix Retainer	0	4	3	6

TABLE (2) Inter- and intragroup comparison of proximal contact tightness

Time	Proximal contact	n (%)			χ^2	p-value
		TOR VM	Composi-Tight 3D Fusion™	Tofflemire Matrix Retainer		
Baseline	Optimum	11 (84.62%)	12 (92.31%)	6 (46.15%)	9.39	0.052
	Tight	2 (15.38%)	1 (7.69%)	5 (38.46%)		
	Open	0 (0.00%)	0 (0.00%)	2 (15.38%)		
6 months	Optimum	11 (84.62%)	12 (92.31%)	6 (46.15%)	9.39	0.052
	Tight	2 (15.38%)	1 (7.69%)	5 (38.46%)		
	Open	0 (0.00%)	0 (0.00%)	2 (15.38%)		
12 months	Optimum	11 (84.62%)	12 (92.31%)	8 (61.54%)	4.44	0.350
	Tight	1 (7.69%)	1 (7.69%)	3 (23.08%)		
	Open	1 (7.69%)	0 (0.00%)	2 (15.38%)		
χ^2		0.19	0.00	0.38		
p-value		0.908	1	0.828		

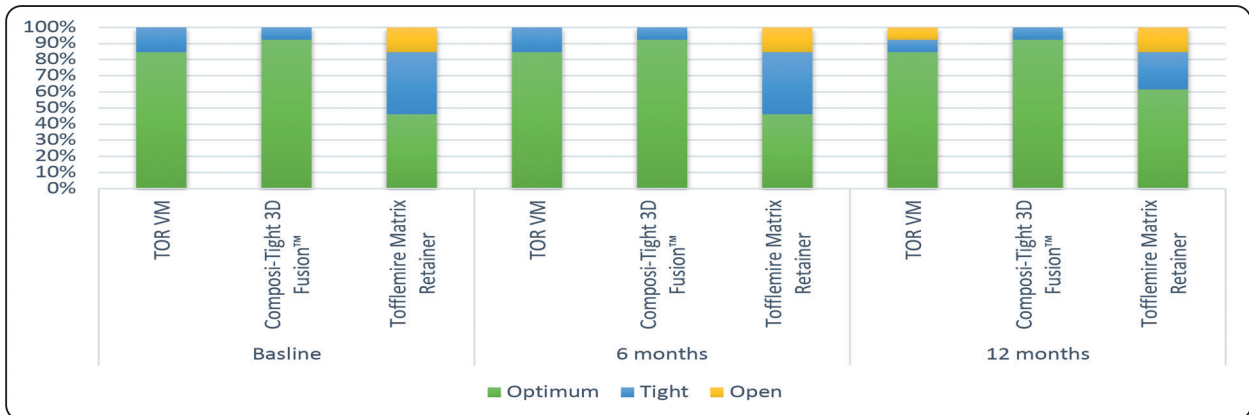
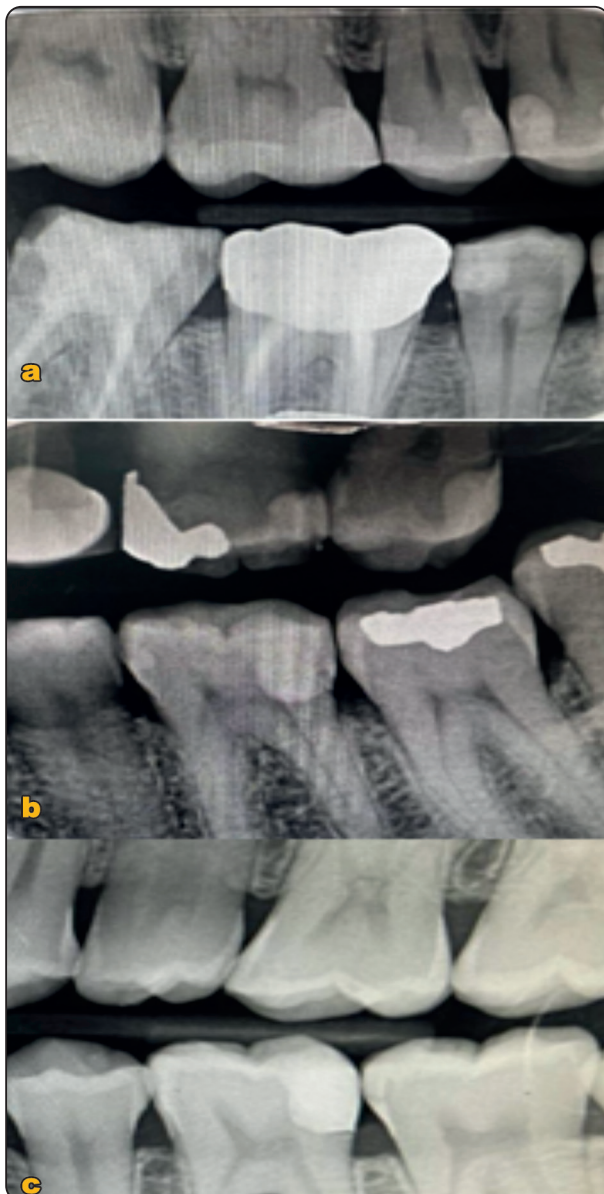

Fig. (2) Stacked bar chart showing proximal contact tightness



Results of radiographic assessment

The proximal overhangs were categorized as absent, positive, or negative (Fig. 3). Results of inter- and intragroup comparisons for radiographic overhangs are presented in (Table 3 and Fig. 4). Within all intervals, there was a significant difference between the tested groups ($p < 0.05$). At all intervals, post hoc pairwise comparisons showed the percentages of restorations free of overhangs in TOR VM and Composi-Tight 3D Fusion™ to be significantly higher than that of the Tofflemire Matrix Retainer group ($p < 0.001$).

Fig. (3) Representative radiographs showing examples of proximal overhang categories: a) absent overhang in the restoration in the distal surface of tooth 45; b) positive overhang in the restoration in the mesial surface of tooth 26; c) negative overhang in the restoration in the distal surface of tooth 36

TABLE (3) Inter and intragroup comparison of radiographic overhangs.

Time	Radiographic overhangs	n (%)			χ^2	p-value
		TOR VM	Composi-Tight 3D Fusion™	Tofflemire Matrix Retainer		
Baseline	Absent	13 (100.00%) ^A	13 (100.00%) ^A	7 (53.85%) ^B	14.18	0.007*
	Positive	0 (0.00%) ^A	0 (0.00%) ^A	4 (30.77%) ^A		
	Negative	0 (0.00%) ^A	0 (0.00%) ^A	2 (15.38%) ^A		
6 months	Absent	13 (100.00%) ^A	13 (100.00%) ^A	6 (46.15%) ^B	17.06	0.006*
	Positive	0 (0.00%) ^A	0 (0.00%) ^A	5 (38.46%) ^B		
	Negative	0 (0.00%) ^A	0 (0.00%) ^A	2 (15.38%) ^A		
12 months	Absent	13 (100.00%) ^A	13 (100.00%) ^A	8 (61.54%) ^B	11.47	0.022*
	Positive	0 (0.00%) ^A	0 (0.00%) ^A	3 (23.08%) ^A		
	Negative	0 (0.00%) ^A	0 (0.00%) ^A	2 (15.38%) ^A		
χ^2		NA	NA	0.29		
p-value		NA	NA	0.867		

NA: Not applicable, values with different superscript letters within the same horizontal rows are significantly different, *Significant (p<0.05).

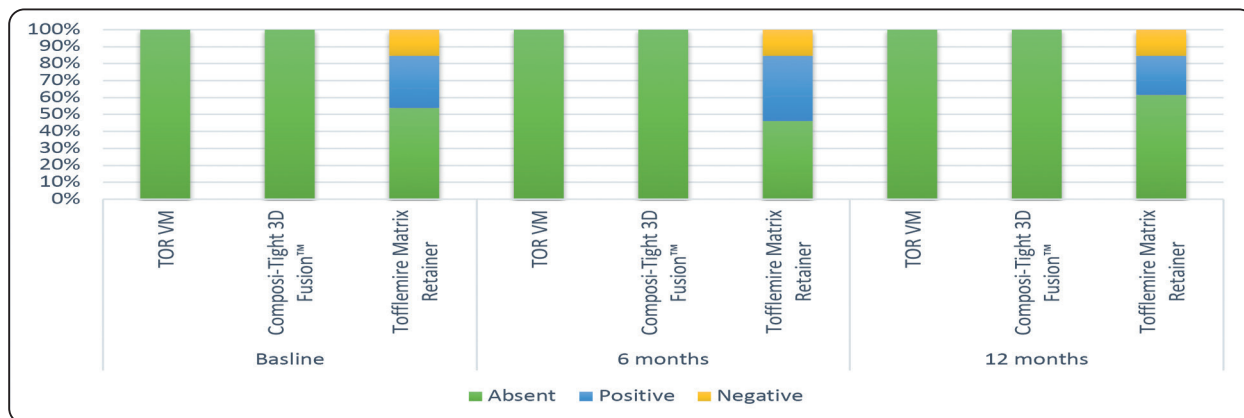


Fig. (4) Stacked bar chart showing radiographic overhangs

DISCUSSION

The longevity of resin composite restorations was reported to be related to the clinician’s skills in addition to the qualities of the restorative material and the restorative technique [37]. Regaining proper proximal anatomy and contour is the key to the success of direct posterior resin composite restoration. The

correlation between the type of matrix system and the reproduction of correct proximal contact has been reported in several studies [14,28,32]. However, to the best of our knowledge, this study is the first randomized clinical trial to evaluate clinically and radiographically two sectional matrix systems in comparison to one circumferential matrix system over a 12-month evaluation period.

Randomized controlled clinical trials have been identified as the best evidence in the evaluation of new dental materials and techniques. However, confounding variables related to the participants and the operator may affect the validity of the obtained results^[38]. To control these confounding variables in this clinical trial, all the restorations were placed by the same operator. To extrapolate the results, posterior teeth from both arches were included with no restrictions regarding the location of the proximal restoration, either mesial or distal, because it was found to have no significant effect on whether the proximal contact was correct or not in previous studies^[27, 39]. Operative field isolation was done using a rubber dam because it is regarded as the standard of restorative treatment and was reported to be associated with achieving proper proximal contact tightness^[14].

The tightness of the interproximal contact can be evaluated objectively in clinical trials using devices measuring the contact strength, but such devices are not commercially available^[40]. The subjective evaluation, according to FDI recommendations, can be done with metal blades or dental floss, with the latter being the most commonly used method. Therefore, waxed dental floss was used in this study^[35,41,42]. Bitewing radiographs were used because they are the most valid and common tool for the radiographic evaluation of restorations^[40,43].

The results of the present study revealed that the restorations placed with sectional matrix systems showed more optimum interproximal contacts than circumferential matrix system, which resulted in more tight and open proximal contacts. These results are in line with those reported in previous studies^[14,32,44]. The superior contact tightness obtained by the sectional matrix systems could be attributed to two possible reasons: the use of a separation ring and the thickness of the matrix band. The pre-restoration separation of teeth is done to facilitate accessibility to the prepared

cavity and simplify the sculpting, finishing, and polishing of the restoration^[9]. Several in vitro and clinical studies^[6,39,45,46] have confirmed that the use of interdental separation rings is associated with obtaining compound proximal resin composite restorations with interproximal contacts having optimum tightness and contours. The application of a separation ring allows tooth separation of 100-200 μm . This created space compensates for matrix band thickness, the polymerization shrinkage of resin composite, and the negative effects of rubber dam application^[4,47]. Chuang et al.^[6] emphasized the influence of matrix band thickness on the contact tightness of the proximal resin composite restorations. Optimum contact tightness was more frequently achieved with matrix bands with less thickness^[46]. In this study, the Composit-Tight 3D Fusion™ group with less matrix band thickness (0.38 mm) showed more optimum contacts than the Tofflemire matrix group, which has greater thickness (0.50 mm). However, the TOR VM group showed more optimum contacts than the Tofflemire matrix group, although they have the same matrix thickness (0.50 mm). In addition, no differences were recorded between the two sectional matrix systems, TOR VM and Composit-Tight 3D Fusion™ despite having different thicknesses (0.050 mm and 0.38 mm), respectively. Therefore, it seems that the optimum contacts achieved by sectional matrix systems are due to the action of the separation ring rather than the thickness of matrix band.

The open proximal contacts reported in 15.38% of the restorations in the circumferential matrix group could be attributed to a lack of sufficient movement of the neighboring tooth caused by the placement of a wooden wedge and a flat matrix band^[48]. A wooden wedge swells when exposed to moisture in the oral environment, which was thought to aid with interdental separation and cervical adaptation of the matrix band. Unfortunately, oral fluids absorption by a wooden wedge makes it fragile and flexible, leading to reduced interdental separation^[49]. On the

other hand, tight proximal contacts were recorded in 38.46% of the restorations in the circumferential matrix group. These tight proximal contacts were located more occlusally, preventing the passage of dental floss or causing its tear^[46].

For all groups, no differences were recorded between the results of baseline and 6-month evaluations. After 12 months, one restoration (7.69%) in the TOR VM group was reported to have open contact. In the Tofflemire matrix group, more optimum contacts (61.54%) and less tight contacts (23.08%) were observed, while no change was recorded in open contacts (15.38%). It was reported that the tightness of proximal contact did not remain stable because it is expected to change over time as a result of proximal wear and the continuing mesial movement of the teeth^[12, 40]. Consequently, an interproximal contact with increased tightness tends to be more loose over time^[2]. The same findings were reported by Loomans et al.^[12] and Wirsching et al.^[28], who confirmed that tight contacts tend to loosen in contrast to loose contacts, which are not changed.

Besides the clinical evaluation of the proximal contact, the proximal contour of the restorations was evaluated radiographically because it is possible that the proximal contour may be defective, although the proximal contact is good, and vice versa. A faulty proximal contour can cause plaque accumulation and the initiation of carious lesions [35]. All the restorations placed using sectional matrix systems showed the absence of proximal overhangs, contrary to the restorations in the Tofflemire matrix group, which showed the presence of positive and negative overhangs. The reason behind these significant differences may be due to the close adaptation and intimate contact between the sectional matrix band and the proximal tooth surface due to the action of the separation ring and the wedge^[44, 50, 51]. It should be noted that the absence of proximal overhangs in the restorations placed with sectional matrix systems

was correlated with the optimum contact tightness observed clinically. However, tight contact was observed in the TOR VM (15.38%) and Composit-Tight 3D Fusion™ (7.69%) groups.

Based on the obtained results, the two null hypotheses were rejected. However, this study had some limitations that should be considered. The restorations were evaluated for 12 months. Extending evaluation periods may reveal different findings. Only two sectional matrix systems were assessed, although plenty of sectional matrix systems are commercially available, so assessments of other systems can help to generalize the findings obtained from this study.

CONCLUSIONS

The use of sectional matrices with separation rings for class II resin composite restorations produced proximal contacts with optimum tightness and contour as compared to the use of a circumferential matrix system. However, all matrix systems produced some deficiencies. The proximal contact tightness was subjected to change over time. The TOR VM sectional matrix system can be an effective alternative to the Composit-Tight 3D Fusion™ system.

REFERENCES

1. Urkande NK, Mankar N, Nikhade PP, Chandak M, Ikhar A, Patel A. Anterior Matrix Systems for Composite Restorations: A Review. *Cureus*. 2023;15:e37145.
2. Saber MH, Bac L, El Zohairy A, Dörfer CE, El-Badrawy W. Evaluation of proximal contact tightness of class II resin composite restorations. *Oper Dent*. 2010;35:37–43.
3. Saber MH, El-Badrawy W, Loomans BAC, Ahmed DR, Dörfer CE, El Zohairy A. Creating tight proximal contacts for mod resin composite restorations. *Oper Dent*. 2011;36:304–10.
4. Peumans M, Venuti P, Politano G, Van Meerbeek B. Effective Protocol for Daily High-quality Direct Posterior Composite Restorations. The Interdental Anatomy of the Class-2 Composite Restoration. *J Adhes Dent*. 2021;23:21–34.

5. Keogh TP, Bertolotti RL. Creating tight, anatomically correct interproximal contacts. *Dent Clin North Am.* 2001;45:83–102.
6. Chuang SF, Su KC, Wang CH, Chang CH. Morphological analysis of proximal contacts in class II direct restorations with 3D image reconstruction. *J Dent.* 2011;39:448–56.
7. Deepak S, Nivedhitha MS. Proximal contact tightness between two different restorative materials - An in vitro study. *J Adv Pharm Educ Res.* 2017;7:153–5.
8. Dörfer CE, Von Bethlenfalvy ER, Staehle HJ, Pioch T. Factors influencing proximal dental contact strengths. *Eur J Oral Sci.* 2000;108:368–77.
9. Owens BM, Phebus DDSJG. An evidence-based review of dental matrix systems. *Gen Dent.* 2016;64:64–70.
10. Kampouropoulos D, Paximada C, Loukidis M, Kakabourra A. The influence of matrix type on the proximal contact in class II resin composite restorations. *Oper Dent.* 2010;35:454–62.
11. Raghu R, Srinivasan R. Optimizing tooth form with direct posterior composite restorations. *J Conserv Dent.* 2011;14:330–6.
12. Loomans BAC, Opdam NJM, Roeters FJM, Bronkhorst EM, Plasschaert AJM. The long-term effect of a composite resin restoration on proximal contact tightness. *J Dent.* 2007;35:104–8.
13. Ferracane JL. Resin composite - State of the art. *Dent Mater.* 2011;27:29–38.
14. Sadaf DE, Ahmad M, Gaikwad R, Arjumand B. Comparison of two different matrix band systems in restoring two surface cavities in posterior teeth done by senior undergraduate students at Qassim University, Saudi Arabia: A randomized controlled clinical trial. *Indian J Dent Res.* 2018;29:459–64.
15. Lynch CD, Wilson NHF. Managing the phase-down of amalgam: Part I. Educational and training issues. *Br Dent J.* 2013;215:109–13.
16. Dörfer CE, Schriever A, Heidemann D, Staehle HJ, Pioch T. Influence of rubber-dam on the reconstruction of proximal contacts with adhesive tooth-colored restorations. *J Adhes Dent.* 2001;3:169–75.
17. Rau PJ, Pioch T, Staehle HJ, Dörfer CE. Influence of the rubber dam on proximal contact strengths. *Oper Dent.* 2006;31:171–5.
18. El-Shamy H, Sonbul H, Alturkestani N, Tashkandi A, Ac Loomans B, Dörfer C, et al. Proximal contact tightness of class II bulk-fill composite resin restorations: An in vitro study. *Dent Mater J.* 2019;38:96–100.
19. El-Badrawy WA, Leung BW, El-mowafy O, Rubo JH, Rubo MH. Evaluation of Proximal Contacts of Posterior Composite Restorations with 4 Placement Techniques. *J Can Dent Assoc (Tor).* 2003;69:162–7.
20. El-Shamy H, Saber MH, Dörfer CE, El-Badrawy W, Loomans BAC. Influence of volumetric shrinkage and curing light intensity on Proximal contact tightness of class II resin composite restorations: In vitro study. *Oper Dent.* 2012;37:205–10.
21. Mackenzie L, Shortall ACC, Burke FJT. Direct posterior composites: a practical guide. *Dent Update.* 2009;36:71–95.
22. Mackenzie L, Shortall A, Burke T, Parmar D. Posterior composites: An update. *Dent Update.* 2019;46:323–43.
23. Al Towayan SAR. Proximal Contour of Class II Composite Restoration: A Literature Review. *J Int Dent Med Res.* 2023;16:865–72.
24. Hahn B, Haubitz I, Krug R, Krastl G, Soliman S. Influence of Matrix Type on Marginal Gap Formation of Deep Class II Bulk-Fill Composite Restorations. *Int J Environ Res Public Health.* 2022;19:4961.
25. Almushayti M, Arjumand B. Operators' Ease and Satisfaction in Restoring Class II Cavities With Sectional Matrix Versus Circumferential Matrix System at Qassim University Dental Clinics. *Cureus.* 2022;14:1–6.
26. Tolba ZO, Oraby E, Abd El Aziz PM. Impact of matrix systems on proximal contact tightness and surface geometry in class II direct composite restoration in-vitro. *BMC Oral Health.* 2023;23:535.
27. Gomes IA, Filho EMM, Mariz DCBR, Borges AH, Tonetto MR, Firoozmand LM, et al. In vivo Evaluation of Proximal Resin Composite Restorations performed using Three Different Matrix Systems. *J Contemp Dent Pract.* 2015;16:643–7.
28. Wirsching E, Loomans BAC, Klaiber B, Dörfer CE. Influence of matrix systems on proximal contact tightness of 2- and 3-surface posterior composite restorations in vivo. *J Dent.* 2011;39:386–90.
29. Bailey O. Sectional matrix solutions: the distorted truth. *Br Dent J.* 2021;231:547–55.

30. Alsheikh R, Almulhim KS, Abdulkader M, Haridy R, Bugshan AS, Aldamanhour R, et al. Toward a Clinically Reliable Class II Resin Composite Restoration: A Cross-Sectional Study into the Current Clinical Practice among Dentists in Saudi Arabia. *Int J Dent*. 2022;2022.
31. Shaalan OO. Evaluation of Matrix Band Systems for Posterior Proximal Restorations among Egyptian Dentists: A Cross-Sectional Survey. *Acta Stomatol Croat*. 2020; 54:392–400.
32. Shaalan OO, Ibrahim SH. Clinical evaluation of sectional matrix versus circumferential matrix for reproduction of proximal contact by undergraduate students and post-graduate dentists: A randomized controlled trial. *J Int Oral Heal*. 2021;13:10–6.
33. Kim HS, Na HJ, Kim HJ, Kang DW, Oh SH. Evaluation of proximal contact strength by postural changes. *J Adv Prosthodont*. 2009;1:118–23.
34. Akhtar Q, Danyal S, Zareen S, Ahmed B, Maqsood M, Azad AA. Clinical evaluation of proximal contact points in fixed prostheses. *J Coll Physicians Surg Pakistan*. 2015;25:702–4.
35. Hickel R, Peschke A, Tyas M, Mjör I, Bayne S, Peters M, et al. FDI World Dental Federation: Clinical criteria for the evaluation of direct and indirect restorations-update and clinical examples. *Clin Oral Investig*. 2010;14:349–66.
36. Patel F, Chokshi P, Patel M, Bhatt R, Patel U. Assessment of Clinical Efficacy and Patient Comfort Using Three Different Matrix Systems for Restoring Two Surface Lesions in Primary Molars : An in Vivo Study. *J Costal Life Med*. 2023;11:491–500.
37. Sancakli HS, Yildiz E, Bayrak I, Ozel S. Effect of different adhesive strategies on the post-operative sensitivity of class I composite restorations. *Eur J Dent*. 2014;8:15–22.
38. Demarco FF, Cenci MS, Lima FG, Donassollo TA, André D de A, Leida FL. Class II composite restorations with metallic and translucent matrices: 2-year follow-up findings. *J Dent*. 2007;35:231–7.
39. Loomans BAC, Opdam NJM, Roeters FJM, Bronkhorst EM, Burgersdijk RCW, Dörfer CE. A randomized clinical trial on proximal contacts of posterior composites. *J Dent*. 2006;34:292–7.
40. Khan FR, Umer F, Rahman M. Comparison of Proximal Contact and Contours of Premolars restored with Composite Restoration using Circumferential Matrix Band with and without Separation Ring: A Randomized Clinical Trial. *Int J Prosthodont Restor Dent*. 2013;3:7–13.
41. Teich ST, Joseph J, Sartori N, Heima M, Duarte S. Dental Floss Selection and Its Impact on Evaluation of Interproximal Contacts in Licensure Exams. *J Dent Educ*. 2014;78:921–6.
42. Hickel R, Mesinger S, Opdam N, Loomans B, Frankenberg R, Cadenaro M, et al. Revised FDI criteria for evaluating direct and indirect dental restorations—recommendations for its clinical use, interpretation, and reporting. *Clin Oral Investig*. 2023;27:2573–92.
43. Cenci MS, Lund RG, Pereira CL, de Carvalho RM, Demarco FF. In vivo and in vitro evaluation of Class II composite resin restorations with different matrix systems. *J Adhes Dent*. 2006;8:127–32.
44. Bhatia HP, Sood S, Sharma N, Singh A, Rajagopal V. Comparative Evaluation of Clinical Efficiency and Patient Acceptability toward the Use of Circumferential Matrix and Sectional Matrix for Restoration of Class II Cavities in Primary Molars: An In Vivo Study. *Int J Clin Pediatr Dent*. 2021;14:748–51.
45. Peumans M, Van Meerbeek B, Asscherickx K, Simon S, Abe Y, Lambrechts P, et al. Do condensable composites help to achieve better proximal contacts? *Dent Mater*. 2001;17:533–41.
46. Loomans BAC, Opdam NJM, Roeters FJM, Bronkhorst EM, Burgersdijk RCW. Comparison of proximal contacts of class II resin composite restorations in vitro. *Oper Dent*. 2006;31:688–93.
47. Clark D. The seven deadly sins of traditional class II restorations. *Dent Today*. 2017;36:119–21.
48. Kampouropoulos D, ... CP-O, 2010 undefined. The influence of matrix type on the proximal contact in Class II resin composite restorations. [meridian.allenpress.comD Kampouropoulos, C Paximada, M Loukidis, A Kakaboura-Operative Dent 2010](http://meridian.allenpress.com/DKampouropoulos, C Paximada, M Loukidis, A Kakaboura-Operative Dent 2010)•meridian.allenpress.com.
49. Loomans BAC, Opdam NJM, Bronkhorst EM, Roeters FJM, Dörfer CE. A clinical study on interdental separation techniques. *Oper Dent*. 2007;32:207–11.
50. Peña VA De, García RP, García RP. Sectional matrix : Step-by-step directions for their clinical use. *Nat Publ Gr*. 2016;220:11–4.
51. Loomans BAC, Opdam NJM, Roeters FJM, Bronkhorst EM, Huysmans MCDNJM. Restoration techniques and marginal overhang in Class II composite resin restorations. *J Dent*. 2009;37:712–7.