

Evolving Role of Whole-Body 18 F-FDG PET/CT in Post Therapeutic Evaluation of Ovarian Malignancy

Ossama Z. Mohamed ^a, Mariem M. Hereba ^b, Sherif A. Abd Alsatir ^b

Abstract:

Background: Ovarian cancer, the most lethal among gynecological malignancies, often presents at an advanced stage, complicating initial diagnosis and treatment planning. Imaging techniques, notably 18F-FDG PET/CT, have emerged as pivotal tools in the post-therapeutic evaluation of ovarian malignancies, aiding in accurate staging, recurrence detection, and therapeutic planning. This study aimed to evaluate the role of whole-body 18F-FDG PET/CT in detecting the loco-regional recurrence and distant metastasis in ovarian cancer patients. **Methods:** This study was carried out in private radiology centers from May 2022 to February 2023 for known patients of ovarian cancers underwent therapy, coming for annual follow up with suspected recurrence, and/or distant metastasis clinically or laboratory. Our study included 25 patients all of them performed PET- CT and diagnosed with ovarian malignant lesions underwent surgical management followed by chemotherapy, however their annual tumor marker assessment showed elevated CA 125 and were referred for PETCT assessment. **Results:** PET- CT was found to be more sensitive in detecting the peritoneal deposits (less than 5 mm in diameter) especially the peripherally located perihepatic ones which couldn't be detected by the CT or CE-CT images, in 5 cases out of 25 (20%). The peritoneal deposits could be detected only by PET- CT images and missed in CT ones giving the upper hand for PET- CT as regards the peritoneal deposits detection sensitivity (83.7 %) and specificity (100%) with P value <0.001 which is statistically significant and as a result its impact on either re-staging or management plans. **Conclusion:** FDG-PET/CT is a useful adjunct to traditional staging as well as tumoral recurrence detection with MR and CT.

Keywords: 18 F-FDG; PET/CT; Ovarian Malignancy.

^a Radiology Department, Maadi
Military Hospital, Egypt.

^b Radiology Department,
Faculty of Medicine Benha
University, Egypt.

Corresponding to:
Dr. Mariem M. Hereba..
Radiology Department, Faculty of
Medicine Benha University, Egypt.
Email: dr.mer00089@gmail.com

Received:
Accepted:

Introduction

Ovarian cancer is the fifth most common malignancy in women and the most lethal among all gynecological diseases. Approximately 70% of malignant ovarian tumors are detected only at an advanced stage, which means that at the time of initial diagnosis, abdomino-pelvic dissemination has already occurred ⁽¹⁾.

Imaging features that suggest a borderline or malignant tumor include mural nodules, papillary projections, enhancing solid (Nonfatty, nonfibrous) components, and thickened walls and septa (Greater than 3 mm), particularly when vascularized ⁽²⁾.

¹⁸F-FDG PET postmenopausal ovaries have no visible FDG uptake. Therefore, any hypermetabolic ovarian uptake in a postmenopausal woman is abnormal and should be considered suspicious for malignancy until proved benign ⁽³⁾.

Imaging plays an important role in tumor size evaluation and in diagnosing distant metastasis, supporting initial diagnosis and planning of surgical treatment. ¹⁸F-FDG PET/CT has been used successfully for the diagnosis, staging, restaging, therapy and prognostic prediction of ovarian cancer ⁽⁴⁾.

PET/CT not only helps in diagnosing recurrence but also affects subsequent management. With its ability to precisely localize the lesion as well as the extent of recurrence and distant metastases, PET/CT plays an important role in restaging for recurrent ovarian cancer ⁽⁵⁾.

¹⁸FDG PET/CT is an accurate modality for detection of recurrence of ovarian cancer. The accuracy of PET-CT in precise localization of suspicious FDG uptake can lead to proper assessment of disease recurrence, thus allow for restaging of the disease and subsequently optimizing treatment plan for these patients ⁽⁶⁾.

PET and PET-CT have a potential role in evaluating patients for recurrent ovarian cancer, particularly those with negative CT or MR imaging findings and rising tumor marker levels. Fused PET-CTscans obtained with combined scanners are

highly accurate. A combination of anatomic and functional imaging can be used to diagnose disease with increased confidence at CT. Fused PET-CT scans can help localize pathologic activity and differentiate this activity from physiologic uptake. Additional investigation is necessary to determine the possible benefits of lesion conspicuity at PET and anatomic localization at CT on combined PET-CT scans ⁽⁷⁾.

The serum marker CA 125 is the most intensively studied ovarian cancer biomarker, used clinically to monitor the treatment response of ovarian carcinomas or disease recurrences. CA 125 has not proved as useful as a screening test because of low sensitivity and specificity ⁽⁴⁾.

Despite its high accuracy in the diagnosis of ovarian cancer recurrence, CA 125 has its limits. While a normal value cannot exclude the presence of disease, an increase of CA 125, even in normal limits, can predict recurrence. According to a study of Bhosale et al., 2015, PET/CT detected recurrence in 58% of cases when CA 125 was normal, while 31% of patients with normal CA 125 and negative CT had ovarian cancer recurrence confirmed by histology. Furthermore, high values cannot differentiate local recurrence from distant metastases. It is the role of imaging, and especially PET/CT, to answer that question ⁽⁸⁾.

The purpose of this study was to evaluate the role of whole-body ¹⁸F-FDG PET/CT in detecting the loco-regional recurrence and distant metastasis in ovarian cancer patients.

Patients and methods

This study was carried out in private radiology centers from May 2022 to February 2023 for known patients of ovarian cancers underwent therapy, coming for annual follow up with suspected recurrence, and/or distant metastasis clinically or laboratory.

Type of study

Cross Sectional Observational Study.

Place of study

Private radiology centers

A total number of 25 female patients were included in our study, their age ranged between 20-75 years [mean age +/- 47.5 years].

Inclusion criteria were patients presenting with ovarian malignancy coming for suspected recurrence / distant metastasis.

Exclusion criteria were patients known to have another malignant disease, with uncontrolled diabetes, severely ill, with unstable clinical status or with renal impairment.

Reference Standard: The reference standard to determine the accuracy of the imaging findings included histopathology after surgery, follow-up studies, clinical and laboratory results of the tumors for the assessment of locoregional recurrence and metastatic lesions.

Imaging Protocol: All cases were imaged by integrated PET/CT scanner (GE Discovery IQ). This is dedicated system integrates a PET scanner with a multisection helical CT scanner and permits the acquisition of co-registered CT and PET images in one session.

Image Interpretation: PET/CT examinations were analyzed by at least two experienced radiologists and nuclear medicine specialists (15-20 years experience). The PET images and the volume of CT scans were evaluated for the presence and extent of 18F-FDG-positive malignancies in the examined regions.

Approval code: 39-2-2022

Statistical analysis

Data were coded and entered using the statistical package SPSS (Statistical Package for the Social Sciences) version 26 (IBM Corp., Armonk, NY, USA). Data

was summarized using mean, standard deviation, median, minimum and maximum in quantitative data and using frequency (count) and relative frequency (percentage) for categorical data. For comparing categorical data, Chi square (χ^2) test was performed. Exact test was used instead when the expected frequency is less than 5⁽⁹⁾. Standard diagnostic indices including sensitivity, specificity, positive predictive value (PPV), negative predictive value (NPV) and diagnostic efficacy were calculated as described by Galen, 1980⁽¹⁰⁾. P value less than 0.05 was considered as statistically significant.

Case Presentation

Case 1:

Female patient 55-years old known case of cancer ovary underwent TABSO. On annual follow up her tumor markers CA 125 was elevated up to 600. PET/CT was advised for better assessment which revealed right operative bed avidly enhancing lesion with SUV max about 3.6 denoting local recurrence. The patient received 2 sessions of radiotherapy and came again for re-evaluation which showed no metabolically active lesion denoting good response. Figure 1,2.

Case 2:

Female patient 56-years old known case of ovarian cancer underwent TABSO, omentectomy, colectomy, splenectomy and received chemotherapy as well, her annual follow up showed elevated tumor markers CA 125 reaching 680. PET/CT was done for better assessment which shows operative bed irregular suspicious mass lesion with avid SUV uptake reaching 11.3 as well as hepatic capsule peritoneal sheet of abnormal FDG uptake with SUV max about Figure 3,4.

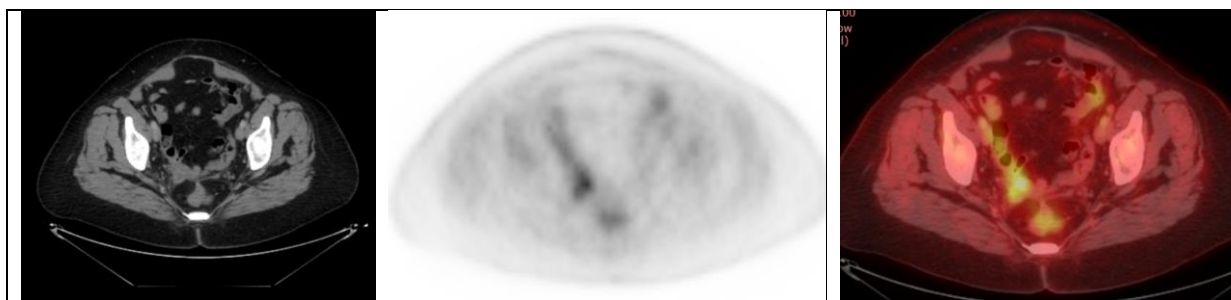


Figure 1: CT, PET & PET/CT images: Right operative bed mass lesion FDG avid uptake with SUV max 3.6.



Figure 2: Post therapeutic follow up showed no FDG uptake denoting complete response.

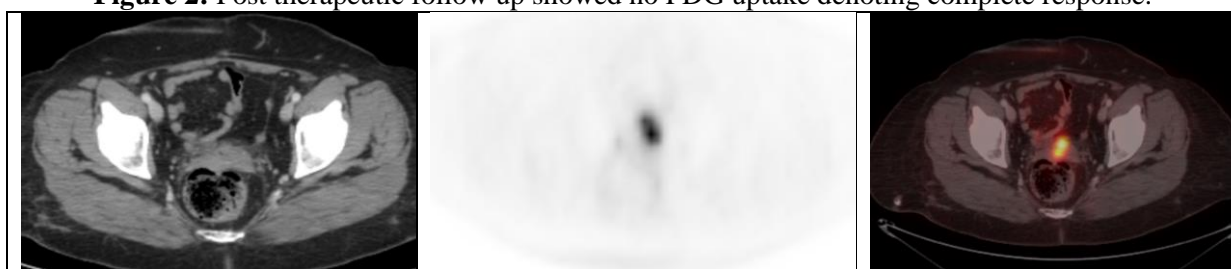


Figure 3: CT, PET & PET/CT images showed operative bed abnormal FDG uptake of about 11.3 SUV max.

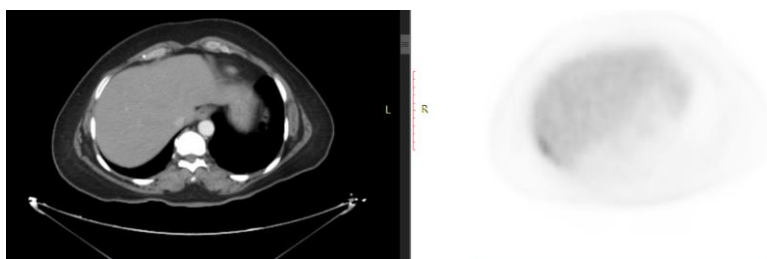


Figure 4: Images showing hepatic capsule peritoneal sheet of abnormal SUV max about 4.3, this abnormal uptake could be appreciated only in PET images.

Results

Our current study included 25 female patients. Age of patients ranged from 20-75 years [mean age 47.5 years SD] were referred for PET/CT scan with pathologically proven primary tumor (The majority of the patients having epithelial tumors), whether for regular follow-up. (Timing of PET/CT after Therapy ranging from 6 months to 2 years).

CA125 was elevated in 15/25 of the cases (more than 35 U/ML) with matching positive PETCT findings found in 15/25, denoting actual recurrence either being local or distant, P value was detected to be < 0.001 which is statistically significant. Table 1

According to tumor recurrence, it was found to be either local (operative bed) in 1/25 (4%) of the cases or distant recurrence (extra-pelvic) in 8/25 (32 %) of

the cases in form of metastatic deposits or mixed (pelvic & extra-pelvic) in 13/25 (52%) of the cases in the form of local and distant metastasis. Table 2

The Extra pelvic /Distant recurrence was found in 19/25 cases (76%) as either peritoneal involvement which is the most common pattern in 9/25 patients (36%), hepatic focal lesions in 4/25 patients

(16%) , bone metastatic deposits in 0/25 patient (0%) , anterior abdominal wall cutaneous/ subcutaneous nodules in 4/25 patients (16%) and malignant ascites was detected in 8/25 patients (32%) as well as metastatic lymph nodes , many of them showed mixed deposits in different areas. Figure 5

Table 1: Correlation between CA 125 level and positive PETCT images findings denoting recurrence in post therapeutic cases and P value assessment.

		Count		%		
CA 125	Elevated	15		60%		
	Normal	0		0.0%		
PETCT RECURRENCE		Positive		15		60%
		Negative		10		40%
PETCT RECURRENCE						
		Positive		Negative		P value
		Count	%	Count	%	
CA 125	Elevated	15	100.0%	0	0.0%	< 0.001
	Normal	0	0.0%	10	100.0%	

Table 2: Pelvic Vs. Extra pelvic Vs. Mixed tumoral recurrence assessment in post-therapeutic cases.

Tumor Recurrence	Count	%	
Local/ pelvic recurrence	Positive	1	4%
	Negative	24	96 %
Extra pelvic recurrence	Positive	8	32%
	Negative	17	68%
Mixed (pelvic & extra-pelvic) recurrence	Positive	13	52%
	Negative	12	48%

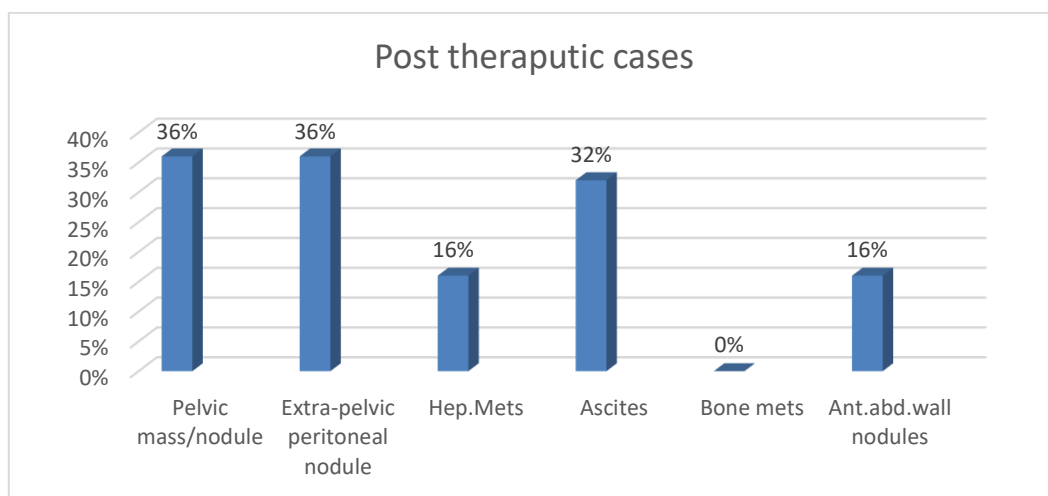


Figure 5: Different sites of Extra pelvic recurrence disturbance in post therapeutic cases.

PETCT was found to be more sensitive in detection the peritoneal nodules especially the peripherally located perihepatic ones which couldn't be detected by the CT or CECT images, in 5 cases out of 25 (20 %) the peritoneal nodules could be detected only by PETCT images and missed in CT ones giving the upper hand for PETCT as regards the peritoneal nodules detection sensitivity (83.7%) and specificity (100%) and as a result its impact on either re-staging or management plans . Three of those cases (60%) detected peripheral in location on the hepatic surface (perihepatic) (being less than 5 mm in diameter) and two cases (40%) detected in the anterior abdominal wall, which resultant P value <0.001 which is statistically significant. Table 3
As regards the metastatic lymph nodes showing metabolic activity in post

therapeutic cases, most common sites detected are abdominal lymph nodes 5/25 cases (20%), namely the para-aortic group, pelvic nodes in 6/25 cases (24 %) (either common iliac LNs, internal, external groups) as well as mediastinal lymph nodes in 6/25 cases (24%). Figure 6
CECT could detect the enlarged metastatic lymph nodes, however PETCT images were more sensitive in detecting the average sized, yet metastatic lymph nodes through their FDG uptake reflecting its metabolic activity and as result re-staging and management plans are re- scheduled, however, out of the total 25 cases in our study 4 of them showed average sized yet metabolically active lymph nodes, one of them located para-aortic (ranging in size from 9-11 mm in short axis diameter). Table 4

Table 3: Peritoneal nodules detected only in PETCT images and their location and P value and Accuracy measures of PET/CT in Peritoneal nodules detection.

				Count	%	
Peritoneal nodules detected only in PETCT		Positive		5	20%	
Peritoneal nodules detected only in PETCT site		Perihepatic		3	60%	
		anterior abdominal wall		2	40%	
Peritoneal nodules (PET CT)						
		Yes		no		P value
		Count	%	Count	%	
Peritoneal nodules (CT)	yes	18	72%	0	0.0%	<0.001
	no	5	20%	6	100.0%	
Statistic		Value		95% CI		
Sensitivity		83.78%		67.99% to 93.81%		
Specificity		100.00%		75.29% to 100.00%		
Positive Predictive Value		100.00%				
Negative Predictive Value		68.42%		51.02% to 81.84%		
Accuracy		88.00%		75.69% to 95.47%		

Table 4: Average size yet metabolically active lymph nodes and para arotic lymph nodes detected in PETCT images.

		Count	%
Average sized metabolically active LNs	Positive	4	16%
	Post therapeutic cases		
		Count	%
Para aortic	Positive	1	4%
	Negative	24	96%

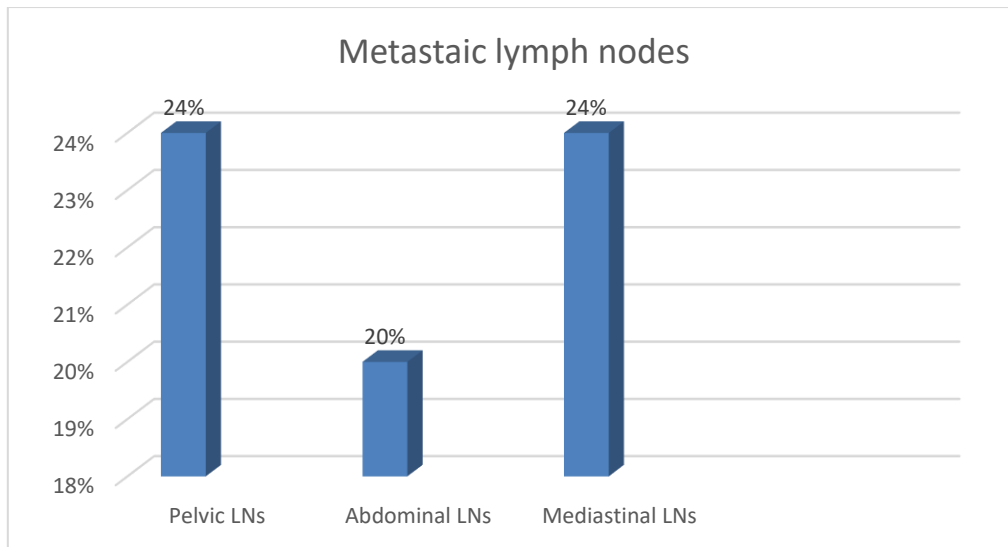


Figure 6: Distribution of Metastatic Lymph nodes in post therapeutic cases.

Discussion

Serum CA-125 is a sensitive tumor marker of recurrent ovarian cancer, especially in patients who have achieved complete remission and normalization of the elevated serum CA-125 levels. Serum CA-125 levels ≥ 35 or < 35 U/mL but with a progressive low-level increase accurately predicted tumor recurrence. Owing to its metabolic tracing ability, FDG-PET/CT has the ability to localize recurrent lesions and second primary tumors. By allowing the interpretation of the minimal serum CA-125 elevation, FDG PET/CT can facilitate the early detection of tumors and successfully localize the surgical target⁽¹¹⁾. In our study, 15/25 cases represented with elevated tumor markers. Among the 15 patients with elevated tumor markers, PET/CT correctly confirmed recurrence, excluding the disease in 10 patients (normal tumor markers patients with Normal PETCT images).

In our study, the correlation between both elevated tumor marker CA 125 and positive PETCT finding, showed CA 125 is highly sensitive in detection the tumor recurrence either being local / pelvic or distant/extra pelvic recurrence with CA 125 Sensitivity and specificity about 100% and 91.6% respectively, Positive

Predictive Value 96.67 %, Negative Predictive Value 100 % and accuracy about 97.56%, with P value < 0.001 which is statistically significant.

Our study results matched with study showed that PET/CT can accurately detect all cases with suspected ovarian cancer recurrence. Positive PET/CT scan were found in all cases with raised CA-125 values yet with unremarkable conventional imaging⁽⁶⁾.

Our study showed that PETCT is more sensitive when compared to conventional CT as regards detecting the small /average sized yet metabolically active lymph nodes which could be form of recurrence, as 4/25 follow up cases showed recurrence in that form (one of them located para-aortic) (ranging in size from 9-11 mm in short axis diameter), and those lymph nodes couldn't be detected by conventional CT yet easily detected by PETCT images owing to their FDG uptake.

Our study results matched with a study, which revealed that PET/CT scan described recurrent lesions in 5 pelvic lymph nodes with sensitivity and specificity of 80 and 98.38% and accuracy of 97%. It described suspicion of ovarian cancer recurrence in para-aortic lymph nodes with sensitivity and specificity of

66.67 and 94.82% and accuracy of 91.04% respectively (3 false positive and 3 false-negative cases). In distant lymph node metastasis, PET/CT scan described 10 lesions with sensitivity and specificity of 90 and 98.24% and accuracy of 97.01%⁽¹²⁾.

A study conducted for lymph node detection, it showed PET/CT had sensitivity and specificity of 80% and 99% and accuracy of 97% in pelvic lymph nodes and 89%, 100%, and 99% for distant lymph node while the corresponding values were 78%, 96%, and 94% for para-aortic lymph nodes, respectively, which also matched with our results⁽¹²⁾.

In a study showed that PET/CT can identify metastatic involvement of normal-sized lymph nodes, including the para-aortic, mediastinal, as well as supraclavicular locations. The overall patient-based sensitivity, specificity, and accuracy of PET/CT to detect nodal metastases were reported as 83.3, 98.2, and 95.6%, respectively. The nodal lesion site-based sensitivity, specificity, and accuracy were reported as 75.5, 99.4, and 98.1%, respectively, matching with our results⁽⁷⁾.

Our study proved that 18F-FDG PET CT is better than standard diagnostic CECT is in the detection of metastatic lymph nodes and distant extra abdominal metastases namely the peritoneal implants. and as result leads to upstage the disease, this finding was matched with the study that showed increased number of patients with Stage 4 disease when 18F-FDG PET CT was done preoperatively for the patients⁽¹³⁾.

Our results were in agreement with a study revealed that PET/CT scan detected 16 lesions of peritoneal metastasis correctly with sensitivity and specificity of 76.19 and 95.65 and accuracy of 89.55%⁽¹²⁾.

Also, with the study that showed CT detected peritoneal seeding in 26/31 (84%) patients, 18F-FDG-PET in 25/31 (81%) patients, while 18F-FDG-PET/MDCT in 30/31 patients, indicating a higher degree

of sensitivity and specificity of combined PET-CT approach⁽¹⁴⁾.

However, a study demonstrated in patients with elevated tumor markers and negative or equivocal conventional CT that 18F-FDG PET CT had a high sensitivity (83.3%) and positive predictive value (93.8%) for detection the macroscopic lesions >1 cm⁽¹⁵⁾.

In a meta-analysis of 34 studies, the improved sensitivity of detecting disease by PET especially in patients with elevated CA125. In comparison to CT and MRI, 18F-FDG PET CT has better accuracy in the detection peritoneal implants <2 cm, being in agreement with our study⁽¹³⁾.

However our study results regarding the role of FDG-PETCT in detection of the peritoneal implants mis-matched with the study which stated that CT was a better diagnostic test than 18F-FDG PET/CT to confirm the presence of peritoneal disease of ovarian origin, as the surgical peritoneal carcinomatosis index should be the gold standard for staging peritoneal dissemination, because some nodules, especially if the patient was treated with chemotherapy before surgery (as occurred in 80% of the patients), could be completely devitalized, which determines a negative result in the histological analysis but not in the evaluation or decision making during surgery⁽¹⁶⁾.

PET/CT is useful to differentiate responders from nonresponders following neo-adjuvant treatment. A study was performed PET/CT at baseline and after three and six courses of neoadjuvant chemotherapy with carboplatinpaclitaxel in 42 advanced ovarian cancer patients. Patients who showed normalization of SUVmax after three courses of treatment had a higher likelihood of complete pathological response after obtaining three additional courses of therapy⁽¹⁷⁾.

In addition, a study showed that PET can predict the early outcome after the first cycle of neoadjuvant chemotherapy. A decrease in SUV > 20% after the first cycle of chemotherapy and > 55% after the

third cycle of chemotherapy were specified as criteria for metabolic response. The metabolic responses after the first and third cycles were significantly associated with higher overall survival ⁽⁷⁾.

Conclusion

FDG-PET/CT is a useful adjunct to traditional staging as well as tumoral recurrence detection with MR and CT.

Sources of funding

This research did not receive any specific grant from funding agencies in the public, commercial, or not-for-profit sectors.

Author contribution

Authors contributed equally in the study.

Conflicts of interest

No conflicts of interest

References

- Zamwar UM, Anjankar AP. Aetiology, Epidemiology, Histopathology, Classification, Detailed Evaluation, and Treatment of Ovarian Cancer. *Cureus*. 2022;14:e30561.
- Taylor EC, Irshaid L, Mathur M. Multimodality Imaging Approach to Ovarian Neoplasms with Pathologic Correlation. *Radiographics*. 2021;41:289-315.
- Lakhani A, Khan SR, Bharwani N, Stewart V, Rockall AG, Khan S, et al. FDG PET/CT pitfalls in gynecologic and genitourinary oncologic imaging. *Radiographics*. 2017;37:577-94.
- Rubini G, Altini C, Notaristefano A, Merenda N, Rubini D, Ianora AA, et al. Role of 18F-FDG PET/CT in diagnosing peritoneal carcinomatosis in the restaging of patient with ovarian cancer as compared to contrast enhanced CT and tumor marker Ca-125. *Rev Esp Med Nucl Imagen Mol*. 2014;33:22-7.
- Prakash P, Cronin CG, Blake MA. Role of PET/CT in ovarian cancer. *AJR Am J Roentgenol*. 2010;194:W464-70.
- Hetta WM, Abdelkawi MM, Abdelbary MH, Nasr MA. Accuracy of 18F-FDG PET/CT in detection and restaging of recurrent ovarian cancer. *The Egyptian Journal of Radiology and Nuclear Medicine*. 2017;48:1049-55.
- Khiewvan B, Torigian DA, Emamzadehfard S, Paydary K, Salavati A, Houshmand S, et al. An update on the role of PET/CT and PET/MRI in ovarian cancer. *Eur J Nucl Med Mol Imaging*. 2017;44:1079-91.
- Rusu D, Carlier T, Colombié M, Goulon D, Fleury V, Rousseau N, et al. Clinical and Survival Impact of FDG PET in Patients with Suspicion of Recurrent Ovarian Cancer: A 6-Year Follow-Up. *Front Med (Lausanne)*. 2015;2:46.
- Chan YH. Biostatistics 103: qualitative data - tests of independence. *Singapore Med J*. 2003;44:498-503.
- Galen RS. Predictive value and efficiency of laboratory testing. *Pediatr Clin North Am*. 1980;27:861-9.
- Peng N-J, Liou W-S, Liu R-S, Hu C, Tsay D-G, Liu C-B. Early detection of recurrent ovarian cancer in patients with low-level increases in serum CA-125 levels by 2-[F-18] fluoro-2-deoxy-D-glucose-positron emission tomography/computed tomography. *Cancer biotherapy & radiopharmaceuticals*. 2011;26:175-81.
- EIHariri MAG, Harira M, Riad MM. Usefulness of PET-CT in the evaluation of suspected recurrent ovarian carcinoma. *Egyptian Journal of Radiology and Nuclear Medicine*. 2019;50:1-8.
- Narayanan P, Sahdev A. The role of (18)F-FDG PET CT in common gynaecological malignancies. *Br J Radiol*. 2017;90:20170283.
- Dirisamer A, Schima W, Heinisch M, Weber M, Lehner HP, Haller J, et al. Detection of histologically proven peritoneal carcinomatosis with fused 18F-FDG-PET/MDCT. *Eur J Radiol*. 2009;69:536-41.
- Bristow RE, del Carmen MG, Pannu HK, Cohade C, Zahurak ML, Fishman EK, et al. Clinically occult recurrent ovarian cancer: patient selection for secondary cytoreductive surgery using combined PET/CT. *Gynecol Oncol*. 2003;90:519-28.
- Lopez-Lopez V, Cascales-Campos PA, Gil J, Frutos L, Andrade RJ, Fuster-Quiñero M, et al. Use of (18)F-FDG PET/CT in the preoperative evaluation of patients diagnosed with peritoneal carcinomatosis of ovarian origin, candidates to cytoreduction and hipec. A pending issue. *Eur J Radiol*. 2016;85:1824-8.
- Martoni AA, Rosati M, Zamagni C, De Jaco P, Castellucci P, Quercia S, et al. Explorative study on the predictive and prognostic value of early complete metabolic response by FDG-PET-CT during neoadjuvant chemotherapy in patients with advanced ovarian cancer. *Clinical Ovarian and Other Gynecologic Cancer*. 2012;5:2-9.

To cite this article: Ossama Z. Mohamed , Mariem M. Hereba , Sherif A.Abd Alsatar. Evolving Role of Whole-Body 18 F-FDG PET/CT in Post Therapeutic Evaluation of Ovarian Malignancy. BMFJ XXX, DOI: 10.21608/bmfj.2024.265862.2006.