

# COMPARISON BETWEEN PERPENDICULAR AND CONVENTIONAL FIXATION IN SYMPHYSEAL AND PARA SYMPHYSEAL MANDIBULAR FRACTURES (RANDOMIZED CONTROLLED TRIAL)

Nesma Anan<sup>1\*</sup> BDS, Ragab S. Hassan<sup>2</sup> PhD, Gaafar N. El -Halawani<sup>3</sup> PhD

## ABSTRACT

**INTRODUCTION:** Mandible fractures are among the most common facial fractures to occur. The conventional internal fixation technique, uses two parallel mini-plates. The perpendicular fixation was introduced to neutralize the compression, shear and tension forces, which its done by moving the inferior mini-plate to be placed at the inferior border of the mandible perpendicularly to the sub apical mini-plate to allow for 3 dimensional fixation.

**OBJECTIVES:** To clinically and radiographically evaluate the use of perpendicular plating protocol compared to the conventional Champy's protocol in mandibular symphyseal and para-symphyseal fractures.

**MATERIALS AND METHODS:** The study was conducted on twenty patients diagnosed with symphyseal and/or para-symphyseal fractures indicated for open reduction and internal fixation. Fracture line was exposed through intra-oral vestibular incision followed by reduction and fixation using perpendicular plating in group A and conventional parallel plating in group B. Patients were followed up clinically and radiographically for 12 weeks to asses pain , edema , wound healing , maximal Interincisal mouth opening , occlusion, and mean bone density CBCT .

**RESULTS:** Insignificant statistical difference was reported in pain, edema, and maximum mouth opening during the followup period when comparing both groups. One case had malocclusion In group A, while the rest of the patients in both groups showed normal occlusion. Two patients one in each group showed postoperative wound infection. By comparing postoperative 12 weeks to immediate values, average bone density had shown significant difference . Moreover, group A ( $p=.005$  ) had a higher mean bone density than group B ( $p=.093$  ).

**CONCLUSION:**The perpendicular mini-plates fixation showed higher mean bone density in the fracture line than the conventional parallel plate fixation proving that it provides better stability across the fracture line neutralizing compressive, tensile and shear stresses.

**KEYWORDS:** Perpendicular, Conventional, Symphyseal, Para-symphyseal, mandibular.

**RUNNING TITLE:** Perpendicular verses conventional fixation in anterior mandibular fractures.

1 -Master student, Oral and Maxillofacial Surgery Department, Faculty of Dentistry, Alexandria University.

2 -Professor of Oral and Maxillofacial Surgery, Faculty of Dentistry, Alexandria University.

3 -Lecturer of Oral and Maxillofacial Surgery, Faculty of Dentistry, Alexandria University.

\*Corresponding author

[fearlessnolla@gmail.com](mailto:fearlessnolla@gmail.com)

## INTRODUCTION

Symphyseal/parasymphyseal fractures of the mandible account for 15.6% to 29.3% of all mandibular fractures (1). During the past few decades open reduction and internal fixation has gained the upper hand over closed reduction in treatment of mandibular symphyseal and parasymphyseal fractures (2). This can be attributed to the fact that it restore the normal anatomical position of bone and allows early return to function. Since then many methods of internal fixation have been introduced throughout the years including compression plates, lag screws, miniplates, microplates and resorbable plates (3).

Miniplates has been widely used since Champy et al., introduced the ideal lines of

osteosynthesis and stated that two parallel miniplates, one placed beneath the root apices and the other placed parallel to the lower border of the mandible, are ideal for symphyseal and parasymphyseal fixation. However, further studies proved that placing miniplates in such a manner only neutralizes compressive and tensile stresses across the fracture line but does not counteract shear stresses (4,5).

In an attempt to provide a three dimensional stability across the fracture line, three dimensional miniplates were introduced; these plates have connecting struts and thus effectively neutralizes compressive, tensile and shear stresses(6). However, these plates are larger in size, more difficult to adapt to the underlying bone

and cannot be used in areas where the fracture line is close to the mental foramen (7).

Recently, the perpendicular protocol for miniplates placement was introduced in which the lower plate is placed on the lower border of the mandible perpendicular to the upper plate which is still placed beneath the apices of the lower anterior teeth. This protocol allows three dimensional stability across the fracture line without the need for connecting struts and thus overcomes the aforementioned drawbacks of three dimensional plates(8).

However, to the best of our knowledge only two studies were conducted to date to test the feasibility of the perpendicular protocol for implant placement. Therefore, the objective of our study was to evaluate both clinical and radiographically the effect of perpendicular plating protocol versus the conventional parallel plating protocol on symphyseal and parasymphyseal fracture healing and stability.

The aim of this study was to compare clinically and radiographically between the conventional and perpendicular fixation of mandibular symphyseal and para-symphyseal fractures.

## MATERIALS AND METHODS

This was a prospective randomized controlled clinical trial with a 1:1 allocation ratio that was carried out after ethical approval from the Alexandria University Faculty of Dentistry's Research Ethics Committee.

### Patients

This study included twenty patients from the Alexandria University Hospital's Emergency Department who had anterior mandibular fractures. Prior to the procedure, all patients signed an informed consent form at Alexandria University's Faculty of Dentistry's Oral and Maxillofacial Surgery Department. Patients were divided on two groups, Group A (Study group) patients were treated using two 2 mm titanium miniplates placed perpendicular to each other. Group B (Control group) patients were treated using two 2 mm titanium mini plates fixed according to the conventional Champy's fixation protocol.

Inclusion criteria were patients suffering from displaced symphyseal and / or parasymphyseal mandibular fractures who are indicated for open reduction and internal fixation, and adult patients with age between 20-50 years with no gender predilection. Patients with old untreated anterior mandibular fractures, infected wounds in the anterior mandible, medically compromised patients specially patients receiving radiotherapy in a period of time less than 6 months were excluded from the study.

Materials (Figure 1)

Standard 2.0mm mini plates and mono-cortical screws measuring 2.0mm in diameter and 11.0mm in length were used to treat anterior mandibular fractures (Stema Medizintechnik GmbH, Stockach, Germany).

### Methods

#### Pre-operative assessment and examinations

##### Clinical examination

Full medical and dental histories were taken followed by extra-oral and intra-oral inspection to confirm the presence or absence of swelling, ecchymosis, facial asymmetry or deformity, laceration especially on the chin area, or deviation of the mandible during opening and closing of the mouth. Moreover, palpation was done to detect any step deformity, alteration in bony contour, tenderness, and bony crepitus.

##### Radiographic examination

Standard computerized tomography (CT) was done pre-operatively to detect fracture line extension, degree of displacement and for the purpose of treatment planning(Figure 2A,2B).

##### Surgical phase

##### Preoperative medications

Prophylactic antibiotic were administered in the form of Amoxicillin/Clavulanic acid (Augmentin 625 mg, GlaxoSmithKline, UK) orally three times daily for three days.

##### Surgical procedure

The operation was performed under general anesthesia with nasotracheal intubation. Intraoral and extraoral scrubbing with povidone iodine was done followed by draping with sterile towels, exposing only the area of surgery. Inter-maxillary fixation (IMF) was performed followed by an intra-oral vestibular incision to expose and reduce the fracture segments(Figure 3A,3B).

For group A, reduction was manually achieved then two titanium mini-plates were fixed using 11.0 mm screws. One of the plates was applied sub-apical while the other one was applied on the inferior border of the mandible perpendicular to each other (Figure 4A). For group B, conventional two parallel mini-plates based on Champy's osteosynthesis lines were used (Figure 4B). Once fixation was done, the IMF was released by the end of the operation and non resorbable 3/0 silk suture material were used to stitch the surgical wound.

##### Postoperative phase

The patients were monitored for 24 hours then reviewed after one and twelve weeks post-operatively. Sutures were removed after seven days.

##### Postoperative medications

All patients were given a 5-days course of systemic antibiotics; intravenous cefotaxime 1 gm/12 hours (Cefotax, E.I.P.I.C.O, Egypt) for the first day followed by Amoxicillin + clavulanate 1 gm tablets (Augmentin 1 g, GlaxoSmithKline,

UK) twice daily for the next 5 days. Metronidazole 500mg tablets (Flagyl 500mg: GlaxoSmithKline, UK) every eight hours for 5 days,  $\alpha$ -chemo-trypsin ampoules (Lourquin France, packed by Amoun pharmaceutical CO.S.A. E-Egypt) as anti-edematous once daily for 5 days, and Diclofenac potassium 50mg tab (Cataflam 50mg: Novartis-Switzerland) every eight hours for 5 days and Chlorhexidine (Hexitol 125mg/100ml, concentration 0.125%: Arabic drug company, ADCO) antiseptic mouth wash. Patients were instructed to follow a soft, fluid, high protein, high calorie diet for 4 weeks postoperatively and to maintain a good oral hygiene.

Follow up phase

Clinical followup

Pain

Visual Analogue Scale (VAS) was used for analyzing pain. A zero to ten (0-1= None, 2-4= Mild, 5-7= Moderate, 8-10= Severe) scale was used and patients were asked to rate any post-surgery pain and discomfort after 24 hours and one week (9).

Edema

Edema was evaluated by its ability to pit by fingers pressed into dependent area of the patients skin for 5 seconds. The finger sank into the tissues and leave an impression when it was removed. The pitting was graded on a scale of +1 to +4 (+1= trace, +2= Mild, +3= Moderate, +4= Severe) on the first 24 hours postoperatively, and a week later (10).

Maximum interincisal Mouth opening

The maximum interincisal mouth opening was measured using a millimeter ruler after 24 hours, one, and twelve weeks (11).

Wound healing

The intra oral incision was examined and followed up throughout the postoperative period for signs of infection including redness, tenderness and pus discharge (12).

Occlusion

The occlusion was checked after 24 hours, one, and twelve weeks throughout the postoperative period to ensure the normal occlusion of the patient in terms of molar relation and midline centralization returned to the way it was before injury (13).

Radiological followup

CBCT scan program (OnDemand3D Cybermed South Korea) and machine (J.MORITA R100 Japan) were used for all patients, the exposure parameters for all patients were 90 kV and 8 mA for 9.4 seconds. CBCT was carried out to assess the radiodensitometric bone changes in the fracture site for both groups immediately postoperatively, and three months postoperatively. (Figure 5A, 5B).

Bone density along the fracture line was measured at eight different points along the fracture line and the mean was calculated.

Statistical analysis

The collected data were analyzed using the Scientific Program for Statistical Solutions (SPSS) version 22.0 (14). Data were described using minimum, maximum, mean, standard deviation, 95% CI of the mean, median, 95% CI of the median, 25<sup>th</sup>-75<sup>th</sup> percentile and inter-quartile range. Comparisons were carried out between two studied independent not-normally distributed subgroups using Mann-Whitney U test. Comparisons were carried out between two studied related not-normally distributed subgroups using Wilcoxon Signed Ranks test. Comparisons were carried out among related-samples by Friedman's test significance tests for the results are quoted as two-tailed probabilities. The obtained results were judged at 5% level of significance. Post-hoc pair-wise comparisons when Friedman test were significant was carried out using Dunn-Sidak test for multiple comparison (9). Significance values have been adjusted by the Bonferroni correction for multiple tests. Z-test for comparing different independent proportions was used. Box and Whiskers plot was used accordingly. An alpha level was set to 5% with a significance level of 95%. Statistical significance was tested at p value < 0.05.



Figure (1): Mini-plate and screw.

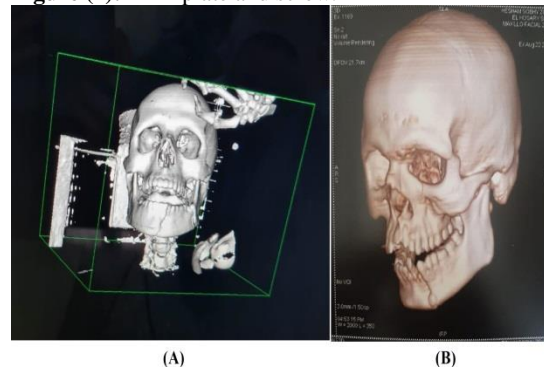
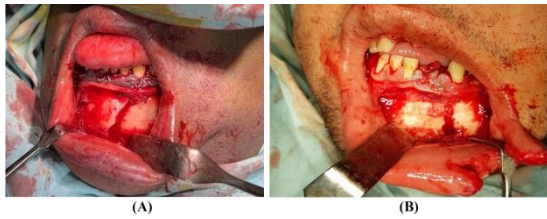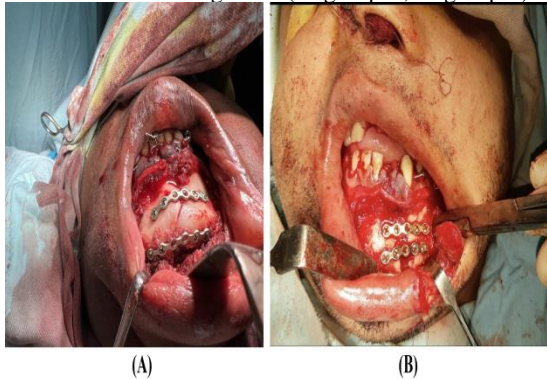


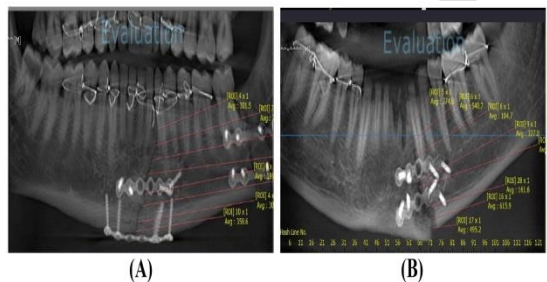
Figure (2): Preoperative CT-scan (A: group A, B: group B).



**Figure (3):** Intra-oral vestibular incision to expose and reduce the fracture segments (A: group A, B: group B).



**Figure (4):** Fixation of fracture line (A: two perpendicular mini-plates, B: two conventional mini-plates).



**Figure (5):** Postoperative CBCT-scan (A: two perpendicular mini-plates, B: two conventional mini-plates).

## RESULTS

### Biodata

The patients included twenty males. Their age ranged between 20-50 years with a mean of  $24.80 \pm 5.55$  years for group A (study group) and  $26.30 \pm 4.24$  for group B (control group). The period of time that elapsed from day of injury to open reduction and internal fixation (ORIF) ranged between 1-4 days.

Throughout the study, all of the patients in both groups were presented with isolated anterior associated fractures. Furthermore, there was no variation in terms of traumatization mode between groups or within each group.

### Clinical Evaluation

#### Pain

All of the cases studied were followed for 24 hours and one week after surgery. Statistically significant pain reduction over the course of the study was reported in all patients using the Visual Analogue Scale (VAS). No statistical variation between the groups over the followup period was

reported; The p value=0.005 in both groups (Table 1).

#### Edema

Edema decreased generally after 24 hours all through a week after. This was found to be statistically significant in all patients over the followup period. No statistical variation between the groups over the followup period was reported; The p value<0.005 in both groups (Table 2).

#### Maximum interincisal Mouth opening

The mean maximum interincisal mouth opening increased from 24 hours to the twelfth weeks in all cases without the IMF. The maximum interincisal mouth opening in the 24 hours follow up period was found to be statistically insignificant as P values were ( $p > .05$ ) in both groups. Moreover inter-group comparison revealed a statistically insignificant difference at each follow-up period ( $p > 0.005$ ).

#### Wound healing

The vestibular intra-oral incision healed well in all cases except in two cases one in each group showed signs of infection in the first week in of the followup period. After antibiotic course and appropriate wound care it was treated by secondary intention.

#### Occlusion

A single patient in group A (study group) developed malocclusion though the followup period. Elastic tractions were used to correct the malocclusion afterward.

#### Radiographic Evaluation

The immediate mean post-operative bone density in Group A was  $323.77 \pm 158.83$  HU, while the mean bone density 12 weeks later for the same group was  $604.12 \pm 135.26$ . In Group B, the mean immediate post-operative bone density was  $384.65 \pm 192.24$ , whereas the mean bone density 12 weeks later was  $453.77 \pm 144.36$ .

In terms of immediate postoperative mean bone density, there was no statistical variation between the two groups ( $p = .450$ ). Group A was  $323.77 \pm 158.83$  HU and group B was  $384.65 \pm 192.24$ . While, the mean bone density 12 weeks later, a statistical variation between the groups ( $p = .045$ ) was reported as group A was  $604.12 \pm 135.26$  and group B was  $453.77 \pm 144.36$ . Nevertheless, when comparing immediate postoperative bone density within each group; ( $p > .05$ ) in both groups, but 12 weeks postoperative bone density within each group was  $p = .005^*$  in group A and  $p = .093$  in group B; meaning that mean bone density significantly increased in group A (study group) (Table 3).

**Table (1):** Comparison of differences in VAS immediately, and one week postoperative

VAS	Group		Test of significance <i>p value</i>
	Conventional Fixation	Perpendicular Fixation	
VAS (24h PO)			
n	10	10	
Min. – Max.	5.00-9.00	5.00-9.00	
Mean ± SD	7.30±1.34	7.40±1.26	
95% CI of the mean	6.34-8.26	6.50-8.30	
Median	7.50	7.50	
95% CI of the median	6.00-8.00	7.00-8.00	
Percentile 25 <sup>th</sup> – Percentile 75 <sup>th</sup>	6.00-8.00	7.00-8.00	
Interquartile Range	2.25	1.50	$Z_{(MW)}=0.155$ $p=.877$ NS
VAS (7d PO)			
n	10	10	
Min. – Max.	1.00-4.00	1.00-5.00	
Mean ± SD	2.00±1.15	2.70±1.70	
95% CI of the mean	1.17-2.83	1.48-3.92	
Median	1.50	2.50	
95% CI of the median	1.00-3.00	1.00-4.00	
Percentile 25 <sup>th</sup> – Percentile 75 <sup>th</sup>	1.00-3.00	1.00-4.00	
Interquartile Range	2.00	3.25	$Z_{(MW)}=0.957$ $p=.957$ NS
Test of significance <i>P</i>	$Z_{(WSR)}=2.814$ $p=.005^*$	$Z_{(WSR)}=2.810$ $p=.005^*$	

\*: Statistically significant ( $p<.05$ )**Table (2):** Comparison of differences in Edema immediately, and one week postoperatively

Edema	Group		Test of significance <i>p value</i>
	Conventional Fixation	Perpendicular Fixation	
Edema (24h PO)			
n	10	10	
Min. – Max.	2.00-4.00	2.00-4.00	
Mean ± SD	3.30±.95	2.90±0.74	
95% CI of the mean	2.62-3.98	2.37-3.43	
Median	4.00	3.00	
95% CI of the median	4.00-4.00	3.00-4.00	
Percentile 25 <sup>th</sup> – Percentile 75 <sup>th</sup>	2.00-4.00	2.00-3.00	
Interquartile Range	2.00	1.25	$Z_{(MW)}=1.125$ $p=.260$ NS
Edema (7d PO)			
n	10	10	
Min. – Max.	1.00-3.00	1.00-3.00	
Mean ± SD	1.70±0.82	2.00±0.94	
95% CI of the mean	1.11-2.29	1.33-2.67	
Median	1.50	2.00	
95% CI of the median	1.00-2.00	1.00-3.00	
Percentile 25 <sup>th</sup> – Percentile 75 <sup>th</sup>	1.00-2.00	1.00-3.00	
Interquartile Range	1.25	2.00	$Z_{(MW)}=0.730$ $p=.465$ NS
Test of significance <i>p</i>	$Z_{(WSR)}=2.724$ $p=.006^*$	$Z_{(WSR)}=1.983$ $p=.047^*$	

\*: Statistically significant ( $p<.05$ )

**Table (3):** Comparison of differences in mean bone densities immediately, and twelve weeks postoperatively

Mean Bone Density (HU)	Group		Test of significance <i>p value</i>
	Conventional Fixation	Perpendicular Fixation	
Mean Bone Density (Immediate PO) (HU) n Min. – Max. Mean ± SD 95% CI of the mean Median 95% CI of the median Percentile 25 <sup>th</sup> – Percentile 75 <sup>th</sup> Interquartile Range	10 211.90-882.30 384.65±192.24 247.13-522.17 329.90 266.40-437.70 266.40-437.70 179.27	10 107.70-704.00 323.77±158.83 210.15-437.39 312.10 231.50-372.00 231.50-372.00 146.38	$Z_{(MW)}=0.756$ $p=.450$ NS
Mean Bone Density (3M PO) (HU) n Min. – Max. Mean ± SD 95% CI of the mean Median 95% CI of the median Percentile 25 <sup>th</sup> – Percentile 75 <sup>th</sup> Interquartile Range	10 244.40-652.70 453.77±144.36 350.50-557.04 430.15 306.80-576.90 306.80-576.90 280.85	10 458.40-920.90 604.12±135.26 507.36-700.87 591.98 495.00-644.20 495.00-644.20 163.65	$Z_{(MW)}=2.004$ $p=.045^*$
Test of significance (Friedman Test) <i>P</i>	$Z_{(WSR)}=1.682$ $p=.093$ NS	$Z_{(WSR)}=2.803$ $p=.005^*$	
Mean Bone Density (3M PO) (HU) n Min. – Max. Mean ± SD 95% CI of the mean Median 95% CI of the median Percentile 25 <sup>th</sup> – Percentile 75 <sup>th</sup> Interquartile Range	10 -30.30 – 52.78 24.89±25.61 6.57-43.21 27.11 15.34-46.94 15.34-46.94 36.36	10 30.81 – 498.14 125.92±137.65 27.45-224.39 84.67 59.51-142.77 59.51-142.77 95.22	$Z_{(MW)}=3.175$ $p=.001^*$

\*: Statistically significant ( $p<.05$ )

## DISCUSSION

In this study, pain was evaluated using VAS scores on a scale of 0–10 at the first 24 hours and 1 week follow-up periods; no significant differences were found between both groups. This could be attributed to the fact that the same surgical approach and same armamentarium were used in both groups. Supporting our study results Mishra et al.,(15),stated that no significant differences in pain were noted postoperatively between the two groups in their study comparing miniplates and 3 D-plates in the mandibular fractures fixation.

In contrast to the previous results, Altaib and Baiomy (16) In their study where they compared between miniplates, and 3 D rectangular miniplates in fixation of symphyseal and parasymphyseal fractures, attributed the lower pain levels in the 3D plate in comparison to the miniplates to the large free areas between the plate

arms and minimal dissection increasing the blood supply to the bone than in the group treated by miniplates accelerating the washing action of inflammatory mediators from fracture region, which conflicts with our results.

Edema was evaluated using ability to pit; The pitting was graded on a scale of +1 to +4 scores at the first 24 hours and 1 week follow-up. No significant differences were found between both groups, due to presence of multiple fractures along with the symphyseal and / or parasymphyseal fractures, the time gap between the initial trauma and the operation.Mishra et al.,(15) reported no significant differences in edema were noted postoperatively between two groups where miniplate and 3 D plate in the mandibular fractures fixation .In contrast , Kaushik et al.,(17) mentioned in his study performed on mandibular fractures and fixed with conventional two miniplates and 3D plates that moderate swelling was noticed on 24 hours after the surgery in the two

mini-plates group, while mild swelling was noticed in the group treated with 3 D plates . He attributed this to the small incision made ,requiring little time , and reducing the dissection of the soft tissue for 3D plate adaptation .

Two patients, one in each group developed postoperative wound infection. This happened because these patients failed to comply with a proper level of oral hygiene. These findings and explanations are in agreement with Rahpeyma et al.,(8) who evaluated the perpendicular two mini-plates in fixing the mandibular fractures and reported that the risk of infection in the perpendicular technique is minimal. He assigned that to extra-oral incision which limited the amount of bacterial entrance to the wound which was not the case in this study , and the choice of medically free patients. On the other hand Sadhwani et al.,(18) reported in their study preformed on 40 fracture sites where he treated them using 3-dimensional (3-D) and 2-dimensional (2-D) 2-mm mini-plates that one patient treated using 2-dimensional mini-plates has developed plate failure and subsequent infection, which was treated by removal of the plate under antibiotic coverage; this occurred due to fractured 2-D mini-plate. They also reported no incidence of plate failure in the patients treated with 3-dimensional (3-D) miniplates.

Regarding maximal interincisal mouth opening, all of the cases showed improvement in their maximal mouth opening throughout the study, with no significant difference between both groups along the followup period. This was due to the presence of associated fractures either at the angle and /or condyle and some of them required IMF for two weeks. Similar to this results .Kaushik et al.,(17) noticed lesser improvement in maximal interincisal mouth opening post operatively in the miniplates treated group in comparison with 3 D miniplates treated group as the 3D plate required less surgical exposure and less time for placement than the two miniplates . On the other hand ,Mishra et al.,(15) reported wider mouth opening in the group of patients treated with conventional mini plate than the group of patients treated with 3-D mini plate on immediate and 7th day postoperatively .

One case in group A showed mild to moderate occlusal derangement which appeared after the removal of IMF. This was attributable to associated condylar fracture and the failure of commitment to traction elastics.Same results were reported by Rahpeyma et al.,(8);mentioning that only one case showed malocclusion due to a presence of two-sided symphysis fracture and a left side condylar fracture. Sadhwani et al.,(18) reported that two patients treated using 2-dimensional mini-plates both suffering from associated fractures developed postoperative

malocclusal, that was corrected by postoperative IMF for 4 weeks. While none of the patients treated with 3-dimensional (3-D) mini-plates developed malocclusal .In contrast, Mishra et al.,(15) reported no significant differences in either groups of patients treated using 3-D mini plate and conventional mini plate regarding the occlusion.

In the immediate postoperative follow up, the mean bone density was  $323.77 \pm 158.83$  in group A and  $384.65 \pm 192.24$  in group B, which demonstrates no statistical difference between the two groups ( $p=0.450$ ). In a 12-week postoperative comparison of both groups, the mean bone density was  $604.12 \pm 135.26$  in group A and  $453.77 \pm 144.36$  in group B, indicating a statistically significant difference between the two groups ( $p=0.045$ ).

In group A, the difference between the immediate and 12 weeks postoperative mean bone density was statistically insignificant ( $p=.093$ ), moreover, the difference between the immediate and 12 weeks postoperative mean bone density in group B was statistically significant ( $p=0.005$ ). Group A had slight elevation in mean bone density than group B 12 weeks after surgery. This could be due to the difference in stability of bone fragments provided by 3D fixation given by the perpendicular plating.

Altaib and Baiomy (16) recorded a statistically significant higher bone density values for the group treated using 3D mini plate compared to the other groups where one of them was treated using double straight mini plates. This matches results of our study and proves the superiority of three dimensional fixation over double straight mini plates.

## CONCLUSION

In conclusion perpendicular fixation provides higher three dimensional stability across the fracture line than the conventional two mini-plates this can be evidenced by the higher bone density across the fracture line. It is recommended to conduct further studies with larger sample size , different parameters and longer follow up periods.

## CONFLICT OF INTEREST

The authors declare that they have no conflicts of interest.

## FUNDING STATEMENT

The authors received no specific funding for the conduction of this study.

## REFERENCES

1. Rahpeyma A, Khajehahmadi S, Abdollahpour S. Mandibular Symphyseal/Parasymphiseal Fracture with Incisor Tooth Loss: Preventing Lower Arch Constriction. *Craniomaxillofac Trauma Reconstr.* 2016;9:15-9.
2. Batbayar EO, Malwand S, Dijkstra PU, Bos RRM, van Minnen B. Accuracy and outcome

- of mandibular fracture reduction without and with an aid of a repositioning forceps. *Oral Maxillofac Surg.* 2019 Jun;23(2):201-208
3. García Carricondo AR, Quesada Bravo FJ, Espín Gálvez F, Parrón Carreño T, Alarcón Rodríguez R. A comparative study between traditional fixation with miniplates and modified lag screws for the treatment of mandibular fractures. *Clin Oral Investig.* 2018 Apr;22(3):1503-1511.
  4. Ellis E. A study of two bone plating methods for fractures of the mandibular symphysis/body. *J Oral Maxillofac Surg* 2011; 69:1978.
  5. Ellis E. Is lag screw fixation superior to plate fixation to treat fractures of the mandibular symphysis? *J Oral Maxillofac Surg* 2012; 70:875.
  6. Joshi U, Kurakar M. Comparison of Stability of Fracture Segments in Mandible Fracture Treated with Different Designs of Mini-Plates Using FEM Analysis. *J Maxillofac Oral Surg.* 2014 Sep;13(3):310-9.
  7. Mittal Y, Varghese KG, Mohan S, Jayakumar N, Chhag S. A Comparative Study of 3-Dimensional Titanium Versus 2-Dimensional Titanium Miniplates for Open Reduction and Fixation of Mandibular Parasymphysis Fracture. *J Maxillofac Oral Surg.* 2016 Mar;15(1):93-8.
  8. Rahpeyma A, Khajehahmadi S, Barkhori Mehni S. Treatment of mandibular fractures by two perpendicular mini-plates. *Iran J Otorhinolaryngol.* 2014;26:31-6.
  9. Raut R, Keerthi R, Vaibhav N, Ghosh A, Kamath Kateel S. Single Miniplate Fixation for Mandibular Symphysis and Parasymphysis Fracture as a Viable Alternative to Conventional Plating Based on Champy's Principles: A Prospective Comparative Clinical Study. *J Maxillofac Oral Surg.* 2017;16:113-7.
  10. Glória JCR, Fernandes IA, Silveira EMD, Souza GM, Rocha RL, Galvão EL, et al. Comparison of Bite Force with Locking Plates versus Non-Locking Plates in the Treatment of Mandibular Fractures: A Meta-Analysis. *Int Arch Otorhinolaryngol.* 2018;22:181-9.
  11. Herford AS, Ellis E. Use of a locking reconstruction plate=screw system for mandibular surgery. *J Oral Maxillofac Surg.* 1998;56:1261-5.
  12. Gallagher C, Gallagher V, Whelton H, Cronin M. The normal range of mouth opening in an Irish population. *J Oral Rehabil.* 2004;31:110-6.
  13. Arora L, Bhardwaj S, Hashmi GS, Anwar SF, Rahman SA. Finite Element Analysis (FEA) of Perpendicular Plating Versus Conventional Plating in Mandibular Symphysis Fracture. *J Maxillofac Oral Surg.* 2020;19:143-8.
  14. BM Corp. IBM SPSS Statistics for Windows, Version 25.0. Ar-monk, NY: IBM Corp; 2017.
  15. Mishra N, Thakkar N, Kar I, Baig SA, Sharma G, Kar R, Sahu GR, Birmiwala KG. 3-D Miniplates Versus Conventional Miniplates in Treatment of Mandible Fractures. *J Maxillofac Oral Surg.* 2019 Mar;18(1):65-72.
  16. Baiomy AA, Mohammed A. Efficacy of different fixation techniques in repair of anterior mandibular fractures. *Egypt J Oral Maxillofac Surg.* 2018;9:109-17.
  17. Kaushik S, Ali I, Dubey M, Bajpai N. 2 mm Conventional Miniplates with Three-Dimensional Strut Plate in Mandibular Fractures. *Ann Maxillofac Surg.* 2020;10:10-5.
  18. Sadhwani BS, Anchlita S. Conventional 2.0 mm miniplates versus 3-D plates in mandibular fractures. *Ann Maxillofac Surg.* 2013 Jul;3(2):154-9.