

EVALUATION OF BOTULINUM TOXIN INJECTION IN REDUCING LIP SCAR FOLLOWING CLEFT LIP REPAIR (RANDOMIZED CONTROLLED CLINICAL TRIAL)

Mohamed N. Mustafa^{1*} MSc, Abdelaziz F. Khalil² PhD,
Ahmed S. EL-Mahalwy² PhD, Mohamed Shokry² PhD

ABSTRACT

INTRODUCTION: One major complication after cleft lip repair is a hypertrophic scar which negatively affects patient's appearance, psychology and function. Several techniques have been proposed to improve lip scar such as steroid and laser therapy, none have been effective.

AIM OF THE STUDY: To evaluate the effect of Botulinum Toxin injections in reducing lip scar following cleft lip repair via study group and control group.

MATERIALS AND METHODS: A randomized controlled clinical trial was performed on a total of twenty-two patients, eleven patients were injected with Botulinum Toxin in lip muscles preoperatively (Study group), and the other eleven patient performed the surgical treatment of cleft lip without Botulinum Toxin injection (Control group.) The sample was selected conveniently to fulfil a list of inclusion and exclusion criteria. Scars were assessed at two weeks, three months and six months postoperatively regarding Vancouver Scar Scale, Visual Analogue Scale, scar width and lip height measurements.

RESULTS: At three months and six months postoperatively, the study group showed significantly better results than control group concerning Vancouver Scar Scale, Visual Analogue Scale, scar width and lip height measurements ($p \leq 0.05$.)

CONCLUSION: Preoperative injection with Botulinum Toxin results in better esthetic outcome regarding the cleft lip repair. Trial Registration: Clinical trial.gov registration ID #NCT05559281.

KEYWORDS: Cleft lip repair, Lip scar, Botulinum toxin.

RUNNING TITLE: Reduction of unilateral cheiloplasty scar using Botulinum Toxin.

1 MSc Faculty of Dentistry Alexandria University

2 Professor of Oral and Maxillofacial Surgery Department, Faculty of Dentistry, Alexandria University, Alexandria, Egypt

* *Corresponding Author:*

E-mail: drmohamednaem@outlook.com

INTRODUCTION

Surgery is the only method to treat a cleft lip, unfortunately a hypertrophic scar results (1).

This scar leads to deformed philtrum, asymmetry in Cupid's bow, and a tight upper lip (2) which later restricts growth and development of maxilla (3).

During searching the literature review, it was noticed that most scar management articles for cleft lip restoration have concentrated on treating the scar rather than preventing it from occurring in the first place. However, treatments carried out during surgery tend to be more effective than those carried out after the scar has developed (4).

Many methods were described to improve lip scar including steroid and laser therapy (5). Other methods aimed in controlling muscular activity

during healing phase like lip taping. Despite these methods, a scar was still observed (6).

Gassner et al introduced another method in controlling the activity of facial muscles via the use of Botulinum toxin type A (BTA) injections (7). BTA is a powerful neurotoxin produced by the gram-positive bacteria Clostridium Botulinum. It is widely used in medicine primarily in reducing the appearance of facial wrinkles (8).

BTA was shown to be safe in children at a dose of 1 unit/kg (9).

Actions of BTA include; inhibition of acetylcholine secretion at the neuromuscular junction thus causing muscle relaxation, inhibition of nor-epinephrine secretion therefore increasing circulatory perfusion and wound healing (10). The toxin has reversible

paralytic effect with a peak at 1-2 weeks after injection and duration of three months (11).

The aim of study was to evaluate clinically the effect of BTA injections in reducing lip scar following cleft lip repair via study group and control group. The null hypothesis stated there was no statistically significant difference in terms of scar reduction either using the injection of BTA before cleft lip repair or without its injection.

MATERIALS AND METHODS

This study was a randomized controlled clinical trial with two groups (Study group and control group) with 1:1 allocation ratio. This study was reported according to CONSORT guidelines. (<http://www.consort-statement.org>). This study followed Declaration of Helsinki 1975, as revised in 2000. The patient's legal guardian received information about the benefits and risks of the intervention, signed informed consent and was ensured of data confidentiality. This research was approved by the Ethics Committee, Faculty of Dentistry, Alexandria University ((International Number IORG0008839; Ethics Committee Number 0208-01/2021) and registered at ClinicalTrials.gov (Registration ID #NCT05559281). Patients were conducted at Outpatient Clinic of Oral and Maxillofacial Surgery Department, Faculty of Dentistry, Alexandria University from July 2021 till October 2022.

The sample size was estimated according to a similar study (12). It was estimated based on assuming 5% alpha error and 80% study power. The mean \pm SD of Vancouver Scar Scale (VSS) for patients treated with BTA injections was 3.44 ± 1.68 compared to 6.29 ± 2.39 for normal saline group "Control group" after six months follow up (12). The sample size was calculated to be ten patients per group but was increased to eleven patients to compensate patient's attrition. The sample size was based on Rosner's method (13) calculated by G. power 3.0.10 (14).

The twenty-two patients were randomly allocated into two equal groups; study group and control group (Simple randomization). Each patient's legal guardian was given a serial number in a sealed opaque envelope. All numbers were submitted in the website Randomizer.org. Computed Generated Randomization table was used to specify which serial number belonged to which group. As a result, the participants were blinded to which group they belonged to.

Inclusion criteria were; patients with mild to severe unilateral cleft lip deformity requiring repair (15), systemically healthy (16), with or without cleft palate. The exclusion criteria were; Patients with syndromic type of cleft lip (17), and/or systemic disorder.

Eleven patients were injected with BTA in lip muscles one week preoperatively (Study group), and the other eleven patient performed the surgical treatment of cleft lip without Botulinum Toxin

type A injection (Control group). All patients were operated by the same surgeon.

The primary objective of this study was to evaluate clinically the effect of Botulinum toxin type A injections in reducing lip scar following cleft lip repair. The secondary objective was to assess the esthetic outcome via VSS, Visual Analogue Scale (VAS), scar width and lip height measurements at two weeks, three months and six months postoperative.

The materials used were; Botulinum toxin type A (Botox® allergan Inc, Irvine, California), Digital Caliper (Qingdao Tlead International Co. Ltd China), Lip Taping (3M Center, Building 275-4W-02 St. Paul, MN 55144-1000 USA), Disposable Insulin Syringe (Hunan Jinhai Medical Equipment Co., Ltd China), 5-0 Vicryl and, 6-0 Prolene sutures (© Ethicon, Inc. Cincinnati, Ohio, United States US0), Steri-Strip (3M Center, Building 275-4W-02 St. Paul, MN 55144-1000 USA).

Presurgical phase

Presurgical clinical examination was performed on all patients extra-orally and intraorally. Classification of the type of cleft according to LAHSAL (18) classification system was identified. For wide alveolar clefts (more than 7mm), lip taping was done preoperatively (19). The patients were ensured fitness for general anesthesia according to Millard's Rule of 10 (16).

For study group, BTA was diluted with saline in a ratio of 25U/ml 0.9% saline, and given with a dose of 1 unit / kg (9) of body weight 1 week preoperatively. Six BTA injections was administered to lip muscles, 5 mm either side of the cleft, below the nasal base and above the vermilion border (Fig. 1).

Surgical phase

Intra-examiner reliability test was done in order to standardize the surgical phase and the postoperative measurements (20).

Cleft lip repair was done via Fisher technique (21). Under general anesthesia. The incisions, dissection and suturing were done in a three-layer fashion: mucosal, muscle, and skin.

Interrupted 5-0 Vicryl sutures were used for mucosal and muscle layer closure whereas 6-0 Prolene interrupted sutures were used for skin closure with Steri-strip placed on top. Nasal stent was done immediately postoperative and was removed with the prolene sutures one week later.

Postsurgical phase

Oral antibiotic (Amoxicillin + Clavulanic acid) and analgesic (Paracetamol) was prescribed according to child's body weight (50 mg/kg body weight per day, 10mg/kg body weight per day respectively) for five days to avoid post-operative infection and pain. The parents were instructed to clean the wound with 0.9% saline and apply antibiotic cream (fusidic acid) and skin moisturizer (pantothenic acid 2%) three times daily.

Follow-up phase

The scar was assessed at period of two weeks, three months and six months postoperatively via VSS (22), VAS (23), scar widths and lip height measurements (23, 24).

The scar width was measured at two certain points using digital caliper, one point 1 mm below nasal sill (top) and the second point 1 mm above white line (bottom) as shown in (Fig. 2).

The lip height measurement was done using digital caliper at cleft and non-cleft side. The lip height was defined as distance from each peak of cupid's bow to virtual plane generated by the initial lateral aspect of columellar base (Fig.3).

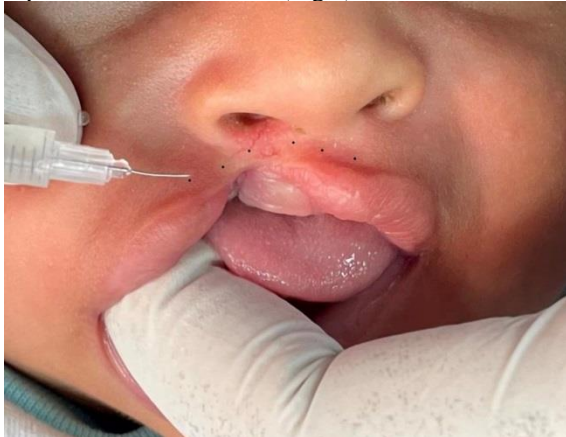

Figure (1): Showing 6 Botox injection.

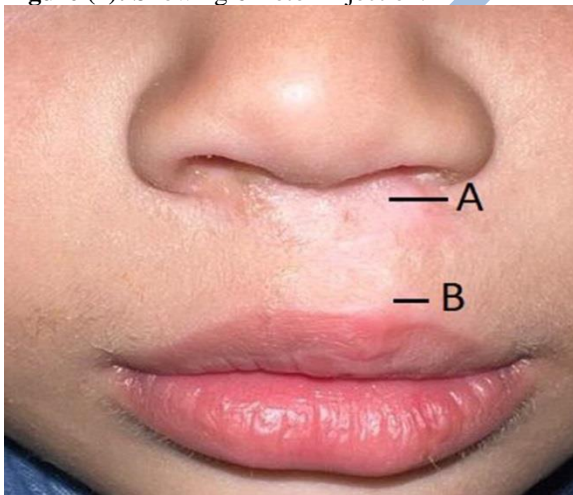


Figure (2): Showing scar widths A) Top and B) Bottom

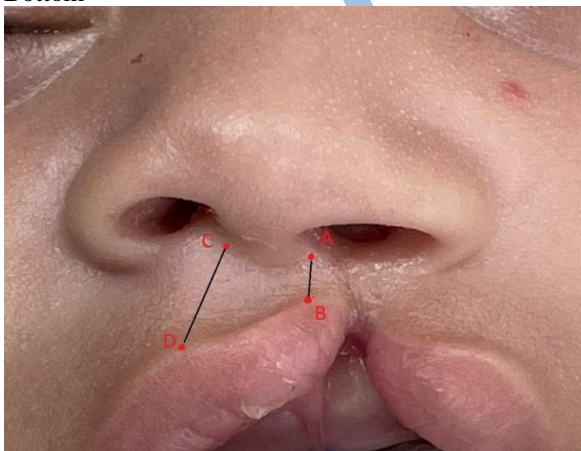


Figure (3): Showing lip height at cleft side (A-B) and non-cleft side (C-D).

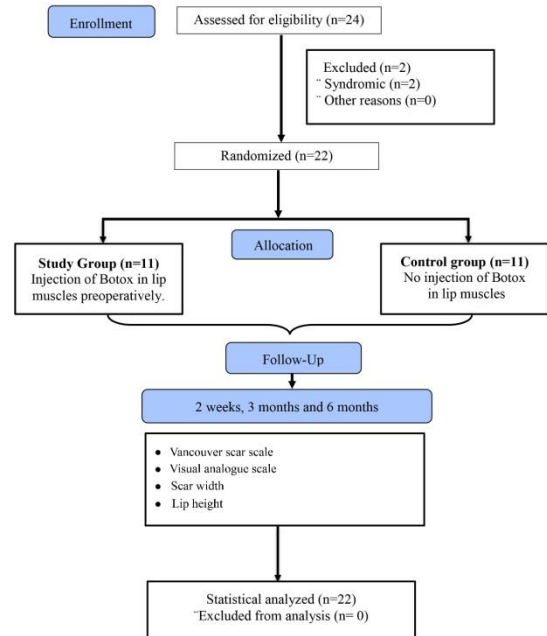


Figure (4): Showing CONSORT 2010 Flow chart.

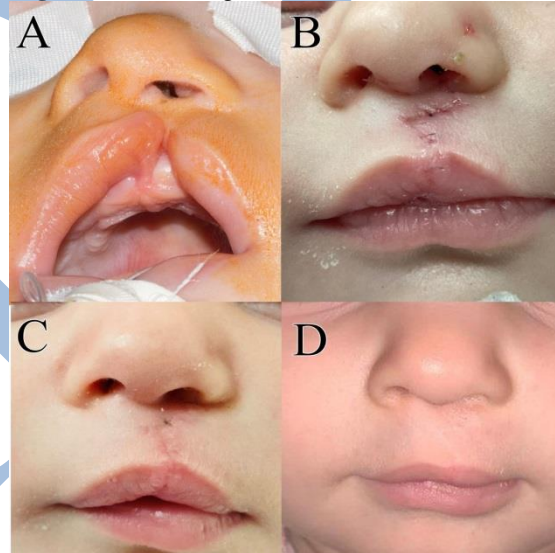


Figure (5): Showing photographs of patients A) preoperative, B) 2 weeks, C)3 months and D) 6 months postoperatively in Study group.

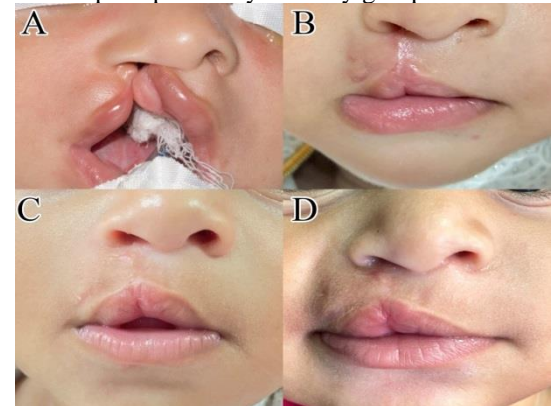


Figure (6): Showing photographs of patients in A) preoperative, B) 2weeks

C) 3 months and D) 6 months postoperatively in control group.

Statistical analysis

Data were analyzed by independent stacionian using IBM SPSS software package version 20.0. (Armonk, NY: IBM Corp). Shapiro-Wilk test was used to verify the normality of distribution. Student t-test was used for normally distributed quantitative variables whereas Mann Whitney test was used for abnormally distributed ones. Quantitative data were described using range (minimum and maximum), mean, standard deviation, median and interquartile range (IQR). Significance of the obtained results was judged at the 5% level.

RESULTS

This research was conducted on a total of Twenty-two patients of age ranging from three to twelve months and a mean age of three months. The study group consisted of eight males and three females whereas the control group consisted of six males and five females. All surgical operations were performed with no complications.

A-Vancouver scar scale

At two weeks, three months and six months postoperatively, the study group showed a lower statistically significant mean average than control group ($p \leq 0.05$) (Table. 1)

B-Visual analogue scale

The study group showed a higher mean values concerning VAS at two weeks, three months and six months postoperative than the control group. The results were statistically significant at three months and six months postoperative ($p \leq 0.05$) (Table. 2)

Table (1): Comparison between the two studied groups according to VSS.

VSS	Study group A (n = 11)	Control group B (n = 11)	t	p
2 weeks				
Min. – Max.	4.0 – 9.0	6.0 – 11.0		
Mean ± SD.	6.36 ± 1.57	8.64 ± 1.50	3.474*	0.002*
Median (IQR)	6.0(5.0 – 7.5)	9.0(8.0 – 9.0)		
3 months				
Min. – Max.	2.0 – 6.0	6.0 – 9.0		
Mean ± SD.	4.64 ± 1.21	7.55 ± 1.29	5.456*	<0.001*
Median (IQR)	5.0(4.0 – 5.5)	7.0(6.5 – 9.0)		
6 months				
Min. – Max.	1.0 – 5.0	4.0 – 9.0		
Mean ± SD.	3.27 ± 1.19	6.18 ± 1.83	4.412*	<0.001*
Median (IQR)	3.0(3.0 – 4.0)	6.0(5.0 – 7.5)		

IQR: **Inter quartile range** SD: **Standard deviation**
t: Student t-test
 p: p value for comparing between the two studied groups
 *: Statistically significant at $p \leq 0.05$

Table (2): Comparison between the two studied groups according to VAS.

VAS	Study group A (n = 11)	Control group B (n = 11)	t	p
2 weeks				
Mean ± SD.	5.4 ± 0.92	4.7 ± 0.79		
Median (Min. – Max.)	5 (4 – 7)	5 (4 – 6)	1.739	0.097
3 months				
Mean ± SD.	6.8 ± 0.98	5.4 ± 0.81		
Median (Min. – Max.)	7 (5 – 8)	5 (4 – 7)	3.792*	0.001*
6 months				
Mean ± SD.	7.8 ± 0.60	5.6 ± 1		
Median (Min. – Max.)	8 (7 – 9)	5 (5 – 8)	6.076*	<0.001*

SD: **Standard deviation** t: **Student t-test**
 p: p value for comparing between the two studied groups
 *: Statistically significant at $p \leq 0.05$

C- scar width

Top (1 mm below nasal sill)

At two weeks postoperative, the study group showed wider scar widths than control group. Whereas at three months and six months postoperative, the study group showed narrower scar widths than control group. No significant difference was found ($P > 0.05$) between both groups.

Bottom (1 mm above white line)

At two weeks, three months and six months postoperative the study group showed narrower scar widths than control group. The results were statistically significant at three months and six months postoperatively ($p \leq 0.05$)

D-Lip height differences

The study group showed smaller differences in lip height between cleft side and non-cleft side at two weeks, three months and six months postoperative than control group. The results were statistically significant at three months and six months postoperatively but not for two weeks postoperatively.

DISCUSSION

When surgical incisions are made within the face, we conceal them within skin lines to decrease muscle pull action and achieve superior aesthetic results. Unfortunately for cleft lip repair, the lip is under constant tension from Orbicularis Oris muscle resulting in a scar. This randomized controlled clinical study was done to eliminate bias

and specifically assess the influence of BTA on the esthetic outcome.

Average age of neonates was chosen to be three months, though this is controversial. Some physicians treat cleft lip in late childhood, owing to the strict postoperative instructions that need maturity to follow (25). Others noted better esthetic results were achieved of age no more than four to six months (26). Treatment can't be performed before three months of age, because; cleft parts would be so small that accurate adaptation would be difficult and also fitness wouldn't have been achieved via rule of 10 (16, 25, 27).

For alveolar clefts wider than 7mm, lip taping was done for six weeks. It is a non-surgical, cheap and effective method to approximate cleft edges and thus reduces tension on the repaired lip after cheiloplasty(15, 16, 19). Some authors disagree with such approach and state it increases patient's morbidity and affects the growth of the maxilla (28).

Ravera et al. in 2000 found that children with unilateral cleft lip surgery had significantly higher levels of Orbicularis Oris muscle electromyographic activity than normal children (29).

Increased muscle activity means more pressure on the cleft lip's healing edges. This is especially true if the incision is perpendicular to the underlying muscle fibres' direction (30, 31).

Galárraga in 2009, confirmed by Electromyography that inhibition of the orbicularis Oris muscle can be achieved by its injection with BTA. This would decrease the tension across wound edges and improve scar quality. This coincide with our study, to temporarily paralyze the Orbicularis Oris muscle with BTA during its healing phase (32).

In 2009, Pascual and Castroviejo established the safety of BTA in children under the age of two. They stated that BTA is a dose-dependent drug that is not affected by age and is one of the safest in the area of neurology (33, 34).

However, it was difficult to choose an optimum quantity of BTA that would reduce muscular activity and still be the smallest given for youngsters. Chang et al. (2014)(35) administered 1 unit/kg in three-month-old neonates, Tollefson et al. (2006)(9) used 1 to 2 units/kg of BTA in infants from three to six months. Thus, accordingly in our study we used 1 unit/kg of body weight diluted with saline in a ratio of 25U/ml 0.9% saline. Subsequently no problems were encountered.

During our work, BTA was injected one week preoperatively. This is because BTA takes three to seven days to start working and reach its maximum effect (36). Meanwhile, Galárraga in 2009 administered BTA at the end of the surgical repair because he stated children frequently suffer from upper respiratory tract infections that often delay their surgeries (32).

Orbicularis Oris is one major but not the only muscle applying tension on cleft margins(37). Others include: Levator labi superioris, Levator

labi superioris alaeque nasi, Zygomaticus minor and major. Thus six BTA injections were given 5 mm on either side of the cleft to affect most of the perioral muscles (38).

By analyzing our results, the study group showed better outcome than control group regarding VSS, VAS, scar width measurements and differences in lip height between cleft side and non-cleft side.

There is no statistical significance at two weeks postoperatively between both groups. This may be attributed to; firstly, the condition of the cleft lip preoperatively, i.e., incomplete cleft lip would have better results than complete cleft lip. This runs parallel with Gian Luca (2010) who notified that the smaller the distance between the cleft segments, the easier and more esthetical the repair segments will be (19). Secondly, insufficient time for the active Orbicularis Oris muscle to apply tension on the healing margins and form a scar.

However, at three and six months postoperative, there was statistical significance between both groups. As For the control group, the active Orbicularis Oris muscle had sufficient time to apply tension and distort the healing wounds. While in the study group, it was temporarily paralyzed, resulting in less pressure and thus better outcome. This runs parallel with previous studies who found better VAS scores with desirable outcome and smaller cheiloplasty scars (9, 11, 35, 39).

Limitations of this study include; the exact boundaries of the scar are not distinct thus discrepancies are present while measuring scar breadth. The scar isn't homogenous across its whole length, thus measuring at those two points may not be illustrative of the entire scar.

Other restrictions include; limited sample size and short follow up periods. Longer follow ups are required to see if any further distortion will occur in the future.

Within limitations, this study concludes that inhibition of the Orbicularis Oris muscle by injection with Botox preoperatively reduces the tension across the healing wound edges. This results in a repaired upper lip with better esthetic outcome regarding VSS and VAS, improved lip height and a narrower cheiloplasty scar.

CONCLUSION

Within limitations, this study concludes that preoperative injection of Botulinum toxin type A reduces the tension across the healing wound edges by inhibiting the Orbicularis Oris muscle. This results in a repaired upper lip with significant better esthetic outcome regarding VSS and VAS, improved lip height and a narrower cheiloplasty scar.

CONFLICT OF INTEREST

The authors declare that they have no conflicts of interest.

FUNDING STATEMENT

The authors received no specific funding for this work.

REFERENCES

- de Korte CL, van Hees N, Lopata RG, Weijers G, Katsaros C, Thijssen JM. Quantitative assessment of oral orbicular muscle deformation after cleft lip reconstruction: an ultrasound elastography study. *IEEE Trans Med Imaging*. 2009;28:1217-22.
- Cohen M. Residual deformities after repair of clefts of the lip and palate. *Clin Plast Surg*. 2004;31:331-45.
- Zhang H, Deng F, Wang H, Huang Q, Zhang Y. Early orthodontic intervention followed by fixed appliance therapy in a patient with a severe Class III malocclusion and cleft lip and palate. *Am J Orthod Dentofacial Orthop*. 2013;144:726-36.
- Liu A, Moy RL, Ozog DM. Current methods employed in the prevention and minimization of surgical scars. *Dermatol Surg*. 2011;37:1740-6.
- Atkinson JA, McKenna KT, Barnett AG, McGrath DJ, Rudd M. A randomized, controlled trial to determine the efficacy of paper tape in preventing hypertrophic scar formation in surgical incisions that traverse Langer's skin tension lines. *Plast Reconstr Surg*. 2005;116:1648-56; discussion 57-8.
- Garland K, Matic D. Current approaches to cleft lip revision. *Curr Opin Otolaryngol Head Neck Surg*. 2019;27:287-93.
- Gassner HG, Brissett AE, Otley CC, Boahene DK, Boggust AJ, Weaver AL, et al. Botulinum toxin to improve facial wound healing: A prospective, blinded, placebo-controlled study. *Mayo Clin Proc*. 2006;81:1023-8.
- Kivi A, Ri S, Wissel J. What clinicians and patients want: The past, the presence, and the future of the botulinum toxins. *Toxicol*. 2020;177:46-51.
- Tollefson TT, Senders CM, Sykes JM, Byorth PJ. Botulinum toxin to improve results in cleft lip repair. *Arch Facial Plast Surg*. 2006;8:221-2.
- Lebeda FJ, Dembek ZF, Adler M. Kinetic and reaction pathway analysis in the application of botulinum toxin a for wound healing. *J Toxicol*. 2012;2012:159726.
- Gassner HG, Sherris DA, Otley CC. Treatment of facial wounds with botulinum toxin A improves cosmetic outcome in primates. *Plast Reconstr Surg*. 2000;105:1948-53; discussion 54-5.
- Li YH, Yang J, Liu JQ, Xie ST, Zhang YJ, Zhang W, et al. A Randomized, Placebo-Controlled, Double-Blind, Prospective Clinical Trial of Botulinum Toxin Type A in Prevention of Hypertrophic Scar Development in Median Sternotomy Wound. *Aesthetic Plast Surg*. 2018;42:1364-9.
- Rosner B. *Fundamentals of biostatistics*. Nelson Education. 2015.
- Universität Düsseldorf. G*Power.2019. Available at: <http://www.gpower.hhu.de/>.
- Pool R, Farnworth TK. Preoperative lip taping in the cleft lip. *Ann Plast Surg*. 1994;32:243-9.
- Włodarczyk J, Higuchi E, Fahradyan A, Liu A, Gibreel W, Jennifer L, et al. A Neuroprotective Protocol in Neonatal Anesthesia: A Review of 101 Early Cleft Lip Repairs. *J Oral Maxillofac Surg*. 2020;78:e32-e4.
- Silva H, Arruda TTS, Souza KSC, Bezerra JF, Leite GCP, Brito MEF, et al. Risk factors and comorbidities in Brazilian patients with orofacial clefts. *Braz Oral Res*. 2018;32:e24.
- Raposo-Amaral CE, Denadai R, Alonso N. Classification of cleft phenotypes. In: *Cleft lip and palate treatment*. Cham: Springer; 2018. pp. 37-46.
- Gatti GL, Lazzeri D, Romeo G, Balmelli B, Massei A. Effect of lip adhesion on maxillary arch alignment and reduction of a cleft's width before definitive cheilognathoplasty in unilateral and bilateral complete cleft lip. *Scand J Plast Reconstr Surg Hand Surg*. 2010;44:88-95.
- Aufdemkampe G. Intraexaminer and interexaminer reliability of the Gillet test. *J Manip Physiol Ther*. 1999;22:4-9.
- Fisher DM. Unilateral cleft lip repair: an anatomical subunit approximation technique. *Plast Reconstr Surg*. 2005;116:61-71.
- Thompson CM, Sood RF, Honari S, Carrouger GJ, Gibran NS. What score on the Vancouver Scar Scale constitutes a hypertrophic scar? Results from a survey of North American burn-care providers. *Burns*. 2015;41:1442-8.
- Chang CS, Wallace CG, Hsiao YC, Chang CJ, Chen PK. Botulinum toxin to improve results in cleft lip repair: a double-blinded, randomized, vehicle-controlled clinical trial. *PLoS One*. 2014;9:e115690.
- Raposo-Amaral CE, Giancolli AP, Denadai R, Marques FF, Somensi RS, Raposo-Amaral CA, et al. Lip Height Improvement during the First Year of Unilateral Complete Cleft Lip Repair Using Cutting Extended Mohler Technique. *Plast Surg Int*. 2012;2012:206481.
- Kummer AW. *Cleft palate and craniofacial conditions: A comprehensive guide to clinical management*. 4th ed. Burlington, Mass: Jones & Bartlett Learning; 2020.
- Losee JE, Kirschner RE. *Comprehensive cleft care*. 2nd ed. Boca Raton, FL: CRC Press, Taylor & Francis Group; 2016.
- Michael L. Bentz, Bruce S. Bauer, Ronald M. Zuker *Principles and Practice of Pediatric Plastic Surgery*. 2nd ed. Stuttgart; Germany Thieme; 2018.

28. Scrimshaw GC. Lip adhesion--a passing fad? *Ann Plast Surg.* 1979;2:183-8.
29. Ravera MJ, Miralles R, Santander H, Valenzuela S, Villaneuva P, Zúñiga C. Comparative study between children with and without cleft lip and cleft palate, part 2: electromyographic analysis. *Cleft Palate Craniofac J.* 2000;37:286-91.
30. Martel H, Walker DC, Reed RK, Bert JL. Dermal fibroblast morphology is affected by stretching and not by C48/80. *Connect Tissue Res.* 2001;42:235-44.
31. Gurtner GC, Dauskardt RH, Wong VW, Bhatt KA, Wu K, Vial IN, et al. Improving cutaneous scar formation by controlling the mechanical environment: large animal and phase I studies. *Ann Surg.* 2011;254:217-25.
32. Galárraga IM. Use of botulinum toxin in cheiloplasty: A new method to decrease tension. *Can J Plast Surg.* 2009;17:e1-2.
33. Pascual-Pascual SI, Pascual-Castroviejo I. Safety of botulinum toxin type A in children younger than 2 years. *Eur J Paediatr Neurol.* 2009;13:511-5.
34. Salgado MD, Meier JD, Tollefson T. Botulinum toxin in cleft lip repair: 3-D videographic analysis. *Otolaryngol Head Neck Surg.* 2009;141:35-P.
35. Chang CS, Wallace CG, Hsiao YC, Chang CJ, Chen PK. Botulinum toxin to improve results in cleft lip repair. *Plast Reconstr Surg.* 2014;134:511-6.
36. Sadick NS, Matarasso SL. Comparison of botulinum toxins A and B in the treatment of facial rhytides. *Dermatol Clin.* 2004;22:221-6.
37. J.L. Deformities after cleft lip and palate surgery: J. Psaume. *Rev. Stomatol.* 56: 256, April, 1955. *Oral Surg Oral Med Oral Pathol.* 1956;9:457.
38. Lu TC, Bhandari K, Yao CF, Chen PK. The effect of botulinum toxin A in unilateral cleft lip scar: comparison of results with different sites of injection. *Int J Oral Maxillofac Surg.* 2022;51:900-5.
39. Wilson AM. Use of botulinum toxin type A to prevent widening of facial scars. *Plast Reconstr Surg.* 2006;117:1758-66; discussion 67-8.