

THE EFFECT OF BONE MARROW ASPIRATE CONCENTRATE IN THE TREATMENT OF MANDIBULAR CYSTIC DEFECTS. A RANDOMIZED CLINICAL TRIAL

Ahmed A. ElSafy^{1*} BDS, Samraa A. Elsheikh²PhD, Ahmed O. Sweedan³PhD

ABSTRACT

INTRODUCTION: Mandibular cystic defects healing is a complex process. Various methods have been developed to shorten the bone regeneration time and to improve its quality. Autogenous grafting is the gold standard for filling the cystic defects due to the osteogenesis property provided by the viable cells but is related with donor site morbidity. Allografts and Xenografts are used for the same purpose. However, the increased cost is their main disadvantage. Bone marrow aspirate concentrate is now used to enhance the healing and regeneration process in many areas of the body with no morbidity and low cost.

OBJECTIVE: To evaluate the effect of bone marrow aspirate concentrate in the treatment of mandibular cystic defects in comparison to the spontaneous healing using clinical and radiographic parameters.

MATERIALS AND METHODS: 16 patients having mandibular radiolucency's diagnosed by aspiration biopsy were divided equally into two groups. Group A included patients whom treated by enucleation and filling the defect by bone marrow aspirate concentrate on a collagen sponge, and group B included those treated conventionally. Clinical follow up was conducted, with a radiographic examination that was performed immediately post-operative and after 3 and 6 months to estimate the mean bone density and the reduction in the defect volume.

RESULTS: The study was conducted on 16 patients with male to female ratio of X and average age of X. The intergroup comparison of bone density was insignificant across the follow-up period. The defect's volume analysis showed a significant difference in the reduction between the two groups across the follow-up period. The volume reduction difference between the two groups was statistically significant (P= 0.002).

CONCLUSION: The use of bone marrow aspirate concentrate in mandibular defects is a safe and minimally invasive procedure to enhance bone healing for better healing of the defect and improvement in bone density. The operation showed adequate clinical and radiographic performance.

KEYWORDS: bone marrow aspirate concentrate, mandibular defects, mandibular cysts.

1 BDS, 2018, Faculty of Dentistry, Alexandria University, Egypt.

2 Professor of Oral and Maxillofacial Surgery, Department of Oral and Maxillofacial Surgery Faculty of Dentistry, Alexandria University, Egypt.

3 Associate Professor of Oral and Maxillofacial Surgery, Department of Oral and Maxillofacial Surgery Faculty of Dentistry, Alexandria University, Egypt.

* Corresponding Author:

E-mail: a.elsafy.dent.pg@alexu.edu.eg

INTRODUCTION

Bone healing is a dynamic cellular process including both bone matrix formation and mineral deposition. Although the process of healing cystic defects is usually of a good prognosis, the insurance of adequate shape and function regain is of major importance to allow for prosthesis rehabilitation (1). Cysts and cystic lesions of the mandible are mainly odontogenic and benign in behavior. Usually, the diagnosis of these cysts requires a combination of clinical, radiographic, and microscopic examination. However, most of these lesions cause bone loss which starts to heal after the lesion removal(2).

Bone healing passes through three main stages; inflammatory, repair, and late remodeling stages. This process may continue for a whole year until about 43% of the defect is filled with bone with a 48% increase in the density of bone (3). In order to promote bone healing and growth, bone grafts are used frequently. Autogenous grafting is the gold standard of bone grafting providing all of the components of the bone regeneration triad; osteoconduction, osteoinduction, and osteogenesis. The presence of possible donor site morbidity in addition to pain, discomfort, and the increased operation time and cost lead to the increased use of other alternatives (4).

Allografts and xenografts are common substitutes for autogenous grafting but the high cost and the possible risk of infection in addition to the variability of results are major disadvantages of these methods. Synthetic bone grafts also are a great scaffold for healing and regeneration, osteoconduction, but they provide no osteoinduction or osteogenesis properties due to the absence of growth factors and viable cells (5). Recently the use of bone marrow aspirate is implemented in the treatment of various conditions such as arthritis, bone fractures, and maxillary sinus augmentation (6, 7).

The importance of bone marrow aspirate is due to the high prevalence of bone progenitor cells which can differentiate into several other types of cells according to the implanted tissue (8). Bone marrow aspiration is a minimally invasive procedure, approved by the FDA regulations, that can be done under local or general anesthesia. It has a minimal risk of infection after its application at the defect size (4, 9). Bone marrow is commonly aspirated from the posterior iliac spine as it has the highest count of mesenchymal cells. Other sites of bone marrow aspiration include the anterior iliac crest and the tibia (6).

Many studies have been done to develop a concentration of the bone marrow stem cells from the aspirate eliminating other bone marrow cells such as; red blood cells, granulocytes, immature myeloid precursors, and platelets. The processes of *Bone Marrow Aspirate Concentrate* (BMAC) sieving is performed after density gradient centrifugation of the aspirated marrow, leaving the progenitor cells. Despite BMAC consisting of a small population of progenitor stem cells (0.01-0.001%), the presence of many important growth factors as platelet-derived growth factor, transforming growth factor B bone morphogenic proteins 2 and 7 is high makes it an exemplary reconstructive option (10, 11).

Some pain relief may be also achieved due to the presence of an accountable concentration of Interleukin-1 Receptor Antagonist (IL-1RA). It inhibits interleukin-1 catabolism and thus accounts for some pain control through the BMAC approach (6). Many studies have used the collagen sponge as a biomaterial in a gel or a sponge form for cellular growth or the delivery of growth factors. The collagen sponge will act as a carrier for the BMAC cells and the growth factors. The collagen sponge has proven to give significant results when used to fill the bony defect (12, 13).

Hence, this study aims to evaluate the clinical and radiographic performance of the BMAC on the healing and regeneration process of the mandibular defects when applied on a collagen sponge scaffold. The null hypothesis is that there is no significant difference in the healing clinically and radiographically between the cases treated by BMAC and the conventionally treated cases.

MATERIAL AND METHODS

This study was a randomized clinical trial with a 1:1 allocation ratio.

It will be set up and reported according to the CONSORT guidelines (<http://www.consort-statement.org>). Sample size was estimated based on assuming a 5% alpha error and 80% study power. The sample size was calculated to be 8 patients per group with regards to patients lost to follow-up (14). The study enrolled patients were divided equally into group I and group II. Group I was managed with enucleation and BMAC application on a carrier collagen sponge scaffold. Group II was treated conventionally with the addition of collagen scaffold without any additives.

The criteria for patients' selection were set as adult patients below, 40 years, with no gender predilection that agreed to present for follow-up visits for a minimum postoperative period of 6 months with medium-sized cystic defect width of 3-6 cm that requires removal under general anesthesia (1, 3). Medically compromised patients contradicting operation, previously enucleated lesions, or patients with previous surgery were excluded, along with those with infection to the pelvis affecting the anterior iliac crest (1, 3).

Materials:

Jamshedji bone marrow aspiration needle was used to collect bone marrow with a 13 Gauge (GEOTEK Healthcare Products, Turkey)(Figure 1)(1). Collagen sponge was used as a scaffold for patients in both groups (Collacone® Natural collagen cone by botiss dental, Germany)(12). Finally; a Centrifugation machine with 220V and 800D was used for the BMAC preparation (Renhotec Group, China)(1).

Methods

I. Preoperative assessment.

Full personal data of the included patients were obtained along with their chief complaint. A throughout clinical examination was performed along with the aspiration of the related lesion for preliminary confirmation of the nature of the disease (15, 16). Cone Beam Computed Tomography (CBCT) scan was obtained Preoperatively for the examination of the extension, size, width, and appearance of the lesion (Figure 2). An examination of the groin area was performed to assess any locations of musculoskeletal pain, limitation of motion, or any mass located in this area.

II. Surgical procedure.

Cyst enucleation

Important laboratory investigations are done to check the patient's fitness for operation under general anesthesia by the anesthesiologist. Surgical operations are done under general anesthesia using nasotracheal intubation. The surgical field will be scrubbed with povidone-iodine (Purdue Products L.P) surgical scrub solution, followed by draping of the patient with sterile towels exposing only

the area of surgery and aspiration. After that, injection of a vasoconstrictor agent was performed at the operating field. The Lesion was exposed via a mucoperiosteal flap, followed by flap elevation and cortectomy to expose the full outline of the lesion. This is Followed by cystic lining separation from the underlying bony margins and full lesion enucleation. Hemostasis is then achieved and, if required, apicectomy and retrograde filling of the related teeth is performed (Figure 3).

Bone Marrow Aspiration

The iliac crest is palpated and the location of the iliac tubercle is located, 5-6 cm posterior to the anterior superior iliac spine. The mid-point of the iliac tubercle is identified, and the needle is advanced between the outer and inner plates of the ileum for 4-6 cm into the cancellous bone. A 10 ml of bone marrow is aspirated (9, 17) (Figure 4).

Bone Marrow Aspiration Concentrate Preparation

A dual centrifugation technique is used for BMAC preparation. Primary centrifugation of the aspirated marrow at 2400 rpm for 10 minutes was performed, then the formed buffy coat layer is extracted by pipet. A second centrifugation of the buffy coat at 3400 rpm for 6 minutes was performed and the resultant liquid pellet was extracted by pipette (10). The BMAC, in the form of a liquid pellet, was soaked in the carrier scaffold and applied to the mandibular defect (13). The scaffold carrying the BMAC was applied to the mandibular defect and closure of the surgical wound was performed (Figure 5).

III. Early postoperative care:

All patients were instructed to apply ice pack extra-orally starting immediately postoperatively for 12 hours(3). Postoperative antibiotic (Augmentin: Amoxicillin 875 mg + Clavulanic acid 125 mg: GlaxoSmithKline, UK) was prescribed twice daily for the next 5 days. An anti-edematous (α -chemo-trypsin: Leurquin France) was prescribed once daily for 5 days along with an anti-inflammatory drug (Cataflam: Diclofenac Potassium 50mg: Novartis-Switzerland) 50mg every eight hours for 5 days. All patients will be instructed to rinse their mouth using chlorhexidine (Hexitol: Arabic drug company, ADCO) antiseptic mouthwash. Instruction of soft, fluid, high protein, high-calorie diet will be given for all patients for 4 weeks postoperatively.

IV. Clinical follow-up phase:

A thorough follow-up was performed after 24 hours, one week, four weeks, and six weeks for the assessment of postoperative pain using a 10-point Visual Analogue Scale (VAS), and wound healing, based on the Landry et al Healing Index (18).

V. Radiographic evaluation

An immediate postoperative CBCT was obtained, followed by another one taken after 3 and 6 months postoperatively. A Region of Interest (ROI) feature was used to estimate the mean bone density in the acquired

scans according to Noureldin and Melek (2020)(19). The mean bone density in the 6 month CBCT-scan was compared with the 3 months and the immediate postoperative scans and the mean difference between the scans was calculated. The percentage of improvement in the recorded bone density was calculated.

VI. Defect Volume evaluation.

The defect Volume was calculated in each of the recorded scans. The outline of the defect was segmented in a thresholding software in each of the obtained CBCT scans (Materialise Mimics 3D Medical Image Processing Software). The segmented 3D object is transformed in an STL format into specialized software for the automatic calculation of the volume of the segmented STL object and compared with the immediate postoperative scan in order to determine the degree of defect healing (20).

VII. Statistical Analysis.

Normality of data was checked using Shapiro Wilk test and Q-Q plots. Age, bone volume, and bone surface area were normally distributed and presented mainly using mean and standard deviation. VAS, wound healing score, bone density, percent change in bone density, volume, and surface area were non-normally distributed and presented mainly using median, interquartile range, minimum and maximum. Comparison between groups regarding bone volume was done using independent t-test t each time point while Repeated measures ANOVA was employed for within-group comparisons. VAS, wound healing, bone density, and percent change were compared using Mann Whitney U test and Friedman test was applied for within groups comparison followed by post hoc test with Bonferroni correction. All tests were two tailed and significance level was set at <0.05. Data were analyzed using IBM SPSS version 23, Armonk, NY, USA

RESULTS

This study was conducted on two groups each consisting of eight patients diagnosed with mandibular cysts. The average reported age in the study was 28.94 with a slight female predominance and male-to-female ratio of 1:1.66. The site prevalence showed a posterior predilection of the mandibular cysts. All cases were positive upon fluid aspiration. Histopathological examination after cyst enucleation revealed that 81.25 % of this study cases were radicular cysts, 12.5% were dentigerous cysts and 6.75% were lateral periodontal cysts. The demographic data of the study are presented in Table 1.

Clinical follow-up data:

VAS score was utilized for postoperative pain assessment and in both groups, the patients reported a statistically significant improvement in the reported VAS score across the follow-up period ($P < 0.0001$). The inter-group comparison at each follow-up period

was statistically Insignificant ($P= 0.328, 0.645, 1.00,$ and 1.00).

Regarding the wound healing assessment, the improvement in the Landry index was statistically significant Across the follow-up period in both groups (group I $P<0.0001$, group II $P<0.0001$). One case in group I suffered from postoperative wound dehiscence, which affected the reported score in group I. This case was managed with wound debridement and irrigation, and the case showed improvement with total wound closure in the third postoperative period (Table 2).

Radiographic data analysis:

Improvement in defect bone density was assessed in this study and showed a statistically significant Improvement in the defect's bone density across the follow-up period ($P <0.0001$). The calculated improvement in the six months scan from the immediate one was 1149.07% for group I and 1634.55% for group II. The improvement difference between the two groups was statistically insignificant ($P= 0.462$) (Table 3,4).

Defect Volume evaluation.

Defect's bone volume calculation was done to allow for estimation of the bone formed quantity. the reduction in defect's bone volume across the follow-up period was statistically significant ($P <0.0001$) for group I and ($P= 0.015$). The calculated volume reduction percent in the three months scan from the immediate one was 51.38% for group I and 30.96% for group II. The volume reduction difference in the first three months between the two groups was statistically insignificant ($P= 0.529$). The bone volume reduction percent in the six months scan from the immediate one was 84.17% for group I and 42.95% for group II. The volume reduction difference between the two groups was statistically significant ($P= 0.002$). (Table 5,6) (Figure 6).



Figure 1: Jamshedji bone marrow aspiration needle for the collection of bone marrow.

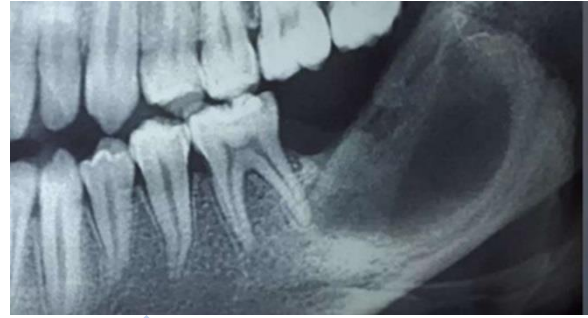

Figure 2: Preoperative radiographic examination

Figure 3 : complete enucleation of the cyst lining

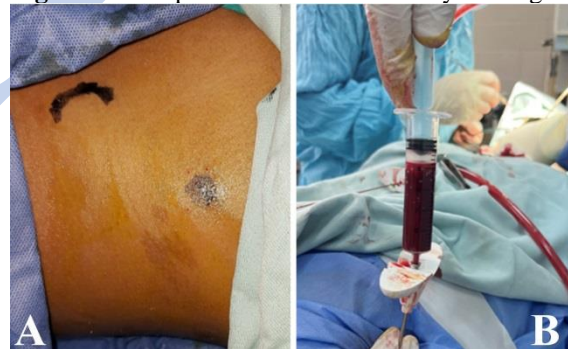

Figure 4 : (A) Examination of the donor site
(B) Process of bone marrow harvesting

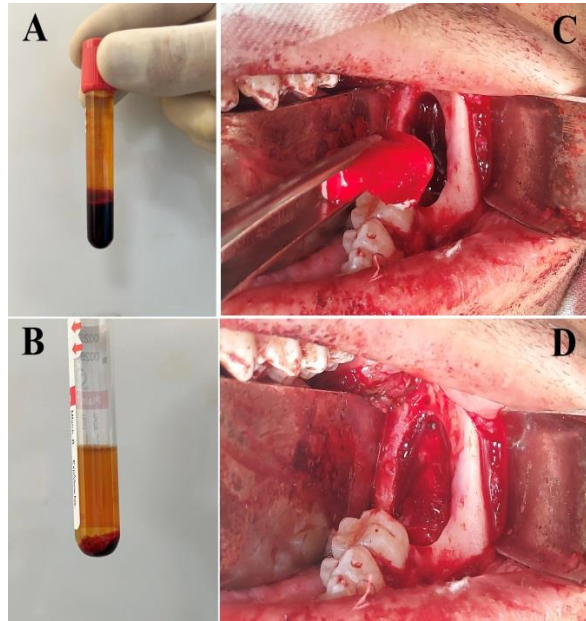


Figure 5 : (A) Buffy coat layer after primary centrifugation
 (B) Liquid pellet after the second centrifugation
 (C) The application of the collagen sponge soaked with the BMAC
 (D) Cystic defect with the collagen sponge scaffold

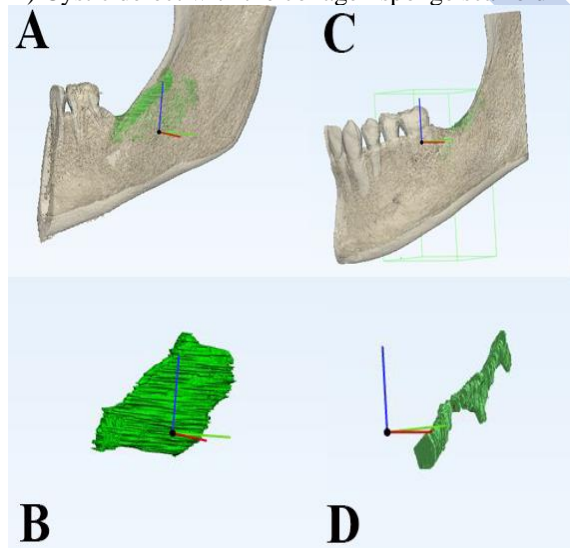


Figure 6 : (A) Segmented defect with the mandible, immediate post-operatively
 (B) Segmented defect, immediate post-operatively
 (C) Segmented defect with the mandible, after 6 months
 (D) Segmented defect, after 6 months

Table 1: Demographic variables and characteristics of the study groups

		Group I (n=8)	Group II (n=8)	P value
Age: Mean (SD)		29.25 (7.34)	28.63 (4.60)	0.841
Gender: n (%)	Males	4 (50%)	3 (37.5%)	1.00
	Females	4 (50%)	5 (62.5%)	
Site: n (%)	Anterior	5 (62.5%)	5 (62.5%)	1.00
	Posterior	3 (37.5%)	3 (37.5%)	
Histopathology: n (%)	Dentigerous	1 (12.5%)	1 (12.5%)	0.584
	Lateral periodontal	0 (0%)	1 (12.5%)	
	Radicular	7 (87.5%)	6 (75%)	
Aspiration: n (%)	Positive	8 (100%)	8 (100%)	1.00
	Negative	0 (0%)	0 (0%)	

Table 2: Percent change in bone density between the study groups

		Group I (n=8)	Group II (n=8)	P value
Immediate - 3 months	Mean (SD)	574.79 (912.21)	932.84 (859.38)	0.529
	Min - Max	40.97 - 2700.00	11.70 - 2250.00	
Immediate - 6 months	Mean (SD)	1149.07 (1663.86)	1634.55 (1443.76)	0.462
	Min - Max	234.72 - 5100.00	61.70 - 3761.54	

Table 3: Percent change in bone volume between the study groups

		Group I (n=8)	Group II (n=8)	P value
Immediate - 3 months	Mean (SD)	-51.38 (4.79)	-30.96 (30.41)	0.248
	Min - Max	-59.38 - 44.55	-73.73 - 0.67	
Immediate - 6 months	Mean (SD)	-84.17 (6.70)	-42.95 (26.98)	0.002*
	Min - Max	-90.98 - 73.58	-81.02 - 14.59	

*Statistically significant at p value<0.05

DISCUSSION

Bone regeneration in cystic defects has always been a point of research to compare between spontaneous natural healing and the use of different grafting methods or bone-inducing material. In this study, BMAC was added to the mandibular cystic defects by the means of a collagen sponge as a scaffold to observe clinically and radiographically whether it will enhance the regeneration process or not.

The average age of the patients in this study was found to be 28.94 years with a strong predominance of radicular cysts over other types of cysts. Johnson et al (2014)(21) conducted a systematic review of the

literature from 1993 to 2011 over 26 papers from 19 different countries, including Egypt, with a total number of 18,297 cyst cases. Their study found that in all countries radicular cysts predominate with a percentage ranging from 38.8% to 84.5%. El Gehani et al (2008)(22) conducted a study to assess the prevalence of odontogenic cysts and found that the average age of cyst cases was 30.16 years with most of the cases occurring in the third and fourth decades. Again, radicular cysts were the most prevalent type of odontogenic cysts. The outcome in both of the abovementioned studies is consistent with the demographic data found in this study. The average age may be related to the predominance of radicular cysts over other types of cysts. Radicular cysts are mostly discovered in the third decade of life as a result of the inoculation of dental bacterial infection to the surrounding perialveolar bone after progression of caries and pulp death procedure from permanent teeth.

In this study, most of the cases occurred in the anterior mandible rather than in the posterior region. This revelation is in contrast with that declared by El Gehani et al (2008), who stated a posterior mandible predominance. Meanwhile, Jones et al (2006)(23) found that mandibular cysts occurrence between the anterior and posterior regions is almost equal. This difference may be referred to the random allocation of cases in the outclinic.

Postoperative pain analysis was performed using the VAS score, which in both groups showed a statistically significant decline across the clinical follow-up period. A similar outcome was reported by Noureldin and Melek (2020)(19) and Ibrahim et al (2016)(24). In this study, the recorded pain reached zero level in the third postoperative period, after one month. Noureldin and Melek (2020) reported a higher VAS score in the first follow-up setting than that reported in this study. The lower score after 24 hours may be related to the use of the collagen sponge in the two groups of the study, which has a hemostatic effect and helps in the initial blood clot stabilization allowing better soft tissue healing and less inflammatory reaction. VAS score after one week is higher than mentioned studies, this may be dedicated to larger cyst sizes included in this study when compared to the mentioned studies and other ones.

The Landry et al (1988) healing index was utilized in this study for the evaluation of postoperative wound healing. In both groups, the calculated score showed statistically significant improvement across the follow-up period. Aggarwal et al (2021)(25) conducted a study for the evaluation of postoperative wound healing in a periodontal surgery with the Landry et al (1988) wound healing index. They

reported a similar outcome as in this study. In this study, the study group reported a lower mean score of wound healing when compared to the control group. This is a self-evident observation based on the fact that one case in the study group suffered from postoperative wound dehiscence most probably due to the action of the mentalis muscle as the cyst was located anteriorly and the patient not following the instruction regarding the chin taping. To our knowledge, this is the first study to report the use of Landry et al score to evaluate postoperative wound healing after cyst enucleation.

As a basic element of radiographic assessment, bone density was observed using Cone Beam Computed Tomograms (CBCT). When comparing the improvement of the bone density between the study and the control groups, the difference was found to be statistically insignificant over the three and six months follow-up period ($P=0.529$, $P=0.462$ respectively). The six months scan revealed a mean bone density of 527.75 HU in the study group and 324.25 HU in the control group. El-ghamrawy et al (2017)(26) conducted a radiographic analysis to evaluate clinical and radiographic evaluation of collagenated cortico-cancellous bone graft after mandibular cyst enucleation. They reported a similar outcome in the six months scan in the control group as reported in this study. The insignificances between both groups may be referred to the heterogenicity and the randomness of the site of the mandible defect, where differences in the nature of the bone affect the outcome of the density evaluation.

In this study, we opted for several measures in order to standardize the measuring procedure of bone density. The same CBCT scanner was utilized with similar scanning parameters for all of the included patients in this study. Furthermore, a standardization for the size and position of the region of interest was performed in order to attain a reliable measuring procedure. Furthermore, this study utilized the percentage of change in bone density as an analysis procedure, in an attempt to remove the errors in the measuring procedure.

Density analysis in mandibular defects healing shows a vast heterogenicity in the indexed literature. The utilization of CBCT is less reliable than CT as it doesn't show true Hounsfield units providing a gray value (GV). Although many trials and advances have been proposed to validate the correlation between the CBCT gray value and bone density, it still should be directed toward evaluating the clinical outcome for dental implants rather than assessing the bone density in pathological lesions (27). The correlation of bone density results in this study to other studies assessing the bone density after cysts enucleation is difficult

and incomparable most of the time as the results are widely affected by the different radiographic assessment tools (CT, CBCT, OPG), and the software used to obtain these results especially if they are measured on gray value. Furthermore, the differences between clinicians and the methods of obtaining an average value for each case affect these values significantly. Thus, unless bone density is measured by true Hounsfield units, they cannot be reliably compared to each other.

As a better factor to be assessed rather than the density, the bone volume was calculated in order to process the reduction in the defect's volume over the follow-up period. In the first three months, the mean volume reduction was 51.38% in group I which is more than the reduction in group II (30.96%) but not statistically significant ($P=0.248$). While after 6 months the volume reduction reached 84.17% and the difference was statistically significant ($P=0.002$) when compared to group II which only raised to 42.95%.

Volumetric analysis was done to observe the spontaneous bone healing in odontogenic cysts by Ku et al (2022)(28). The average rate of healing of jaw cysts in the first year postoperatively is $33.5 \pm 32.8\%$ which is close to the mean rate found in group II (control group) of this study after 6 months. However, the average age of patients in this study is 28.94 years, which is lower than that of the previously mentioned study, 40.3 years. This may explain the slightly higher healing rate in this study. Furthermore, Ku et al (2022) state the rate of healing in another group with more than a one-year follow-up period raises to 74.5%. This percentage is close to the 84.17% reported in the study group after 6 months. These results indicate that the use of BMAC in cystic defects may result in a better quality of the newly formed bone in a significantly shorter period of time.

This is consistent with the study done by Eissa et al (2018)(29) to evaluate the effect of autogenous bone marrow mesenchymal stem cells in the healing of mandibular osseous defects grafted with beta-tricalcium phosphate in dogs. They found that the amount of newly formed bone in defects treated by bone marrow-derived graft is significantly higher than in the control group. This is coherent with what we mentioned previously and can be explained by the bone marrow stem cells' functional, tissue-specific biodiversity. This is regulated by the "cell to cell" communication by adhesion molecules, growth factors, and cytokines allowing the differentiation of these stem cells to bone-forming cells (30).

Several reports are available regarding the use of BMAC in the oral and maxillofacial field, however, the majority of them are animal studies with histopathological confirmation regarding the biological effect of BMAC on bone healing (29, 31, 32). The human trials regarding the use of BMAC in the oral and maxillofacial field are somehow limited

(33, 34). Pelegrine et al (2016)(33) used the BMAC in the reconstruction of atrophied anterior maxilla and Ting et al (2018)(34) conducted a study to evaluate the use of BMAC in maxillary sinus augmentation for implant placement. The bone marrow harvesting procedure is safe and minimally invasive with low, or even minimal, donor site morbidity. However, the use of BMAC in mandibular defects is limited to procedures that are made under general anesthesia, as its use under local anesthesia still may cause a variable degree of pain and pressure. To our knowledge, this is the first report to utilize the BMAC in mandibular cystic defects in an attempt to improve defect healing.

Many limitations were experienced during the conduction of this study, such as the inability to use Computed tomography (CT) for bone density evaluation to avoid exposing the patient to multiple large doses of radiation. Furthermore, the heterogeneity of the cysts site and the difference in nature between the anterior and posterior mandibular area has restricted the accuracy of the data analysis especially for the bone density. Furthermore, cases near the upper limit of the included age were more difficult in the aspiration process when compared to younger patients while the aspirated bone marrow was more fatty and less cellular. This may be due to the lower resilience of bone and the lower volume of bone marrow spaces and their content.

The exemplary clinical and radiographic performance of the cases with mandibular defects managed with scaffolded Bone Marrow Aspirate Concentrate for healing promotion may introduce its application in several different aspects of the oral and maxillofacial field. The study reported BMAC as a safe, autogenous, and minimally invasive defect healing endorser. At the end of the radiographic follow-up period, the study cases reported a significant reduction in the defect volume.

REFERENCES

1. U V, Mehrotra D, Howlader D, Kumar S, Anand V. Bone Marrow Aspirate in Cystic Maxillofacial Bony Defects. *J Craniofac Surg*. 2019;30(3):e247-e51.
2. Scholl RJ, Kellett HM, Neumann DP, Lurie AG. Cysts and cystic lesions of the mandible: clinical and radiologic-histopathologic review. *Radiographics*. 1999;19(5):1107-24.
3. Gali RS, Devireddy SK, Mohan Rao N, Kishore Kumar RV, Kanubaddy SR, Dasari M, et al. Autogenous Bone Marrow Aspirate Coated Synthetic Hydroxyapatite for Reconstruction of Maxillo-Mandibular Osseous Defects: A Prospective Study. *J Maxillofac Oral Surg*. 2017;16(1):71-8.

4. Zizzari VL, Zara S, Tete G, Vinci R, Gherlone E, Cataldi A. Biologic and clinical aspects of integration of different bone substitutes in oral surgery: a literature review. *Oral Surg Oral Med Oral Pathol Oral Radiol.* 2016;122(4):392-402.
5. Friedlaender GE, Strong DM, Tomford WW, Mankin HJ. Long-term follow-up of patients with osteochondral allografts. A correlation between immunologic responses and clinical outcome. *Orthop Clin North Am.* 1999;30(4):583-8.
6. Chahla J, Mannava S, Cinque ME, Geeslin AG, Codina D, LaPrade RF. Bone Marrow Aspirate Concentrate Harvesting and Processing Technique. *Arthrosc Tech.* 2017;6(2):e441-e5.
7. de Oliveira TA, Aloise AC, Orosz JE, de Mello EOR, de Carvalho P, Pelegrine AA. Double Centrifugation Versus Single Centrifugation of Bone Marrow Aspirate Concentrate in Sinus Floor Elevation: A Pilot Study. *Int J Oral Maxillofac Implants.* 2016;31(1):216-22.
8. Muschler GF, Boehm C, Easley K. Aspiration to obtain osteoblast progenitor cells from human bone marrow: the influence of aspiration volume. *J Bone Joint Surg Am.* 1997;79(11):1699-709.
9. Kim GB, Seo MS, Park WT, Lee GW. Bone Marrow Aspirate Concentrate: Its Uses in Osteoarthritis. *Int J Mol Sci.* 2020;21(9):3224.
10. Martin DR, Cox NR, Hathcock TL, Niemeyer GP, Baker HJ. Isolation and characterization of multipotential mesenchymal stem cells from feline bone marrow. *Exp Hematol.* 2002;30(8):879-86.
11. Chahla J, Piuze NS, Mitchell JJ, Dean CS, Pascual-Garrido C, LaPrade RF, et al. Intra-Articular Cellular Therapy for Osteoarthritis and Focal Cartilage Defects of the Knee: A Systematic Review of the Literature and Study Quality Analysis. *J Bone Joint Surg Am.* 2016;98(18):1511-21.
12. Kim JW, Seong TW, Cho S, Kim SJ. Randomized controlled trial on the effectiveness of absorbable collagen sponge after extraction of impacted mandibular third molar: split-mouth design. *BMC oral health.* 2020;20(1):77.
13. Ozawa Y, Kubota T, Yamamoto T, Tsukune N, Koshi R, Nishida T, et al. Comparison of the bone augmentation ability of absorbable collagen sponge with that of hydroxyapatite/collagen composite. *J Oral Sci.* 2018;60(4):514-8.
14. Rosner B. *Fundamentals of biostatistics.* 8th ed. USA: Cengage learning; 2015.
15. Som PM, Curtin HD. *Head and Neck Imaging: Fourth Edition.* 4th ed: Mosby; 2003 November.
16. Devenney-Cakir B, Subramaniam RM, Reddy SM, Imسانده H, Gohel A, Sakai O. Cystic and cystic-appearing lesions of the mandible: review. *AJR Am J Roentgenol.* 2011;196(6 Suppl):WS66-77.
17. Friedlis MF, Centeno CJ. Performing a Better Bone Marrow Aspiration. *Phys Med Rehabil Clin N Am.* 2016;27(4):919-39.
18. Lingamaneni S, Mandadi LR, Pathakota KR. Assessment of healing following low-level laser irradiation after gingivectomy operations using a novel soft tissue healing index: A randomized, double-blind, split-mouth clinical pilot study. *J Indian Soc Periodontol.* 2019;23(1):53-7.
19. Noureldin M, Melek L. Clinical and Radiographic Outcomes of Radicular Cyst Enucleation Using Piezosurgery Versus Conventional Surgery. *Egypt Dent J.* 2020;66(2):943-50.
20. el-mahallawy y, Fahmy M, Elsheikh S, ElAshwah A. Functional evaluation of computer-assisted mandibular reconstruction with iliac crest bone graft. *Alex dent j.* 2022;0(0):0-.
21. Johnson NR, Gannon OM, Savage NW, Batstone MD. Frequency of odontogenic cysts and tumors: a systematic review. *J Investig Clin Dent.* 2014;5(1):9-14.
22. El Gehani R, Krishnan B, Orafi H. The prevalence of inflammatory and developmental odontogenic cysts in a libyan population. *The Libyan journal of medicine.* 2008;3(2):75-7.
23. Jones AV, Craig GT, Franklin CD. Range and demographics of odontogenic cysts diagnosed in a UK population over a 30-year period. *J Oral Pathol Med.* 2006;35(8):500-7.
24. Ibrahim YA, Aly TM, Ragab HR. A comparative study of mandibular cyst enucleation using the piezoelectric surgery versus the conventional technique. *Alexandria Dental Journal.* 2016;41(3):350-6.
25. Aggarwal K, Gupta S, Sood S, Bhardwaj SB, Prashar S, Jain A. Effect of nano-crystalline silver membrane on early wound healing after periodontal surgery: A comparative randomized study. *J Indian Soc Periodontol.* 2021;25(6):504-9.
26. El-ghamrawy AS, Mohammed NS, Melek LN. Clinical and radiographic evaluation of collagenated cortico-cancellous bone graft after mandibular cyst enucleation. *Alexandria Dental Journal.* 2017;42(2):177-81.
27. Pauwels R, Jacobs R, Singer SR, Mupparapu M. CBCT-based bone quality assessment: are Hounsfield units applicable? *Dentomaxillofac Radiol.* 2015;44(1):20140238.

28. Ku J-K, Han M, Yongvikul A, Huh J-K, Kim J-Y. Volumetric analysis of spontaneous bone healing after jaw cyst enucleation. *Sci Rep.* 2022;12(1):14953.
29. Eissa AS, Karam SS, Omar SS, Sayed MI. Effect of autogenous bone marrow mesenchymal stem cells in healing of mandibular osseous defects grafted with beta tricalcium phosphate in dogs. *Alexandria Dental Journal.* 2018;43(3):48-52.
30. Sponer P, Kučera T, Diaz-Garcia D, Filip S. The role of mesenchymal stem cells in bone repair and regeneration. *European journal of orthopaedic surgery & traumatology : orthopedie traumatologie.* 2014;24(3):257-62.
31. Kohno Y, Lin T, Pajarinen J, Romero-Lopez M, Maruyama M, Huang JF, et al. Osteogenic ability of rat bone marrow concentrate is at least as efficacious as mesenchymal stem cells in vitro. *Journal of biomedical materials research Part B, Applied biomaterials.* 2019;107(8):2500-6.
32. Gianakos A, Ni A, Zambrana L, Kennedy JG, Lane JM. Bone Marrow Aspirate Concentrate in Animal Long Bone Healing: An Analysis of Basic Science Evidence. *Journal of orthopaedic trauma.* 2016;30(1):1-9.
33. Pelegrine AA, Teixeira ML, Sperandio M, Almada TS, Kahnberg KE, Pasquali PJ, et al. Can bone marrow aspirate concentrate change the mineralization pattern of the anterior maxilla treated with xenografts? A preliminary study. *Contemp Clin Dent.* 2016;7(1):21-6.
34. Ting M, Afshar P, Adhami A, Braid SM, Suzuki JB. Maxillary sinus augmentation using chairside bone marrow aspirate concentrates for implant site development: a systematic review of histomorphometric studies. *Int J Implant Dent.* 2018;4(1):25.