

## Effects of Chronic Use of Tramadol on Uterus and Ovary of Albino Rats

Hatem Ali Ahmed Abd El-Mottaleb<sup>1</sup>, Shrief Fahmy Mahmoud<sup>1</sup>, Ashraf Ibrahim Hassan<sup>1</sup>,

Al-Sayed Mohamed Ibrahim Tealeb<sup>2</sup> and Gamal Zakaria Almorsy<sup>3</sup>

Departments of <sup>1</sup>Forensic Medicine and Toxicology, <sup>2</sup>Pathology, and <sup>3</sup>Clinical Pathology

Faculty of Medicine, Al-Azhar University

**Corresponding author:** Hatem Ali Ahmed Abd El-Mottaleb e-mail:dr.hatemali84@yahoo.com,

Mobile: 01007766568

### ABSTRACT

**Backgrounds:** The researches on endocrinopathy related with oral opioids had focused more on males, while fewer studies had focused on females. **Objective:** it was to demonstrate the possible chronic tramadol toxic effect (histopathological & biochemical) on ovary and endometrium of adult female albino rats.

**Materials and methods:** Twenty-five female rats (control group), were given normal food and water, while one hundred adult female rats were given 30 mg/kg/day tramadol dissolved in distilled water (which represent 1/10 LD50) on daily basis for each rat for 3 months (An average 0.6ml for each rat). Rats were weighted at the beginning of the study and then 2 times weekly. At end of this period, blood samples were taken for Biochemical analysis. Rats' ovaries and uterus were examined by light microscope after staining with Haematoxylin and Eosin, and then data were analyzed and statistically studied. **Results:** Our study showed gradual decrease in female body weight and levels of sex hormones. In tramadol treated group, ovaries showed apparent decrease in the number of growing follicles and an increase in the number of corpora lutea. The medulla showed dilated congested blood vessels. Many of the follicles appeared atretic. In the corpora lutea, there were degenerated cells. While endometrium in tramadol treated group there was apparent atrophic glands and stroma in the surface of the endometrium with appearance of inflammatory cells in the stroma.

**Conclusion:** it has harmful histopathological and functional effects on the reproductive organs of female albino rats.

**Keywords:** tramadol, ovary, uterus, rat.

### INTRODUCTION

Chronic pain is one of the most common problems in medicine and despite the recent introduction of new painkillers; opioid analgesic drugs are still considered the most effective therapies for treatment of moderate to severe pain<sup>(1)</sup>. Tramadol is centrally acting analgesic with weak opioid action. Prolonged use of opioids may induce addiction resulting in physical and psychological dependence<sup>(2)</sup>. Tramadol is a commonly abused drug in Egypt especially among youth. Tramadol abuse has dramatically increased in Egypt since 2008 and has led to many admissions to addiction treatment centers<sup>(3)</sup>. In a study by Abbas *et al.* <sup>(4)</sup>, done in Zagazig Governmental Hospitals, Egypt, demonstrated that tramadol was found to be the second most common substance abused after cannabis (Bango). According to the records of Poisoning Control Center (PCC) of Ain Shams University Hospitals in Egypt, there are trading jumps in numbers of admitted patients with tramadol toxicity in the last few years <sup>(5)</sup>. The widespread of tramadol use is due to its availability through illegal marketing, its easily illegal smuggling and its cheap prices <sup>(6)</sup>.

Studies have shown that opioid therapy leads to impaired endocrine function and dysregulated sex steroid balance in women. Longterm opioid use exposes women to unique risks, including endocrinopathy, reduced fertility <sup>(7)</sup>. More than half of the opioid-taking women aged 30–50 had nonsurgical amenorrhea (52%), compared with 20% of the control

group, suggesting opioid-induced endocrinopathy <sup>(8)</sup>. Symptoms and signs of sex hormone deficiency occur in both men and women but are under-reported and are often clinically unrecognized <sup>(8)</sup>.

The potential effects of long term opioid therapy on the endocrine system should be explained to patients before opioid therapy is commenced. Monitoring of sex hormones is recommended; if there are deficiencies opioids should be tapered and withdrawn, if this is clinically acceptable.

If opioid therapy has to continue, hormone replacement therapy should be initiated and monitored by an endocrinologist <sup>(9)</sup>.

### AIM OF THE WORK

The present study aims to demonstrate the possible chronic toxic effects (histopathological and biochemical) of tramadol on both the ovary and the uterine endometrium of adult female albino rats.

### MATERIALS AND METHODS

#### A) Materials

**1-** Tramadol hydrochloride (TH) purchased from Mina Pharm Egypt. Each tablet of tramadol contains 100mg.

**2- Kits:** Kits for determination of serum Estrogen, Progesterone, Follicular Stimulating Hormone (FSH) and Luteinizing hormone (LH) purchased from Roche Diagnostics Sandhofer in Germany.

**Animals:**

One hundred and twenty five (125) female adult healthy albino rats weighting 180 – 220 gm were obtained from the animal house, Faculty of Medicine, Assiut University, Egypt. This study was conducted in accordance with ethical procedures and policies approved by Animal Care and Use Committee of Faculty of Medicine, Al-Azhar University, Cairo, Egypt.

Rats were housed in clean capacious macro-lane cages under standard laboratory conditions including good aerated room with suitable temperature, relative humidity, maintained at good light with alternating 12 hours light/dark cycles and were given standard food and water. Rats were acclimatized and monitored under lab. conditions for a month to exclude any pregnancy.

**(B) Methods****Experimental design:**

**Group 1 (Control group):** Twenty five adult female albino rats were given normal food and water. The current work was done on 125 adult female albino rats. Twenty five female rates were divided into two groups (positive control and negative control) the positive control group (15 female rates) and the negative control group (10 female rates) were not given any saline but only the normal food and water and. One hundred adult female albino rats were given 30 mg/kg/day tramadol dissolved in distilled water orally by gavage tube (which represent 1/10 LD50) for 3 consecutive months, and all the adult female albino rats obtained from the animal house of Faculty of Medicine, Assiut University.

**Group 2 (Tramadol treated group):** One hundred females were given 30 mg/kg/day tramadol dissolved in distilled water (which represent 1/10 LD50) for 3 months. With an average 0.6ml/rat, given orally by a curved needle-like oral tube that was introduced directly into stomach (gavage process). Rats were weighted at the beginning of the study and then 2 times weekly until the end of work to calculate the dose of the drug according to the weight and to determine the effect of tramadol on weight of rats. At end of this period, before scarification, blood samples were taken. Then, examination of possible histopathological changes in ovaries and uterine endometrium were done.

**(I) Biochemical analysis:**

Three milliliters of blood was collected from retro-orbital veins of each rat of control and treated rat groups in glass vial (Vacutainer tube) without anticoagulant (5ml capacity). Blood samples were held on ice and serum was obtained by centrifugation of samples at 2000 rpm for 15 minute within one hour of

collection. Serum samples were stored at -20°C until the day of analysis. Serum levels of FSH, Luteinizing hormone LH, Estrogen and Progesterone were determined in female rats of all groups using enzyme-linked immunosorbent assay (ELISA) kits (Diagnostics Systems Laboratories, Webster, TX) according to manufacturer's manual.

**(II) Histopathological examination:** Rats were sacrificed by decapitation using light ether anesthesia. Identification of the pituitary gland and ovaries was done. Ovaries and uterus from female rats of all groups were fixed in 10% Formalin, dehydrated through ascending grades of alcohol, cleared and then embedded in paraffin. Paraffin sections of 5 µm thickness were prepared and stained with Haematoxylin and Eosin. The stained sections were examined using light microscope according to Bancroft and Gamble<sup>(10)</sup>.

**Statistical Analysis**

The data were tested for normality using the Anderson-Darling test and for homogeneity variances prior to further statistical analysis. Continuous variables described by mean and standard error (Mean, SE). Comparison between continuous variables was done by student t-test. The two-tailed  $p < 0.05$  value was considered statistically significant. All analyses were performed with the IBM Statistical Package for Social Sciences (SPSS) program version 20.0 software.

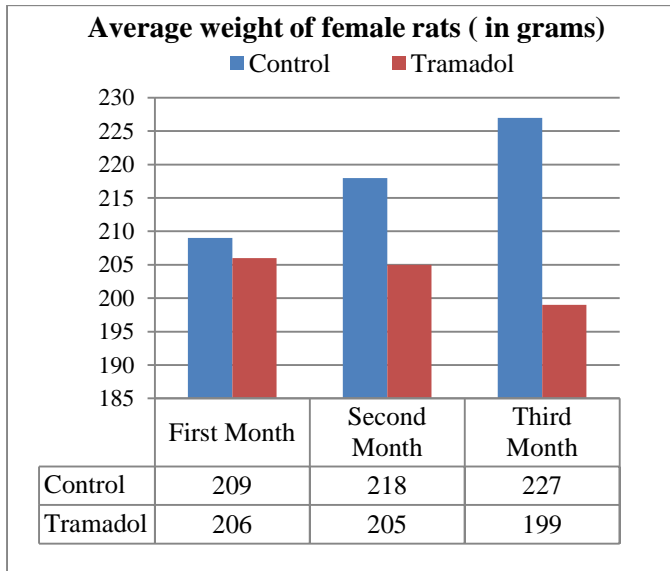
**RESULTS****(1) Total body weight:**

Table (1) and figure (1) show total body weight of control and tramadol-treated female rats. There is no significant statistical decrease in the total body weight at the end of the first month of the study in the tramadol-treated rats compared with the control rats, with significant statistical decrease at the end of the second months and highly significant statistical decrease at the end of the third months.

**Table (1): Changes in mean total body weight of control and tramadol-treated adult female albino rats monthly for three months**

Female total body weight (gm)	control	Tramadol	P.value
	Mean±SE	Mean±SE	
One month	209.0±0.307	206.83±0.307	0.097
Two months	218.0±0.407	205±0.632	0.013*
Three months	227.0±0.312	199±0.922	<0.001**

NB. Student t-test statistical difference analysis, non-significant difference ( $p > 0.05$ ), \*Statistically significant difference ( $p < 0.05$ ), \*\*Statistically highly significant ( $p < 0.01$ )



**Figure (1): Comparison between total body weight of control and tramadol-treated female rats**

**(2) Biochemical analysis:**

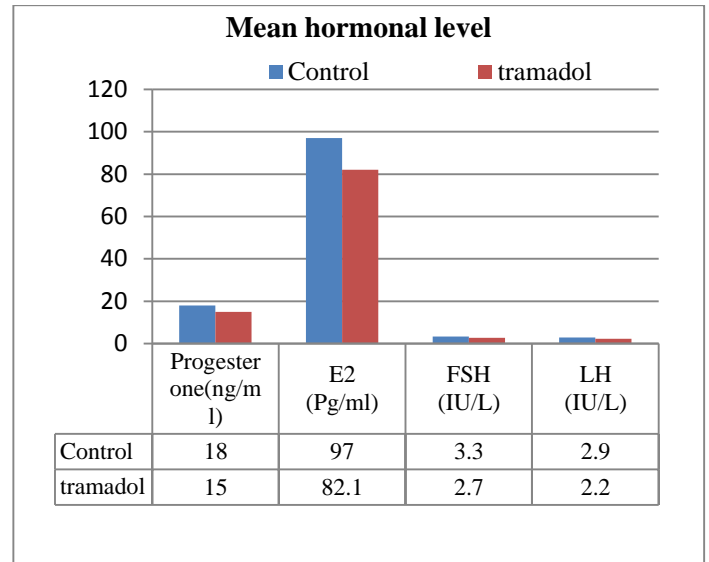
Table (2) and Figure (2) show concentration of serum progesterone, estradiol (E2), LH and FSH in the control and tramadol-treated female rats.

There is a significant statistical decrease in serum levels of progesterone, estrogen, LH and FSH in tramadol-treated female rats compared with the control female rats.

**Table (2): concentration of serum progesterone, estradiol (E2), LH and FSH in the control and tramadol-treated adult female albino rats**

Bbiochemical analysis	Control	tramadol	P. value
	Mean+SE	Mean+SE	
Progesterone(ng/ml)	18+0.01	15+0.17	0.001**
E2 (Pg/ml)	97+0.01	82.1+2.82	0.001**
FSH (IU/L)	3.3+0.02	2.7+0.04	0.002**
LH (IU/L)	2.9+0.01	2.2+0.05	0.003**

**NB.** Statistically non-significant difference ( $p>0.05$ ),  
 \*Statistically significant difference ( $p<0.05$ )  
 \*\*Statistically highly significant difference ( $p<0.01$ )



**Figure (2): Comparison between concentration of serum progesterone, estradiol (E2), LH and FSH in the control and tramadol-treated female rats.**

**3) Histopathological results:**

**1-Ovaries:**

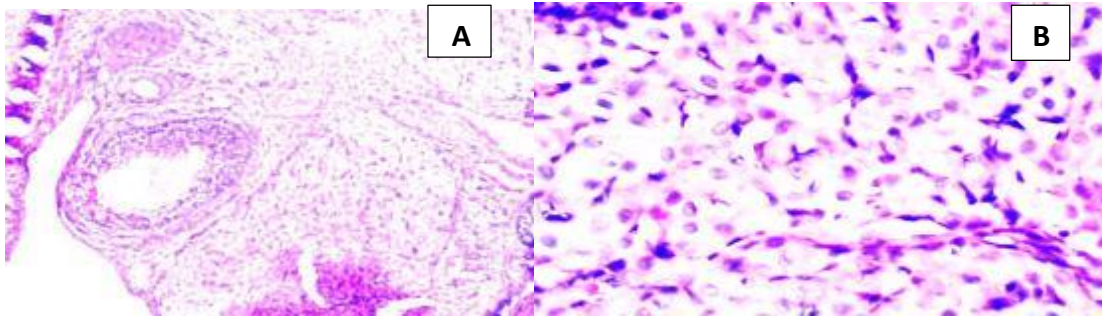
**1-Control group:** H&E showed no histopathological changes in the cortex and medulla as seen in figures (3)

**II- Tramadol treated group:** apparent decrease in the number of growing follicles, and many of the follicles appeared atretic. Granulosa cells showed an apparent increase of pyknosis and absence of antral cavity. Corpora lutea showed degenerated cells that appeared with deeply stained acidophilic cytoplasm and eccentric pyknotic nuclei with an increase in the number of corpora lutea. Medulla showed dilated congested blood vessels. These are seen in figures (5,6,7,8).

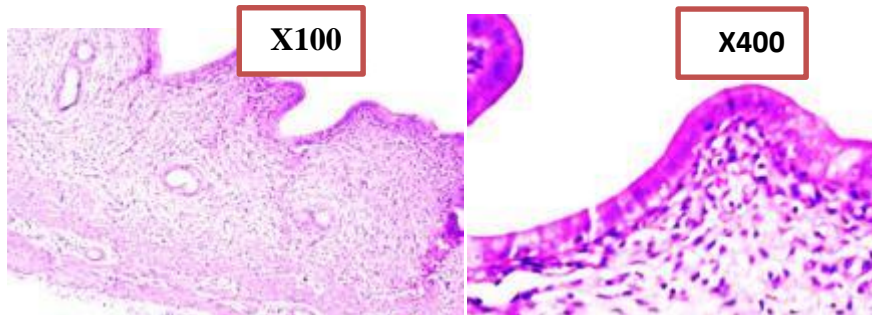
**2-Uterus:**

**1-Control group:** normal histological architecture as seen in figures (4)

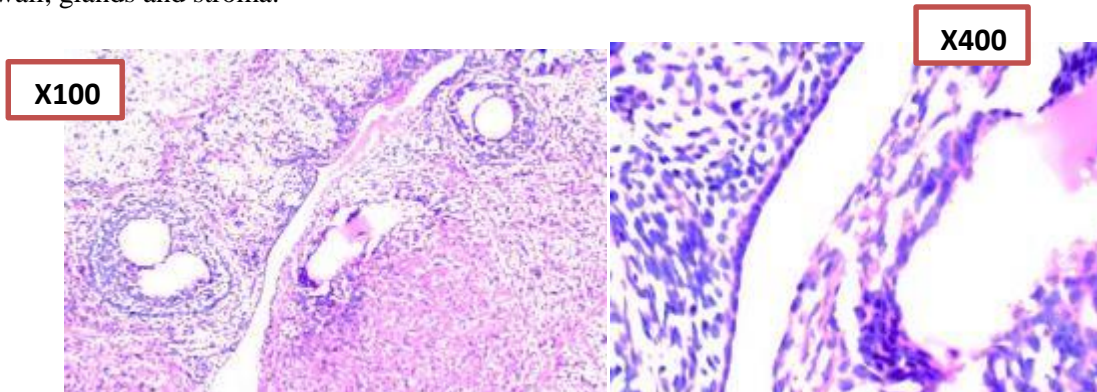
**2- Tramadol treated group:** apparent atrophic glands and stroma in the surface of the endometrium with appearance of inflammatory cells in the stroma, in the same time there was hyperplastic glands in the endometrium, as seen in figures (9,10,11).



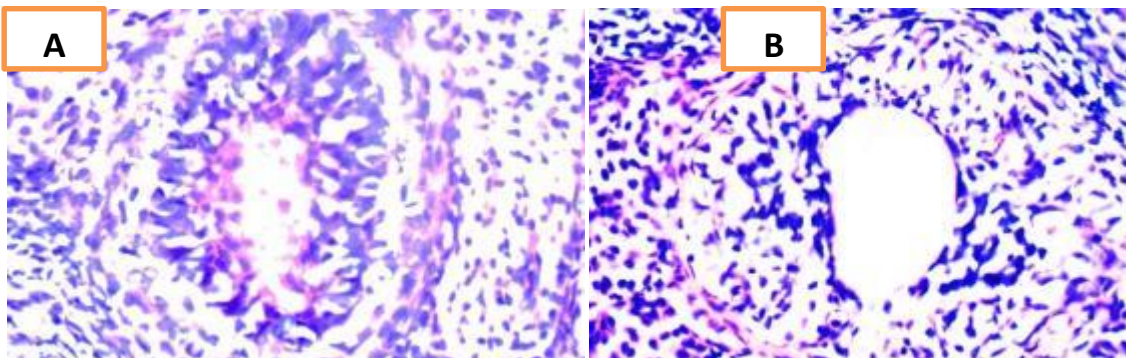
**Figure (3):** photographs of a section in the ovary of the control rat group stained with H & E, in which (A) shows normal ovary with mature follicles in various stages of maturation. (x 100), (B) ovarian follicles (x400)



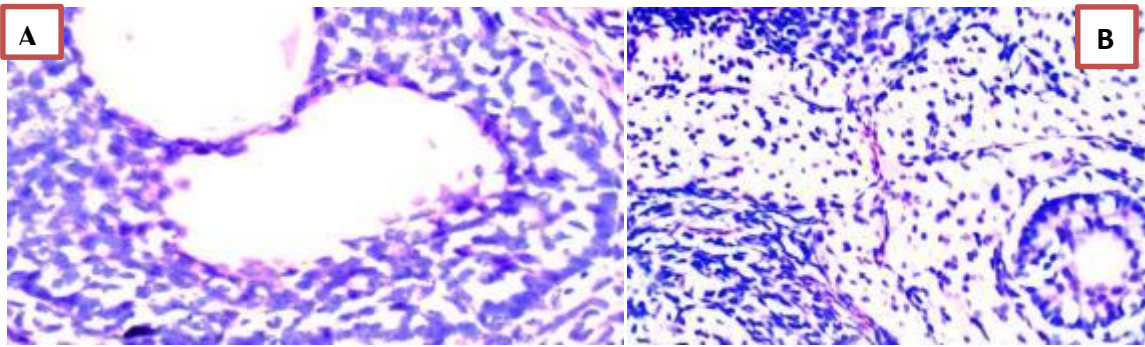
**Figure (4):** photograph of a section in the uterus of the control rat group stained with H & E showing normal uterine wall, glands and stroma.



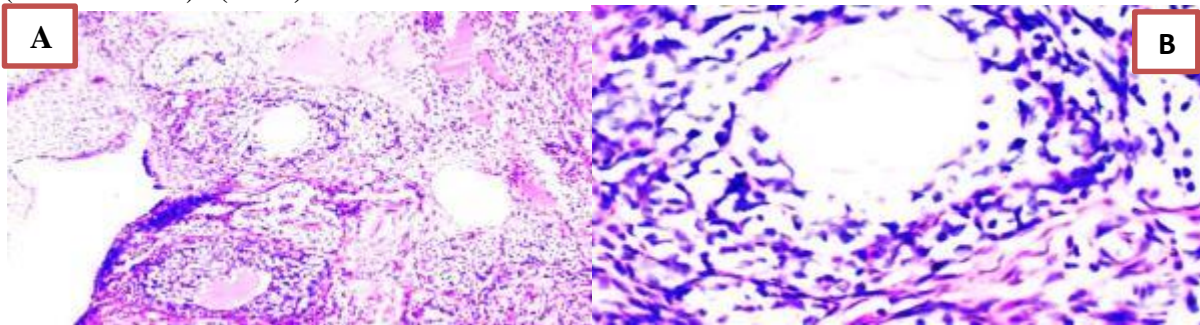
**Figure (5):** A photograph of a section in the ovary of the tramadol treated rat group stained with H & E showing; degenerative changes in follicles.



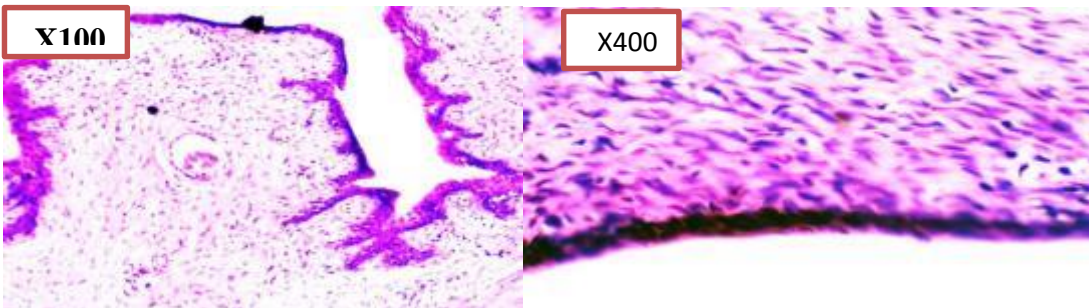
**Figure (6):** A photograph of a section in the ovary of the tramadol treated rat group stained with H & E where (A) shows fibrosis in the stroma. (x 400) and (B) shows cystic changes. (x 400).



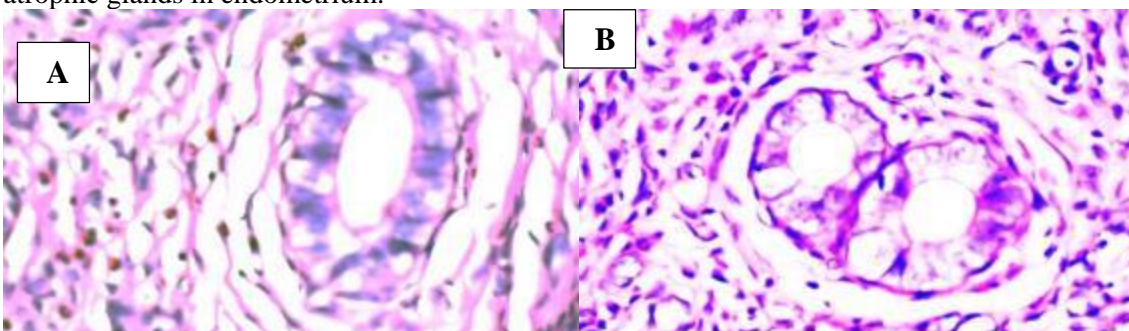
**Figure (7):** A photograph of an ovarian section of the tramadol treated rat group stained with H & E showing in (A) degenerative changes in follicular cells (vacuolation) while (B) shows degenerative changes in stroma (vacuolated cells). (x 400)



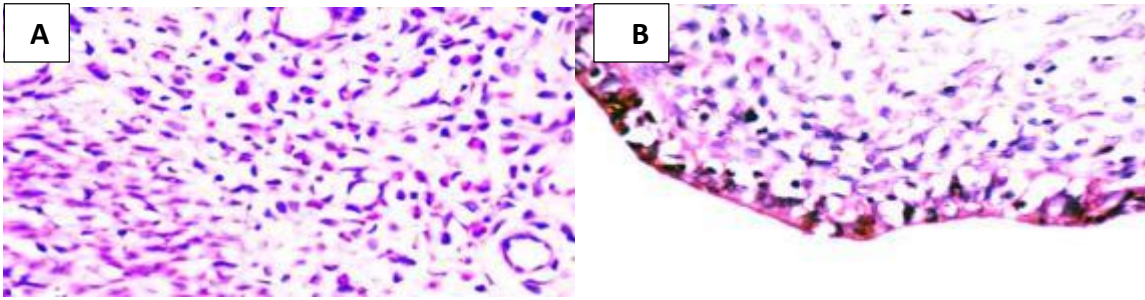
**Figure (8):** A photograph of a section in the ovary of the tramadol treated rat group stained with H & E where (A) shows degenerative changes in the stroma and follicles (granulosa cells). (x 400) while (B) shows degenerative changes in stroma. (x 100)



**Figure (9):** A photograph of a section in the uterus of the tramadol treated rat group stained with H & E showing atrophic glands in endometrium.



**Figure (10):** A photograph of a section in the uterus of the tramadol treated rat group stained with H & E where (A) shows atrophic surface glands with degenerated stroma (vacuolated cells) and (B) shows hyperplastic endometrial glands (cells with nucleoli). (x400)



**Figure (11):** A photograph of a section in the uterus of the tramadol treated rat group stained with H & E where (A) shows endometrium hyperplastic glands (cells with nucleoli) while (B) shows stroma with inflammatory cells and atrophic glands. (x 400)

## DISCUSSION

Toxicity to tramadol can happen to those who take overdoses of the drug as a treatment of different types of pain as well as those who abuse it<sup>(11)</sup>.

The study of **Paulis and Abbas**<sup>(12)</sup> mentioned that tramadol administration to female rats diminished both pituitary sex hormones (LH and FSH) and gonadal hormones (estrogen and progesterone). So, the present study was carried out to demonstrate the possible histopathological toxic effect of chronic tramadol administration on ovaries and uterus of adult female albino rats.

Our study showed progressive decrease of body weight of female rats given 30 mg/kg/day for three months which is in accordance with studies of **Shuey et al.**<sup>(13)</sup> and **Paulis and Abbas**<sup>(12)</sup> who reported that there was significant decrease in body weight in female rats treated with tramadol in a dose of 40mg/kg and body weight loss in rats received tramadol in adose of 80mg/kg for 8 weeks. The loss of body weight in some of those taking the drug may be attributed to its gastrointestinal side effect including loss of appetite<sup>(14)</sup>. In contrast to this, **Ahmed and Kurkar**<sup>(15)</sup>, found that tramadol did not affect the final body weight of male rats. This difference may be attributed to different dose of tramadol (40mg/kg 3 times weekly for 8 weeks or may be related to sex difference.

**Paulis and Abbas**<sup>(12)</sup>, study demonstrated that chronic tramadol administration in female rats diminished both pituitary sex hormones; LH and FSH. It is well established that opioids decrease the release of GnRH or interfere with its normal pulsatility at the level of the hypothalamus, resulting in a decreased release of LH and FSH from the pituitary gland<sup>(16, 17, 18)</sup>.

Our work demonstrated significant statistical decrease in serum levels of progesterone and estrogen in tramadol-treated female rats compared with the control female rats, which goes in harmony with results of **Paulis and Abbas**<sup>(12)</sup> who reported that,

tramadol significantly decrease gonadal hormones estrogen and progesterone in female rats.

Our study showed apparent decrease in the number of growing follicles, with many atretic follicles. Granulose cells showed an apparent increase of pyknosis and absence of antral cavity. There was an increase in the number of corpora lutea. Corpora lutea showed degenerated cells that appeared with deeply stained acidophilic cytoplasm and eccentric pyknotic nuclei. Medulla showed dilated congested blood vessels.

Our study also showed in tramadol treated group apparent atrophic glands and stroma with appearance of inflammatory cells in the stroma with increase of cellularity and hypertrophy of the endometrial glands which is in agreement with the study of **El-Ghawet**<sup>(19)</sup> which led to decrease secretory function of the endometrial glands.

## CONCLUSION

Chronic tramadol use or abuse has adverse harmful histopathological and functional effects on the reproductive organs of female albino rats.

## REFERENCES

- Vazzana MA, Andreani BC, Fangueiro JD et al. (2015):** Tramadol hydrochloride: Pharmacokinetics, pharmacodynamics, adverse side effects, co-administration of drugs and new drug delivery systems. *Biomedicine & Pharmacotherapy*, 70: 234–238.
- Zhang H and Liu H (2013):** The investigation of tramadol dependence with no history of substance abuse: a cross-sectional survey of spontaneously reported cases in Guangzhou city, China., *Biomed Res Int.*, 12:283-425
- Abolmaged S, Kodera A, Okasha T et al. (2013):** Tramadol use in Egypt: Emergence of a major new public health problem. *Can. J. Addiction Med.*, 4(1): 5-7.
- Abbas RA, Hammam RA, El-Gohary SS et al. (2013):** Screening for common mental disorders and substance abuse among temporary hired cleaners in Egyptian Governmental Hospitals, Zagazig City, Sharqia Governorate. In *J Occup Environ Med.*, 4(1):13-26.

5. **Fouad S, Hassan N and Nassief N (2015):** Critical score as a predictor for progression of tramadol intoxication. *J Clin Toxicol.*, 5: 249-255.
6. **Fawzi M (2011):** Some medicolegal aspects concerning tramadol abuse: The new Middle East youth plague. An Egyptian overview *Egyptian Journal of Forensic Sciences*, 1: 99–102.
7. **Daniell HW (2008):** Opioid endocrinopathy in women consuming prescribed sustained-action opioids for control of nonmalignant pain. *J Pain*, 9(1):28–36.
8. **Beth DD, Brett RS and Chou R (2012):** Medical and psychological risks and consequences of long term opioid therapy in women, *Pain Med.*, 13(9): 1181–1211.
9. **Seyfried O, Hester J (2012):** Opioids and endocrine dysfunction. *Br J Pain*, 6(1):17-24.
10. **Bancroft JD, Gamble M (2002):** Theory and Practice of Histological Technique. (5th edition), Churchill Livingstone, Edinburg, London. <https://www.sigmaaldrich.com/catalog/product/sigma/t5321?lang=en&region=EG>
11. **Shadnia S, Soltaninejad K, Heydari K et al. (2008):** Tramadol intoxication: a review of 114 cases. *Hum. Exp. Toxicol.*, 27(3): 201-05.
12. **Paulis MG, Abbas MF (2015):** Tramadol subchronic toxicity on pituitary-gonadal axis and ovarian functions in adult female rats. *First international forensic medicine and clinical toxicology Conference*, Minia University, Available at: [https://www.researchgate.net/publication/299612495\\_Tramadol\\_toxicity\\_onpituitary-gonadal\\_axis\\_and\\_ovarian\\_functions\\_in\\_female\\_rats](https://www.researchgate.net/publication/299612495_Tramadol_toxicity_onpituitary-gonadal_axis_and_ovarian_functions_in_female_rats)
13. **Shuey DL, Stump DG, Carliss RD et al. (2008):** Effects of the opioid analgesic oxymorphone hydrochloride on reproductive function in male and female rats. *Birth Defects Res B Dev Reprod Toxicol.*, 83(1): 12-18.
14. **Jolobe O (2015):** Tramadol-related hypoglycaemia and tramadol-induced anorexia. *Br J Hosp Med.*, 76(4):249-256.
15. **Ahmed MA, Kurkar A (2014):** Effects of opioid (tramadol) treatment on testicular functions in adult male rats: The role of nitric oxide and oxidative stress. *Clin Exp Pharmacol Physiol.*, 41(4):317-23.
16. **Colameco S, Coren JS (2009):** Opioid-induced endocrinopathy. *J Am Osteopath Assoc.*, 109(1):20-5.
17. **Katz N, Mazer NA (2009):** The impact of opioids on the endocrine system. *Clin J Pain*, 25(2):170-5.
18. **Seyfried O, Hester J (2012):** Opioids and endocrine dysfunction *British Journal of Pain*, 6(1): 17–24.
19. **El-Ghawet HA (2015):** Effects of tramadol on the reproductive function of wistar albino rats. *Euro J Exp Bio.*, 5(1):56-64.